

CLINICAL IMAGE

Primary solitary extramedullary plasmacytoma progressing to multiple bone plasmacytomas: a rare condition with therapeutic dilemmas

Anna Suska¹, Łukasz Chmura², Grzegorz Dyduch², Bogdan Małkowski³, Artur Jurczyszyn¹

¹ Department of Hematology, Jagiellonian University Medical College, Kraków, Poland

² Department of Pathomorphology, Jagiellonian University Medical College, Kraków, Poland

³ Department of Nuclear Medicine, Center of Oncology, Bydgoszcz, Poland

A 54-year-old woman presented with a pea-sized solid lump in the sacral region, surrounded by a red areola and neither painful nor itchy. A histopathologic examination showed diffuse infiltrate (**FIGURE 1A**) composed of atypical plasma cells positive for light chains (**FIGURE 1B**), CD56, CD138 (Supplementary material, *Figure S1*) and negative for CD3, CD20, CD30, CD123, anaplastic lymphoma kinase and κ light chains (Supplementary material, *Figure S2*), with a Ki-67 proliferation index of 50%. The lesion was identified as an extramedullary plasmacytoma. Intact immunoglobulins and free light chains remained within normal limits, and a slightly separated immunoglobulin A zone was revealed on immunofixation. No protein was detected on urinalysis. Bone marrow trephine biopsy showed 4% to 5% of dispersed CD138⁺ plasma cells with a normal immunohistochemical reaction to light (κ/λ) chains (**FIGURE 1C**). Fusion positron-emission tomography-computed tomography (PET-CT) revealed a mass with an elevated

standardized uptake, infiltrating the ascending colon wall, and an osteolytic lesion in the right ischial tuberosity (**FIGURE 1D** and **1E**).

Given the risk of colon perforation, the patient underwent right hemicolectomy. The colonic lesion was identified as an extramedullary plasmacytoma infiltrating the intestinal muscular layer and focally invading the serosa, without angioinvasion and with negative surgical margins. The patient received radiotherapy to the right ischial tuberosity area (50 Gy in 25 fractions), which resulted in complete hematologic remission (CR). However, PET-CT performed a month later showed disease progression, with a focal increase in ¹⁸F-fluoro-ethyl-tyrosine uptake in the sternum, multiple plasmacytomas in the left fourth rib, and a persisting osteolytic lesion in the right ischial tuberosity (**FIGURE 1F-1H**). After achieving complete remission with 6 cycles of VTD (bortezomib, thalidomide, dexamethasone), the patient underwent tandem autologous hematopoietic

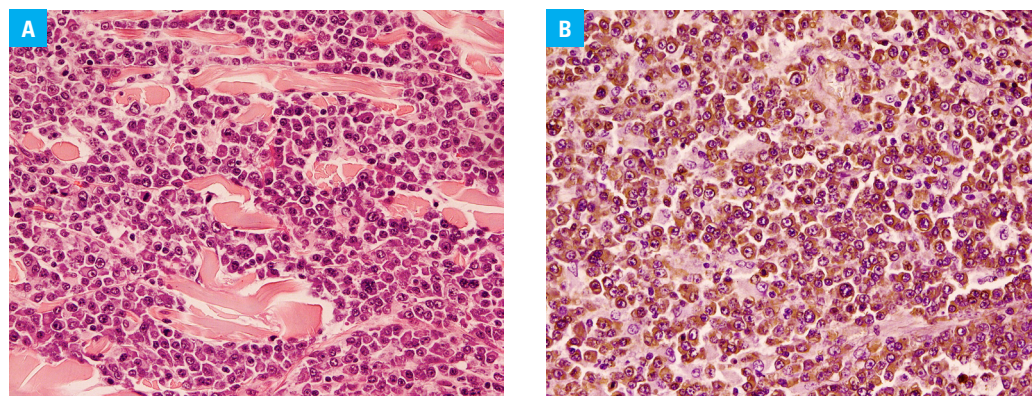


FIGURE 1 A, B – histopathologic specimen obtained from the skin lump: **A** – plasma cells with eosinophilic cytoplasm and round nucleus with granular chromatin (hematoxylin and eosin staining, $\times 400$); **B** – positive immunohistochemical reaction to λ light chains ($\times 400$).

Correspondence to:

Artur Jurczyszyn, MD, PhD,
Department of Hematology,
Jagiellonian University Medical
College, ul. Kopernika 17,
31-501 Kraków, Poland,
phone: +48 12 424 74 26,
email: mmjurczy@cyf-kr.edu.pl

Received: September 30, 2018.

Revision accepted: October 12, 2018.

Published online: October 18, 2018.

Conflict of interest: none declared.

Pol Arch Intern Med. 2018;

128 (11): 706-708

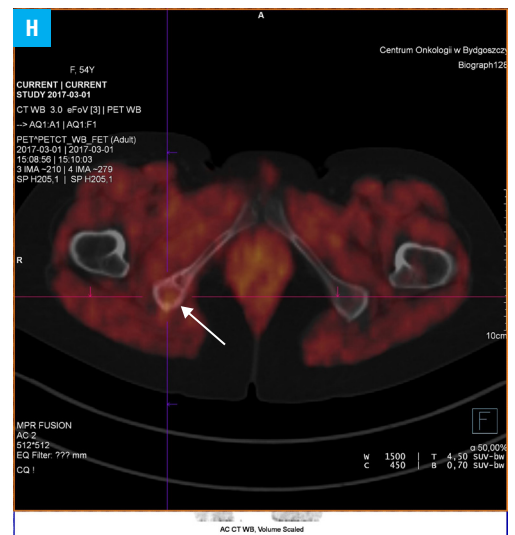
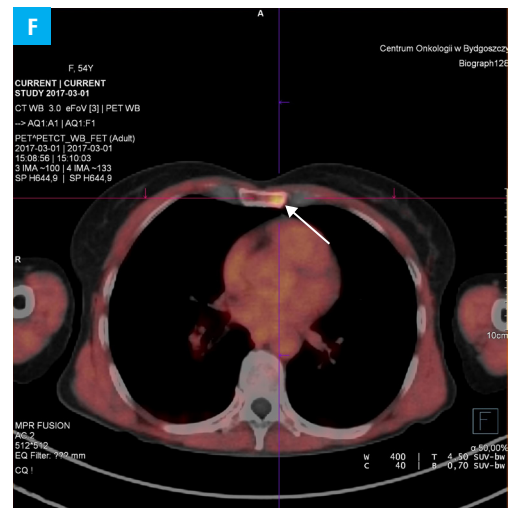
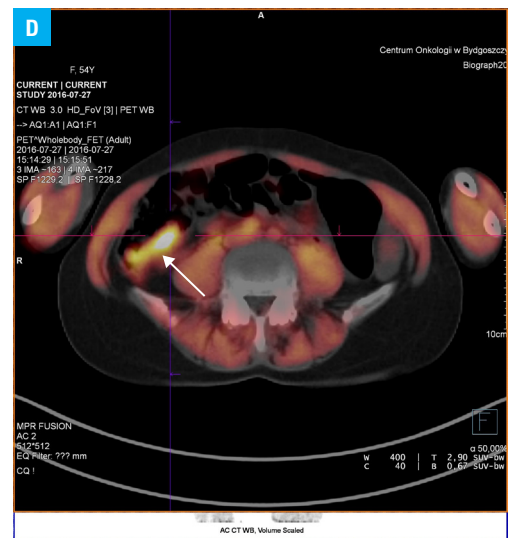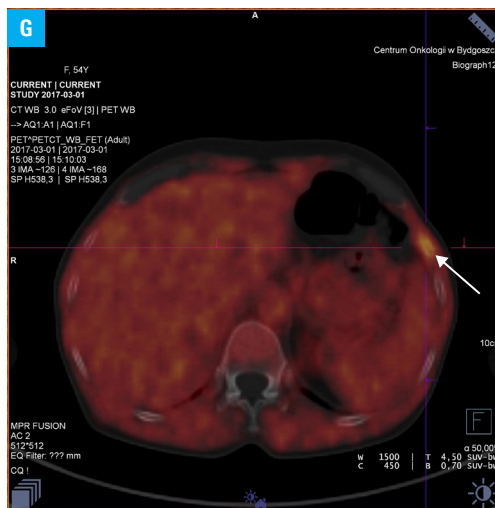
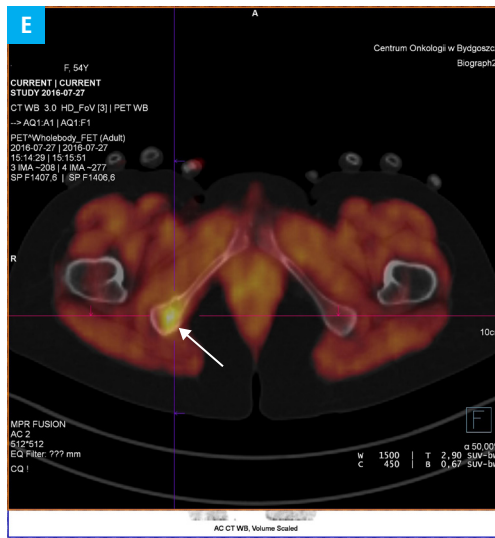
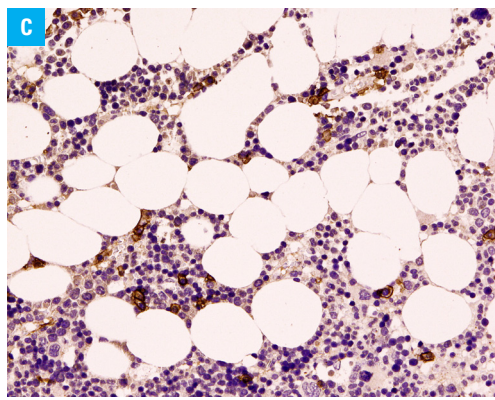
doi:10.20452/pamw.4353

Copyright by Medycyna Praktyczna,

Kraków 2018

FIGURE 1

C – bone marrow trephine biopsy; positive immunohistochemical reaction to CD138 ($\times 400$). **D, E, F, G, H** – positron-emission tomography-computed tomography scan in axial plane: **D** – a mass ($39 \times 13 \times 42$ mm) infiltrating the ascending colon wall; enhanced ^{18}F -fluoro-ethyl-tyrosine uptake (^{18}F -FET; standardized uptake value [SUV], 4.12); **E** – an osteolytic lesion (diameter, 9 mm) in the right ischial tuberosity (arrow); enhanced ^{18}F -FET uptake (SUV, 2.9); **F** – focal increase in ^{18}F -FET uptake (11×9 mm; SUV, 3.64) in the sternum, at the level of the left fourth rib attachment (arrow); **G** – focal increase in ^{18}F -FET uptake (SUV, 2.94) in the left fourth rib (arrow); **H** – an osteolytic lesion (16×17 mm) in the right ischial tuberosity (arrow); enhanced ^{18}F -FET uptake (SUV, 2.27)



stem cell transplantation (auto-HSCT), followed by consolidation VDT-PACE therapy (bortezomib, dexamethasone, thalidomide, cisplatin, doxorubicin, cyclophosphamide, etoposide). Currently, 6 months after auto-HSCT, she shows no signs of progression.

Solitary plasmacytoma is rare, representing less than 5% of plasma cell malignancies. It may present as a single bone lesion, solitary bone

plasmacytoma (SBP), or as a soft tissue mass, extramedullary plasmacytoma (EMP).¹ EMP may develop in any tissue but is primarily found in the head and neck region, gastrointestinal tract, and lungs.² SBP is more likely to progress to multiple myeloma (MM) (3-year progression rate, 60% vs 20% for EMP).³ Solitary plasmacytoma can be diagnosed if biopsy shows clonal plasma cell infiltration of the lesion, with no or minimal (<10%)

bone marrow involvement, normal skeletal survey results, no additional lesions on spinal and pelvic magnetic resonance imaging (or computed tomography), and no features of end-organ damage.³ Both SBP and EMP are treated locally (fractionated radiotherapy, 40–50 Gy, with at least 2-cm margin of normal tissue).^{1–4} Surgery, followed by radiotherapy, should be considered in patients with pathological fractures, large and well-defined soft tissue lesions, or high risk of complications.¹ Chemotherapy, using the same protocols as for MM, including high-dose chemotherapy followed by auto-HSCT in younger patients, is indicated in refractory disease or relapse.⁴ However, in some countries, especially those in Central and Eastern Europe, inadequate access to advanced antimyeloma therapy, including auto-HSCT, may limit treatment success.⁵

SUPPLEMENTARY MATERIAL Supplementary material is available with the article at www.pamw.pl.

OPEN ACCESS This is an Open Access article distributed under the terms of the Creative Commons Attribution-NonCommercial-ShareAlike 4.0 International License ([CC BY-NC-SA 4.0](https://creativecommons.org/licenses/by-nc-sa/4.0/)), allowing third parties to copy and redistribute the material in any medium or format and to remix, transform, and build upon the material, provided the original work is properly cited, distributed under the same license, and used for non-commercial purposes only. For commercial use, please contact the journal office at pamw@mp.pl.

REFERENCES

- 1 Caers J, Paiva B, Zamagni E, et al. Diagnosis, treatment, and response assessment in solitary plasmacytoma: updated recommendations from a European Expert Panel. *J Hematol Oncol*. 2018; 11: 1-10. [↗](#)
- 2 Nahi H, Genell A, Wälinder G, et al. Incidence, characteristics, and outcome of solitary plasmacytoma and plasma cell leukemia: population-based data from the Swedish Myeloma Register. *Eur J Haematol*. 2017; 99: 216-222. [↗](#)
- 3 Rajkumar SV, Dimopoulos MA, Palumbo A, et al. International Myeloma Working Group updated criteria for the diagnosis of multiple myeloma. *Lancet Oncol*. 2014; 15: e538-e548.
- 4 Soutar R, Lucraft H, Jackson G, et al. Guidelines on the diagnosis and management of solitary plasmacytoma of bone and solitary extramedullary plasmacytoma. *Br J Haematol*. 2004; 16: 405-413.
- 5 Coriu D, Dytfeld D, Niepel D, et al. Real-world multiple myeloma management practice patterns and outcomes in six Central and Eastern European countries. *Pol Arch Intern Med*. 2018; 128: 500-511. [↗](#)