



FOLIA MEDICA CRACOVIENSIA
Vol. LVIII, 1, 2018: 107–111
PL ISSN 0015-5616

The median nerve penetrating through the radial head of the flexor digitorum superficialis muscle: Case report

MACIEJ LIS¹, BERNARD SOLEWSKI¹, MATEUSZ KOZIEJ¹, EWA WALOCHA²,
JERZY A. WALOCHA¹, WIESŁAWA KLIMEK-PIOTROWSKA¹

¹Department of Anatomy, Jagiellonian University Medical College, Kraków, Poland

²Department of Clinical Nursing, Institute of Nursing and Obstetrics, Jagiellonian University Medical College
Kraków, Poland

Corresponding author: Maciej Lis

Department of Anatomy, Jagiellonian University Medical College

ul. Kopernika 12, 31-034 Kraków, Poland

Phone/Fax: +48 12 422 95 11; E-mail: maciej97.lis@gmail.com

Abstract: The forearm is a body region of numerous anatomical variations. Due to its favorable anatomy flexor digitorum superficialis muscle (FDS) is commonly used in tendon transfer surgeries. In this study a unique combination of abnormalities was found in a single forearm: the flexor digitorum superficialis muscle penetrated by the median nerve, one of the flexor digitorum superficialis tendons early division and absence of the palmaris longus muscle. Described variation potentially may lead to the clinical manifestation of the median nerve compression and should be also considered during FDS surgery.

Key words: anatomic variation, flexor digitorum superficialis, median nerve; palmaris longus; tendon transfer.

Introduction

The median nerve originates from a fusion of medial (C_8-T_1) and lateral (C_5-C_7) roots in the axillary fossa. It travels distally in medial bicipital sulcus of the arm together with the brachial artery as a neurovascular bundle. It descends to the cubital fossa and then traverses three consecutive structures — the bicipital aponeurosis, Y — shaped convergence formed by heads of pronator teres muscle and second Y — shaped

convergence, but now formed by the heads of flexor digitorum superficialis (FDS). Then it situates between the flexor digitorum profundus and flexor digitorum superficialis muscles [1]. In the lower part of the forearm, the median nerve lies more superficially, due to FDS muscle turning into separate tendons. Just before entering the hand the median nerve is covered anteriorly by fascia of forearm and partially by the palmaris longus muscle tendon. Laterally it goes with the flexor pollicis longus tendon which lies near the tendon of flexor carpi radialis [2].

The aim of this report is to present a rare anatomical variation in which the median nerve travels through the forearm piercing a belly of FDS muscle. Although the median nerve variations are described in the literature, the cases of the forearm variations are fairly uncommon.

Case report

During a routine anatomical dissection in Department of Anatomy in Jagiellonian University Medical College (Kraków, Poland), an unusual variation on the course of the median nerve was found in a male's right upper limb (Fig. 1). The nerve typically

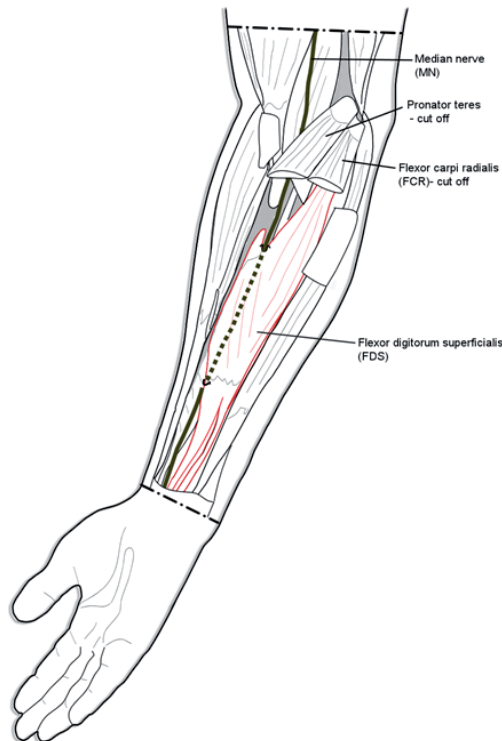


Fig. 1. Discovered course of the median nerve — scheme.

passed between two heads of pronator teres and then entered the space between the flexor digitorum superficialis and profundus with the ulnar artery in accordance with its typical path. Its following course was, however, unusual. Instead of a classic path, in which it lies under the dorsal surface of the flexor digitorum superficialis, the median nerve entered this muscle and passed through its radial head (Fig. 2). It pierced muscle tissue over a distance of 11.2 cm. It left the muscle on the radial side, heading towards the radial artery.

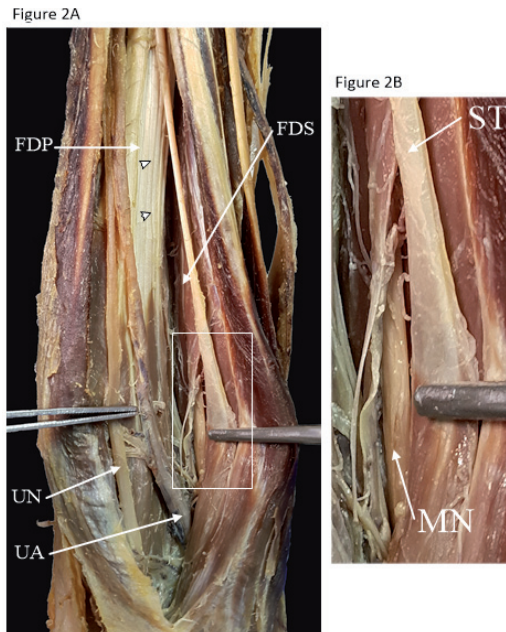


Fig. 2. Unusual course of the median nerve through the forearm. A — Medial view on the right forearm. (FDP) flexor digitorum profundus, (UA) Ulnar artery, (UN) Ulnar nerve, (FDS) flexor digitorum superficialis. Arrowheads indicate the normal pathway of the median nerve (MN). B — Magnified area marked with white rectangle depicted in A. Early division of separate tendon (ST) from the FDS is shown. (MN) Median nerve.

Other unusual anatomical features were also noticed in the examined forearm: an absence of palmaris longus muscle as well as an early division of one of the tendons of the flexor digitorum superficialis, which in the carpal tunnel joined a bundle of tendons of the flexor digitorum profundus.

Discussion

As to the authors knowledge, a case of the median nerve penetrating muscle tissue of the flexor digitorum superficialis has been described just once previously [3, 4].

The muscles of the upper limb including the flexor digitorum superficialis develop from somites and are identifiable by 7th week of embryonic development. The nerves enter the limb by the 5th week of embryonic development. The median nerve arises from the cubital fossa between the two heads of the pronator teres muscle. Its branch, going to the flexor digitorum superficialis muscle goes off before passing under the tendinous arch of the flexor digitorum superficialis [5]. In this case, the above mentioned branch was not separated from the median trunk, but all median nerve fibres have entered muscle tissue of the flexor digitorum superficialis muscle.

Interestingly, there has been an inverse situation reported by Skie and Ciocanel [6], that means the flexor digitorum superficialis pierced the median nerve. In that case the anatomical anomaly was clinically manifested by the symptoms of median nerve compression. In our case, since the medical records were not available, we can only assume that activities requiring numerous repetitive or single prolonged and forced contractions of the flexor digitorum superficialis might have led to a temporal occurrence of the symptoms of median nerve compression. Paresthesia and general disturbances of feeling on palmar side of the hand within the range of neuration of the median nerve, as well as disorders of muscles supplied by its motoric part might have occurred.

Due to its favorable anatomy [7], FDS is commonly used in tendon transfer surgeries. The middle finger portion of the muscle is independent, therefore it can be used in non-synergistic tendon transfers, as opposed to other finger tendons, which can be used for synergistic transfers. Since FDS tendon transfers require a division of tendons, the risk of damaging the median nerve which pierces muscle tissue might be increased. In non-synergistic transfers of the middle fingers tendon of FDS Boyes [8] recommended suturing tendons under maximum tension to provide better finger extension, however it entails more tension also in the rest of FDS. The postoperative complications seem to be even more convincing, as described by Chuinard *et al.* [9] and Richer and Peimer [10], such a situation might cause compression of the median nerve because of increased intramuscular pressure during contraction of FDS muscle. In our case, the occurrence of such condition would be probably significantly increased.

The agenesis of the palmaris longus muscle is the most common variation of that muscle [11] with a prevalence of 10.3% (95% CI: 6.4–15.0) measured in cadaveric studies and 15.6% (95% CI: 11.5–20.3) measured in functional studies [12]. The palmaris longus muscle is also used as a landmark for the median nerve localization during surgery [13]. Anomaly described in this case consisted of an absence of the palmaris longus muscle combined with such an unusual course of the median nerve that may cause some confusion during surgery.

Cumulative variations of the palmaris longus and the flexor digitorum superficialis have been previously reported [11], however, a pattern of the flexor digitorum

superficialis tendon joining the flexor digitorum profundus tendons in the carpal tunnel described in this report contributes to exceptionality of the case.

Conflict of interest

No declared.

References

1. Savastano L., Yang L.J.: Anatomy of the Median Nerve and Its Branches. Elsevier Ltd., 2014.
2. Mizia E., Tomaszewski K., Depukat P., et al.: Median nerve (anatomical variations) and carpal tunnel syndrome — revisited. *Folia Med Cracov.* 2013; 53: 37–46.
3. Thompson I.M.: Anomaly of median nerve and flexor digitorum sublimis muscle. *J Anat Physiol.* 1923; 23: 375–379.
4. Tubbs R.S., Shoja M.M., Loukas M.: Human anatomic variations. Wiley Blackwell, 2016; 1085.
5. Elliot D., Khandwala A.R., Kulkarni M.: Anomalies of the flexor digitorum superficialis muscle. *J Hand Surg J Br Soc Surg Hand.* 1999; 24: 570–574. doi: 10.1054/jhsb.1999.0237.
6. Skie M., Ciocanel D., Hedayat I., et al.: Anomaly of Flexor Digitorum Superficialis Penetrating Through the Median Nerve: Case Report. *J Hand Surg Am.* 2010; 35: 27–29. doi: 10.1016/j.jhsa.2009.09.010.
7. Agee J., McCarroll H.R., Hollister A.: The anatomy of the flexor digitorum superficialis relevant to tendon transfers. *J Hand Surg Br.* 1991; 16: 68–69.
8. Boyes J.: Tendon Transfers for Radial Palsy. *Bull Hosp Joint Dis.* 1960; 21: 97–105.
9. Chuinard R.G., Boyes J.H., Stark H.H., Ashworth C.R.: Tendon transfers for radial nerve palsy: use of superficialis tendons for digital extension. *J Hand Surg Am.* 1978; 3: 560–570.
10. Richer R.J., Peimer C.A.: Flexor superficialis abductor transfer with carpal tunnel release for thenar palsy. *J Hand Surg Am.* 2005; 30: 506–512. doi: 10.1016/j.jhsa.2004.12.010.
11. Yammine K.: Clinical prevalence of palmaris longus agenesis: A systematic review and meta-analysis. *Clin Anat.* 2013; 26: 709–718. doi: 10.1002/ca.22289.
12. Pękala P.A., Henry B.M., Pękala J.R., Skinningsrud B., Walocha J.A., Bonczar M., Tomaszewski K.A.: Congenital absence of the palmaris longus muscle: A meta-analysis comparing cadaveric and functional studies. *J Plast Reconstr Aesthet Surg.* 2017 Dec; 70 (12): 1715–1724. doi: 10.1016/j.bjps.2017.08.002.
13. Bernardes A., Melo C., Pinheiro S.: A combined variation of Palmaris longus and Flexor digitorum superficialis: Case report and review of literature. *Morphologie.* 2016; 100: 245–249. doi: 10.1016/j.morpho.2016.03.002.