

# Early results of aortic arch reconstruction and bilateral pulmonary artery banding: modification of the Norwood operation for treatment of hypoplastic left heart syndrome

Jacek W. Pająk<sup>1</sup>, Michał Buczyński<sup>1</sup>, Piotr Stanek<sup>2</sup>, Grzegorz Zalewski<sup>2</sup>, Marek Wites<sup>2</sup>, Lesław Szydłowski<sup>3</sup>, Lidia Tomkiewicz-Pająk<sup>4</sup>

<sup>1</sup>Paediatric Heart Surgery Department and General Paediatric Surgery Department, Medical University of Warsaw, Warsaw, Poland

<sup>2</sup>Paediatric Heart Surgery Department, The Independent Public Clinical Hospital no. 6 of the School of Medicine in Katowice, Katowice, Poland

<sup>3</sup>Chair and Department of Children's Cardiology, School of Medicine, Katowice, Poland

<sup>4</sup>Institute of Cardiology, Jagiellonian University Medical College and John Paul II Hospital, Krakow, Poland

## Abstract

**Background:** In the period from 2003 to the end of 2015, 96 Norwood I procedures were performed in the Paediatric Heart Surgery Department in Katowice, Poland, in children with hypoplastic left heart syndrome (HLHS).

**Aim:** This paper presents a retrospective analysis of early surgical results.

**Methods:** The patients consisted of two groups: group I included 59 children operated on in the years 2003–2012, in whom the stage I Norwood procedure with the Sano modification was performed with the aortic arch reconstructed by use of a homogenous pulmonary artery patch or a bovine pericardial patch. Group II included 37 children after our modification of the Norwood I procedure, in which the aortic arch was reconstructed with an extracellular matrix patch and bilateral pulmonary artery banding was done.

**Results:** Aortic cross-clamping time was significantly shorter in group II (mean 52; range 38–62 min) than in group I (mean 57; range 39–72 min;  $p < 0.009$ ). Eighteen (30.5%) children in group I and six (16.2%) in group II died. Although this difference did not reach statistical significance ( $p = 0.12$ ), it suggested that improved outcomes with the modified procedure are possible. The cause of death in group I was significantly more frequently due to massive postoperative bleeding ( $n = 6$ ; 33.3%) than in group II ( $n = 1$ ; 16.7%;  $p = 0.046$ ).

**Conclusions:** The introduction of this new surgical technique reduced postoperative bleeding rates, shortened the operation time, and might improve the mortality rate in the first-stage surgical treatment of children with HLHS.

**Key words:** hypoplastic left heart syndrome, Norwood procedures, CorMatrix

Kardiologia Polska 2018; 76, 4: 770–775

## INTRODUCTION

In recent years, in the first stage of surgical treatment of children with hypoplastic left heart syndrome (HLHS), three management models have been employed: the classic Norwood operation with a systemic-pulmonary shunt; the Norwood operation as modified by Sano, with a conduit between the free right ventricular wall and pulmonary arteries; and

the hybrid operation involving stenting of the patent ductus arteriosus (PDA) with bilateral pulmonary artery banding [1]. In the years 2003–2012, all children with HLHS operated on in our centre received the Norwood operation with right ventricle-pulmonary artery shunt modification. The aortic arch was reconstructed with a homogenous pulmonary artery patch or a bovine pericardial patch [2]. The great extensiveness

### Address for correspondence:

Jacek W. Pająk, MD, PhD, Paediatric Heart Surgery and General Paediatric Surgery Department, Medical University of Warsaw, ul. Żwirki i Wigury 63A, 02-091 Warszawa, Poland, e-mail: jacekpajak@poczta.onet.pl

Received: 25.06.2017

Accepted: 18.12.2017

Available as AoP: 12.01.2018

Kardiologia Polska Copyright © Polish Cardiac Society 2018

of the Norwood I operation, the well-known disadvantages of both homografts and bovine pericardium, and postoperative bleeding, which was relatively frequent, prompted us to search for a more straightforward operative technique and a better haemostatic material to reconstruct the aortic arch [3]. Previous studies showed that CorMatrix was a satisfactory material for congenital cardiac or great vessel surgery, pericardial reconstruction [4–8], valve reconstruction in both adults and children [4, 9], endocarditis [10], and to repair damaged myocardium [4]. However, data regarding use of CorMatrix in the first stage of surgical treatment of children with HLHS are scarce [4, 7].

Since the beginning of 2013, all children with HLHS operated on in our centre have had aortic arch reconstruction accomplished by use of a CorMatrix patch. At the same time, we have been striving to develop a surgical technique that would decrease the extent of surgery, shorten the operation time, and reduce the mortality rates. Accordingly, our attention has been drawn to hybrid procedures, which consist of PDA stenting and bilateral pulmonary artery banding. These procedures are commonly performed in children who are at high surgical risk, but the operation is still associated with a relatively low mortality [11, 12]. The haemodynamic situation after the hybrid procedure is reasonably well tolerated in spite of the severe condition of the children. In this event, the extent of the second stage of the surgical treatment is much broader. With the intent of improving upon our results with stage I operations for HLHS, we have attempted to achieve similar haemodynamic conditions by reconstructing the aortic arch rather than by stenting the PDA and banding the pulmonary arteries. With this strategy, the stage II operation would be shorter than the operation after the hybrid procedure because the aortic arch reconstruction would be omitted.

The purpose of the study was to analyse the early results of stage I surgical treatment of patients with HLHS. We also compared two methods of surgery: stage I Norwood procedure with the Sano modification and aortic arch patch reconstruction with bilateral pulmonary artery banding, which is our modification of the Norwood operation.

## METHODS

### *Study participants*

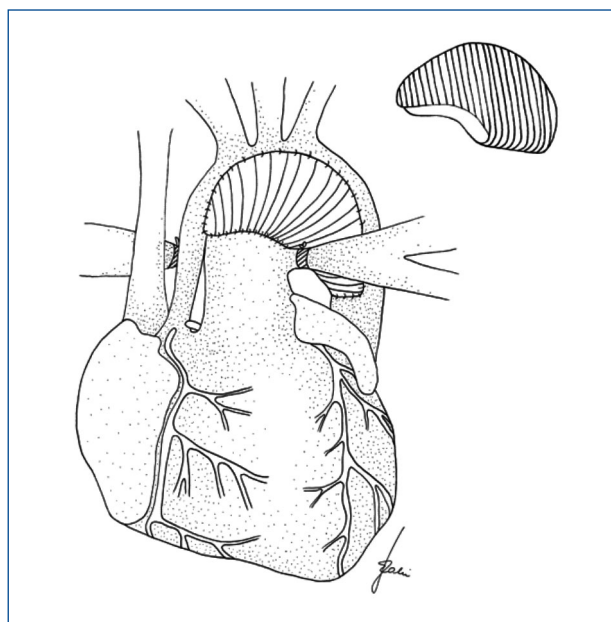
All the study patients operated on for HLHS were recruited consecutively at the Paediatric Heart Surgery Department in Katowice, Poland. They were included in the study from July 2003 to December 2015. Children with low birth body weight (below 2500 g) and preterm neonates were excluded from the study. Demographic, clinical, and anatomical features, as well as early postoperative complications, were studied by a retrospective analysis of all the medical records. The mean body mass of the children on the day of operation was  $3.32 \pm 0.7$  kg. Mean age at operation was 17 days (from 0 to 87 days). The study group

included 34 (29.7%) girls and 62 (70.2%) boys. Based on the type of surgery, the patients were allocated into two groups. Group I included 59 children operated on in the period from 2003 to the end of 2012. All children in this group received the stage I Norwood procedure with the Sano modification, the aortic arch being reconstructed by use of a homogenous pulmonary artery patch (38 patients, 64.4%) or a bovine pericardial patch (21 patients, 35.6%). Group II included 37 children operated on between early 2013 and the end of 2015. In this group, the stage I Norwood procedure was modified to include aortic arch reconstruction with a CorMatrix patch and bilateral pulmonary artery banding, which reduced pulmonary blood inflow. For all patients, diagnosis and qualification for operation was done on the basis of echocardiographic examination. The follow-up time was 30 days. Postoperative mortality and the most common adverse events, including preoperative pneumonia/sepsis, preoperative necrotising enterocolitis, aortic cross-clamp time, postoperative opened chest, postoperative bleeding requiring chest revision, postoperative intubation days, were analysed with respect to their relation to the mortality rates.

### *Surgical technique*

In all the cases, the surgical approach was via median sternotomy. All the procedures were performed with patients undergoing cardiopulmonary bypass, in deep hypothermic circulatory arrest. In each case, a single-stage venous cannula was introduced to the right cardiac auricle. The aortic cannula was introduced to the ascending aorta at the level of the brachiocephalic trunk branching if the ascending aorta size was approximately 4 mm or more, and followed by ligation of the PDA. In cases with significant hypoplasia of the ascending aorta, the aortic cannula was inserted into the main pulmonary artery, and tourniquets were applied to the pulmonary artery branches for the duration of cooling, with the PDA remaining patent until circulatory arrest. After the patient's body temperature was lowered to 17–18°C, tourniquets were tightened around the cervical arteries, the cardiopulmonary bypass was stopped, aortic and venous cannulas were removed, and crystalline cardioplegia was administered. The bottom of the fossa ovalis was resected via a cannulation hole in the right auricle, thus widening the inter-atrial communication. In cases where the fossa ovalis was not well visualised through the cannulation opening in the right atrium, the free right atrial wall was opened and the approach was used to increase the inter-atrial communication.

In group I children, the proximal part of the PDA was banded, and the distal segment was excised. The ascending aorta was anastomosed side-to-side, with the main pulmonary artery directly above the valve level; the ascending aorta and aortic arch were reconstructed by use of a homogenous pulmonary artery patch or a bovine pericardial patch.



**Figure 1.** CorMatrix patch for stage I hypoplastic left heart syndrome aortic arch reconstruction

In group II children, the PDA was completely excised. Directly above the pulmonary artery branching, the main pulmonary artery was anastomosed side-to-side with the initial segment of the aortic arch, and the remaining portion of the arch was reconstructed with a CorMatrix patch (Fig. 1).

When anastomosing all the homogenous tissues and patch materials with the homogenous tissues, we used Prolen 6-0 sutures. In all children in both groups, the patch employed in the aortic reconstruction, with its distal end extended to the initial segment of the descending aorta, which had a “Y-shaped” section, was situated as low as possible. In both groups, in each case when the suture line in the aortic-arch reconstruction passed by the cannula opening in the ascending aorta, the aortic cannula was reintroduced, a transverse clamp was placed on the ascending aorta, and cardiopulmonary bypass was reinitiated. In children, in whom the aortic cannula had been previously inserted into the main

pulmonary artery, cardiopulmonary bypass was reinitiated only after completion of the aortic reconstruction. In group I, during cardiopulmonary bypass and while warming the child, a 5-mm diameter polytetrafluorethylene graft was sutured between the free right ventricular wall and the main pulmonary artery stump; the main pulmonary artery-directed side ended with an oval homogenous pulmonary artery or bovine pericardial patch, sutured in immediately before the surgical procedure. In group II, during cardiopulmonary bypass and while warming the child, the bilateral pulmonary arteries were banded. The bands used were 1.5-mm-long fragments of a polytetrafluorethylene graft 3.5 mm in diameter, which had been cut open. The bands placed on the pulmonary arteries were sutured with Prolen 6-0 approximately 1 mm from the cut margin. The bands were bilaterally fixed to the main pulmonary artery by a single Prolen 6-0 suture.

Postoperatively, all patients were hospitalised in the cardiosurgical postoperative intensive care unit. Group I patients received antiplatelet treatment in the postoperative period, but group II patients did not.

### Statistical methods

Assessment of differences between the groups and the effect of qualitative properties on mortality rates were based on the  $\chi^2$  test or Fisher's exact test; quantitative properties were analysed with the Student's t-test or Mann-Whitney tests. All  $p < 0.05$  were considered statistically significant. All calculations were made with the STATISTICA software package (StatSoft® Poland).

### RESULTS

Of 104 patients who were assessed for eligibility, eight subjects were excluded due to low birth body weight ( $n = 6$ ) and preterm neonates ( $n = 2$ ). The study population consisted of 96 participants.

The 30-day hospital overall mortality rate and the rates of death due to bleeding, pneumonia/sepsis, and low cardiac output are presented in Table 1.

No differences were observed between the groups in terms of age, mean body mass, anatomical HLHS type, ascending aorta size, function of the right ventricular and atrio-ventricular valve, and pulmonary artery anatomy.

**Table 1.** Postoperative complications and mortality

Variable	Group I	Group II	p
Hospital 30 days mortality	18 (30.5%)	6 (16.2%)	0.115
Deaths:			
Bleeding	6 (33.3%)	1 (16.7%)	0.621
Pneumonia/sepsis	1 (5.6%)	1 (16.7%)	0.446
Low cardiac output	11 (61.1%)	4 (66.7%)	0.621

Data are presented as number (percentage).

**Table 2.** Analysed perioperative factors

Variable	Group I	Group II	p
Preoperative pneumonia/sepsis	15 (25.9%)	5 (13.5%)	0.150
Preoperative necrotising enterocolitis	4 (6.9%)	1 (2.8%)	0.645
Aortic cross-clamp time [min]	57/39–72	52/38–62	0.009
Postoperative opened chest	17 (28.8%)	15 (41.7%)	0.427
Postoperative bleeding requiring chest revision	17 (28.8%)	7 (19.4%)	0.153
Postoperative intubation [days]	7/2–20	8/2–28	0.585

Data are presented as mean/range or number (percentage).

**Table 3.** Factors affecting mortality

Variable	Group I		p	Group II		p
	Alive	Death		Alive	Death	
Preoperative pneumonia/sepsis	9 (22.0%)	6 (35.3%)	0.291	3 (9.7%)	2 (33.3%)	0.177
Preoperative necrotising enterocolitis	0 (0.0%)	1 (5.6%)	0.999	1 (3.2%)	0 (0.0%)	0.327
Postoperative bleeding requiring chest revision	11 (26.8%)	6 (60.0%)	0.046	6 (19.4%)	1 (20.0%)	0.999
Postoperative opened chest	14 (34.1%)	3 (30.0%)	0.999	10 (32.3%)	6 (100.0%)	0.008
Postoperative pneumonia/sepsis	9 (22.0%)	1 (10.0%)	0.664	5 (16.1%)	1 (20.0%)	0.999
Aortic cross-clamp time [min]	58 ± 9	56 ± 9	0.398	52 ± 8	55 ± 6	0.439

Data are presented as mean ± standard deviation or number (percentage).

Although the overall 30-day mortality rate was lower in group II than in group I patients, the difference did not reach statistical significance, and deaths from the various causes also were not significantly different.

Various preoperative, intraoperative, and postoperative features of the procedures are shown in Table 2.

The only significant difference between the two groups was a modest difference in aortic cross-clamping time (mean 57, range 39–72 min, in group I; mean 52, range 38–62 min, in group II;  $p < 0.009$ ). Differences between the two groups in preoperative pneumonia/sepsis, preoperative necrotising enterocolitis, and postoperative bleeding requiring chest revision appeared substantial, but they did not reach statistical significance, perhaps in part because of the small number of cases.

The most common adverse events were analysed with respect to their relation to the mortality rates (Table 3).

A significant effect was exerted on the mortality rate of children in group I by postoperative severe bleeding that required chest revision ( $p = 0.046$ ); in group II, no such association was observed ( $p = 0.999$ ). In all the non-stable patients in group II, the chest was left open; all five (100%) children from this group who died had their chests opened ( $p = 0.008$ ), whereas in group I, the number of such patients was only three (30.0%). Preoperative pneumonia or sepsis, necrotising enterocolitis, and postoperative sepsis had no significant impact on the mortality rates. The mean time of

the aortic cross-clamping, although significantly shorter in group II, had no statistically significant effect on the mortality rates in the two groups.

After our centre obtained a circulatory assist device with extracorporeal membrane oxygenation in 2013, assisted circulation was employed in four (10.8%) group II children. This change resulted in a critical decrease in cardiac output after the Norwood procedure, and in two cases assisted circulation was discontinued with a positive effect.

## DISCUSSION

Our study showed a relatively high early postoperative mortality rate (30.5% in group I) in children with HLHS after the first stage of surgical treatment in the initial years of our centre's activity. It might be associated with a low number of operated patients and low team experience in the neonatology, cardiology, and heart surgery departments. In some leading centres at that time, the mortality rate was about 10% lower than in our institution [13], so we focused on improving our results. During the three years after the technique modification, we have achieved a considerable decrease in the postoperative mortality rate (from 30.5% to 16.2%) in children with HLHS after the first stage of surgical treatment. This result has been obtained even though the operation was often delayed due to infectious complications that required treatment in neonatology centres. A delay of operation because of severe infection or sepsis, mostly with ventilator support,

is a well-known preoperative risk factor of the Norwood operation [3, 14]. However, in our cohort we did not find any statistically significant association between preoperative infectious complications and the postoperative mortality rates. We achieved shortening of the mean aortic cross clamp time and a decrease in the percentage of significant postoperative bleeding in group II when compared to group I. This finding might reduce the mortality rate, but we did not find statistically significant associations of this parameter due to the small group of patients. It should be noted that, in the context of improvement of our modification of the operative technique in the analysed cohort of patients in group II in the year 2015, the mortality rate was 0%.

We attribute the lower mortality rate in group II compared with group I to the change in the surgical technique and use of a smaller patch for reconstruction of the aortic arch. The CorMatrix patch has more potent haemostatic properties [4] than the pulmonary homografts or bovine pericardial patches we previously used. When we used a smaller CorMatrix patch than we had previously used, postoperative bleeding requiring opening of the chest decreased from 28.8% in group I to 19.4% in group II. Pronounced postoperative bleeding requiring opening of the chest in group I significantly contributed to the high mortality rate in this group. Multicentre studies [3] have demonstrated a markedly lower percentage (approximately 8%) of postoperative interventions due to bleeding than we had. This difference may be due to delayed postoperative chest closure commonly (56.0%) employed in many centres, whereas we used this technique, intended to reduce the risk of cardiac tamponade and disturbed haemodynamic stability, in only 28.8% of the patients in group I but in as many as 41.7% of those in group II. For group II patients, we obtained a circulatory assist device with extracorporeal membrane oxygenation in 2013. This helpful tool was employed for four (10.8%) patients post stage I modified Norwood operation. Two of them (50.0%) survived. The result looks impressive in comparison with other centres, but it could be due to the low number of patients treated until now in our institution with the circulatory assist device.

Limitation of pulmonary flow by bilateral pulmonary artery banding permits pulsative blood flow to be maintained in pulmonary arteries. This technique protects also the single ventricle from additional volume work connected with a partial blood return during the diastole phase via the right ventricle — pulmonary artery conduit, which can happen after Norwood operation with Sano modification.

Leaving banded pulmonary artery branches in their original position permits a higher anastomosis of the ascending aorta and main pulmonary artery. The patch used is straight and shorter. The shortened suture line reduces the risk of bleeding and decreases the operation time. Although the shorter aortic cross-clamping time statistically was not associ-

ated with a lower mortality rate in our material, it may still have beneficial effects due to shortening the time of ischaemia of the heart and, consequently, in postoperative patient's condition. A high anastomosis of the pulmonary artery trunk with the native aorta and the aortic arch-widening patch removes the region of altered lines of force tension from the new aortic valve, a technique which minimises the risk of valvular regurgitation in the "neo-aorta" [15].

Anastomosing the main pulmonary artery with the aortic arch-widening patch above the pulmonary artery branching does not require a long, bow-curved patch, but rather a moderately long, straight patch fragment; this kind of patch complements the junction of the high main pulmonary artery stump with the aortic arch and incision of the descending aorta. The Y-shaped incision may be made deeper in the descending aorta in order to reduce the likelihood of aortic stenosis at the anastomotic site. The use of a short but wide patch decreases patch angulation, which might otherwise result in narrowing in the aortic arch, with a loss of kinetic energy of blood flow [16]. The shape of the patch we used leads to a wide, non-stenotic, and at times oversized, aortic arch. The slightly oversized aortic arch is well tolerated haemodynamically and is not noticeable as the child grows. On the other hand, the patch should not be too short, so that compression of the left bronchus by the new aortic arch is avoided. A patch that is too short and (more frequently) a direct anastomosis of the main pulmonary artery with the descending aorta may both result in the difficult-to-treat complication of left bronchial compression and stenosis [17, 18].

Early results of our modification of the Norwood I operation looks very promising; however, the results require validation during long-term follow-up. The first data regarding the long-term results after our "modification" can be found in our recently published article [19].

There are several limitations to this study. First, the number of patients in the study was small; however, we presented the experience of single centre. Also, the lack of randomisation and the retrospective nature of the study introduce threats that may affect the validity of the analysis performed.

In conclusion, the introduction of a new surgical technique reduced postoperative bleeding rates, shortened the operation time, and might improve the mortality rate in the first stage of surgical treatment of children with HLHS.

#### ***Acknowledgements, ethical approval and consent to participate***

We thank Dr. H. Stanuch for performing statistical analysis.

Because this was a retrospective study based on existing patient data, individual informed consent was not required. The study was, nevertheless, registered and approved by the local Ethics Committee (KNW/0022/KB/100/16).

***Conflict of interest:*** none declared

## References

- Barron DJ. The Norwood procedure: in favor of the RV-PA conduit. *Semin Thorac Cardiovasc Surg Pediatr Card Surg Annu.* 2013; 16(1): 52–58, doi: [10.1053/j.pcsu.2013.01.002](https://doi.org/10.1053/j.pcsu.2013.01.002), indexed in Pubmed: [23561818](https://pubmed.ncbi.nlm.nih.gov/23561818/).
- Morell VO, Wearden PA. Experience with bovine pericardium for the reconstruction of the aortic arch in patients undergoing a Norwood procedure. *Ann Thorac Surg.* 2007; 84(4): 1312–1315, doi: [10.1016/j.athoracsur.2007.05.036](https://doi.org/10.1016/j.athoracsur.2007.05.036), indexed in Pubmed: [17888988](https://pubmed.ncbi.nlm.nih.gov/17888988/).
- Hornik CP, He X, Jacobs JP, et al. Complications after the Norwood operation: an analysis of The Society of Thoracic Surgeons Congenital Heart Surgery Database. *Ann Thorac Surg.* 2011; 92(5): 1734–1740, doi: [10.1016/j.athoracsur.2011.05.100](https://doi.org/10.1016/j.athoracsur.2011.05.100), indexed in Pubmed: [21937021](https://pubmed.ncbi.nlm.nih.gov/21937021/).
- Mosala Nezhad Z, Poncelet A, de Kerchove L, et al. Small intestinal submucosa extracellular matrix (CorMatrix®) in cardiovascular surgery: a systematic review. *Interact Cardiovasc Thorac Surg.* 2016; 22(6): 839–850, doi: [10.1093/icvts/ivw020](https://doi.org/10.1093/icvts/ivw020), indexed in Pubmed: [26912574](https://pubmed.ncbi.nlm.nih.gov/26912574/).
- Quarti A, Nardone S, Colaneri M, et al. Preliminary experience in the use of an extracellular matrix to repair congenital heart diseases. *Interact Cardiovasc Thorac Surg.* 2011; 13(6): 569–572, doi: [10.1510/icvts.2011.280016](https://doi.org/10.1510/icvts.2011.280016), indexed in Pubmed: [21979987](https://pubmed.ncbi.nlm.nih.gov/21979987/).
- Witt RG, Raff G, Van Gundy J, et al. Short-term experience of porcine small intestinal submucosa patches in paediatric cardiovascular surgery. *Eur J Cardiothorac Surg.* 2013; 44(1): 72–76, doi: [10.1093/ejcts/ezs638](https://doi.org/10.1093/ejcts/ezs638), indexed in Pubmed: [23321433](https://pubmed.ncbi.nlm.nih.gov/23321433/).
- Hibino N, McConnell P, Shinoka T, et al. Preliminary Experience in the Use of an Extracellular Matrix (CorMatrix) as a Tube Graft: Word of Caution. *Semin Thorac Cardiovasc Surg.* 2015; 27(3): 288–295, doi: [10.1053/j.semtcvs.2015.08.008](https://doi.org/10.1053/j.semtcvs.2015.08.008), indexed in Pubmed: [26708369](https://pubmed.ncbi.nlm.nih.gov/26708369/).
- Rosario-Quinones F, Magid MS, Yau J, et al. Tissue reaction to porcine intestinal Submucosa (CorMatrix) implants in pediatric cardiac patients: a single-center experience. *Ann Thorac Surg.* 2015; 99(4): 1373–1377, doi: [10.1016/j.athoracsur.2014.11.064](https://doi.org/10.1016/j.athoracsur.2014.11.064), indexed in Pubmed: [25707584](https://pubmed.ncbi.nlm.nih.gov/25707584/).
- Gerdisch MW, Shea RJ, Barron MD. Clinical experience with CorMatrix extracellular matrix in the surgical treatment of mitral valve disease. *J Thorac Cardiovasc Surg.* 2014; 148(4): 1370–1378, doi: [10.1016/j.jtcvs.2013.10.055](https://doi.org/10.1016/j.jtcvs.2013.10.055), indexed in Pubmed: [24332188](https://pubmed.ncbi.nlm.nih.gov/24332188/).
- Gerdisch MW, Boyd WD, Harlan JL, et al. Early experience treating tricuspid valve endocarditis with a novel extracellular matrix cylinder reconstruction. *J Thorac Cardiovasc Surg.* 2014; 148(6): 3042–3048, doi: [10.1016/j.jtcvs.2014.06.092](https://doi.org/10.1016/j.jtcvs.2014.06.092), indexed in Pubmed: [25175957](https://pubmed.ncbi.nlm.nih.gov/25175957/).
- Akintuerk H, Michel-Behnke I, Valeske K, et al. Stenting of the arterial duct and banding of the pulmonary arteries: basis for combined Norwood stage I and II repair in hypoplastic left heart. *Circulation.* 2002; 105(9): 1099–1103, doi: [10.1161/hc0902.104709](https://doi.org/10.1161/hc0902.104709), indexed in Pubmed: [11877362](https://pubmed.ncbi.nlm.nih.gov/11877362/).
- Miyamoto T, Yoshii T, Inui A, et al. Staged repair for aortic arch reconstruction and intracardiac repair following bilateral pulmonary artery banding in 3 critical patients. *Interact Cardiovasc Thorac Surg.* 2013; 16(6): 892–894, doi: [10.1093/icvts/ivt073](https://doi.org/10.1093/icvts/ivt073), indexed in Pubmed: [23462462](https://pubmed.ncbi.nlm.nih.gov/23462462/).
- Gaynor JW, Mahle WT, Cohen MI, et al. Risk factors for mortality after the Norwood procedure. *Eur J Cardiothorac Surg.* 2002; 22(1): 82–89, doi: [10.1016/s1010-7940\(02\)00198-7](https://doi.org/10.1016/s1010-7940(02)00198-7), indexed in Pubmed: [12103378](https://pubmed.ncbi.nlm.nih.gov/12103378/).
- Atallah J, Dinu IA, Joffe AR, et al. tWestern Canadian Complex Pediatric Therapies Follow-Up Group. Two-year survival and mental and psychomotor outcomes after the Norwood procedure: an analysis of the modified Blalock-Taussig shunt and right ventricle-to-pulmonary artery shunt surgical eras. *Circulation.* 2008; 118(14): 1410–1418, doi: [10.1161/CIRCULATIONAHA.107.741579](https://doi.org/10.1161/CIRCULATIONAHA.107.741579), indexed in Pubmed: [18794395](https://pubmed.ncbi.nlm.nih.gov/18794395/).
- Pusca SV, Kanter KR, Kirshbom PM, et al. Freedom from neo-aortic insufficiency: a comparison of classic Norwood and Norwood-Sano procedures. *Congenit Heart Dis.* 2006; 1(6): 289–293, doi: [10.1111/j.1747-0803.2006.00049.x](https://doi.org/10.1111/j.1747-0803.2006.00049.x), indexed in Pubmed: [18377496](https://pubmed.ncbi.nlm.nih.gov/18377496/).
- Lamberti JJ. Aortic arch obstruction after the Norwood procedure for hypoplastic left-heart syndrome is it inevitable? Is it preventable? *J Am Coll Cardiol.* 2011; 58(8): 877–879, doi: [10.1016/j.jacc.2011.03.050](https://doi.org/10.1016/j.jacc.2011.03.050), indexed in Pubmed: [21835325](https://pubmed.ncbi.nlm.nih.gov/21835325/).
- Hasegawa T, Oshima Y, Maruo A, et al. Aortic arch geometry after the Norwood procedure: The value of arch angle augmentation. *J Thorac Cardiovasc Surg.* 2015; 150(2): 358–366, doi: [10.1016/j.jtcvs.2015.05.012](https://doi.org/10.1016/j.jtcvs.2015.05.012), indexed in Pubmed: [26092502](https://pubmed.ncbi.nlm.nih.gov/26092502/).
- Schreiber C, Eicken A, Vogt M, et al. Repair of interrupted aortic arch: results after more than 20 years. *Ann Thorac Surg.* 2000; 70(6): 1896–1899, doi: [10.1016/s0003-4975\(00\)01858-0](https://doi.org/10.1016/s0003-4975(00)01858-0), indexed in Pubmed: [11156091](https://pubmed.ncbi.nlm.nih.gov/11156091/).
- Pająk J, Buczyński M, Stanek P, et al. Preoperative single ventricle function determines early outcome after second-stage palliation of single ventricle heart. *Cardiovasc Ultrasound.* 2017; 15(1): 21, doi: [10.1186/s12947-017-0114-7](https://doi.org/10.1186/s12947-017-0114-7), indexed in Pubmed: [28893257](https://pubmed.ncbi.nlm.nih.gov/28893257/).

**Cite this article as:** Pająk JW, Buczyński M, Stanek P, et al. Early results of aortic arch reconstruction and bilateral pulmonary artery banding: modification of the Norwood operation for treatment of hypoplastic left heart syndrome. *Kardiologia Polska.* 2018; 76(4): 770–775, doi: [10.5603/KPa.2018.0025](https://doi.org/10.5603/KPa.2018.0025).