

## CLINICAL IMAGE

# Composed revascularization techniques for rescue endovascular management of acute occlusion of abdominal aorta and renal arteries

Paweł Latacz<sup>1</sup>, Marian Simka<sup>2</sup>, Marcin Krzanowski<sup>3</sup>, Joanna Dolipska<sup>3</sup>, Władysław Sułowicz<sup>3</sup>

<sup>1</sup> Department of Neurology, Jagiellonian University Medical College, Kraków, Poland

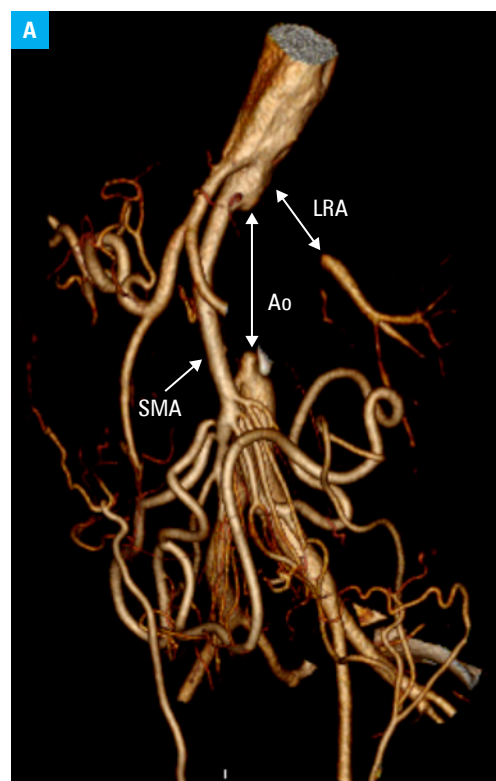
<sup>2</sup> Department of Anatomy, University of Opole, Opole, Poland

<sup>3</sup> Department of Nephrology, Jagiellonian University Medical College, Kraków, Poland

Revascularization of the renal arteries in case of their acute obstruction resulting in renal failure (RF) remains a therapeutic challenge. Renal ischemia is often asymptomatic, and it is also difficult to determine when the organ is irreversibly damaged. We present a successful rescue angioplasty of the abdominal aorta and left renal artery (LRA), using the chimney technique. We managed a 52-year-old woman presenting with acute RF requiring hemodialysis. Computed angiography revealed an occlusion of the abdominal aorta just below the origin of the superior mesenteric artery and occlusion of both renal arteries (FIGURE 1A). There were also radiologic features of cirrhosis of the right kidney, while the left kidney was normally sized. Despite abdominal aortic occlusion, there were no clinical signs of lower limb ischemia, since collateral circulation was good. An actual cause of the occlusion was difficult to determine. The patient was asymptomatic until symptoms of RF developed. Most likely, the occlusion resulted from aortic dissection followed by thrombosis. Echocardiographic examination demonstrated low ejection fraction (<30%), still with no signs of valvular dysfunction. Preprocedural course was complicated by heparin-induced thrombocytopenia, which was successfully managed with fondaparinux.

Considering the high risk of an open surgical revascularization, we decided to attempt endovascular angioplasty of the occluded abdominal aorta and the LRA, using the chimney technique. First, we cannulated the aorta up to the level of occlusion. Contrast injected at this level revealed that the distal part of the LRA, about 4 cm from the aorta, was patent and received blood supply from collateral circulation (FIGURE 1B and 1C). Using a hydrophilic guidewire (AqWire™, Covidien,

ev3 Endovascular, Inc., Plymouth, Minnesota, United States), we navigated across the occluded distal part of the aorta. Since the origin of the LRA was not visible, we dilated the aorta using angioplastic balloons in the area where such origin should be located, which resulted in visualization of the proximal portion of the LRA.



**FIGURE 1 A** – computed tomography angiography showing occlusion of the abdominal aorta (Ao) coexisting with occlusions of the left renal artery (LRA); SMA, superior mesenteric artery

**Correspondence to:**

Paweł Latacz, MD, PhD,  
Klinika Neurologii, Uniwersytet  
Jagielloński, Collegium Medicum,  
ul. Botaniczna 3, 31-503 Kraków,  
Poland, phone: +48 12 424 86 46,  
email: pawlat@me.com

Received: March 17, 2018.

Accepted: April 17, 2018.

Published online: April 17, 2018.

Conflict of interest: none declared.

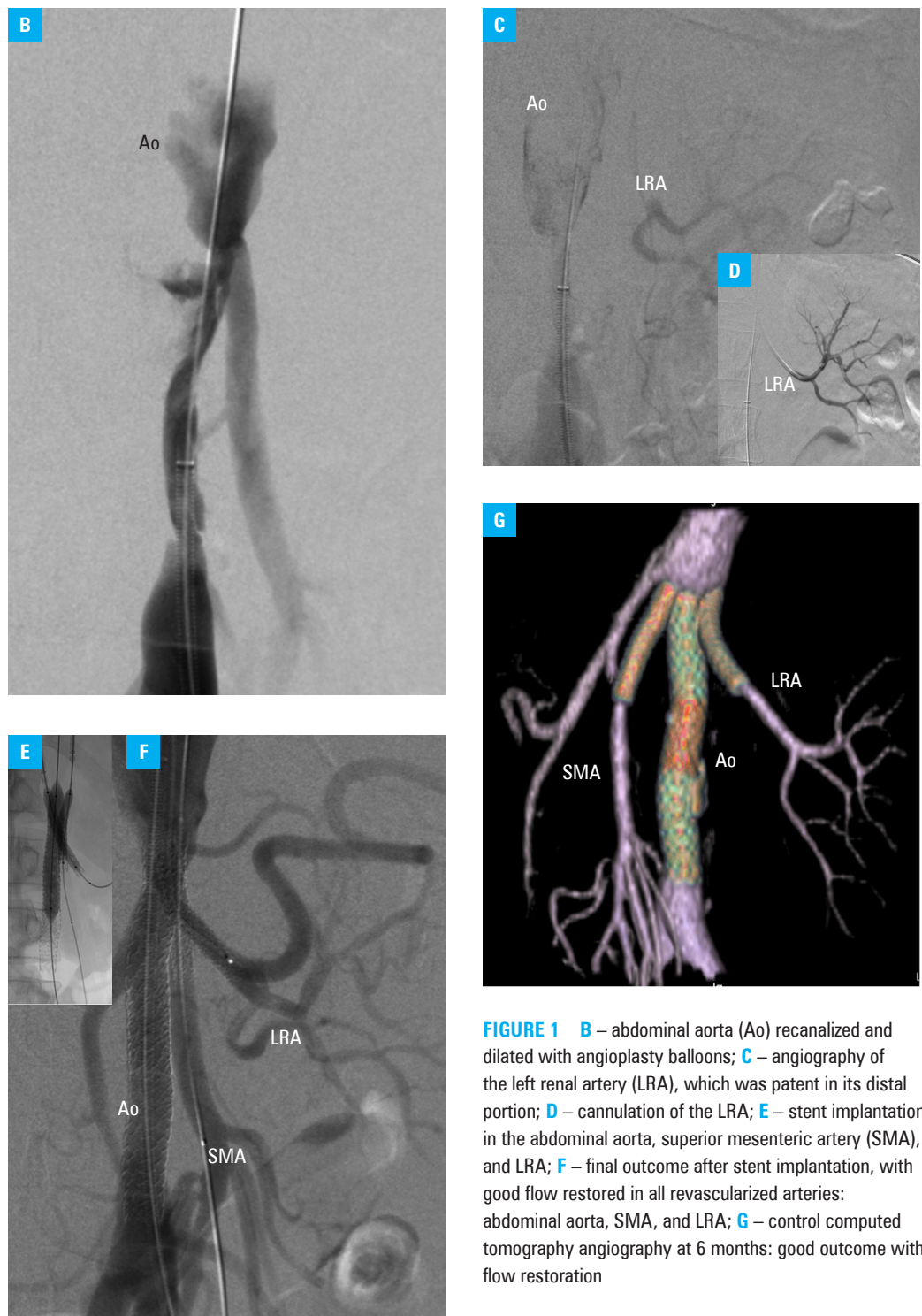
Pol Arch Intern Med. 2018;

128 (5): 319-321

doi:10.20452/pamw.4249

Copyright by Medycyna Praktyczna,

Kraków 2018



**FIGURE 1** B – abdominal aorta (Ao) recanalized and dilated with angioplasty balloons; C – angiography of the left renal artery (LRA), which was patent in its distal portion; D – cannulation of the LRA; E – stent implantation in the abdominal aorta, superior mesenteric artery (SMA), and LRA; F – final outcome after stent implantation, with good flow restored in all revascularized arteries: abdominal aorta, SMA, and LRA; G – control computed tomography angiography at 6 months: good outcome with flow restoration

Using a 0.014" guidewire, we navigated through the occluded segment of this artery (FIGURE 1D). Then, using the chimney technique and simultaneous expansion of stents, we implanted 2 BeGraft stents (Bentley InnoMed, Hechingen, Germany) in the superior mesenteric artery and in the LRA, and bigger BeGraft stents in the abdominal aorta (FIGURE 1E and 1F). The final angiographic outcome of the procedure was good, with restored flow to the left kidney parenchyma (FIGURE 1F). After the procedure, normal levels of renal biochemical parameters and diuresis were restored. The patient was discharged after 12 days of hospitalization, with a recommendation of dual antiplatelet

therapy (aspirin and clopidogrel), anticoagulation with fondaparinux for 3 months, and antihypertensive therapy. Control computed angiography at 6 months (FIGURE 1G) and ultrasound examination at 12 and 18 months revealed good flow in all arteries where stents were implanted.

In our opinion, endovascular revascularization of an acutely occluded renal artery is a promising alternative for open surgical repair.<sup>1-5</sup> It should be emphasized that it is difficult to determine the duration of irreversible renal ischemia. Therefore, endovascular revascularization of renal arteries resulting in RF should always be considered, especially in high-risk patients.<sup>3-5</sup>

**OPEN ACCESS** This is an Open Access article distributed under the terms of the Creative Commons Attribution-NonCommercial-ShareAlike 4.0 International License ([CC BY-NC-SA 4.0](https://creativecommons.org/licenses/by-nc-sa/4.0/)), allowing third parties to copy and redistribute the material in any medium or format and to remix, transform, and build upon the material, provided the original work is properly cited, distributed under the same license, and used for non-commercial purposes only. For commercial use, please contact the journal office at [pamw@mp.pl](mailto:pamw@mp.pl).

## REFERENCES

- 1 Silverberg D, Menes T, Rimon U, et al. Acute renal artery occlusion: presentation, treatment and outcome. *J Vasc Surg.* 2016; 64: 1026-1032.
- 2 Latacz P, Rudnik A, Gutowska A, et al. Percutaneous angioplasty of the left renal artery in a patient with acute infarction of the left kidney with persistent occlusion of the right renal artery treated with angiotensin converting enzyme inhibitor. *Kardio Pol.* 2011; 69: 702-705.
- 3 Kanamori H, Toma M, Fukatsu A., Improvement of renal function after opening occluded atherosclerotic renal arteries. *J Invasive Cardiol.* 2009; 21: E171-174.
- 4 Hedayati N, Lin PH, Lumsden AB, et al. Prolonged renal artery occlusion after endovascular aneurysm repair: endovascular rescue and renal function salvage. *J Vasc Surg.* 2008; 47: 446-449.
- 5 Jongkind V, Kievit JK, Wiersema AM, Recovery of renal function after prolonged anuria in acute suprarenal aortic occlusion. *Ann Vasc Surg.* 2016; 30: 307.e11-307.e14.