

Short communications

Hybrid one-day coronary artery bypass grafting and carotid artery stenting – cardiac surgeons' perspective on the procedure's safety

Jacek Piątek^{1,2}, Anna Kędziora^{1,2}, Karolina Dzierwa^{1,3}, Janusz Konstanty-Kalandyć^{1,2}, Marcin Wrózek⁴, Krzysztof L. Bryniarski^{1,3}, Piotr Musiałek^{1,5}, Krzysztof Bartuś^{1,2}, Bogusław Kapelak^{1,2}, Piotr Pieniżek^{1,5}

¹Institute of Cardiology, Jagiellonian University Medical College, Krakow, Poland

²Department of Cardiovascular Surgery and Transplantology, John Paul II Hospital, Krakow, Poland

³Department of Interventional Cardiology, John Paul II Hospital, Krakow, Poland

⁴Cardiosurgical Students' Scientific Group, Jagiellonian University Medical College, Krakow, Poland

⁵Department of Cardiac and Vascular Diseases, John Paul II Hospital, Krakow, Poland

Adv Interv Cardiol 2018; 14, 1 (51): 99–102
DOI: <https://doi.org/10.5114/aic.2018.74362>

Introduction

Nowadays, patients scheduled for coronary artery bypass grafting (CABG) present with multiple comorbidities that may increase the incidence of complications and worsen the outcome. Concomitant and significant carotid stenosis is observed in around 8–14% of patients eligible for surgical myocardial revascularization [1]. In such cases, postoperative neurological complications and higher mortality are observed, especially in individuals with a history of prior stroke or transient ischemic attack (TIA) [2]. Currently, in patients qualified for CABG, prophylactic carotid revascularization should be considered in symptomatic cases and may be considered in asymptomatic ones after a multidisciplinary discussion [3]. Nevertheless, there are no strict guidelines regarding the timing and the modality of both procedures. Based on observational studies, combined 1-day hybrid intervention may reduce the interstage myocardial infarction (MI) rate observed in patients undergoing staged procedures [4, 5]. In spite of there being only a few available reports so far, this approach provides satisfactory early and long-term outcomes and could be considered as an especially attractive alternative for patients with advanced or unstable coronary artery disease, which results in high risk of cardiac complications during the carotid procedure [6, 7].

Aim

The aim of the study was to assess the surgical safety of one-day carotid artery stenting (CAS) combined with CABG.

Material and methods

In a retrospective cohort study we enrolled 57 consecutive patients (42 males, 15 females; mean age: 70.8 ± 6.9 years) with a median EuroSCORE II of 2.4% (1.7–3.0) who were scheduled for hybrid one-day CAS combined with CABG based on a multidisciplinary Heart Team decision, including neurological and vascular consultations [3]. All patients required urgent (definitive procedure within the same hospitalization) cardiac surgery and had concomitant carotid artery stenosis qualifying them for revascularization (Table I A).

Carotid artery stenting was performed under local anesthesia through percutaneous transfemoral access using different embolic protection devices and different stent types according to the tailored CAS algorithm [8–10]. After the procedure, the patient was immediately transferred to the cardiac operating room, where additional neurological assessment was performed. In case of any focal deficits, the protocol assumed postponing the surgery until further evaluation. In patients with especially high risk of cardiac complications, the procedure was performed in a hybrid operating room under general anesthesia, and started with a sternotomy. The sutures for emergent cannulation were placed and then the CAS procedure and subsequent CABG were performed. This approach, with a cardiopulmonary bypass (CPB) on stand-by, secured the possibility to go on-pump emergently in case of hemodynamic instability or sudden cardiac arrest. In these patients neurological assessment

Corresponding author:

Anna Kędziora MD, Department of Cardiovascular Surgery and Transplantology, John Paul II Hospital, 80 Prądnicka St, 31-202 Krakow, Poland, phone: +48 12 614 30 75, e-mail: kdzra.a@gmail.com

Received: 23.01.2018, accepted: 20.02.2018.

Table I. Baseline characteristics

A. Preoperative outcome

Variables	Analyzed population, N = 57
Age [years]	70.8 ±6.9
Male sex, n (%)	42 (73.7)
BMI [kg/m ²]	28.3 ±4.7
Diabetes, n (%)	22 (38.6)
Hypertension, n (%)	53 (93)
Hyperlipidemia, n (%)	55 (96.5)
Smoking, n (%)	20 (35.1)
Previous stroke or TIA, n (%)	15 (26.3)
Previous MI, n (%)	18 (31.6)
CKD, n (%)	14 (24.6)
Preoperative creatine level [μmol/l]	91.4 ±23.5
Preoperative platelet count [× 10 ³ /μl]	234.3 ±74.3
Three-vessel disease, n (%)	47 (82.5)
LM disease, n (%)	22 (38.6)
EuroSCORE II	2.7 ±1.3

B. Postoperative outcome

Variables	Analyzed population, N = 57
30-day all-cause death, n (%)	0 (0)
30-day MACCE, n (%)	0 (0)
Chest-tube output before clopidogrel administration [ml/kg/h]	0.21 (0.12–0.38)
Chest-tube output after clopidogrel administration [ml/kg/h]	0.36 (0.24–0.59)
Postoperative platelet count [×10 ³ /μl]	150.7 ±50.3
BE, n (%)	11 (19.3)
Re-exploration for bleeding, n (%)	5 (8.7)
Cardiac tamponade, n (%)	0 (0)
Pleural hematoma, n (%)	2 (3.5)
Active bleeding, n (%)	1 (1.8)
PRBC transfusion (≥ 5 units), n (%)	6 (10.5)
FFP transfusion (≥ 5 units), n (%)	8 (14)
GI bleeding, n (%)	0 (0)
AKI, n (%)	13 (22.8)
Postoperative creatinine level [μmol/l]	106.7 ±49.2

Data shown as mean ± SD or as median (IQR), number (percentage). BMI – body mass index, TIA – transient ischemic attack, MI – myocardial infarction, CKD – chronic kidney disease, LM – left main, MACCE – major adverse cardiac and cerebrovascular events, BE – bleeding event, PRBC – packed red blood cells, FFP – fresh frozen plasma, GI – gastrointestinal, AKI – acute kidney injury. MACCE was defined as cardiac death, cerebrovascular death, non-fatal cardiac arrest, acute myocardial infarction, stroke, or TIA. BE was defined as re-exploration for bleeding, pleural hematoma, cardiac tamponade, active bleeding (chest-tube output > 1.5 ml/kg/h), massive blood product transfusions (≥ 5 units of PRBC or FFP), or gastrointestinal bleeding within 30 days after surgery. AKI was defined as an increase in serum creatinine by ≥ 26.5 μmol/l within 48 h after surgery.

was performed as soon as possible after weaning off the sedation following completion of a combined procedure.

All CABG procedures were performed via a median sternotomy and with CPB. Heparinization was first started during the CAS procedure with 1 mg/kg intra-arterially as a bolus with a target activated clotting time (ACT) of 250 s. Activated clotting time was then assessed on the admission to the operating room and an additional dose of heparin was administered in order to achieve ACT ≥ 480 s before CPB start. Heparinization was subsequently reversed by protamine 1 : 1.

Prior to the procedure all patients were receiving aspirin (75 mg orally) according to the primary prevention algorithm. Postoperative antiplatelet management was obtained with a loading dose of clopidogrel (300 mg) administered through a nasogastric tube within the first hours after surgery. The decision to institute clopidogrel was made based on the chest-tube output volume. From the next postoperative day, all patients received dual antiplatelet therapy with clopidogrel (75 mg orally) and aspirin (75 mg orally) for a duration of 1 month (Figure 1).

All patients were followed up as part of a standard cardiac surgery out-patient clinic appointment 1 month after surgery.

Statistical analysis

Statistical analysis was performed using IBM SPSS software. Results were presented based on the parameters of descriptive statistics, including mean values and

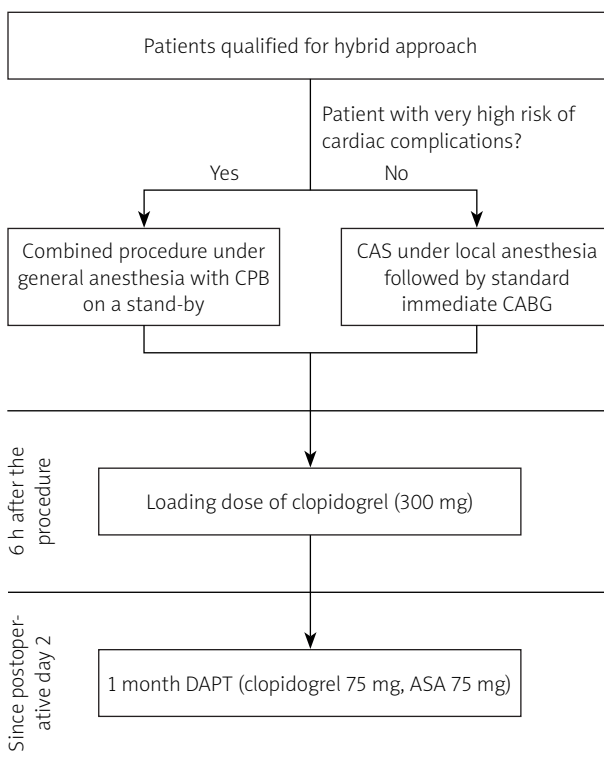


Figure 1. Postoperative antiplatelet management

standard deviations, or median values and quartiles, as appropriate. Categorical variables were presented as percentages. Univariate logistic regression was used to determine risk factors for the end-points. A *p*-value less than 0.05 was considered significant.

Results

We did not have to postpone or cancel the surgery due to neurological complications in any of the scheduled cases. The median time from the end of surgery to the loading dose of clopidogrel was 8 h.

No 30-day mortality or MACCE were observed and patients were usually discharged on postoperative day 8.

Postoperative chest-tube output significantly increased after receiving clopidogrel (0.2 vs. 0.4 ml/kg/h; *p* < 0.001); however, active bleeding was observed only in 3 (5.3%) patients. BE occurred in 11 (19.3%) individuals but re-exploration for bleeding was required only in 5 (8.7%) cases (Table I B).

In a univariate logistic regression model, platelet count \leq 110 000 at the cessation of CPB increased the risk of BE (OR = 5.7 (1.39–23.36); *p* = 0.016); however, no impact was found with respect to preoperative platelet count or the platelet count decrease during the CPB.

Acute kidney injury was observed in 13 (22.8%) patients and the risk increased with the duration of CPB based on a univariate logistic regression model (OR = 1.41 (1.06–1.88); *p* = 0.02 for every 10 min). In all cases effective diuresis was successfully maintained with intravenous loop diuretics.

Discussion

The proper timing and modality of multisite revascularization remains an unresolved issue. Nevertheless, current guidelines underline the necessity to individualize patients' care [3]. The approach proposed in this study appears to be a satisfactory alternative for patients with severe carotid stenosis and coronary artery disease requiring urgent surgical intervention. However, in spite of the potential benefits, which include a decrease of cardiac and neurological complications, there are a few major concerns regarding the management within the early postoperative period that necessitate a multidisciplinary discussion.

Firstly, patients after hybrid procedures require quick implementation of a dual antiplatelet therapy (DAPT), including a loading dose of clopidogrel [6]. In spite of the fact that chest-tube output significantly increased after clopidogrel administration, the proposed approach appears to be safer than operating on patients in whom DAPT is already instituted, i.e. in case of a staged multisite revascularization [3, 11]. In the study, the surgical criteria for active bleeding were met only in 3 individuals. Therefore, in spite of a very high reported BE rate (19.3%), in comparison to other studies, we still consider

the proposed procedure to be a safe method in terms of bleeding complications. Our endpoint included adverse events that are usually not reported, so we could achieve the highest possible sensitivity. Moreover, out of all BE, re-exploration was observed only in 5 cases, providing an acceptable rate of 8.7% that is comparable to our center's outcome after standard CABG [12].

Nevertheless, the occurrence of BE was difficult to predict, and based on the univariate analysis, the only factor increasing the risk was the platelet count \leq 110 000 at the cessation of CPB. Although no tests for platelet activity were performed postoperatively before or after instituting clopidogrel, based on the literature, it is known that 300 mg of clopidogrel usually inhibits around 50% of platelets at 4 h after administration [13]. Therefore, in those individuals with a count of 110 000 at the cessation of CPB, only around 55 000 platelets are expected to be active, which is not sufficient to provide optimal hemostasis within the early perioperative period. Moreover, according to the EACTS guidelines, microvascular bleeding observed at the end of a cardiac procedure is an indication for platelet transfusion in patients receiving antiplatelet therapy [14]. Although acute stent thrombosis is rarely observed in terms of carotid revascularization, platelet transfusion should be administered with caution in these individuals. Therefore, such procedures require very precise intraoperative hemostasis, which limits the availability only to experienced cardiac centers.

Another expected complication, due to the combined effect of both intravenous contrast administration and CPB, was AKI. Although it occurred in almost 30% of the cases, it is consistent with the rates reported after standard cardiac surgery procedures [15]. Moreover, in none of the patients was hemodialysis required, which proves the safety of the procedure in terms of potential renal impairment.

Nevertheless, despite these complications and high perioperative risk assessed with the EuroSCORE II, we observed excellent 30-day outcomes with no MACCE and no mortality. These excellent results suggest that in the case of CAS combined with immediate CABG, antiplatelet therapy managed with a loading dose of clopidogrel within the first 24 h and regular DAPT starting on the next postprocedural day is a safe approach, as no early thrombosis was observed in implanted stents. Presumably, prolonged ACT achieved for on-pump CABG guarantees the safety of such a delay in introducing DAPT without increasing the risk of intracranial bleeding complications.

Limitations

The study is a retrospective analysis of a small sample size from a single center. As only one factor was de-

terminated to be significant in univariate regression models, multivariate analyses were not performed.

Conclusions

Performing one-day CAS combined with subsequent CABG is feasible in a specialized cardiac center and can be performed safely by an experienced multidisciplinary team with satisfactory early results and a low surgical complication rate.

Conflict of interest

The authors declare no conflict of interest.

References

1. Borger MA, Fremes SE, Weisel RD, et al. Coronary bypass and carotid endarterectomy: does a combined approach increase risk? A metaanalysis. *Ann Thorac Surg* 1999; 68: 14-20.
2. Naylor AR, Bown MJ. Stroke after cardiac surgery and its association with asymptomatic carotid disease: an updated systematic review and meta-analysis. *Eur J Vasc Endovasc Surg* 2011; 41: 607-24.
3. Aboyans V, Ricco JB, Bartelink ML, et al. 2017 ESC Guidelines on the Diagnosis and Treatment of Peripheral Arterial Diseases, in collaboration with the European Society for Vascular Surgery (ESVS). *Eur Heart J* 2018; 39: 763-816.
4. Randall MS, McKeivitt FM, Cleveland TJ, et al. Is there any benefit from staged carotid and coronary revascularization using carotid stents? A single-center experience highlights the need for a randomized controlled trial. *Stroke* 2006; 37: 435-9.
5. Van der Heyden J, Suttorp MJ, Bal ET, et al. Staged carotid angioplasty and stenting followed by cardiac surgery in patients with severe asymptomatic carotid artery stenosis: early and long-term results. *Circulation* 2007; 116: 2036-42.
6. Versaci F, Del Giudice C, Scafuri A, et al. Sequential hybrid carotid and coronary artery revascularization: immediate and mid-term results. *Ann Thorac Surg* 2007; 84: 1508-14.
7. Chiariello L, Nardi P, Pellegrino A, et al. Simultaneous carotid artery stenting and heart surgery: expanded experience of hybrid surgical procedures. *Ann Thorac Surg* 2015; 99: 1291-7.
8. Latacz P, Simka M, Brzegowy P, et al. Patient- and lesion-tailored algorithm of endovascular treatment for arterial occlusive disease of extracranial arteries supplying the brain: safety of the treatment at 30-day follow-up. *Adv Interv Cardiol* 2017; 13: 53-61.
9. Pieniżek P, Tekieli L, Musiatek P, et al. Carotid artery stenting according to the tailored-CAS algorithm is associated with a low complication rate at 30 days: data from the TARGET-CAS study. *Kardiologia* 2012; 70: 378-86.
10. Pieniżek P, Musialek P, Kablak-Ziembicka A, et al. Carotid artery stenting with patient- and lesion-tailored selection of the neuroprotection system and stent type: early and 5-year results from a prospective academic registry of 535 consecutive procedures (TARGET-CAS). *J Endovasc Ther* 2008; 15: 249-62.
11. Valgimigli M, Bueno H, Byrne RA, et al. 2017 ESC focused update on dual antiplatelet therapy in coronary artery disease developed in collaboration with EACTS. *Eur Heart J* 2017; 39: 213-60.
12. Piątek J, Kędziora A, Konstanty-Kalandyć J, et al. Risk factors for in-hospital mortality after coronary artery bypass grafting in patients 80 years old or older: a retrospective case-series study. *Peer J* 2016; 4: e2667.
13. Fukushima K, Kobayashi Y, Kitahara H, et al. Effect of 150-mg vs 300-mg loading doses of clopidogrel on platelet function in Japanese patients undergoing coronary stent placement. *Circ J* 2008; 72: 1282-4.
14. Pagano D, Milojevic M, Meesters MI, et al. 2017 EACTS/EACTA Guidelines on patient blood management for adult cardiac surgery. *Eur J Cardiothorac Surg* 2018; 53: 79-111.
15. O'Neal JB, Shaw AD, Billings FT. Acute kidney injury following cardiac surgery: current understanding and future directions. *Crit Care* 2016; 20: 187.