


Received: 10 October 2017

Accepted: 21 November 2017

DOI: 10.1002/joa3.12026

CASE REPORTWILEY *Journal of Arrhythmia*
Open Access

Temporary external implantable cardioverter-defibrillator as a bridge to reimplantation after infected device extraction

Maciej Dębski MD¹  | Andrzej Ząbek MD, PhD, MSc¹ | Krzysztof Boczar MD, PhD¹ |
Małgorzata Urbańczyk-Zawadzka MD² | Jacek Lelakowski MD, PhD^{1,3} |
Barbara Małecka MD, PhD^{1,3}

¹Department of Electrophysiology, John Paul II Hospital, Krakow, Poland

²Radiology and Diagnostic Imaging Department, John Paul II Hospital, Krakow, Poland

³Institute of Cardiology, Jagiellonian University Medical College, Krakow, Poland

Correspondence

Maciej Dębski, Department of Electrophysiology, John Paul II Hospital, Kraków, Poland.
Email: maciekdebski@gmail.com

Abstract

Patients with cardiac implantable electronic devices (CIED) and endovascular infection represent a difficult management group. The explantation of an implantable cardioverter-defibrillator (ICD) system deprives the patient of the protection against life-threatening ventricular tachyarrhythmias. In this study, we describe feasibility and clinical outcomes of bridging with temporary dual-coil ICD lead and external ICD following the extraction of a CIED due to endovascular infection and compare the performance of this approach to other available options.

KEYWORDS

device-related infection, implantable cardioverter-defibrillator, sudden cardiac death, transvenous lead extraction, ventricular tachycardia

1 | INTRODUCTION

The mainstay of treatment in patients with cardiac implantable electronic device (CIED)-related infection is removal of all hardware.¹ The benefit of providing backup defibrillation protection after explantation of a right ventricular shock lead varies according to patient's risk of sudden cardiac death (SCD). In danger are patients in secondary SCD prevention, and those with earlier implantable cardioverter-defibrillator (ICD) therapies, relative to primary prevention patients who have never received appropriate ICD therapies.²

2 | CASE REPORT

A 64 year-old woman was admitted due to CIED-related infective endocarditis. Her past medical history was remarkable for non-ST-segment elevation myocardial infarction in 2001. Subsequent coronary angiogram showed no significant intraluminal lesions. Due to

sick sinus syndrome, she received a dual-chamber permanent pacemaker in 2001. After cardiac arrest caused by ventricular fibrillation in 2002, she was implanted contralaterally with single-chamber ICD for secondary prevention of sudden cardiac death. During 3 months before the index admission, patient had been hospitalized twice due to recurrent fever, pneumonia, and massive saddle pulmonary embolism. At that period, she presented with repetitive (11 episodes) ventricular tachycardia (VT) which triggered, in total, 33 antitachycardia pacing (ATP) sequences and 16 shocks. Two episodes of VT lasted for several minutes, a number of ICD therapies were ineffective, and VT was terminated with 5th shock and 9th shock, respectively. Lead-dependent infective endocarditis was diagnosed based on fever, vegetations, and septic pulmonary embolism. Blood cultures were negative. After admission to tertiary referral center for transvenous lead extraction (TLE), a single-step procedure of complete transvenous extraction of all hardware was performed with the use of mechanical systems (Byrd Polypropylene Dilator Sheath Set, Cook Medical™). The ICD lead was identified as the most challenging to extract and was hence extracted first;

This is an open access article under the terms of the Creative Commons Attribution-NonCommercial License, which permits use, distribution and reproduction in any medium, provided the original work is properly cited and is not used for commercial purposes.

© 2017 The Authors. *Journal of Arrhythmia* published by John Wiley & Sons Australia, Ltd on behalf of the Japanese Heart Rhythm Society.

the whole DDD pacemaker was then extracted from the left side of chest. As a bridge to permanent ICD reimplantation, a temporary system was implanted, consisting of an active-fixation dual-coil DF4 ICD lead (St. Jude Medical Durata™ 7120Q-65) inserted via percutaneous puncture of the left subclavian vein, anchored to the skin, and attached to an epicutaneous single-chamber defibrillator (St. Jude Medical Ellipse™ VR) (Figure 1A-B). “Active-can” ICD was turned off, and the shock polarity was programmed from the right ventricular coil to the superior vena cava coil. Two weeks later, patient developed two episodes of VT, one of which was stopped by a first burst of ATP (Figure 2A), and the other did not respond to ATP sequence and was terminated with a 35 J shock (Figure 2B-C). The ventricular arrhythmia was triggered by sinus bradycardia (Figure 2D); hence, later overdrive VVI pacing at 70 beats per minute fully suppressed the ventricular tachyarrhythmia for the remaining period of the endocarditis treatment (Figure 2E). Her antiarrhythmic treatment consisted of sotalol increased from 80 mg twice daily to three times daily. Chronic treatment with amiodarone was deferred due to the past medical history of

amiodarone-induced thyrotoxicosis. Antibiotic treatment consisted of vancomycin 1 g twice daily and ceftriaxone 2 g twice daily. Finally, 6 weeks after the TLE procedure, a new dual-chamber ICD with single-coil shock lead was implanted in the left pectoral region, and temporary ICD system was removed with simple traction. Evaluation at a 3 month follow-up showed that the patient was in good condition.

3 | DISCUSSION

Bridging patients with prior ICD therapies who require continuous ICD backup in the period between device explantation and reimplantation is particularly challenging.² The options available to physicians include immobilization in an intensive care unit or telemetry ward, with continuous ECG monitoring where instant access to external defibrillation is provided; a wearable cardioverter-defibrillator (WCD)³; and a subcutaneous ICD (S-ICD) as a permanent reimplantation device.⁴

A promising approach for patients in whom ICD implantation must be deferred, but in whom there is an urgent need to manage malignant tachyarrhythmias, is bridging with a temporary external ICD. Cooper et al reported a successful use of external ICD, programmed to burst ATP therapies only and connected to an active-fixation pacemaker lead, in a patient who had both an ICD infection and a history of recurrent VT (responsive to single ATP therapy).⁵ Furthermore, in a similar setting, Dell’Era et al showed efficacious delivery of ATP and shock from a system consisting of a temporary dual-coil active-fixation DF4 lead, connected to an external ICD with passive-can shock configuration.⁶ Our case demonstrates an additional method of controlling heart rhythm with VVI overdrive pacing, which has not been described in the aforementioned reports.

The noteworthy benefit of the temporary external ICD system over WCD is that it automatically starts treatment, whereas the latter is interactive and significantly depends on patient compliance. Moreover, an external ICD shares the same capacities as a traditional ICD, enabling bradycardia pacing, overdrive pacing, and ATP therapies. These are unavailable in the treatment choices involving “external” defibrillation, such as continuous ECG monitoring in an intensive care unit, WCD, and S-ICD.

A limitation of the presented technique is a temporary ICD lead in the vascular system, which may impede complete infection elimination and contribute to increased risk of infection recurrence. Promising short-term outcomes with no early infection recurrences were reported by Maciąg et al in a retrospective analysis of 34 pacemaker-dependent patients. The patients were bridged with externalized active-fixation pacing lead for 4-26 days following TLE due to infection.⁷ Amraoui et al in a retrospective analysis of 80 consecutive pacemaker-dependent patients bridged with externalized pacing lead for 4-14 days reported excellent short- and long-term effects with no early lead dislodgement and no infection recurrence at 1 year follow-up.⁸ Of note, Perrin et al presented follow-up outcomes in the group of 52 pacemaker-dependent patients who were

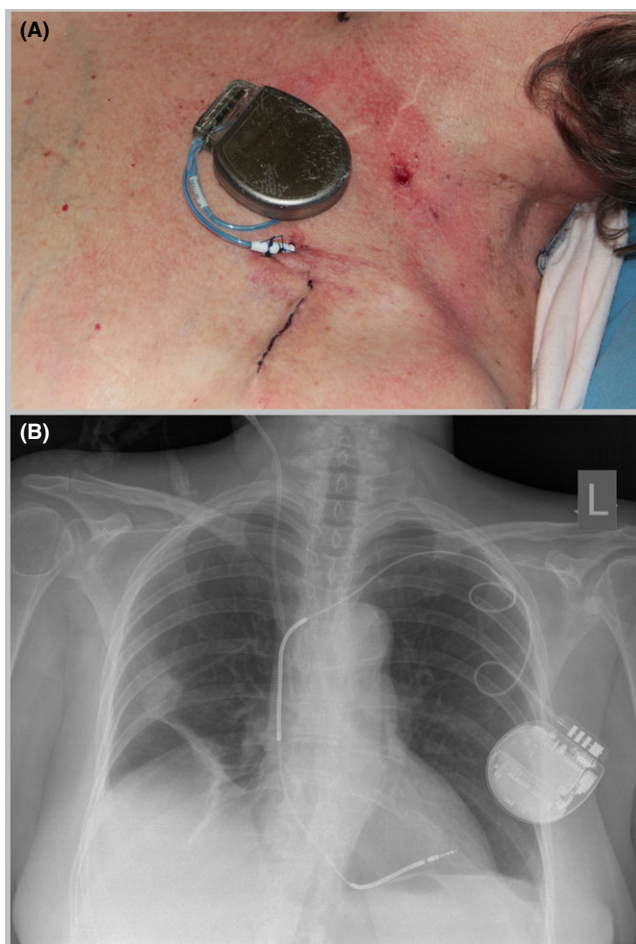


FIGURE 1 A, ICD lead implanted via a percutaneous puncture of the left subclavian vein, sutured to the skin, and connected to ICD unit; B, Chest x-ray after lead extraction and temporary dual-coil ICD lead implantation

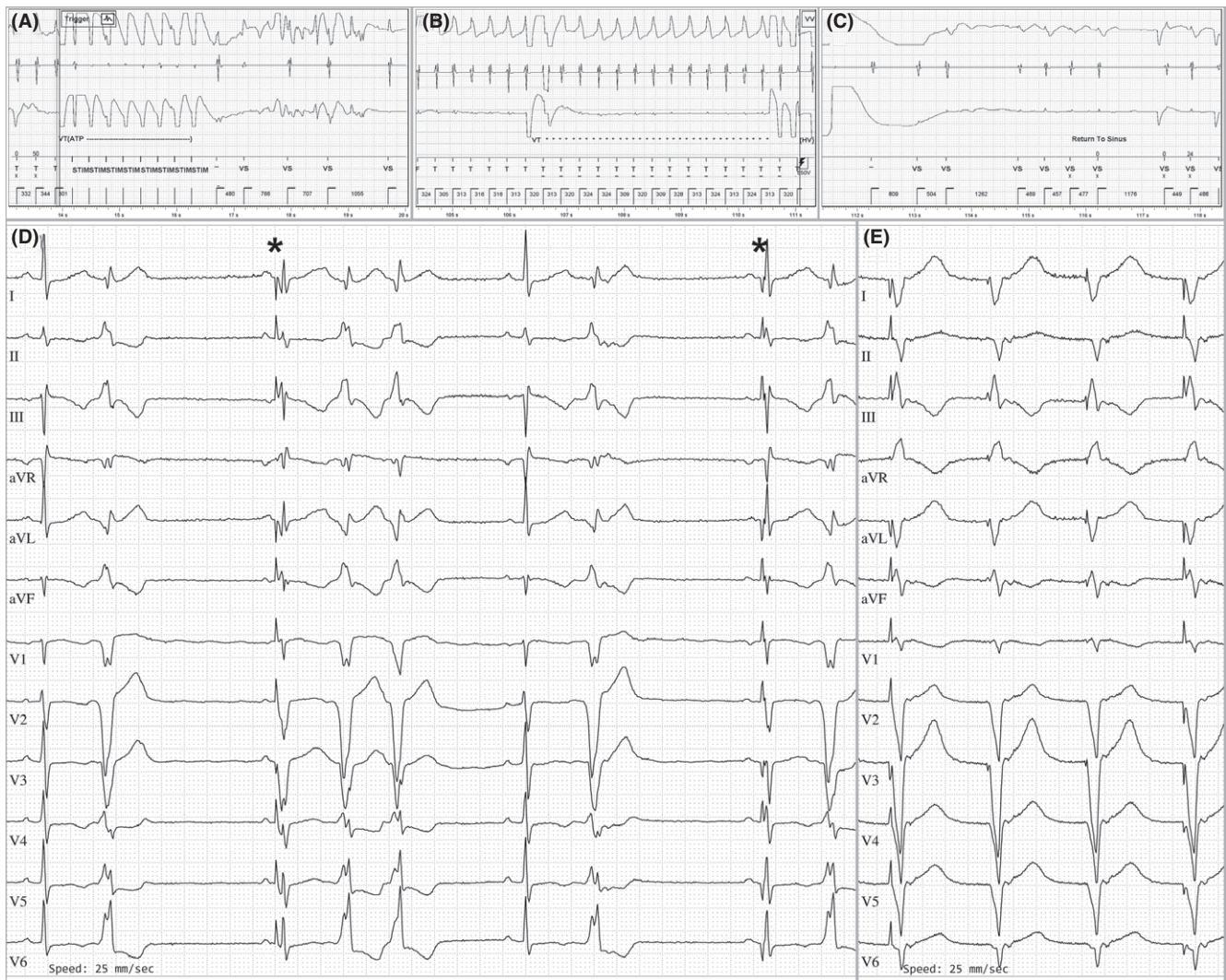


FIGURE 2 A, VT termination via ATP burst; B-C, VT termination via 35 J shock; D, Bradycardia and ventricular ectopic beats (*—pacing spikes and ventricular fusion beats); E, Overdrive VVI pacing

bridged with screwed-in temporary lead for 11.1 ± 9.7 days and retrospectively followed up for a mean period of 25.2 months: Eight patients (15.4%) developed vegetations on their temporary lead; one temporary lead dislodged with sudden loss of capture; and one patient developed a CIED reinfection after 21 months of follow-up.⁹ Undoubtedly, a prospective study would be required to fully assess the long-term safety of temporary lead bridging. Importantly, in the above-mentioned studies by Maciąg et al and Perrin et al, up to 20% of patients had an infected ICD system,^{7,9} whereas in the study by Amraoui et al, ICD patients were excluded from analysis.⁸

The technique described above provides an important option for prolonged ICD backup. The presented case shows that a temporary external ICD is an efficacious bridge to permanent device reimplantation.

CONFLICT OF INTEREST

Authors declare no Conflict of Interests for this article.

ORCID

Maciej Dębski  <http://orcid.org/0000-0002-3669-3916>

REFERENCES

1. Wilkoff BL, Love CJ, Byrd CL, et al. Transvenous lead extraction: heart rhythm society expert consensus on facilities, training, indications, and patient management. *Heart Rhythm*. 2009;6:1085–104.
2. Nishii N. Arrhythmia management after device removal. *J Arrhythm*. 2015;32:287–92.
3. Piccini Sr JP, Allen LA, Kudenchuk PJ, et al. Wearable cardioverter-defibrillator therapy for the prevention of sudden cardiac death. *Circulation*. 2016;133:1715–27.
4. Boersma L, Burke MC, Neuzil P, et al. Infection and mortality after implantation of a subcutaneous ICD after transvenous ICD extraction. *Heart Rhythm*. 2016;13:157–64.
5. Cooper JM, Lavi N, Polin GM, et al. Temporary external implantable cardioverter defibrillator in the pacemaker-dependent ventricular tachycardia patient. *Europace*. 2011;13:761–3.

6. Dell'Era G, Magnani A, Occhetta E. External implantable defibrillator as a bridge to reimplant after implantable cardioverter-defibrillator explant. *Europace*. 2015;17:1726.
7. Maciąg A, Syska P, Oreziak A, et al. Long-term temporary pacing with an active fixation lead. *Kardiol Pol*. 2015;73:1304–9.
8. Amraoui S, Sohal M, Li A, et al. Comparison of delayed transvenous reimplantation and immediate surgical epicardial approach in pacing-dependent patients undergoing extraction of infected permanent pacemakers. *Heart Rhythm*. 2015;12:1209–15.
9. Perrin T, Maille B, Lemoine C, et al. Comparison of epicardial vs. endocardial reimplantation in pacemaker-dependent patients with

device infection. *Europace*. 2017;1–9. <https://doi.org/10.1093/europace/eux111>. [Epub ahead of print]

How to cite this article: Dębski M, Ząbek A, Boczar K, Urbańczyk-Zawadzka M, Lelakowski J, Małecka B. Temporary external implantable cardioverter-defibrillator as a bridge to reimplantation after infected device extraction. *J Arrhythmia*. 2018;34:77–80. <https://doi.org/10.1002/joa3.12026>