

(17)

AJL macular buckle for the treatment of myopic foveoschisis with posterior staphyloma

Implantacja plombki plamkowej AJL w leczeniu krótkowzrocznego rozwarstwienia siatkówki w plamce z towarzyszącym mu garbiakiem tylnym

Krzysztof Morawski, Joanna Kozioł-Moszczyńska, Katarzyna Kozicka, Joanna Miniewicz, Agnieszka Kubicka-Trzaska, Bożena Romanowska-Dixon

Chair of Ophthalmology Jagiellonian University Medical College, Kraków, Poland

Department of Ophthalmology and Ocular Oncology University Hospital, Kraków, Poland

Head of the Department: Professor Bożena Romanowska-Dixon, MD, PhD

Summary:

The aim of the paper is to discuss a new treatment method of myopic foveoschisis with posterior staphyloma using pars plana vitrectomy with internal limiting membrane peeling and implantation of AJL macular buckle. The case of a 48-year-old woman admitted to our department due to myopic foveoschisis with posterior staphyloma of the left eye is presented. The patient underwent pars plana vitrectomy and implantation of AJL macular buckle. The anatomy of the posterior pole was improved as a result of retinal reattachment in the macular area confirmed clinically and with the deep range imaging optical coherence tomography. Postoperative visual acuity was also improved. We also achieved resolution of subjective symptoms such as metamorphopsia and relative scotoma in a visual field. AJL macular buckle implantation and vitrectomy with internal limiting membrane peeling can be an effective treatment of the myopic foveoschisis with posterior staphyloma.

Key words:

high myopia, macular buckling, myopic foveoschisis.

Streszczenie:

Celem pracy jest przedstawienie nowej metody leczenia krótkowzrocznego rozwarstwienia siatkówki w plamce za pomocą plombki plamkowej AJL oraz zabiegu pars plana witrektomii z peelingiem błony granicznej wewnętrznej. Leczeniem i obserwacją objęto 48-letnią chorą przyjętą do kliniki z powodu rozwarstwienia siatkówki okolicy plamkowej w przebiegu wysokiej krótkowzroczności z towarzyszącym mu garbiakiem tylnym oka lewego. Wykonano zabieg pars plana witrektomii z peelingiem błony granicznej wewnętrznej, a następnie zaimplantowano plombę plamkową AJL. W wyniku leczenia uzyskano przyłożenie siatkówki w plamce oraz odtworzono morfologię dołka – potwierdzone badaniem klinicznym oraz badaniem deep range imaging optical coherence tomography. Ponadto stwierdzono poprawę funkcji oka oraz ustąpienie objawów subiektywnych tj. metamorfopsji i mroczka względnego w centrum pola widzenia. Implantacja plombki plamkowej AJL oraz witrektomia z peelingiem błony granicznej wewnętrznej mogą być skutecznym sposobem leczenia krótkowzrocznego rozwarstwienia siatkówki w plamce z towarzyszącym mu garbiakiem tylnym.

Słowa kluczowe: wysoka krótkowzroczność, plomba plamkowa, krótkowzroczne rozwarstwienie siatkówki.

The authors declare no conflict of interest/ Autorzy zgłaszają brak konfliktu interesów w związku z publikowaną pracą

Introduction

Pathological myopia is defined as a spherical aberration over -6.0 D or ocular length over 26.0 mm. In pathological myopia, the eye elongates anteroposteriorly which causes degenerative lesions to the sclera, retina, choroid and the optic disc.

Posterior staphyloma with concomitant myopic foveoschisis or retinal detachment within the posterior pole is one of the most severe complications of pathological myopia. It presents a challenge for vitreoretinal surgery (1–3). Pars plana vitrectomy, without the indentation (buckling) of the posterior pole, may be insufficient to achieve vision improvement and restore normal macular anatomy in these cases (4–6).

The aim of this paper is to present the results of combined surgical treatment with pars plana vitrectomy, internal limiting membrane (ILM) peeling and implantation of the AJL macular buckle in a patient with myopic foveoschisis and posterior staphyloma secondary to pathological myopia.

Case report

A 48-year-old female was referred to the Retinal Clinic at the Department of Ophthalmology and Ocular Oncology in Cracow with a presumptive diagnosis of retinal detachment in her left eye. The patient had a 6-month history of vision deterioration and metamorphopsia in her left eye. She had a history of intraocular surgery with iris claw lenses for high myopia correction in both eyes.

The best corrected visual acuity (BCVA) was 0.5 in the right eye (RE) and 0.16 in the left eye (LE). Intraocular pressure was normal in both eyes. Slit lamp examination revealed the presence of iris claw lenses in the anterior chamber of both eyes, other ocular structures were normal. Indirect ophthalmoscopy revealed (Fig. 1) the presence of floaters in the vitreous, peripapillary atrophy, posterior staphyloma, and retinal pigment epithelium (RPE) mottling in the macular area of the right eye as well as myopic macular foveoschisis in the left eye.

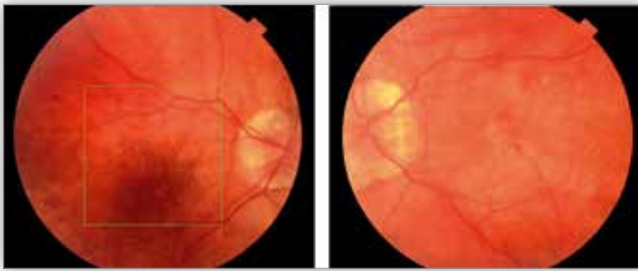

Fig. 1. Color fundus photograph of both right and left eye.

Ryc. 1. Zdjęcie barwne dna oczu prawego i lewego.

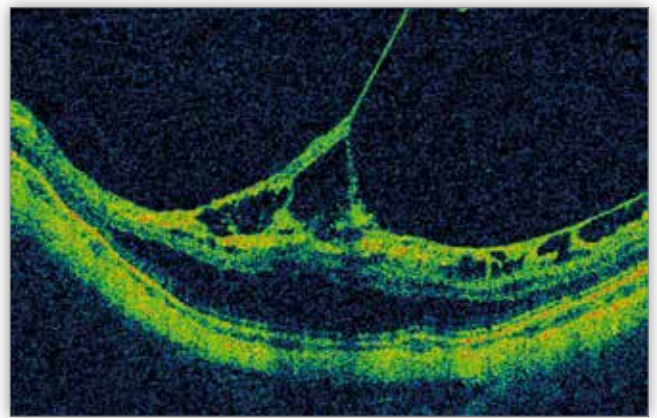


Fig. 5. OCT of the left eye.

Ryc. 5. Wynik badania OCT lewego oka.

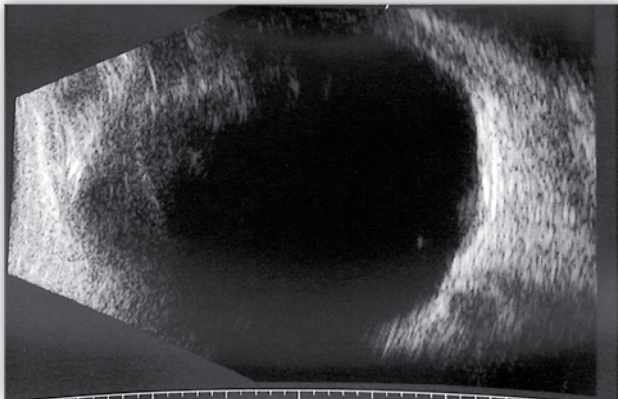


Fig. 2. Ultrasound of the right eye.

Ryc. 2. Wynik badania USG prawego oka.

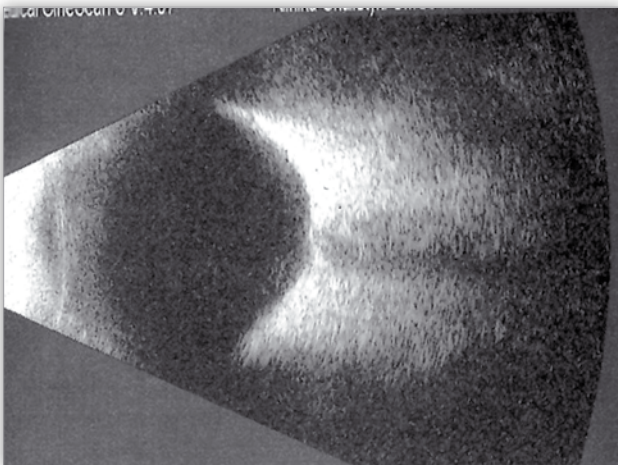


Fig. 3. Ultrasound of the left eye.

Ryc. 3. Wynik badania USG lewego oka.

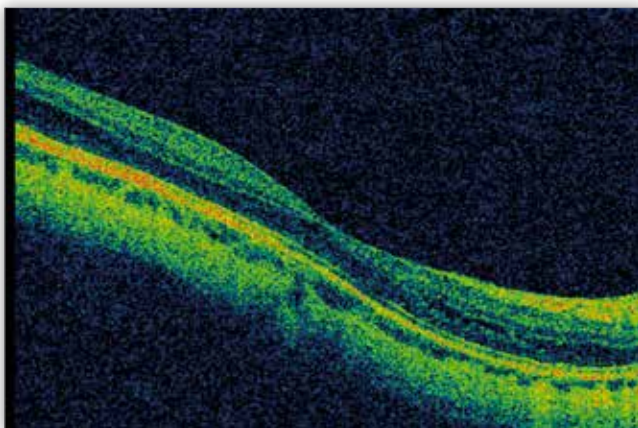


Fig. 4. OCT of the right eye.

Ryc. 4. Wynik badania OCT prawego oka.

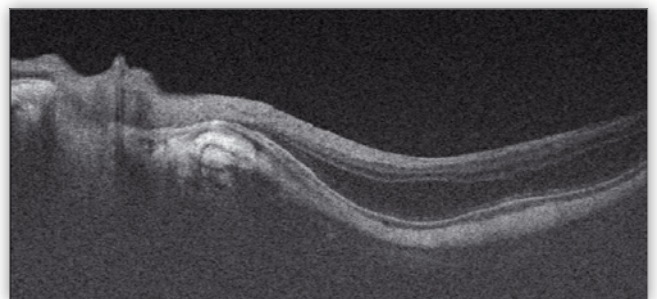


Fig. 6. DRI-OCT of the left eye after the first pars plana vitrectomy.

Ryc. 6. Wynik badania DRI-OCT lewego oka po pierwszej operacji witrektomii.

Additionally, ultrasonography (Fig. 2, 3) and optical coherence tomography (OCT) (Fig. 4, 5) of both eyes were performed. Ultrasonography showed anteroposterior elongation of both eyes and posterior staphylomas without retinal detachment. OCT examination revealed normal macular morphology with the presence of linear changes within the RPE, RPE thinning or atrophy in the right eye as well as the epiretinal membrane with anteroposterior and tangential traction and myopic foveoschisis in the left eye. Ocular length of 2014 was compared to the values of 2006, indicating the progression of axial myopia in both eyes. In the 8-year follow-up (2006–2014), ocular axial dimension changed from 29.7 mm to 31.0 mm and from 29.9 mm to 31.8 in RE and LE, respectively. This gave a basis for a definitive diagnosis of myopic foveoschisis with vitreoretinal tractions in the macular area and coexisting posterior staphyloma in the left eye. The patient was found eligible for pars plana vitrectomy with ILM peeling.

In July 2014, a 23G pars plana vitrectomy in the LE was performed. 23G trocar cannulas were placed in a typical position. Having administered Diphropos, the vitreous and vitreoretinal tractions were removed, followed by membrane blue-assisted ILM and epiretinal membrane peeling. Fluid-air exchange was then performed and 25% sulfur hexafluoride (SF₆) was administered as gas tamponade.

During the follow-up assessments in September and October 2014, there was no improvement in visual acuity. In DRI OCT of the treated eye, myopic foveoschisis was still visible, yet without the tangential and anteroposterior tractions within the macular area (Fig. 6). Thus, primary surgery was considered

unsuccessful due to persistent myopic foveoschisis and the decision to implant the AJL macular buckle was made.

The sclera was exposed with a perilimbal conjunctival peritomy and extraocular rectus muscles were isolated. Traction sutures were placed underneath the isolated muscles. The superotemporal scleral quadrant was exposed. Having inserted the 25G optical fibre into the AJL buckle, the head of the buckle was adjusted and positioned underneath the macula (Fig. 7, 8).

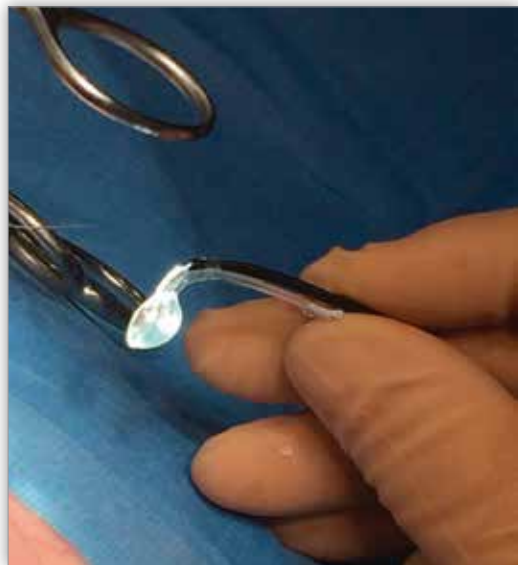

Fig. 7. AJL macular buckle.
Ryc. 7. Plomba plamkowa AJL.

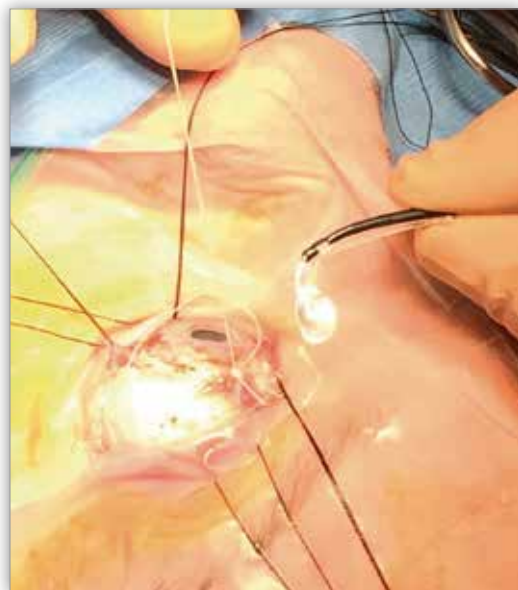

Fig. 8. AJL macular buckle implantation.
Ryc. 8. Implantacja plomby plamkowej AJL.

The buckle was fixed with two Ethibond 5-0 sutures. The three 23G transscleral ports were set up in a typical location. Supplementary peripheral vitrectomy was performed and membrane blue was applied, which confirmed the absence of ILM or pathological membranes on the retinal surface, as it did not stain. After the fluid-gas exchange, the SF6 20% endotamponade was performed. Finally, the conjunctiva was sutured. The intraoperative and early postoperative course were uneventful.

During follow-up assessments, the patient demonstrated gradual improvement in BCVA, up to 0.2 achieved in July 2015. The fundoscopy showed retinal reattachment in the macular region (Fig. 9). Macular morphology appeared almost normal on DRI OCT scans (Fig. 10).

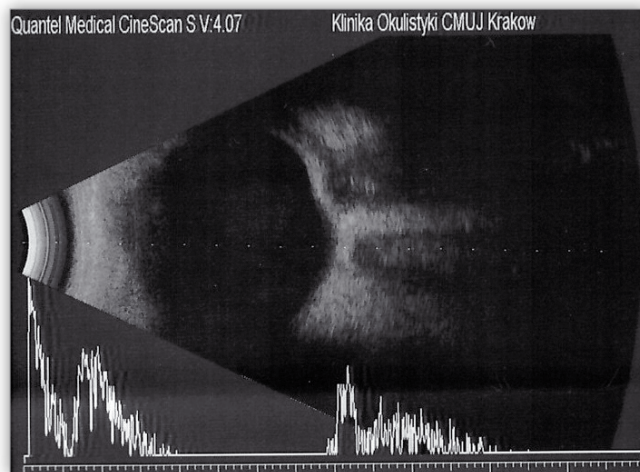


Fig. 9. Ultrasound of the left eye following AJL macular buckle implantation.
Ryc. 9. Wynik badania USG lewego oka po implantacji plomby plamkowej AJL.

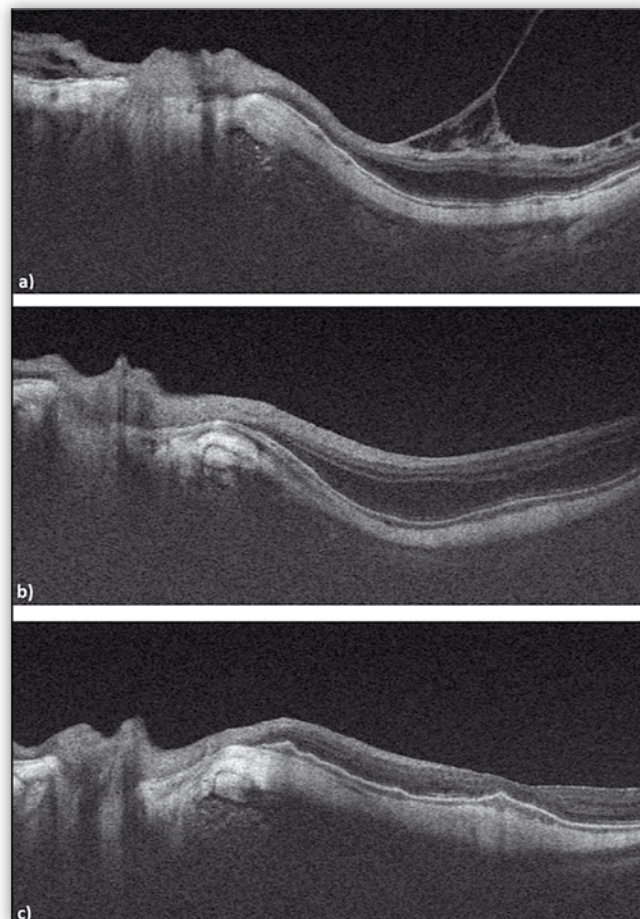


Fig. 10. DRI-OCT of the left eye: a. before the first surgery, b. after the first surgery, c. after reoperation.
Ryc. 10. Wynik badania DRI-OCT lewego oka: a. przed pierwszą operacją, b. po pierwszej operacji, c. po drugiej operacji.

Discussion

In literature, the development and optimum management in myopic foveoschisis secondary to high myopia and a posterior staphyloma has been widely debated. One of the theories to explain the development of lesions within the posterior pole in high myopia postulates that the stretching sclera also stretches the retina, in particular its outer layers. The incomplete posterior vitreous detachment, preretinal membranes, ILM's inflexibility and retinal vessel stiffness collectively contribute to poor expansion of internal retinal layers. As a result, retinoschisis develops, followed by retinal detachment (1, 3). Additionally, in some cases of high myopia, choroidal thinning may lead to an impaired inflow of nutrients to the RPE causing its atrophy, which is responsible for visual acuity deterioration (3).

According to some authors, superficial vitreoretinal tractions, later released with pars plana vitrectomy with or without ILM peeling, are the key mechanism contributing to retinoschisis in high (7–9, 10). However, in some cases, even this treatment proves insufficient and retinoschisis either persists or reoccurs following a complete reattachment. Other authors point out the need to prevent further ocular elongation by providing external mechanical support, such as different types of macular buckles (1, 4, 5, 11). There are reports of positive functional and anatomical results after combined procedures including pars plana vitrectomy and macular buckle implantation (3). In our case, the combined procedure was chosen due to the failure of primary vitrectomy. The postoperative course was uneventful, following the primary and the second procedure.

Retinoschisis secondary to high myopia with coexisting posterior staphyloma is one of the greatest challenges in vitreoretinal surgery. Pars plana vitrectomy with macular buckle implantation physically increases the proximity between the ocular wall and the retina, facilitating retinal reattachment and providing mechanical support for the atrophic RPE where it is poorly adherent to other retinal layers. External mechanical stabilisation offers restoring normal anatomy of the posterior pole and better retinal reattachment than vitrectomy alone. Combined procedure is advisable in complex cases, as the one reported here.

Conclusions

Pars plana vitrectomy combined with AJL macular buckle implantation might be a more effective management option

in myopic macular detachment concomitant with posterior staphyloma, as compared to stand alone pars plana vitrectomy with gas endotamponade.

References:

1. Ward B: *Degenerative myopia: myopic macular schisis and the posterior pole buckle*. Retina. 2013 Jan; 33(1): 224–231.
2. Mc Brien NA, Gentle A: *Role of the sclera in the development and pathological complications of myopia*. Prog Retina Eye Res. 2003; 32: 307–388.
3. El Rayes EN: *Supra choroidal buckling in managing myopic vitreoretinal interface disorders: 1-year data*. Retina. 2014 Jan; 34(1): 129–135.
4. Parolini B, Frisina R, Pinackatt S, Mete M: *A new L-shaped design of macular buckle to support a posterior staphyloma in high myopia*. Retina. 2013 Jul-Aug; 33(7): 1466–1470.
5. Devin F, Tsui I, Morin B, Duprat JP, Hubschman JP: *T-shaped scleral buckle for macular detachments in high myopes*. Retina. 2011 Jan; 31(1): 177–180.
6. Siam AL, El-Mamoun TA, Ali MH: *A restudy of the surgical anatomy of the posterior aspect of the globe: an essential topography for exact macular buckling*. Retina. 2011 Jul-Aug; 31(7): 1405–1411.
7. Rey A, Jürgens I, Maseras X, Carbajal M: *Natural Course and Surgical Management of High Myopic Foveoschisis*. Ophthalmologica. 2014; 231: 45–50.
8. Ikuno Y, Sayanagi K, Soga K, Oshima Y, Ohji M, Tano Y: *Foveal Anatomical Status and Surgical Results in Vitrectomy for Myopic Foveoschisis*. Jpn J Ophthalmol. 2008; 52: 269–276.
9. Ikuno Y, Tano Y: *Vitrectomy for macular holes associated with myopic foveoschisis*. Am J Ophthalmol. 2006; 141: 774–776.
10. Yeh SI, Chang WC, Chen LJ: *Vitrectomy without internal limiting membrane peeling for macular retinoschisis and foveal detachment in highly myopic eyes*. Acta Ophthalmol. 2008; 86: 219–224.
11. Mateo C, Burés-Jelstrup A, Navarro R, Corcóstegui B: *Macular buckling for eyes with myopic foveoschisis secondary to posterior staphyloma*. Retina. 2012 Jun; 32(6): 1121–1128.

The paper was originally received 09.02.2017 (KO-00111-2017)/

Praca wpłynęła do Redakcji 09.02.2017 r. (KO-00111-2017)

Accepted for publication 05.06.2017/

Zakwalifikowano do druku 05.06. 2017 r.

Reprint requests to (Adres do korespondencji):

Katarzyna Kozicka

Klinika Okulistyki i Onkologii Okulistycznej UJ CM

ul. Kopernika 38

31-501 Kraków

e-mail: katarzyna.kozicka@gmail.com