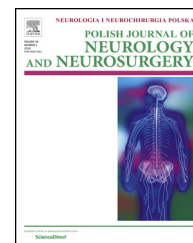

Available online at [www.sciencedirect.com](http://www.sciencedirect.com)

ScienceDirect

journal homepage: <http://www.elsevier.com/locate/pjnns>

## Original research article

# Early results of endovascular treatment of patients with bilateral stenoses of the internal carotid arteries using proximal protection systems at 30-day follow-up



Paweł Latacz<sup>a,\*</sup>, Marian Simka<sup>b</sup>, Tadeusz Popiela<sup>c</sup>, Marek Kazibudzki<sup>d</sup>,  
Tomasz Mrowiecki<sup>a</sup>

<sup>a</sup>Department of Vascular Surgery, University Hospital, Krakow, Poland

<sup>b</sup>Private Healthcare Institution SANA Outpatient Department of Angiology, Pszczyna, Poland

<sup>c</sup>Chair of Radiology, Jagiellonian University Collegium Medicum, Krakow, Poland

<sup>d</sup>Department of Vascular Surgery, John Paul II Hospital, Krakow, Poland

## ARTICLE INFO

## Article history:

Received 24 February 2017

Accepted 30 June 2017

Available online 8 July 2017

## Keywords:

Carotid  
Angioplasty  
Proximal  
Protection  
Systems  
Stents

## ABSTRACT

**Background:** Although surgical endarterectomy remains the treatment of choice for carotid artery stenosis, carotid artery stenting (CAS) with use of proximal protection systems (PPS) plays an very important role as alternative treatment modality, especially in patients with critical, symptomatic lesions.

This study was single-centre study to evaluate the technical and clinical success of proximal protection devices as the first choice for embolic protection in symptomatic and asymptomatic carotid stenosis in patients with bilateral, advanced lesions of carotid arteries (bilateral stenoses or stenosis and occlusion).

**Methods:** This was a post hoc analysis, with 30-day follow up. We analyzed results of treatment of 38 patients who underwent 38 CAS with PPS, 17 such procedures in asymptomatic (group A), and 21 in symptomatic individuals (group B). The GORE<sup>®</sup> Flow Reversal System (W.L. Gore, Flagstaff, AZ, USA) was used in 2 patients, and the Mo.Ma Ultra device (Medtronic, Minneapolis, MN, USA) in 36 patients. Mean age was 68 ± 7 years, 65% percent of patient were male.

**Results:** There were no procedural and during 30-day follow-up neurologic events. Intolerance of occlusion system occurred in 4 patients (11%) in both groups with any later symptoms. Risk factors of this adverse event comprised: lesions of the left internal carotid lesion and coexisting diabetes mellitus.

**Conclusions:** CAS in high risk patients with bilateral lesions of carotid arteries with the use of PPS seems to be a relatively very safe procedure.

© 2017 Published by Elsevier Sp. z o.o. on behalf of Polish Neurological Society.

\* Corresponding author at: Department of Vascular Surgery, University Hospital, ul. Botaniczna 3, 31-503 Krakow, Poland.  
E-mail address: [pawlat@me.com](mailto:pawlat@me.com) (P. Latacz).

<http://dx.doi.org/10.1016/j.pjnns.2017.06.010>

0028-3843/© 2017 Published by Elsevier Sp. z o.o. on behalf of Polish Neurological Society.

## 1. Introduction

Carotid angioplasty and stenting is an alternative treatment modality for the management of stenosis of the carotid artery and plays an important role in stroke prevention. Stenting of carotid artery is particularly preferred in patients presenting with high risk of surgical endarterectomy. Carotid angioplasty and stenting is also used for the treatment of other, non-atherosclerotic lesions of these arteries [1–4]. A number of trials demonstrated that the use of proximal protection systems (PPS) during carotid stenting is safe and effectively protects the brain from ischemic events during the procedure [5–8]. Still, this type of protection is difficult to use in a case of contralateral stenosis or occlusion, and therefore in many such patients an alternative protection system is utilized. In this retrospective study we analyzed the results of treatment in selected patients presenting with significant bilateral stenoses, or stenosis and contralateral occlusion of the internal carotid arteries (ICA), with the procedure performed using PPS.

## 2. Aim

This post hoc analysis, with 30-day follow-up, was aimed at assessment of safety and efficacy of stent implantation for the treatment of atherosclerotic stenoses of the ICAs coexisting with significant contralateral lesions, with the use of a PPS, and also at identification of risk factors associated with such an endovascular technique in these high-risk patients.

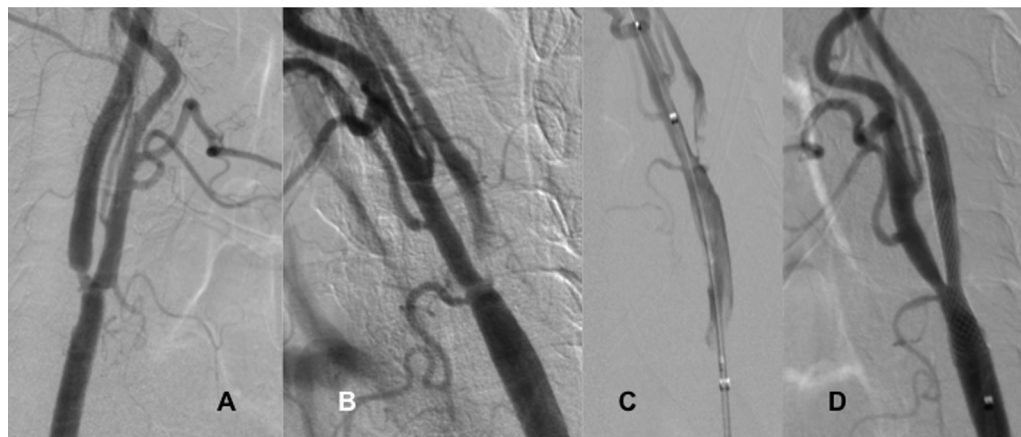
## 3. Patients and methods

We reviewed our register of endovascular interventions and identified 38 patients with bilateral significant lesions of the ICAs who were managed with the use of PPS. From March 2011 to December 2016 there were 38 such patients, 25 males and 13 females, aged  $68 \pm 7$  years, 2 of them (5%) were older than 80 years.

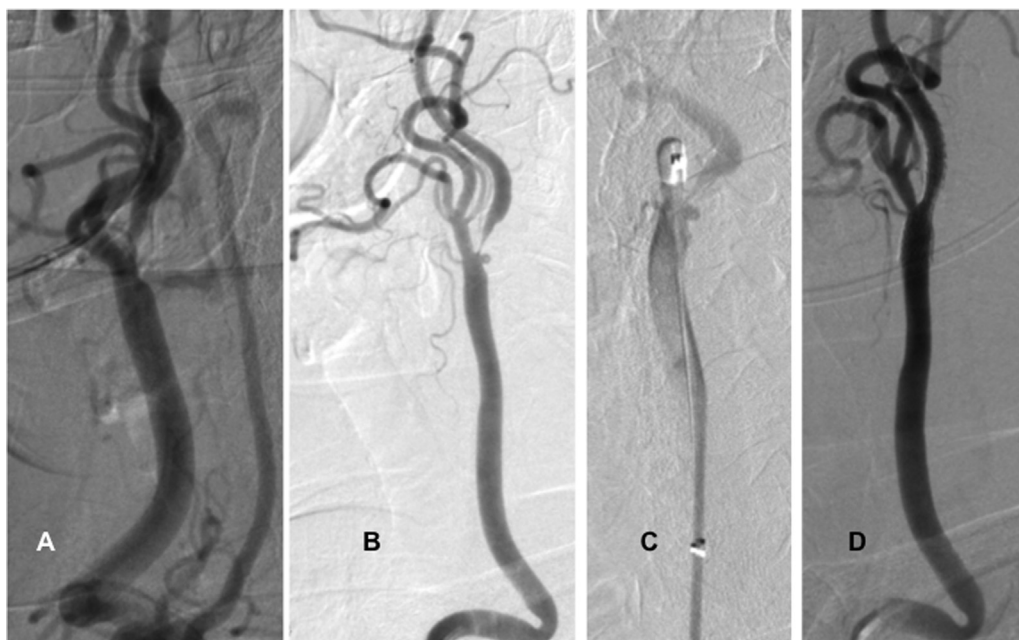
The primary endpoint of this analysis was the proportion of patients who had stroke or stroke-related death. We included all types of strokes, both ipsi- and contralateral, as well as minor, major and fatal strokes. The secondary endpoint was the proportion of patients who had myocardial infarction (both STEMI and non-STEMI events) or a death that was not caused by stroke. In addition to demographic and clinical data of the patients, we analyzed angiographic characteristics, such as presence of coexisting lesions in other arteries supplying the brain, including intracranial stenoses. Also, we assessed endovascular technique used (type of protection, type of stent, duration of the procedure, duration of occlusion of the artery, etc.).

Out of 38 endovascular stent implantations with the use of PPS in this particular patient group, 17 such procedures were performed in asymptomatic patients and 21 in symptomatic ones. Twelve symptomatic patients had a stroke and nine patients presented with a history of transient ischemic attack. The time from an ischemic event to endovascular procedure was 5–190 days, mean time: 45 days. Degree of stenosis of the ICA revealed by initial angiography ranged from 65 to 100% (mean:  $93.9 \pm 8.3\%$ ), thus subtotal stenoses prevailed in these patients. One asymptomatic and three symptomatic patients had contralateral ICAs totally occluded. Other patients presented with severe stenoses of these arteries – on average  $75.5 \pm 14\%$  stenosis in asymptomatic patients and  $78.3 \pm 13\%$  (Fig. 1) in symptomatic ones (Fig. 2). Clinical characteristics of patients and potential risk factors are presented in Table 1 and comparison between asymptomatic and symptomatic patients regarding these risk factors is given in Table 2.

Standard preprocedural management of patients comprised multidisciplinary assessment, including neurological, vascular and cardiologic consultations. Potential risks and benefits associated with the planned procedure were discussed with patients, and all of them gave their written informed consent. Neurological assessment was performed at least before the procedure and on the first postprocedural day. Sonographic follow-up of the treated arteries was performed on the day of procedure, and then after 1 and 6 months.



**Fig. 1** – A patient with bilateral, asymptomatic carotid lesions. (A) Critical stenosis of the right internal carotid artery; (B) subtotal stenosis of the left internal carotid artery; (C) Mo.Ma system introduced on the left side; and (D) final result after implantation of Carotid Wallstent on the left side.



**Fig. 2 – Patient with symptomatic stenosis of the left side and a critical lesion of the right internal carotid artery. (A) Critical narrowing of the right internal carotid artery; (B) critical symptomatic stenosis of the left internal carotid artery; (C) Mo.Ma system – occlusion of left external artery; and (D) final result after implantation Precise RX stent.**

**Table 1 – Clinical characteristics of the patients and potential risk factors; number of patients: N = 38.**

Comorbidities and potential risk factors	N	%
Stable coronary heart disease	10	26.3
Arterial hypertension	32	84.2
Diabetes mellitus type 2	11	28.9
Dislipidemia	26	68.4
Cigarette smoking	10	26.3
Renal impairment	2	5.2
Peripheral artery disease	3	7.9
History of percutaneous coronary angioplasty	3	7.9
History of coronary artery bypass graft surgery	1	2.6
History of myocardial infarction	4	10.5
Symptomatic carotid artery stenosis	19	0.5
History of transient ischemic attack	9	23.7
History of stroke	10	26.3
Bilateral stenosis of the internal carotid artery	31	81.6
Occlusion of the internal carotid artery	3	7.9
Stenosis of the vertebral artery	2	5.2

Two types of PPS were utilized: the Mo.Ma (Medtronic, Minneapolis, MN, USA) and the Gore Flow Reversal System (Gore & Associates, Inc., Flagstaff, AZ, USA). The first system protects the brain against embolization thanks to stopped flow in the ICA, which occurs after the balloons of this system are expanded in the common and external carotid arteries. In the case of the Gore Flow system, there is a flow reversal in the ICA, which results from temporary shunting from the ICA to the femoral vein through catheters and filter of this device. Proximal protection was chosen in patients presenting with subtotal stenoses of the ICA, tortuous carotid arteries, thrombotic and other unstable lesions, and also in other

cases where the use of distal protection was not technically feasible. In one particular patient we utilized both proximal and distal (SpiderFX; Covidien, ev3 Endovascular, Inc., Plymouth, MN, USA) protections. An average time of closure of the common carotid artery by protection system was  $7.5 \pm 3.8$  min (2.1–11.2 min), still a longer time of occlusion regarded earlier interventions and with better expertise and modified technique this time in latter patients was shortened to  $5.2 \pm 2.5$  min. In 17 patients (45%) PPS captured macroscopically detectable embolic material (Table 3). In all patients we implanted self-expandable stents, primarily with a close-cell design. A predilatation before stent implantation was needed in 11 patients (29%) and postdilatation in all patients. After the procedure residual stenosis in all patients was less than 20%.

#### 4. Statistical analysis

Statistical analysis was performed using the SPSS software (Statistical Package for the Social Sciences (version 23.0, SPSS Inc., Chicago, IL, USA)). Continuous variables were expressed as means  $\pm$  standard deviation; categorical variables were expressed as percentages. Analysis of normality was performed with the Kolmogorov-Smirnov test. Comparison of categorical variables between the groups was performed using the chi-square test. Comparisons of continuous variables between the two groups were performed using the independent sample t-test. Multivariate, stepwise backward conditional logistic regression analysis was used to determine independent predictors of successful intervention. All significant parameters in the univariate analysis were selected in the multivariate model. The significance of the two-tailed  $p$  was set at  $p < 0.05$ .

**Table 2 – Risks factors in asymptomatic vs. symptomatic patients (NS – the difference was not statistically significant).**

Risk factor	Asymptomatic patients (17 procedures)	Symptomatic patients (21 procedures)	p value
Patients' age (in years)	68.7 ± 6.7	67.5 ± 8.0	NS
Patients aged >80 years	1	1	NS
Patients aged <60 years	2	7	NS
Male gender	9	13	NS
Stable coronary heart disease	4	6	NS
Congestive heart failure	2	1	NS
Cigarette smoking	5	7	NS
Diabetes mellitus type 2	5	6	NS
Arterial hypertension	13	18	NS
Dislipidemia	10	16	NS
Renal impairment	1	1	NS
Peripheral arterial disease	2	1	NS
History of myocardial infarction	2	2	NS
History of percutaneous coronary angioplasty	1	2	NS
History of coronary artery bypass graft surgery	0	1	NS
Contralateral stenosis of the internal carotid artery	16	18	NS
Occlusion of the internal carotid artery	1	3	NS
Stenosis of the vertebral artery	2	0	NS

**Table 3 – Characteristics of stents utilized and embolic material captured by protection system in asymptomatic vs. symptomatic patients (NS – difference statistically not significant).**

	Asymptomatic patients (17)	Symptomatic patients (21)	p value
Stents (brand)			
Precise (Cordis, Fremont, CA, USA)	5	5	NS
Carotid Wallstent (Boston Scientific, Natick, MA, USA)	7	11	NS
Cristallo Ideale (Medtronic, Minneapolis, MN, USA)	5	5	NS
Stents (design)			
Close-cell design stents	12	16	NS
Open-cell stents	5	5	NS
Macroscopically visible embolic material in protection system			
Single plaque or thrombus	6	10	NS
A little of debris	0	1	NS

**Table 4 – Complications during endovascular procedure and during 30 days follow-up in asymptomatic vs. symptomatic patients; (difference between the groups was not statistically significant).**

Adverse events	Asymptomatic patients (17)	Symptomatic patients (21)
Mild reversible neurological symptoms after introduction of the protection system	2	2
Periprocedural hypotension	1	2
Any fatality	0	0
Stroke	0	0
Transient ischemic attack	0	0
Myocardial infarction	0	0

## 5. Results

Four patients (11%) developed neurological symptoms after introduction of the PPS, but these symptoms of intolerance were present only during occlusion of the protection system and did not result in further clinical consequences. Also, 3 patients (7.8%) developed periprocedural hypotension, which in one case required an intravenous administration of dopamine. Apart from these rather minor events, there were no serious periprocedural complications.

There were no fatalities during 30-day follow-up. Patients were advised to report any neurological events that occurred during this period. They neither developed a stroke, nor did they suffer from milder neurologic ischemic events or other serious non-neurologic complications during 30-day follow-up. Details are given in [Table 4](#).

Logistic multivariate analysis revealed some risk factors significantly predisposing for above-presented periprocedural complications. These comprised left-sided lesions (HR = 8.12;  $p = 0.02$ ) and coexisting diabetes mellitus (HR = 7.36;  $p = 0.03$ ).



## 6. Discussion

Retrospective and open-label design of this study appears to be its main limitation. Also, the group of patients assessed was not homogenous and rather mirrored everyday clinical practice. By the same token, endovascular armamentarium and periprocedural pharmacological management were not standardized but patient-tailored. Nevertheless, our results indicate that carotid artery stenting in patients presenting with bilateral severe lesions can be performed safely and efficiently using the PPS. Similarly to other authors we opt for obligatory use of protection systems during carotid artery stenting [5,6,9]. In our patient series we found macroscopic embolic material captured by PPS quite frequently, in 6 asymptomatic (35.3.0%) and 11 symptomatic (52.4%) patients (Table 3), thus a potential risk of periprocedural embolic stroke in these patients was very high. Although for the time being distal protection devices are predominantly used, there is a growing body of evidence supporting the use of PPS during carotid angioplasty and stenting. This concept is supported by a low rate of neurologic adverse events during such procedures with the use of proximal protection. Bijuklic et al. [10] compared distal and proximal protection systems and found that the latter mode was associated with significantly fewer postprocedural cerebral lesions (45.2% vs. 87.1%;  $p = 0.001$ ) revealed by means of diffusion MR imaging. Similarly, Montorsi et al. [11] who compared PPS (the Mo.Ma) with distal protection system (the FilterWire), demonstrated that there were significantly fewer (13% vs. 93%) periprocedural embolic events if proximal protection were applied.

Since there were no serious complications amongst our patients, we can only discuss risk factors associated with minor adverse events. These risk factors comprised left-sided lesions and diabetes mellitus. Other researchers found that adverse events after carotid stenting with the use of PPS were more likely in patients with bilateral lesions, aged more than 80 years, presenting with long lesions and a history of myocardial infarction [5,6,8].

Metaanalysis by Bersin et al., which was published in 2012 and discussed results of carotid stenting with the use of PPS in 2397 patients, reported stroke rate during 30-day follow-up at the level of 1.71% and incidence of stroke, death or myocardial infarction at the level of 2.6%. In this metaanalysis diabetes mellitus and advanced patient's age were found to be associated with an increased risk of adverse events [12]. A similar metaanalysis by Hornung et al. [13], who studied efficacy of PPS in 124 patients, reported one stroke (0.8%) during 30-day follow-up (of note, in this particular case an open-cell stent was implanted). In the study published by Stabile et al. the Mo.Ma system was used in 1300 patients. The composite complication rate (comprising stroke and death) at 30-day follow-up was 1.4% (3% in symptomatic patients and 0.9% in asymptomatic ones) and was not increased in elderly individuals. By contrast, a low operator experience (less than 100 procedures performed) and symptomatic lesions were associated with a higher risk of adverse events [14]. In the randomized multicenter study ARMOUR, which evaluated a group of 222 patients (15% of them were symptomatic, 29% were older than 80 years; occlusion or stenosis of the

contralateral artery constituted an exclusion criterion for the use of PPS) the composite complication rate (comprising stroke, death and myocardial infarction) was 2.7%, and stroke rate at 30 days follow-up was 0.9% [7]. Efficacy and safety of the Gore Flow Reversal System have been evaluated in the multicentre prospective, nonrandomized study EMPiRE [15]. In this study 245 patients have been studied, including 30% symptomatic and 16% older than 80 years. In this study contralateral stenosis or occlusion of the ICA was not an exclusion criterion; quite the contrary, actually 10.5% of patients enrolled presented with an occlusion of the contralateral ICA. Composite complication rate in this study (including stroke, death, myocardial infarction or TIA) during 30-day follow-up was 4.5%. Composite complication rate comprising only stroke and death was 2.9% (still, not a single patient in this study developed a major stroke). The death/stroke rates in this study in the symptomatic, asymptomatic and patients older than 80 years were 2.6%, 3% and 2.6%, respectively [15].

In our potentially high-risk patients presenting with bilateral stenoses of the ICAs, results at 30 days follow-up were at least as good as in the above-presented large group studies. There were neither strokes nor fatalities, also intolerance of PPS was relatively infrequent (in the AROMOUR study intolerance of proximal protection was seen in 13.8% of patients, despite the fact that individuals presenting with bilateral lesions were not managed using this type of protection [7]). In the EMPiRE study [15] a contralateral stenosis of the ICA did not constitute an exclusion criterion for the use of PPS, still in this study incidence of serious adverse events, such as stroke or death, was quite high.

An increased risk of adverse events in diabetics, which was also revealed in the metaanalysis published by Bersin et al., probably reflects more aggressive course of arterial disease in the settings of diabetes mellitus [11]. An unsuspected finding of our survey was the fact that all four cases of intolerance of PPS, manifesting with neurological symptoms occurring after introduction of the device into the carotid artery, were seen in patients managed for the lesions of the left ICA. It remains unclear if the left ICA is indeed more prone to such adverse events. It is also possible that it is easier to diagnose a mild left-sided cerebral ischemia, since non-paretic clinical symptoms of the left cerebral hemisphere ischemia, such as dysphasia, are more obvious than the symptoms of ischemia of right hemisphere (comprising linguistic deficit, decreased attention, anosognosia, prosopagnosia or other complex deficits, which require a thorough and time-consuming neurological assessment to be revealed). Nonetheless, there were only a few such intolerances of PPS amongst our patients. We believe that a relatively low incidence of these adverse events could be explained by some modifications of endovascular technique used. In each patient we tried to postpone the closure of the common carotid artery until the guidewire and stent were introduced into the distal part of the system. This enabled a shorter average time of the occlusion – 5.2 min instead of 7.5 min. A selective use of both proximal and distal protection system is also an option aimed at minimizing the rate of complications. Such a dual protection has already been shown to be safe and effective [16,17]. Importantly, a high experience of operators could potentially play a role. Stabile et al. [14] have

reported that adverse events after carotid stenting with the use of PPS are less likely when the procedure is performed by operators who have already performed more than 100 such treatments. Expertise of the operator as an independent factor associated with reduced complication rate has also been demonstrated by other studies, and there seems to be a learning curve with significant drop in the incidence of adverse events with more than 200 procedures performed [5-7,18-20].

We utilized lesion-tailored stents, preferentially closed-cell ones. Although we did not observe different clinical outcomes in patients managed with closed- vs. open-cell stents, other researchers revealed better results after implantation of closed-cell devices [21]. Recently, a new generation of carotid stents has been marketed; they combine small area of the cells with flexibility characteristic for open-cell devices, which potentially could improve results of carotid stenting [21,22].

## 7. Conclusions

Results of this retrospective analysis suggest that proximal protection is a safe treatment modality for carotid artery stenting in patients with bilateral stenoses of the ICA. Still, only a prospective study comparing the results of different types of protection systems could guide the treatment in this unique group of patients.

## Conflict of interest

None declared.

## Acknowledgement and financial support

None declared.

## REFERENCES

- [1] Endarterectomy for asymptomatic carotid artery stenosis. Executive committee for the asymptomatic carotid atherosclerosis study. *JAMA* 1995;273:1421-8.
- [2] Barnett HJ, Taylor DW, Eliasziw M, Fox AJ, Ferguson GG, Haynes RB, et al. Benefit of carotid endarterectomy in patients with symptomatic moderate or severe stenosis. North American symptomatic carotid endarterectomy trial collaborators. *N Engl J Med* 1998;339:1415-25.
- [3] North American Symptomatic Carotid Endarterectomy Trial Collaborators. Beneficial effect of carotid endarterectomy in symptomatic patients with high-grade carotid stenosis. *N Engl J Med* 1991;325(7):445-53.
- [4] Randomised trial of endarterectomy for recently symptomatic carotid stenosis: final results of the MRC European Carotid Surgery Trial (ECST). *Lancet* 1998;351(9113):1379-87.
- [5] Cremonesi A, Giowarsingh S, Spagnolo B, Manetti R, Liso A, Furgieri A, et al. Safety, efficacy and long-term durability of endovascular therapy for carotid artery disease: the tailored-Carotid Artery Stenting Experience of a single high-volume centre (tailored-CASE Registry). *EuroIntervention* 2009;5(November (5)):589-98.
- [6] Pieniżek P, Musialek P, Kablak-Ziembicka A, Tekieli L, Motyl R, Przewlocki T, et al. Carotid artery stenting with patient- and lesion-tailored selection of the neuroprotection system and stent type: early and 5-year result from a prospective academic registry of 535 consecutive procedures (TARGET-CAS). *J Endovasc Ther* 2008;15(3):249-62.
- [7] Ansel GM, Hopkins LN, Jaff MR, Rubino P, Bacharach JM, Scheinert D, et al. Investigators for the ARMOUR Pivotal Trial, Safety and effectiveness of the INVATEC MO.MA proximal cerebral protection device during carotid artery stenting: results from the ARMOUR pivotal trial. *Catheter Cardiovasc Interv* 2010;76(July (1)):1-8.
- [8] Pieniżek P, Tekieli L, Musialek P, Kablak Ziembicka A, Przewlocki T, Motyl R, et al. Carotid artery stenting according to the tailored-CAS algorithm is associated with a low complication rate at 30 days: data from the TARGET-CAS study. *Kardiol Pol* 2012;70(4):378-86.
- [9] Reimers B, Schluter M, Castriota F, Tübler T, Corvaja N, Cernetti C, et al. Routine use of cerebral protection during carotid artery stenting: results of a multicenter registry of 753 patients. *Am J Med* 2004;116:217-22.
- [10] Bijuklic K, Wandler A, Hazizi F, Schofer J. The PROFI study (Prevention of Cerebral Embolization by Proximal Balloon Occlusion Compared to Filter Protection During Carotid Artery Stenting): a prospective randomized trial. *J Am Coll Cardiol* 2012;59(15):1383-9.
- [11] Montorsi P, Caputi L, Galli S, Ciceri E, Ballerini G, Agrifoglio M, et al. Microembolization during carotid artery stenting in patients with high-risk, lipid-rich plaque. A randomized trial of proximal versus distal cerebral protection. *J Am Coll Cardiol* 2011;58(16):1656-63.
- [12] Bersin RM, Stabile E, Ansel GM, Clair DG, Cremonesi A, Hopkins LN, et al. A meta-analysis of proximal occlusion device outcomes in carotid artery stenting. *Catheter Cardiovasc Interv* 2012;80(7):1072-8.
- [13] Hornung M, Bertog S, Franke J, Grunwald I, Sievert H. Evaluation of proximal protection devices during carotid artery stenting as first choice for embolic protection. *EuroIntervention* 2015;10:1362-7.
- [14] Stabile E, Salemme L, Sorropago G, Tesorio T, Nammias W, Miranda M, et al. Proximal endovascular occlusion for carotid artery stenting: results from a prospective registry of 1,300 patients. *J Am Coll Cardiol* 2010;55(16):1661-7.
- [15] Clair DG, Hopkins LN, Mehta M, Kasirajan K, Schermerhorn M, Schönholz C, et al. EMPiRE Clinical Study Investigators, Neuroprotection during carotid artery stenting using the GORE flow reversal system: 30-day outcomes in the EMPiRE Clinical Study. *Catheter Cardiovasc Interv* 2011;77(February (3)):420-9.
- [16] Latacz P, Ochała A, Janas P, Pieniżek P, Cebulski W, Tendera M, et al. Composed angioplasty of the multilevel right common and internal carotid artery stenoses with implantation stents with used of proximal and distal protection system. *Kardiol Pol* 2012;70(1):88-90.
- [17] Kajihara Y, Sakamoto S, Kiura Y. Comparison of dual protection and distal filter protection as a distal embolic protection method during carotid artery stenting: a single-center carotid artery stenting experience. *Neurosurg Rev* 2015;38(October (4)):671-6.
- [18] Eckstein HH, Ringleb P, Allenberg JR, Berger J, Fraedrich G, Hacke W, et al. Results of the stent-protected angioplasty versus carotid endarterectomy (SPACE) study to treat symptomatic stenoses at 2 years: a multinational, prospective, randomised trial. *Lancet Neurol* 2008;7:893-902.
- [19] Ielasi A, Latib A, Godino C, Sharp AS, Al Lamee R, Montorfano M, et al. Clinical outcomes following protected carotid artery stenting in symptomatic and asymptomatic patients. *J Endovasc Ther* 2010;17:298-307.

- [20] Latacz P, Simka M, Brzegowy P, Kazibudzki M, Pieniążek P, Ochała A, et al. Patient- and lesion-tailored algorithm of endovascular treatment for arterial occlusive disease of extracranial arteries supplying the brain: safety of the treatment at 30-day follow up. *Adv Interv Cardiol* 2017;13(1):53-61.
- [21] Kouvelos GN, Patelis N, Antoniou GA, Lazaris A, Matsagkas MI. Meta-analysis of the effect of stent design on 30-day outcome after carotid artery stenting. *J Endovasc Ther* 2015;22(October (5)):789-97.
- [22] Setacci C, Speziale F, De Donato G, Sirignano P, Setacci F, Capoccia L, et al. IRON-Guard Study Group, Physician-initiated prospective Italian Registry of carotid stenting with the C-Guard mesh-stent: the IRON-Guard registry. Rationale and design. *J Cardiovasc Surg (Torino)* 2015;56(October (5)):787-91.