

Maciej Gnass¹, Joanna Sola², Anna Filarecka³, Stanisław Orzechowski³, Piotr Kocoń⁴,
 Monika Pasięka-Lis², Juliusz Pankowski², Lucyna Rudnicka⁵, Jerzy Soja⁶, Artur Szlubowski^{1,3}

¹Endoscopy Unit, John Paul II Hospital, Jagiellonian University, Cracow, Poland

²Department of Pathology, Hospital of Lung Diseases in Zakopane, Zakopane, Poland

³Department of Pulmonology, Hospital of Lung Diseases in Zakopane, Zakopane, Poland

⁴Department of Thoracic Surgery, John Paul II Hospital, Jagiellonian University, Cracow, Poland

⁵Department of Pathology, John Paul II Hospital, Jagiellonian University, Cracow, Poland

⁶Department of Medicine, Jagiellonian University, Cracow, Poland

Initial Polish experience of Flexible 19 gauge Endobronchial Ultrasound-Guided Transbronchial Needle Aspiration

The authors declare no financial disclosure

Abstract

Introduction: EBUS is a well established minimally invasive diagnostic tool for mediastinal and hilar lymphadenopathy. The novel ViziShot Flex 19G needle (Olympus Respiratory America, Redmond, WA, USA) was introduced in 2015 in order to improve loaded scope flexion and to obtain larger tissue samples for analysis.

The aims of this study were to assess diagnostic yield of Flex 19G needles and to present endoscopist's feedback about the endobronchial ultrasound-guided transbronchial needle aspiration (EBUS-TBNA).

Material and methods: The Flex 19G needles were used in patients with hilar and/or mediastinal adenopathy in two Polish pulmonology centers. Cytology smears and cell blocks (CB) were prepared. The prospective analysis was performed due to collected data.

Results: Twenty two selected patients with confirmed adenopathy on chest-CT (mean age 58 ± 12) underwent EBUS-TBNA with use of Flex 19G needles. All procedures occurred to be diagnostic for smears (yield 100%). The malignancy was found in 15 cases (68.2%), and benign adenopathy in 7 (31.8%). In 12 of 14 cases of lung cancer (yield 85.7%) CB were diagnostic for immunohistochemical and molecular staining. After puncturing nodes, especially in hilar position not extensive bleeding was observed. Comparing to standard 21/22G EBUS-TBNA endoscopists underlined better flexion of loaded scope and sample adequacy and found non-significant differences in another biopsy details.

Conclusions: The first Polish experience with use of Flex 19G EBUS-TBNA needle occurs to be similar in performance with standard technique with use of 22/21G needles and presents high diagnostic yield for lung cancer diagnostics, especially when preparing CB. A safety profile of the biopsy is acceptable.

Key words: EBUS-TBNA, flex 19G needle, lung cancer, sarcoidosis, lymphadenopathy

Adv. Respir. Med. 2017; 85: 64–68

Introduction

The role of the Endobronchial Ultrasound-Guided Transbronchial Needle Aspiration (EBUS-TBNA) combined with Endoscopic Ultrasonography-Guided Fine Needle Aspiration using

EBUS scope (EUS-B-FNA) or EUS scope is a well established and recommended method as the first step towards minimally invasive lung cancer staging [1]. EBUS-TBNA is also successfully performed for diagnostic purposes in patients with paratracheal and peribronchial tumours [2, 3].

Address for correspondence: Maciej Gnass, Endoscopy Unit, John Paul II Hospital, ul. Prądnicza 80, 31–202 Cracow, Polska, tel. +48 12 614 23 09; fax: +48 12 614 22 15, e-mail: m.gnass@gmail.com

DOI: 10.5603/ARM.2017.0012

Received: 26.10.2016

Copyright © 2017 PTChP

ISSN 2451–4934

There is quite a lot of data presenting the usefulness of the EBUS-TBNA for diagnosing patients with benign mediastinal and/or hilar lymphadenopathy, especially those suspected of sarcoidosis [4]. The area visualised with the EBUS scope includes the upper and lower para- and retrotracheal, subcarinal and hilar regions. Whereas the only limitation of the ultrasonographic visualisation is the outer diameter of the scope, in some cases its flexibility decreased by introducing TBNA needle into the working channel reduces the bioptic area.

The novel first generation of Flex 19G needle (Olympus Respiratory America, Redmond, WA, USA) for the EBUS-TBNA use was developed and brought to market in 2015. The main advantages of the needle claimed by the manufacturer are as follows: improved flexibility (from 45° maximal flex for scope loaded with standard 21G needle to 84° while using Flex 19G needle) (Fig. 1), enlarged inner lumen with the same outer diameter (1.9 mm) for obtaining bigger tissue samples and improved echogenicity of the needle for better visualisation on ultrasound image.

In the current paper we presented our initial experience of the first generation of Flex 19G EBUS-TBNA needle. The aim of our work was to assess diagnostic yield and to report complications associated while using the tool and to present subjective endoscopist's feedback after its use.

Material and methods

The Flex 19G needle was used for EBUS-TBNA in 22 selected patients with enlarged hilar or mediastinal lymph nodes on CT scans for staging and diagnosis of lung cancer and for other benign lymphadenopathies. The procedure was performed by three experienced endoscopists in two Polish pulmonology centers. The Olympus EBUS scope (BF-UC180F) with 2.2 mm working channel diameter was used. After signing informed consent, all patients underwent EBUS under mild conscious sedation with the use of midazolam (2–5 mg) and fentanyl (0.025–0.1 mg) administered intravenously. Pulsoxymetric measurement for patients' monitoring was mandatory, and oxygen supplementation provided when necessary.

EBUS-TBNA was performed with 2 to 3 needle passes in at least 2 selected areas. For cytological assessment smears and cell blocks (CB), when malignancy was suspected were prepared. After the procedure, both sampled areas (nodal stations or tumour) and endoscopist's feedback

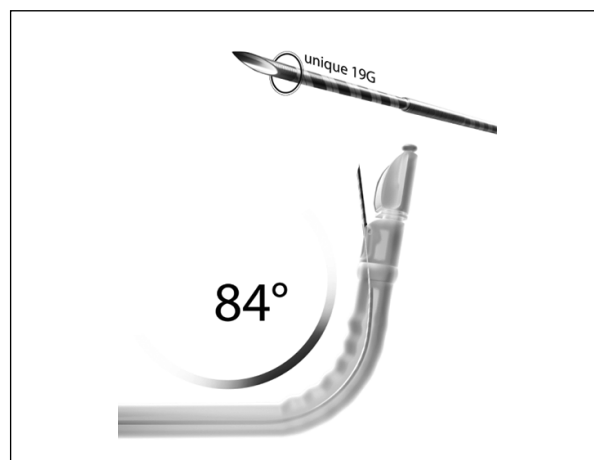


Figure 1. ViziShot 19G Flex needle (Olympus Respiratory America, Redmond, WA, USA)

were noted. Lymph node stations were examined in accordance to the lymph node map introduced by the International Association for the Study of Lung Cancer (IASLC) [5]. Endoscopists were asked to fill the questionnaire after finishing the procedure. Absolute and relative (comparing with standard 21/22G EBUS-TBNA) performance was assessed using the questionnaire. Endoscopists also answered questions about possible disadvantages of the new needle as shown in Table 1. Physician's feedback was referred to flexibility of the loaded scope, facility of puncture of the targeted area, quality of the needle visualisation in the ultrasound image and the quality and amount of the obtained tissue for preparing smears.

Biopsies were assessed by experienced pathologists in both hospitals for being diagnostic, and if so, for final diagnosis. In case of non-diagnostic biopsy, other invasive procedures such as mediastinoscopy or systematic lymph node dissection during lung resection were planned to establish final diagnosis.

Results

Endoscopic procedures were performed in October and November 2015 in Endoscopy Units of Pulmonary Hospital in Zakopane (16 patients) and John Paul II Hospital in Cracow (6 patients). Twenty two selected patients with mediastinal and/or hilar lymphadenopathy underwent EBUS-TBNA with Flex 19G needle. The examined group consisted of 15 (68.2%) men and 7 (31.8%) women, aged between 32 and 80, mean 58 ± 12 years.

In 22 patients, 48 selected areas (nodal stations or tumours) were biopsied as shown in Table 2. The final diagnosis was established by EBUS-TB-

Table 1. Results of the questionnaire filled by bronchoscopists after each procedure

	Absolute performance		Relative performance		
	Unacceptable	Acceptable	Worse	Comparable	Better
Did the device penetrate the target?	1 (4.5%)	21 (95.5%)	–	19 (86.4%)	3 (13.6%)
Did the device collect adequate samples?	–	22 (100%)	–	2 (9.1%)	20 (90.9%)
Was the device visible during sampling?	–	22 (100%)	–	20 (90.9%)	2 (9.1%)
Overall impression of performance	–	22 (100%)	–	16 (72.7%)	6 (27.3%)
	Yes	No			
Did the needle become ‘bent’ or ‘curved’?	–	22			
Did the needle become excessively curved?	–	22			
Did the needle become noticeably dull?	–	22			
Did the needle ever snag and/or penetrate the sheath?	–	22			

Table 2. Baseline characteristics

Total (n)	22
Gender	
Male	15 (68.2%)
Female	7 (31.8%)
Age (years)	58 ± 12
Final diagnosis	
Sarcoidosis	4 (18.2%)
Reactive LN	3 (13.6%)
Lung cancer	14 (63.6%)
Adenocarcinoma	5 (22.7%)
Squamous cell carcinoma	4 (18.2%)
Small cell lung cancer	4 (18.2%)
Non-small cell lung cancer	1 (4.5%)
Clear cell adenocarcinoma	1 (4.5%)
Lymph nodes biopsied	48
4R	7
4L	6
7	15
10R	4
10L	2
11R	3
11L	4
Tumor	7

NA with the use of the Flex 19G needles in all cases. There were 7 benign lymphadenopathies (4 sarcoidosis and 3 reactive lymph nodes). Malignancy was found in 15 cases (14 primary lung cancers and 1 metastatic clear cell cancer of the

Table 3. Diagnostic yield of smears and cell blocks (CB)

Final diagnosis	Smears n = 22	CB n = 15
	22/22 (100%)	13/15 (86.7%)
Sarcoidosis	4/4 (100%)	–
Reactive LN	3/3 (100%)	–
Lung cancer	14/14 (100%)	12/14 (85.7%)
Clear cell adenocarcinoma	1/1 (100%)	1/1 (100%)

CB — cell blocks

kidney). If needed, tissue material obtained by needle biopsy was adequate for immunocytochemical (IHC) staining and molecular genotyping (EGFR mutation testing). Smears were prepared in all 22 patients and all of them were found to be diagnostic (yield 100%).

Cell blocks (CB) were prepared in 15 patients suspected of malignancy and were diagnostic in 13 of them (86.7%) (Table 3).

As shown in Table 1, absolute performance was acceptable regarding penetration of the target (95.5%), collecting adequate sample (100%), visibility of the needle in ultrasonography (100%) and overall impression of the procedure (100%). Relative performance was assessed as comparable in the area of target penetration (86.4%), needle visibility (90.9%) and overall impression of the procedure (72.7%); and was found to be better in obtaining adequate samples for preparing smears (90.9%). No device dependent complications were reported.

Improved flexibility of the loaded scope measured in our sites was about 21 degrees (from 57° while using standard 22G needle to 78° with new device) (Figs 2, 3).




Figure 2. EBUS scope loaded with 22G needle

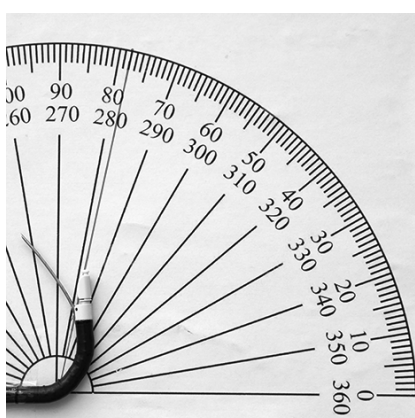


Figure 3. EBUS scope loaded with ViziShot 19G Flex needle

No severe complications were observed except for the subject who presented bleeding after biopsy of the right hilar nodes, controlled with cooled saline.

Discussion

In the first Polish experience, EBUS-TBNA with the use of the Flex 19G needles showed very high diagnostic yield for malignancy and sarcoidosis. But the small number of selected patients must be underlined regarding reported in the literature diagnostic yield of this procedure in lung cancer staging — 89%, and in mediastinal lymphadenopathy — 92% [6, 7].

The Canadian experience of the device also suggests high diagnostic yield in different lymphadenopathies [8].

The endoscopist's feedback shown in our work corresponds with the results presented by Sczaniecka *et al.* [9] at the European Respiratory Society Congress in London (September 2016).

The tissue sample obtained with the needle occurred to be adequate for cytological, IHC and

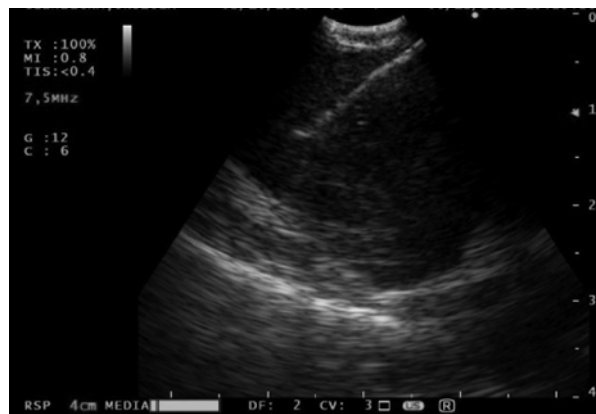

Figure 4. EBUS-TBNA with ViziShot 19G Flex (lymph node 4R)

molecular (EGFR) lung cancer typing, which is in accordance with the literature on the topic [10–12]. The quality of CB samples are highly promising especially for ALK, ROS1 and PD-L1 typing, when bigger samples are needed. A complication rate observed in our study was comparable with the standard EBUS-TBNA [1, 2, 6–8].

Conclusions

In our experience, Flex 19G EBUS-TBNA needle occurs to be similar in performance to standard technique using 22/21G needles, and presents high diagnostic yield for lung cancer diagnostics, especially for preparing CB. A significantly better flexion of the loaded scope allows the access for the bigger bioptic area, hence better sample adequacy can be achieved. A safety profile of the biopsy is acceptable.

Conflict of interest

The authors declare no conflict of interest.

References:

1. Vilmann P, Clementsen PF, Colella S, et al. Combined endobronchial and esophageal endosonography for the diagnosis and staging of lung cancer: European Society of Gastrointestinal Endoscopy (ESGE) Guideline, in cooperation with the European Respiratory Society (ERS) and the European Society of Thoracic Surgeons (ESTS). *Endoscopy*. 2015; 47(6): 545–559, doi: [10.1055/s-0034-1392040](https://doi.org/10.1055/s-0034-1392040), indexed in Pubmed: [26030890](https://pubmed.ncbi.nlm.nih.gov/26030890/).
2. Kheir F, Itani A, Assasa O, et al. The utility of endobronchial ultrasound-transbronchial needle aspiration in lymphoma. *Endosc Ultrasound*. 2016; 5(1): 43–48, doi: [10.4103/2303-9027.175884](https://doi.org/10.4103/2303-9027.175884), indexed in Pubmed: [26879166](https://pubmed.ncbi.nlm.nih.gov/26879166/).
3. Ortakoylu MG, Iliaz S, Bahadır A, et al. Diagnostic value of endobronchial ultrasound-guided transbronchial needle aspiration in various lung diseases. *J Bras Pneumol*. 2015; 41(5): 410–414, doi: [10.1590/S1806-37132015000004493](https://doi.org/10.1590/S1806-37132015000004493), indexed in Pubmed: [26578131](https://pubmed.ncbi.nlm.nih.gov/26578131/).
4. von Bartheld MB, Dekkers OM, Szlubowski A, et al. Endosonography vs conventional bronchoscopy for the diagnosis of sar-

- coidosis: the GRANULOMA randomized clinical trial. *JAMA*. 2013; 309(23): 2457–2464, doi: [10.1001/jama.2013.5823](https://doi.org/10.1001/jama.2013.5823), indexed in Pubmed: [23780458](https://pubmed.ncbi.nlm.nih.gov/23780458/).
5. Rusch VW, Asamura H, Watanabe H, et al. Members of IASLC Staging Committee. The IASLC lung cancer staging project: a proposal for a new international lymph node map in the forthcoming seventh edition of the TNM classification for lung cancer. *J Thorac Oncol*. 2009; 4(5): 568–577, doi: [10.1097/JTO.0b013e3181a0d82e](https://doi.org/10.1097/JTO.0b013e3181a0d82e), indexed in Pubmed: [19357537](https://pubmed.ncbi.nlm.nih.gov/19357537/).
 6. Silvestri GA, Gonzalez AV, Jantz MA, et al. Methods for staging non-small cell lung cancer: Diagnosis and management of lung cancer, 3rd ed: American College of Chest Physicians evidence-based clinical practice guidelines. *Chest*. 2013; 143(5 Suppl): e211S–e250S, doi: [10.1378/chest.12-2355](https://doi.org/10.1378/chest.12-2355), indexed in Pubmed: [23649440](https://pubmed.ncbi.nlm.nih.gov/23649440/).
 7. Dietrich CF, Annema JT, Clementsen P, et al. Ultrasound techniques in the evaluation of the mediastinum, part I: endoscopic ultrasound (EUS), endobronchial ultrasound (EBUS) and transcutaneous mediastinal ultrasound (TMUS), introduction into ultrasound techniques. *J Thorac Dis*. 2015; 7(9): E311–E325, doi: [10.3978/j.issn.2072-1439.2015.09.40](https://doi.org/10.3978/j.issn.2072-1439.2015.09.40), indexed in Pubmed: [26543620](https://pubmed.ncbi.nlm.nih.gov/26543620/).
 8. Tyan C, Patel P, Czarniecka K, et al. Flexible 19 Gauge Endobronchial Ultrasound-Guided Transbronchial Needle Aspiration Needle – First Canadian Experience. *Am J Respir Crit Care Med*. 2015; 19: A6389.
 9. Sczaniecka A, Gonzalez X, Zuccatosta L, et al. A novel flexible 19G EBUS-TBNA needle: Absolute and relative performance in patients. *European Respiratory Journal*. 2016; 48(suppl 60): PA2036, doi: [10.1183/13993003.congress-2016.pa2036](https://doi.org/10.1183/13993003.congress-2016.pa2036).
 10. Jeyabalan A, Bhatt N, Plummeridge MJ, et al. Adequacy of endobronchial ultrasound-guided transbronchial needle aspiration samples processed as histopathological samples for genetic mutation analysis in lung adenocarcinoma. *Mol Clin Oncol*. 2016; 4(1): 119–125, doi: [10.3892/mco.2015.672](https://doi.org/10.3892/mco.2015.672), indexed in Pubmed: [26870369](https://pubmed.ncbi.nlm.nih.gov/26870369/).
 11. Powrózek T, Krawczyk P, Pankowski J, et al. The efficacy of EGFR gene mutation testing in various samples from non-small cell lung cancer patients: a multicenter retrospective study. *J Cancer Res Clin Oncol*. 2015; 141(1): 61–68, doi: [10.1007/s00432-014-1789-x](https://doi.org/10.1007/s00432-014-1789-x), indexed in Pubmed: [25086987](https://pubmed.ncbi.nlm.nih.gov/25086987/).
 12. van der Heijden EH, Casal RF, Trisolini R, et al. World Association for Bronchology and Interventional Pulmonology, Task Force on Specimen Guidelines. Guideline for the acquisition and preparation of conventional and endobronchial ultrasound-guided transbronchial needle aspiration specimens for the diagnosis and molecular testing of patients with known or suspected lung cancer. *Respiration*. 2014; 88(6): 500–517, doi: [10.1159/000368857](https://doi.org/10.1159/000368857), indexed in Pubmed: [25377908](https://pubmed.ncbi.nlm.nih.gov/25377908/).