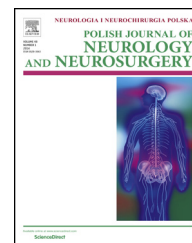

Available online at [www.sciencedirect.com](http://www.sciencedirect.com)

ScienceDirect

journal homepage: <http://www.elsevier.com/locate/pjnns>

## Case report

# Endovascular management of carotid artery dissections with the use of new generation stents and protection systems

Paweł Latacz<sup>a,\*</sup>, Marian Simka<sup>b</sup>, Tadeusz Popiela<sup>c</sup>, Paweł Brzegowy<sup>c</sup>, Marek Moskała<sup>d</sup>

<sup>a</sup>Department of Vascular Surgery, University Hospital, Krakow, Poland

<sup>b</sup>Department of Nursing, College of Applied Sciences, Ruda Śląska, Poland

<sup>c</sup>Chair of Radiology, Jagiellonian University Collegium Medicum, Krakow, Poland

<sup>d</sup>Department of Neurosurgery and Neurotraumatology, University Hospital, Krakow, Poland

## ARTICLE INFO

## Article history:

Received 12 February 2016

Received in revised form

23 June 2016

Accepted 19 July 2016

Available online 27 July 2016

## Keywords:

Dissection

Carotid Artery

Angioplasty

## ABSTRACT

Dissection of the internal carotid artery (ICA) is a rare disease, but in young patients is responsible for about 20% of cerebral events. We presented three different cases of ICA dissection, including one iatrogenic and two spontaneous ones, which were successfully managed endovascularly, with the use of different techniques, different protection devices and stents. In this article, the clinical management and details of procedures were described.

© 2016 Polish Neurological Society. Published by Elsevier Sp. z o.o. All rights reserved.

Dissection of the internal carotid artery (ICA) is a rare disease, but in young patients is responsible for about 20% of cerebral events [1]. Whatever the cause, it represents a big therapeutic challenge, especially if the dissection is located intracranially, in the petrous or more distal segments of the artery. In this paper we present three different cases of ICA dissection, including one iatrogenic and two spontaneous ones. Iatrogenic dissection involved most of the ICA, from its proximal part (C1) up to the ophthalmic segment (C6). One spontaneous dissection was associated with an aneurysm of the ICA and affected the ICA from the petrous (C2) to the ophthalmic segment (C6), while the other dissection extended from proximal part of the artery up to its lacerum segment (C3). The later resulted in

cerebral stroke, despite adequate anticoagulation. All these three patients were successfully managed endovascularly, with the use of different techniques, different protection devices and stents, which were chosen respecting anatomical challenges associated with each particular case.

## 1. Case presentations

### 1.1. Patient 1

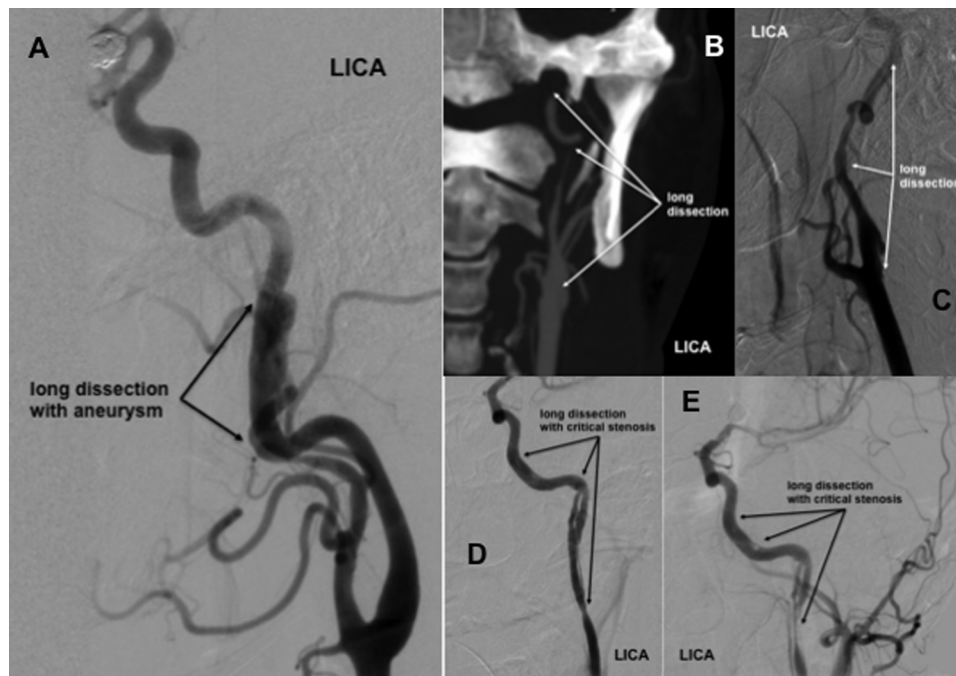
A 54-year-old male patient with a history of embolization of symptomatic aneurysm of the middle cerebral artery (MCA).

\* Corresponding author at: Department of Vascular Surgery, University Hospital, Krakow, ul. Botaniczna 3, Krakow, Poland. Tel.: +48 12 4248642.

E-mail address: [pawlat@me.com](mailto:pawlat@me.com) (P. Latacz).

<http://dx.doi.org/10.1016/j.pjnns.2016.07.006>

0028-3843/© 2016 Polish Neurological Society. Published by Elsevier Sp. z o.o. All rights reserved.



**Fig. 1 – Angiographies before endovascular repair: (A) catheter angiography in patient 1. (B) CT angiography in patient 2; (C) catheter angiography in patient 1, a long dissection of the left internal carotid artery with aneurysmatic dilatation; (D and E) catheter angiography in patient 3, a long dissection of the left internal carotid artery with false canal and critical stenosis; LICA—the left internal carotid artery.**

During embolization of this aneurysm there has also been revealed a dissection of the left ICA. This dissection was unlikely to be of iatrogenic character, since it was revealed by catheter angiography, prior to any intervention (Fig. 1A). Taking into account a high risk of cerebral embolism caused by dissected artery and contraindications for anticoagulant therapy, we decided to perform endovascular treatment of the dissection with the use of a self-expanding covered stent.

### 1.2. Patient 2

A 47-year-old male patient, a blue-collar worker with symptomatic idiopathic dissection of the left ICA, which probably was caused by an intense physical exertion. The dissection originated from proximal part of the ICA and extended to the lacerum segment (C3) of the artery (Fig. 1B and C). Initially the patient was managed conservatively with oral anticoagulants, but after 2 months of such a treatment, despite adequate anticoagulation, he developed cerebral stroke of the left hemisphere. Therefore, we decided to address the dissection endovascularly and perform the angioplasty with implantation of a stent into the dissected artery and to use a proximal protection system.

### 1.3. Patient 3

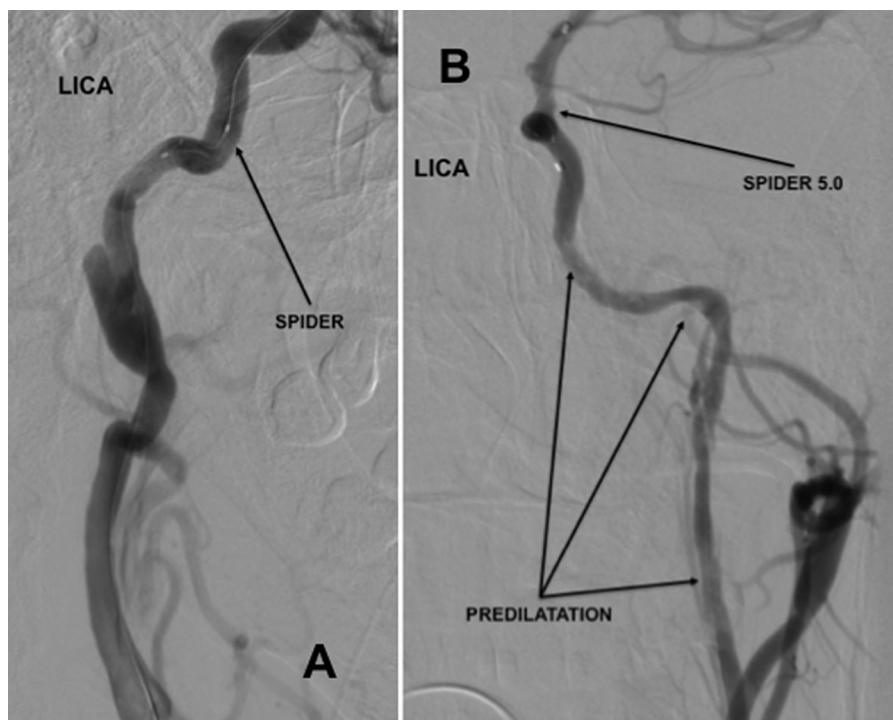
A 25-year-old female patient with a history of subarachnoid hemorrhage, which occurred in February 2015 and was caused by an aneurysm of the MCA. She has been managed with endovascular embolization of this aneurysm. At follow-up

digital angiography revealed a properly embolized aneurysm, but there was a new aneurysmal dilatation of the MCA, which was located proximally from the previous one, and also a long dissection of the left ICA, which extended from its proximal part up to its clinoid segment (C5). In addition, there was a critical stenosis in the middle part of dissection and a long false channel (Fig. 1D and E). The dissection was probably of iatrogenic character and resulted from previous endovascular intervention. After consultation by vascular team, taking into account contraindications for long-term anticoagulation (a history of subarachnoid hemorrhage and the presence of intracranial aneurysm), we decided to address the dissection endovascularly and to cover the distal part of dissected artery with a new generation self-expanding carotid stent. We implanted the RoadSaver™ stent (Terumo, Tokyo, Japan), which is a double layer mesh self-expanding device. We have chosen this stent because of its high flexibility (the lesion involved distal part of the ICA) and also because it can be used as a flow-diverter stent.

## 2. Interventions

### 2.1. Patient 1

Considering tortuous course of the artery at the site of dissection, we decided to use a self-expanding covered stent and a distal protection system. Firstly, over the hydrophilic AqWire™ guidewire (Covidien, ev3 Endovascular, Inc., Plymouth, MN, USA) we cannulated the left external carotid



**Fig. 2 – Catheter angiography performed after positioning of the SpiderFX™ distal protection system. (A) patient 1; (B) patient 3. LICA—the left internal carotid artery.**

artery (ECA) with a 5F vertebral diagnostic catheter. Then we replaced the AqWire™ guidewire with the Hi-Torque Supra Core one (Abbott Vascular, Abbott Park, IL, USA) and introduced the 8F 90-cm-long Destination® Guiding Sheath (Terumo, Tokyo, Japan) into the left common carotid artery. Through this guiding sheath, under fluoroscopic control, we advanced the 0.014" 300-cm-long V-14™ ControlWire™ guidewire Wallstent™ (Boston Scientific, Natick, MA, USA) into the MCA. Then, over another 0.014" guidewire, we introduced the 320-cm-long SpiderFX™ Embolic Protection Device (Covidien, ev3 Endovascular, Inc., Plymouth, MN, USA) with 6.0 mm filter into the distal part of the left ICA (Fig. 2A). Finally, utilizing both 0.014" guidewires, we implanted the 6 × 50 mm Viabahn® Endoprosthesis covered stent (Gore & Associates, Flagstaff, AZ, USA). Since there was no residual stenosis after the implantation (Fig. 4B) we did not perform postdilatation, considering the risk of migration of the stent after such a maneuver. CT angiography, which was done at follow-up 5 months after endovascular procedure, revealed normal flow, patent stent, no residual stenosis and no signs of a dissection (Fig. 5B).

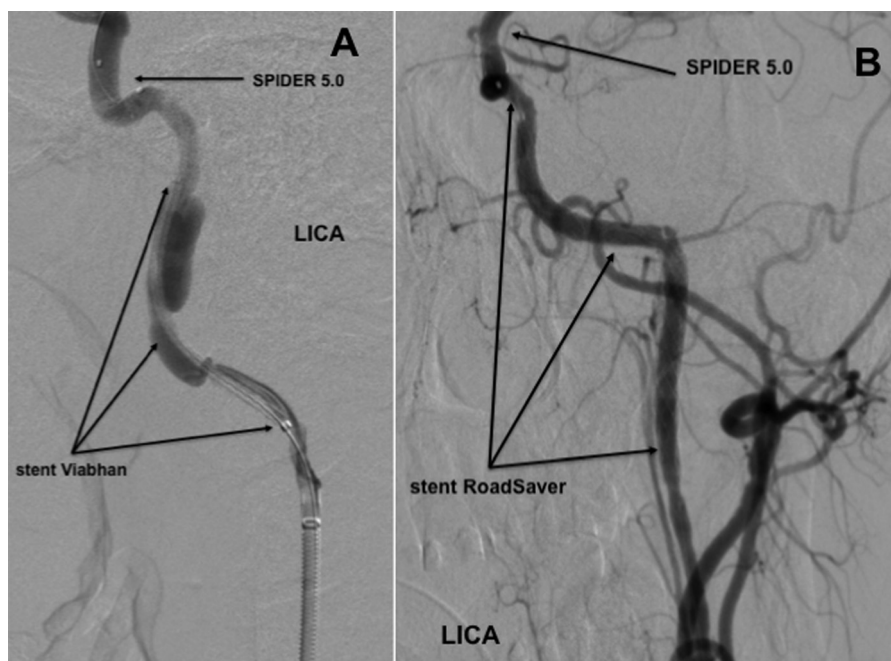
## 2.2. Patient 2

In this patient we decided to manage a long dissection of the artery with two self-expanding stents and to use a proximal protection system. Similarly to the previous case, we introduced the hydrophilic AqWire™ guidewire (Covidien, ev3 Endovascular, Inc., Plymouth, MN, USA) into the left ECA, over this guidewire we introduced a 4F vertebral diagnostic catheter and replaced the AqWire™ with the Hi-Torque Supra Core

guidewire. Over this guidewire we introduced the 8F Mo.Ma Ultra proximal cerebral protection device (Medtronic, Minneapolis, MN, USA). We inflated both balloons of the Mo.Ma system and under fluoroscopic control introduced the 0.014" guidewire into the MCA. Using this guidewire we implanted the 5 mm × 40 mm Precise® self-expanding stent (Cordis, Fremont, CA, USA), which covered distal part of the dissection and the other 8 mm × 40 mm Precise® stent, which slightly overlapped the distally placed stent and covered the proximal part of the dissected artery. We aspirated quite a lot of thrombotic debris from the Mo.Ma system. Since control catheter angiography revealed the protrusions of thrombotic lesions through the stent struts, we performed balloon angioplasty at these locations, still with no major success. Therefore, we implanted the third stent: 7 × 30 mm Carotid Wallstent™ (Boston Scientific, Natick, MA, USA) into the proximal part of the ICA, which—after postdilatation with angioplastic balloon using the pressure of 6 atm—resulted in a final good flow, with no residual stenosis and no signs of dissection or a plaque protrusion (Fig. 4B). CT-angiography assessment performed after follow-up 6 months (Fig. 5B) after endovascular treatment confirmed good hemodynamic effect and patency of the implanted stents.

## 2.3. Patient 3

In this patient we decided to manage the distal part of dissection using a new generation of self-expanding stent and the proximal part with a standard self-expanding stent. We also decided to use a distal protection system. As in the previous cases, we cannulated the left ECA with a 4F vertebral



**Fig. 3 – (A) Catheter angiography performed before implantation of the Viabahn® Endoprosthesis covered stent. (B) Catheter angiography performed after implantation of the RoadSaver™ stent; LICA—the left internal carotid artery.**

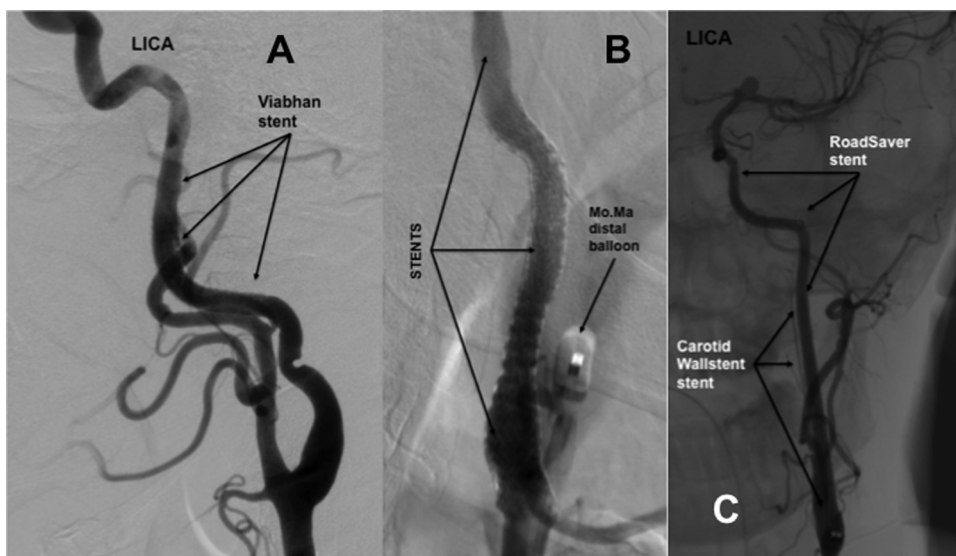
diagnostic catheter, which was introduced over the hydrophilic AqWire™ guidewire. Then we replaced the AqWire™ with the Hi-Torque Supra Core one and over this guidewire we introduced the 5F 90-cm-long Destination® Guiding Sheath. Through this guiding sheath, under fluoroscopic control, we advanced the 0.014 in. V-14™ ControlWire™ guidewire into the MCA. Plan of the treatment included the use of a distal protection system. Yet, because of the stenosis in the middle part of the ICA, an introduction of the SpiderFX™ Embolic Protection Device was not successful. Therefore, we performed angioplasty of the narrowed segment with a 2 mm × 20 mm angioplastic balloon, using the pressure of 10 atm. Thereafter, we successfully navigated through stenosed segment and positioned the SpiderFX™ Embolic Protection Device in the distal part of the ICA (Fig. 2B). Then, we performed another angioplasty with a 3 mm × 20 mm angioplastic balloon, which was inflated under the pressure of 10 atm. With the ICA sufficiently dilatated, we implanted the 5 × 40 mm Road-Saver™ stent (Terumo, Tokyo, Japan) in order to cover the distal part of dissection (Fig. 3B) and a second stent: the 7 mm × 40 mm Carotid Wallstent™ (Boston Scientific, Natick, MA, USA), which slightly overlapped the distally placed one and covered the proximal part of dissected artery. Then, we performed several postdilations with the use of 4 mm × 20 mm and 5 mm × 20 mm angioplastic balloons, which were inflated up to the pressure of 10-14 atm, with a final satisfactory result and a 40% residual stenosis in the middle part of the ICA (Fig. 4C). Removed embolic protection device contained a lot of thrombotic debris. Follow-up angiography, which was performed 5 months later during endovascular procedure aimed at embolization of aneurysm of the MCA, demonstrated good hemodynamic effect, no signs of dissection and patency of the implanted stents (Fig. 5C).

### 3. Discussion

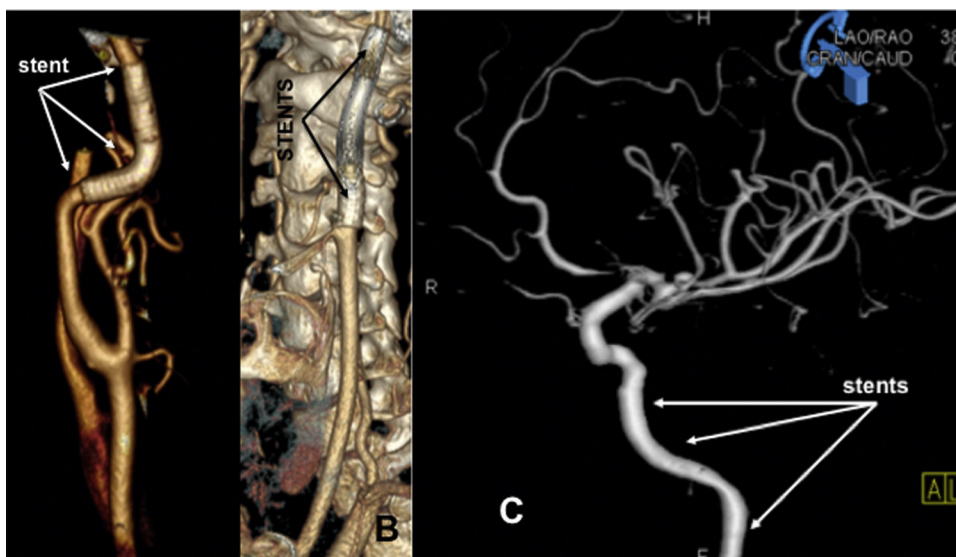
Annual incidence rate of ICA dissection is at the level of 2.6 per 100,000 and in young patients may be responsible for about 20% of strokes [1,2]. Majority of strokes related to carotid artery dissection are of embolic origin and only a small minority develop due to haemodynamic failure [3,4]. In many patients, the dissection progresses or an aneurysmatic dilatation of the artery develops, which, despite adequate anticoagulation, carries an increased risk of late embolization [5,6]. Treatment options for ICA dissection comprise open surgical repair and endovascular approach. The later is currently preferred [7].

In our opinion, endovascular treatment for ICA dissection should primarily be used in patients who develop progression of dissection or present with a high risk of haemorrhagic complications related to anticoagulation. Also patients with dissection associated with stenosis of the ICA, especially young individuals with a risk of complete occlusion of the artery, should be managed with this method when dissection is not available for open surgical repair. Perhaps, endovascular treatment with the use of new generation stents will appear to be safer and more effective than conservative management, still it should be demonstrated by prospective studies.

Although embolism remains the most frequently reported complication associated with the treatment for ICA dissection, Cohen *et al.* who managed endovascularly 23 patients with ICA dissections and used distal protection devices only in 3 (13%) of them, did not report thromboembolic event associated with the procedures [8]. Similarly Malek *et al.* did not use protection devices and did not observe embolic events [7]. Still, these were relatively small trials. The results of large-scale registries on endovascular carotid interventions demonstrated that risk of



**Fig. 4** – Final results of the procedures. (A) the dissection covered with the Viabahn® Endoprosthesis covered stent (patient 1); (B) the dissection covered with three stents: two Precise® stents and one Carotid Wallstent™ stent (patient 2), there is visible inflated distal balloon of the Mo.Ma proximal protection system; (C) the dissection covered with two stents: the RoadSaver™ and the Carotid Wallstent™ (patient 3); LICA—the left internal carotid artery.



**Fig. 5** – Angiographies performed at follow-up visits. (A) CT angiographies performed 5 months after the procedure in patient 1; (B) CT angiographies performed 6 months after the procedure in patient 2; (C) angiography performed 5 months after the procedure in patient 3.

cerebral embolization is quite unpredictable and therefore the use of a protection system is warranted [9,10]. Consequently, we applied protection systems in all 3 patients treated, and it seems that our approach was correct. In both patients who were managed with distal protection devices the filters contained quite a lot of embolic debris and similarly in patients treated with a proximal protection system we aspirated huge amount of thromboembolic material. In addition, in one patient, due to protrusion of the plaques through stent struts, it was necessary to implant an additional stent. Therefore, it seems that ICA dissection carries a high risk of cerebral embolization and a strategy aimed at minimizing this risk is important.

The choice of a proper stent represents another therapeutic challenge. In each of the presented cases we utilised different stents. In the patient who presented with dissection and coexisting aneurysm we applied a self-expanding covered stent (Viabahn® Endoprosthesis). We did not decide to use in this case a flow-diverter stent, considering the risk of migration of such a stent into the aneurysm sac [11]. On the other hand, we chose such a stent in the patient with long iatrogenic dissection of the ICA, benefiting from a high flexibility and a unique design of the RoadSaver™ stent. The patient with protrusions of atherosclerotic plaques required an implantation of a closed cell stent (Carotid Wallstent™) for optimal lesion coverage and

the same type of stent was needed to address a difficult-to-manage stenosis and at the level of dissection. We believe that all these decisions were correct, since none of the patients developed perioperative complications, the dissections were fully covered by the stents and follow-ups at 3-9 months revealed normal flow without recurrence of the disease. It should be mentioned that in meta-analysis of 46 patients with carotid artery dissections, who were managed with stent implantations, 11% of them developed periprocedural complications, 8% restenosis at follow-up and 6% secondary pseudoaneurysms [12].

---

### Conflict of interest

None declared.

---

### Acknowledgement and financial support

None declared.

---

### Ethics

The work described in this article has been carried out in accordance with The Code of Ethics of the World Medical Association (Declaration of Helsinki) for experiments involving humans; Uniform Requirements for manuscripts submitted to Biomedical journals.

---

### REFERENCES

- [1] Schievink WI, Mokri B, Whisnant JP. Internal carotid artery dissection in a community. *Stroke* 1993;24:1678-80.
- [2] Bougousslavsky J, Regli F. Ischemic stroke in adults younger than 30 years of age. Cause and prognosis. *Arch Neurol* 1987;44:479-82.
- [3] Lucas C, Moulin T, Deplanque D, Tatu L, Chavot D. Stroke patterns of internal carotid artery dissection in 40 patients. *Stroke* 1998;29:2646-8.
- [4] Sturzenegger M. Spontaneous internal carotid artery dissection: early diagnosis and management in 44 patients. *J Neurol* 1995;242:231-8.
- [5] Mokri B, Sundt Jr TM, Houser OW, Piepgras DG. Spontaneous dissection of the cervical internal carotid artery. *Ann Neurol* 1986;19:126-38.
- [6] Martin PJ, Humphrey PR. Disabling stroke arising five months after internal carotid artery dissection [Letter]. *J Neurol Neurosurg Psychiatry* 1998;65:136-7.
- [7] Malek AM, Higashida RT, Phatouros CC, Lempert TE, Meyers PM, Smith WS, et al. Endovascular management of extracranial carotid artery dissection achieved using stent angioplasty. *AJNR Am J Neuroradiol* 2000;21:1280-92.
- [8] Cohen JE, Gomori JM, Itshayek E, Spektor S, Shoshan Y, Rosenthal G, et al. Single-center experience on endovascular reconstruction of traumatic internal carotid artery dissections. *J Trauma Acute Care Surg* 2012;72:216-21.
- [9] Cremonesi A, Gieowarsingh S, Spagnolo B, Manetti R, Liso A, Furgieri A, et al. Safety, efficacy and long-term durability of endovascular therapy for carotid artery disease: the tailored-Carotid Artery Stenting Experience of a single high-volume centre (tailored-CASE Registry). *EuroIntervention* 2009;5:589-98.
- [10] Reimers B, Schluter M, Castriota F, Tubler T, Corvaja N, Manetti R, et al. Routine use of cerebral protection during carotid artery stenting: results of a multicenter registry of 753 patients. *Am J Med* 2004;116:217-22.
- [11] Vega RA, Brzezicki G, Reavey-Cantwell JF. Delayed collapse of a pipeline embolization device. *Neurosurgery* 2016;12:83-8.
- [12] Hassan AE, Zacharatos H, Souslian F, Suri MF, Qureshi AI. Long-term clinical and angiographic outcomes in patients with cervico-cranial dissections treated with stent placement: a meta-analysis of case series. *J Neurotrauma* 2012;29:1342-53.