

DOI: 10.12740/APP/63511

Brain biopsy in the diagnosis of Creutzfeldt-Jakob disease with a history of prodromal psychiatric symptoms and catatonic behavior

Adrian Andrzej Chrobak, Alicja Dudek, Marcin Wnuk, Zofia Łysiak, Marcin Siwek, Dariusz Adamek, Agata Świerkosz, Dominika Dudek

Summary

Creutzfeldt-Jakob disease (CJD) is a neurodegenerative disorder belonging to the group of transmissible spongiform encephalopathies. The transition of physiological, soluble, neuroprotective prion protein PrP^c into its insoluble, misfolded isoform PrP^{Sc} remains its central pathogenic event. The progressive accumulation of isoform PrP^{Sc} within the brain tissue results in spongiform degeneration and a plethora of clinical symptoms. Typically, CJD manifests as progressive dementia with myoclonus, visual or cerebellar dysfunction, pyramidal/extrapyramidal signs or akinetic mutism. However, a growing number of studies indicate that CJD may present with prodromal psychiatric manifestations including anhedonia, anxiety, irritability, depression, insomnia, psychosis and catatonic behavior. We present a case of CJD with a history of prodromal psychiatric symptoms and catatonic behavior diagnosed by brain biopsy.

Creutzfeldt-Jakob disease/brain biopsy/psychiatric symptoms

INTRODUCTION

Creutzfeldt-Jakob disease (CJD) is a neurodegenerative disorder belonging to the group of transmissible spongiform encephalopathies. The transition of physiological, soluble, neuroprotective prion protein PrP^c into its insoluble, misfolded isoform PrP^{Sc} remains the central pathogenic event in this disorder [1]. PrP^{Sc} cre-

ates toxic deposits resilient to cellular clearance mechanisms [2]. Their progressive accumulation within the brain tissue results in spongiform degeneration and a plethora of clinical symptoms. Typically, CJD manifests as progressive dementia with myoclonus, visual or cerebellar dysfunction, pyramidal/extrapyramidal signs or akinetic mutism. However, a growing number of studies indicate that CJD may present with prodromal psychiatric manifestations including anhedonia, anxiety, irritability, depression, insomnia, psychosis and behavioral changes [3]. Brown et al. [4] showed that behavioral changes occurred in 30% of patients at the disease onset and in 57% at the later stages. In another study, 5 out of 8 CJD patients showed psychiatric manifestation including mood, thought and behavior disruption; 4 out of 8 of these patients were diag-

Adrian Andrzej Chrobak¹, Alicja Dudek¹, Marcin Wnuk², Zofia Łysiak², Marcin Siwek³, Dariusz Adamek⁴, Agata Świerkosz³, Dominika Dudek³: ¹Faculty of Medicine, Jagiellonian University Medical College, Kraków, Poland; ²Department of Neurology, Jagiellonian University Medical College, Kraków, Poland; ³Department of Affective Disorders, Chair of Psychiatry, Jagiellonian University Medical College, Kraków, Poland; ⁴Department of Neuropathology, Chair of Pathomorphology, Jagiellonian University Medical College, Kraków, Poland.

nosed with different psychiatric disorders [5]. Mood disorder symptoms, paranoid ideation and hallucinations were present in 7 out of 11 CJD cases described in the study by Satishchandra et al. [6]. A retrospective study indicated that 18–39% of patients with sporadic CJD presented with psychiatric symptoms such as depressive disorder, emotional lability or personality changes [7]. CJD cases from Brazil presented by Sobreira et al. [8] showed heterogeneous psychiatric manifestations including sudden psychomotor agitation, aggression, disinhibition and cognitive dysfunctions. Moreover, it was reported that early stages of the disease may manifest as dissociative disorder with histrionic behavior and dissimulation [9]. Siwek et al. [10] presented a case of a 34-year-old female with CJD, primarily diagnosed with conversion disorder, who manifested with blurred vision, diplopia and gait impairment. All of these reported cases indicate that CJD may manifest with a plethora of uncharacteristic, atypical psychiatric symptoms and it is likely that psychiatrists may be the first-line doctors dealing with a CJD patient at the early stages of the disease [11].

Catatonia is a neuropsychiatric syndrome characterized by mutism, stupor, negativism and hypo/hyperkinesia. While it is mostly associated with schizophrenia, catatonia is often caused by affective disorders and neurological illnesses [12]. We present a case of CJD diagnosed by brain biopsy in a patient with a history of prodromal psychiatric symptoms and catatonic behavior.

CASE

A 49-year-old woman was admitted to a psychiatric hospital for the first time 9 months before the proper diagnosis was established, due to her bizarre behavior, deterioration of social interactions, reduced food intake, hallucinations, psychomotor retardation with periodic episodes of agitation, passive negativism and sleep disorders. All symptoms, lasting for a period of 4 weeks, indicated an acute psychotic disorder and the patient was discharged on olanzapine 5mg daily and biperiden 2mg daily. After the discharge, the patient's family observed a deterioration in her health; she ceased to be

independent and required assistance with basic activities. There was also a significant deterioration in her vision. Due to lowered mood and psychomotor retardation, the patient was admitted to the psychiatric hospital for the second time. Her symptoms remained stable except for increasing muscle rigidity. An electroencephalogram (EEG) test showed pathological tracing with diffused and generalized paroxysmal theta activity. She was discharged with the diagnosis of drug-induced Parkinsonism and treated with biperiden 2mg three times a day without concomitant antipsychotic medication. A month later, the patient was again admitted to the psychiatric hospital because of aggressive and agitated behavior. A hostile attitude towards the hospital staff was also marked. The patient's condition gradually deteriorated further, with mutism, increased hypertonia and negativism. The clinical picture tended towards a suspicion of the catatonic syndrome. Olanzapine 10mg daily was administered. However, after several days the patient's body temperature went up to 39°C and olanzapine was discontinued. As infection was suspected, she was started on intravenous ceftriaxone. However, subsequent internal medicine consultation with blood and urine culture and cerebrospinal fluid (CSF) examination as well as head computed tomography (CT) excluded the suspected source of infection (including neuroinfection), leading to a suspicion of neuroleptic malignant syndrome.

Finally, due to unclear clinical presentation, the patient was admitted to the Clinical Department of Adult Psychiatry at the University Hospital in Kraków in a state of consciousness requiring differentiation between stupor and vegetative state. The physical examination revealed eyes opening spontaneously and no verbal contact, but the patient responded with a grimace to painful stimulation. No spontaneous movements, hypertonia and muscle atrophy of the upper and lower limbs were present. Because of dysphagia, the patient was supported with a feeding tube.

A consecutive neurological examination identified spastic quadriplegia and jaw muscles spasm. The palmomental reflex was present on the left side. The clinical picture of progressive encephalopathy of unknown etiology suggested further diagnostic evaluation towards CJD. Head magnetic

resonance imaging (MRI) revealed diffuse linear cortical enhancement at diffusion-weighted imaging sequence. The neuroimaging result prompted the team to consider a CJD diagnosis despite lack of typical changes in the basal ganglia.

The patient, conscious with no verbal contact, was then admitted to the Neurology Department at the University Hospital in Kraków. Neurological examination showed spastic quadriplegia (more severe on the right side) with hyperreflexia and four limbs' contractures. The EEG showed generalized slow activity without rhythmic slow waves typical for CJD and CSF analysis did not reveal 14–3–3 protein elevation. Because of the lack of typical CJD findings from the EEG and CSF examination and a concomitant clinical and MRI picture suggesting diffuse encephalopathy, brain biopsy was performed after obtaining the approval from a family court.

Applying the method of open brain biopsy, the sample of approximately 1.5cm in diameter containing both the cortex and subcortical white matter was obtained from the left temporal lobe. The tissue was treated accordingly to the universally accepted methods for handling tissue suspected of being "infected" with a pathogenic prion strain, including 1h immersion in formic acid. Histopathological investigations including immunohistochemistry were made on sections of samples embedded in paraffin blocks. Hematoxylin and eosin (H&E) staining showed vacuolization in the neuropil and neuronal loss indicating spongiform degeneration (Fig. 1). Immunohistochemical staining for PrP demonstrated immunopositive deposits around spongiform changes resistant to autoclaving and proteinase K digestion (Fig. 2). These results confirmed the diagnosis of CJD in our patient.

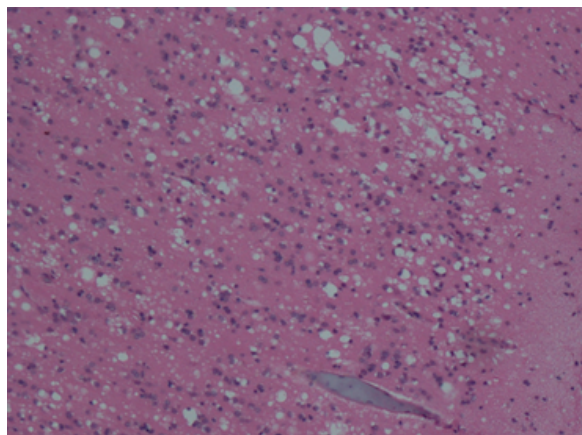


Fig 1. Brain biopsy, left temporal lobe, H&E staining. Vacuolization in the neuropil and neuronal loss indicate spongiform degeneration.

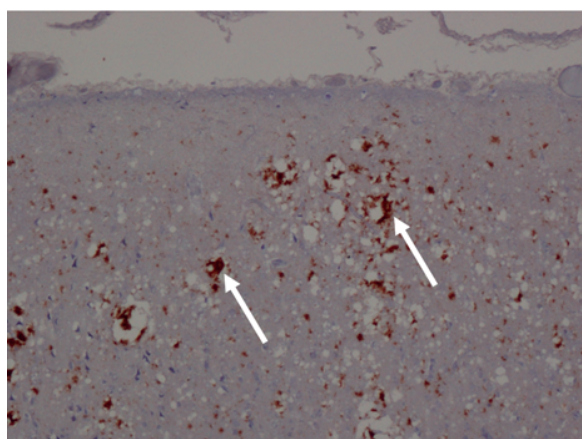


Fig 2. Brain biopsy, left temporal lobe, immunohistochemical staining for PrP. Immunopositive deposits around the spongiform change may be observed (arrowhead).

DISCUSSION

Reports indicate that CJD, as well as other prion diseases like fatal familial insomnia, may manifest as catatonia [13]. Table 1 presents published cases of CJD patients presenting with catatonic behavior. Our case report and collected data point out several features facilitating dif-

ferential diagnosis between catatonic behavior observed in mental disorders and that observed in CJD. Those features include: short duration of illness, rapid deterioration, and no improvement in psychiatric symptoms despite pharmacological treatment. Patients may often be wrongly diagnosed with neuroleptic malignant syndrome [14].

Tab 1. Published cases of CJD patients presenting with catatonic behavior

Age	Gender	Type of CJD	Duration of illness (months)	Psychiatric symptoms before catatonic behavior	Neuroimaging	EEG	CSF
51	Female	sCJD	4	Reduced attention and concentration, insomnia, decreased psychomotor activity, deteriorating memory function, anhedonia, anxiety irritability, propensity to cry, diagnosis of depression for 20 years	MRI: mild generalized cerebral and cerebellar atrophy DWI: areas of cortical diffusion restriction and slow wave complexes	Bilateral periodic lateralized epileptiform discharges	14–3–3 and tau protein elevation
35	Male	nvCJD	3	Fatigue, decreased interaction, mood swings	MRI: high signal intensity on T2WI and fluid attenuated inversion recovery (FLAIR) in caudate nucleus, thalamus bilaterally (hockey stick sign), posterior cingulate and parietal lobe DWI: bilateral symmetric hyperintense signals in the caudate, frontal, parietal and occipital regions	Diffuse slowing of background activity to delta range	Negative
52	Female	CJD	4	Depressive symptoms, confusion, disorientation, insomnia, loss of appetite, periodic agitation, anxiety, delusions	Unremarkable	Generalized background slowing with a few irregular sharp waves	Negative

59	Female	sCJD	5	Impulsive and socially inappropriate behavior, somnolence, withdrawal, memory deficits, vocal tics with grunting and barking, Tourette syndrome-like sounds, involuntary movements	Unremarkable	Initial EEG: nonspecific background slowing, after 5 months – periodic sharp wave complexes typical of sCJD	14–3–3 and tau protein elevation
60	Male	CJD	4	Anxiety, visual hallucinations, depression	DWI: cortical ribbon sign and hyperintense caudate nucleus	Periodic triphasic sharp waves	Negative for viral markers, 14–3–3 not evaluated
80	Female	sCJD	29	Anxiety, anhedonia, fatigue, depressed mood, apathy, psychomotor retardation	MRI: bilateral temporal-occipital cortex predominantly left hemispheric alterations with integrity of basal ganglia DWI: bilateral parieto-occipital cortical hyperintensities that affected several gyri	Slowness and diffuse period sharp wave complexes (PSWC) predominantly in left hemisphere	Elevated 14–3–3

CJD, Creutzfeld-Jakob disease; nvCJD, new variant CJD; sCJD, sporadic CJD; vCJD, variant CJD; CSF, cerebrospinal fluid; DWI, diffusion-weighted magnetic resonance imaging; EEG, electroencephalogram; MRI, magnetic resonance imaging.

Electroconvulsive therapy (ECT), which remains the predominant method of treatment in catatonia, may not only be ineffective in CJD, but in some cases may also be associated with symptoms' progression. Grande et al. [15] reported a case of CJD patient who, after eight bilateral ECT sessions in 25 days, became disoriented, inattentive and perseverative, with hypophonic, monotonous speech with a paucity of content and difficulties in naming and understanding complex orders. The patient also developed rigidity, postural tremor, bradykinesia, gait disturbances and became wheelchair bound [15]. In such cases of ECT-resistant catatonic behavior, EEG, MRI and CSF examinations should be conducted. The EEG pattern differs depending on the stage of the disease. In the early stages, diffuse slowing and frontal rhythmic delta activity (FIRDA) may be present, whereas the middle and late stages of sporadic CJD (sCJD) present with disease-typical periodic sharp wave complexes (PSWC) [16]. Control EEG performed in

the presented case revealed a pattern characteristic for sCJD. Thus, there was no need for further diagnostics for variant CJD (vCJD) (e.g. tonsil biopsy).

In CSF tests, elevated 14–3–3 protein is detected in about 90% cases of sCJD, but in only 50% cases of vCJD [17]. However, histological examination is the only method of final diagnosis. Brain biopsy sampling may be helpful in the diagnostic approach to rare cases of atypical manifestation of this disease, when CSF parameters, EEG and MRI results are inconsistent and neuropsychological examination is not possible [18].

The presented case indicates that sCJD should be considered in the wide differential diagnosis of catatonic behavior, especially when there is a short duration of psychiatric symptoms and their resistance to treatment, as well as rapid deterioration of patient's health.

REFERENCES

1. Chrobak AA, Adamek D. New light on prions: putative role of co-operation of PrPc and A β proteins in cognition. *Folia Neuropathol.* 2014; 1: 1–9.
2. Morales R, Estrada LD, Diaz-Espinoza R, Morales-Scheihing D, Jara MC, Castilla J, et al. Molecular cross talk between misfolded proteins in animal models of Alzheimer's and prion diseases. *J Neurosci.* 2010; 30: 4528–35.
3. Milanlioglu A, Ozdemir PG, Cilingir V, Ozdemi O. Catatonic depression as the presenting manifestation of Creutzfeldt-Jakob disease. *J Neurosci Rural Pract.* 2015; 6: 122.
4. Brown P, Gibbs CJ, Rodgers-Johnson P, Asher DM, Sulima MP, Bacote A, et al. Human spongiform encephalopathy: the National Institutes of Health series of 300 cases of experimentally transmitted disease. *Ann Neurol.* 1994; 35: 513–29.
5. Yen CF, Lin RT, Liu CK, Lee PW, Chen CC, Chang YP. The psychiatric manifestation of Creutzfeldt-Jakob disease. *Kaohsiung J Med Sci.* 1997; 13: 263–7.
6. Satishchandra P, Sharma P, Chatterji S, Shankar SK. Psychiatric manifestations of Creutzfeldt-Jakob disease: probable neuropathological correlates. *Neurol India.* 1996; 44: 43–6.
7. Will RG, Matthews WB. A retrospective study of Creutzfeldt-Jakob disease in England and Wales 1970–79. I: Clinical features. *J Neurol Neurosurg Psychiatry.* 1984; 47: 134–40.
8. Sobreira S, Mota IA, Da Cunha JEG, Mello R, Oliveira JR. How heterogeneous can the clinical presentation for Creutzfeldt-Jakob disease be? *J Neuropsychiatry Clin Neurosci.* 2013; 25: 44–5.
9. Berent D, Bączek I, Florkowski A, Gałeczki P. Choroba Creutzfeldta-Jakoba w praktyce psychiatrycznej – opis przypadków postaci atakycznej i Heidenhaina. *Psychiatr Pol.* 2014; 48: 187–94.
10. Siwek M, Dudek D, Smoleń P, Michałowska K. Od zaburzeń konwersyjnych i lękowo-depresyjnych do choroby Creutzfeldta –Jakoba. In: Rabe-Jabłońska J, ed. *Trudne diagnozy psychiatryczne.* Warsaw: PZWL; 2014: pp. 91–8.
11. Shekhawat LS, Kumar S, Ramdurg SI, Manjunatha N, Gupta P. New variant Creutzfeldt-Jakob disease presenting with catatonia: a rare presentation. *J Neuropsychiatry Clin Neurosci.* 2012; 3: 51–3.
12. Daniels J. Catatonia: clinical aspects and neurobiological correlates. *J Neuropsychiatry Clin Neurosci.* 2009; 21: 371–80.
13. Oliveros RG, Saracibar N, Gutierrez M, Bank DNA, Ehu UP V, Muñón T, et al. Catatonia due to a prion familial disease. *Schizophr Res.* 2009; 108: 309–10.
14. Tho JH, Binnie CD, Vowels G. Creutzfeldt-Jakob disease presenting with unusual psychiatric symptoms: Report of an Asian patient. *Neurol Asia.* 2005; 10: 131–3.
15. Grande I, Fortea J, Gelpi E, Flamarique I, Udina M, Blanch J, et al. Atypical Creutzfeldt-Jakob disease evolution after electroconvulsive therapy for catatonic depression. *Case Rep Psychiatry.* 2011; 2011: 791275. doi:10.1155/2011/791275.
16. Wieser HG, Schindler K, Zumsteg D. EEG in Creutzfeldt-Jakob disease. *Clin Neurophysiol.* 2006; 117: 935–51.
17. Golańska E, Liberski PP. 14–3–3 protein in diagnostics of sporadic Creutzfeldt-Jakob disease. *Aktual Neurol.* 2011; 11: 38–43.
18. Heinemann U, Krasnianski A, Meissner B, Kallenberg K, Kretschmar HA, Schulz-Schaeffer W, et al. Brain biopsy in patients with suspected Creutzfeldt-Jakob disease. *J Neurosurg.* 2008; 109: 735–41.
19. Molina M, Fekete R. Stereotypic movements in case of sporadic Creutzfeldt-Jakob disease: possible role of anti-NMDA receptor antibodies. *Case Rep Neurol.* 2012; 4: 244–7.
20. Tripathi SM, Tripathi RK, Tiwari SC. An atypical presentation of Creutzfeldt-Jakob disease. *IJSAR.* 2015; 2: 46–9.
21. Cumber E, Furfari K, Guerrasio J. Creutzfeldt-Jakob disease presenting as severe depression: a case report. *Cases J.* 2009; 2: 122.