

Regenerative medicine- techniques and methods of administering autologous derived stem cells in urinary incontinence

Medycyna regeneracyjna w leczeniu nietrzymania moczu a technika i sposoby podania materiału komórkowego do zwieracza cewki moczowej

Klaudia Stangel-Wojcikiewicz¹, Maciej Petko², Konrad Kobus², Marcin Majka³, Tomasz Gołąbek⁴, Piotr Chłosta⁴, Antoni Basta¹

¹ Department of Gynaecology and Oncology, Jagiellonian University Collegium Medicum, Cracow, Poland

² AGH University of Science and Technology, Faculty of Mechanical Engineering and Robotics Kraków, Poland

³ Department of Transplantation, Jagiellonian University Collegium Medicum, Cracow, Poland

⁴ Department of Urology, Jagiellonian University Collegium Medicum, Cracow, Poland

Abstract

The aim of the work is to present regenerative medicine achievement as an alternative SUI treatment and the variety of injected cells type as well as injection techniques itself with the analysis of their quality and possible the mechanism in which they reduce urinary incontinence symptoms.

For over a decade numerous authors declare use of different type of autologous mesenchymal-derived stem cells (AMDC) in male and female SUI. The leakage improvement reached 80%, despite the number of injected cells as well as the injection technique. Important subject in the AMDC treatment is the precise cell material injection into the selected spot which might be possible with the use of the endoscopic assisting robot.

The robotic supported system for cells procedure might bring the missing percentage in reaching the goal in SUI treatment.

Key words: **stem cells / stress urinary incontinence / endoscopy / robotic systems /**

Corresponding author:

Klaudia Stangel-Wojcikiewicz
Department of Gynecology and Oncology, Jagiellonian University Collegium Medicum,
Kopernika 23, 31-501 Cracow, Poland
e-mail: ksw@cm-uj.krakow.pl

Otrzymano: 29.06.2015
Zaakceptowano do druku: 04.12.2015

Klaudia Stangel-Wojcikiewicz et al. *Regenerative medicine- techniques and methods of administering autologous derived stem cells in urinary incontinence.*

Streszczenie

Celem pracy jest przedstawienie osiągnięć medycyny regeneracyjnej jako alternatywnej terapii w wysiłkowym nietrzymaniu moczu (WNM). Dokonany przegląd literatury problemu wskazuje na różnorodność podawanych linii komórkowych, ich rodzaju, jak i samej techniki iniekcji z analizą jakości i ewentualnego mechanizmu, w którym zmniejszeniu uległy objawy nietrzymania moczu.

Od ponad dziesięciu lat wielu autorów deklaruje korzystanie z różnych rodzajów autologicznych mezenchymalnych komórek macierzystych (AMDC autologous muscle derived stem cells) w leczeniu mężczyzn i kobiet z WNM. Poprawa utrzymania moczu sięga wg niektórych źródeł 80%, niezależnie od liczby wstrzykniętych komórek, oraz sposobu ich podania. Ważnym zagadnieniem w leczeniu z użyciem AMDC, jest precyzyjne podanie materiału komórkowego do wybranego miejsca (zwieracza cewki moczowej), które można udoskonalić stosując endoskopowo wspomagany system robota.

Zastosowanie ww systemu mogłoby poprawić technikę podania materiału komórkowego i zobiektywizować wyniki leczenia.

Słowa kluczowe: **komórki macierzyste / wysiłkowe nietrzymanie moczu /
/ endoskopia / robotyka /**

Urinary incontinence is symptom which has strong impact on the quality of life, both in women and in men. In the case of female stress urinary incontinence (SUI), apart from pelvic floor physiotherapy, pessaries and others surgery is the one method of treatment [1]. Until recently, the Burch procedure (colposuspension) was the “gold standard”. Long-term observations of up to 30 years allowed to believe that no new treatment will achieve such a high (up to 80%) effectiveness of therapy. Laparoscopic modification allowed to minimize the side effects (including post-surgery pain and bleeding) as well as the duration of surgery and hospitalization. A limiting factor for this technique is still the learning curve, particularly laparoscopic access, which can significantly impact the final effect of urinary continence. Further research were oriented at simplification of the technique, while maintaining high effectiveness of the procedure. In the nineties, synthetic tapes were introduced; the application techniques included tension free vaginal tape (TVT) and transobturator tape (TOT) [2, 3]. The tape material resistance ensured long-term therapeutic effect. Yet, there was a problem resulting from tissue barrier of the immune reaction to the foreign body. Complications, i.e. erosion of the tape with accompanying fistulas, symptoms of dysuria, and even generalized infection (sepsis) induced the researchers to seek new, biodegradable or autologous materials as prosthesis for the urethra and/or vaginal wall [4, 5].

Stem cells therapy for management of male stress urinary incontinence

Despite improvements in surgical techniques and implementation of minimally invasive procedures, male stress urinary incontinence (MSUI) affects a substantial number of patients after prostatic surgery. Historically the incidence rate of MSUI following radical prostatectomy was as high as 87% [6]. However, contemporary series have reported lower incontinence rates ranging 4-50% after radical prostatectomy and approximately 1% following transurethral resection of the prostate [7]. Pathophysiologic mechanisms of postoperative MSUI include a direct injury to the urethral sphincter itself, as well as, to adjacent supportive tissues and nerves [8].

Although conservative and pharmacological management of low and intermediate grade MSUI may be effective particularly in a short-term, the majority of patients will eventually require more invasive approach including sling procedure or artificial urinary sphincter (AUS) implantation [9]. Despite AUS recommendation as a current gold standard treatment option for men with postoperative stress urinary incontinence, with the resultant continence rates reaching 80%, it is associated with the substantial risk of early and late complications, considerable cost and need for device revision at 5 years in up to 25% of patients [10].

To date, only few studies have examined the efficacy of autologous adult-derived stem cells for the management of MSUI in human patients. Table I summarizes the clinical studies of autologous mesenchymal-derived stem cells in men with SUI after prostatic surgery.

The first results for injection of autologous myoblasts and fibroblasts obtained from skeletal muscle biopsies in 41 of the 63 male patients (65%) with SUI after radical prostatectomy were continent 12 months following injection of autologous myoblasts and fibroblasts [11]. A significant improvement in quality of life scores, the thicknesses of the urethra and the rhabdosphincter, as well as, the increased contractility of the rhabdosphincter were observed after a period of 1-year. Of note, presence of preoperative urethral strictures, scars, or fibrotic areas in the membranous part of the urethra, as well as, prior treatment with bulking agents or internal urethrotomy, or pelvic irradiation negatively affected the success rates. The findings from both studies have supported validity of MDSCs as a treatment option for male MSI. Further confirmatory data regarding the benefit of MDSCs application for treatment of MSUI have been reported by Cornu et al. [12]. In their study, authors observed improved urinary continence in all 12 patients who underwent intrasphincteric injections of autologous muscular cells isolated from a biopsy of the deltoid muscle. Of note, the efficacy results 1 year after the treatment were not homogeneous, with 4 out of 12 patients describing reduced urine leakage episodes, 1 out of 12 patients presenting increased maximal closure pressure, and 8 out of 12 patients showing improvement on pad-test.

Table I. Clinical studies of autologous mesenchymal-derived stem cells for male stress urinary incontinence.

Author [reference]	Number of male patients	Grade of MSUI	Stem cell source	Harvesting Tissue	Duration of follow-up	Morbidity
Mitterberger [11]	63	Severe	MDSCs	Biceps muscle	12 months	No
Comu [12]	12	ND	MDSCs	Deltoid muscle	12 months	UTI in 3 men
Yamamoto [13]	3	Moderate	ADSCs	Anterior abdominal wall	6 months	No
Gotoh [14]	11	ND	ADSCs	Anterior abdominal wall	12 months	No

Key: MSUI=male stress urinary incontinence; ND=not described; MDSCs= muscle-derived stem cells; ADSCs= adipose-derived stem cells; UTI=urinary tract infection.

Table II. Autologous stem cells studies in female SUI.

Scientific centre	Harvesting tissue	Technique	Biopsy muscle volume
Carr/ Chancellor 2008 [16]	quadriceps femoris	percutaneous needle technique	Not given
Peters/ Chancellor 2014 [17]	quadriceps femoris	percutaneous needle technique	86±33 mg
Blaganje/ Lukanovic 2012 [18]	upper arm	open cut	~0.5 cm ³
Stangel-Wójcikiewicz 2014 [19]	deltoid muscle	14-G 10-cm Ultra CORE Biopsy Needle (Angiotech, Gainesville, FL).	0.2g

Table III. Comparison of techniques, tools or systems enabling precise location of the urethra sphincter and the injection spot.

Scientific centre	Technique/tool	Number of perisphincteral injections	Cell's dose
Carr/ Chancellor 2008 [16]	<ol style="list-style-type: none"> 1. Transurethral injection with 8-mm Cook® Williams® cystoscopic injection needle 2. Transurethral injection with modified 10-mm Williams® needle 3. Periurethrally injection with 1,5-in. 25-gauge needle 	2 injections (at the 3 and 9 o'clock) 4 injections (at the 3, 6, 9 and 12 o'clock) 4 injections (at the 3, 6, 9 and 12 o'clock)	18-22x10 ⁶ MDSC
Peters/ Chancellor 2014 [17]	<ol style="list-style-type: none"> 1. Cystoscopic guided tranurethral injection 2. Cystoscopic guided periurethral injection 3. Transurethral injection with the SUI Injection Needle (Cook Medical) 	8 injections of about 0.5 ml each	10-200x10 ⁶ AMDC-USR
Blaganje/ Lukanovic 2012 [18]	Sonoject, A.M.I., Feldkirch, Austria with transurethral 8F ultrasound probe	26 depots of 50-100 µl each in to levels Kształt odwróconej litery U	1x10 ⁶ -5x10 ⁷
Stangel-Wójcikiewicz 2014 [19]	Bulkamid® System; cystoscopic guided tranurethral injection	3 injections (at 3, 12 and 9 o'clock)	0.6–25x10 ⁶ MDC

Adipose-derived stem cells have also been investigated for treatment of MSUI. Yamamoto et al. published their preliminary results regarding 3 male patients with moderate MSUI secondary to radical prostatectomy or holmium laser enucleation of the prostate (HoLEP) treated with ADSCs [13]. During a 6-month follow-up urinary incontinence progressively improved in all cases. This was evidenced by both functional and imaging studies. No significant adverse events were observed peri- and postoperatively.

Further support for the use of ADSCs in the management of postoperative MSUI in men comes from the report by Gotoh et al. [14]. The results of this recently published study on efficacy

of autologous adipose-derived regenerative cells isolated from abdominal adipose tissue obtained by liposuction are encouraging. The authors observed a progressive improvement of MSUI in 8 out of 11 men during the 1-year follow-up which was shown by a 59% decrease in the leakage volume in the 24-hour pad test, an increase of the maximum urethral closing pressure and functional profile length. There were no significant peri- or postoperative morbidity noted during the study period.

So far, all published studies evaluating periurethral injection of autologous MDSCs and ADSCs in the management of MSUI showed promising results. Moreover, this treatment modality seems to be a safe and feasible method for restoring urinary

continence in male patients. However, since all currently available data come from small, single centre, noncomparable studies, as well as, have limited follow-up, further research is required to address all the aforementioned issues and subsequently provide an answer to the question about the role of autologous adult mesenchymal-derived stem cells in the treatment of SUI in men.

Tissue harvesting for female SUI treatment

Since 2001 numerous authors declare use of different type of autologous mesenchymal-derived stem cells in female SUI. The leakage improvement reached 80%, despite the number of injected cells as well as the injection technique [15]. In the available literature, the following places and procedures of acquiring the tissue material are mentioned (Table II).

In research carried out by Chancellors group, the tissue biopsy was extracted from quadriceps femoris, a muscle which—according to the scientists—guarantees a sufficient amount of tissue for further cultivation [16, 17]. Lukanovic group reports open cut biopsy from location specified upper arm [18]. In order to minimize potential side effects as well as discomfort of the patient, Stangel-Wójcikiewicz et al. carry out research using techniques known from biopsy of lesions in the mammary gland [19]. An additional ultrasound scan allowed to eliminate vessels and bone tissue injury. In each of the quoted research, the material was collected in on an outpatient basis, i.e. the patient could return to they daily activities right after the biopsy. No serious complications or permanent tissue damage at the extraction site were reported.

Cell's injection techniques

Similarly to the methods of tissue biopsy, also the techniques of administering the cellular suspension are described in a different manner. This variety is especially noticeable in female SUI stem cells injections (Table III).

Depending on the facility, from 2 to 26 injections around the urethral sphincter were made, each time using endoscopic imaging (cystoscopy) or ultrasound imaging. In the research published in 2008 and 2011, Chancellor's group applied the system of cytoscopy and administration through or perisphincteral, initially 2 injections (at the 3 and 9 o'clock), to increase the number of injections to 8 in the next study [16,17]. The volume of the injected material was less then 4 ml, in order to avoid the so-called bulking agent effect. Higher dose groups tended to have greater percentages of patients with at least a 50% reduction in stress leaks and pad weight at 12-month follow up. There was no technic indication to be more advantage to another. Lukanovic et al. used much more injections, namely 26 [18]. One may ponder on the fact of stimulating local inflammatory reaction and secretion of tissue growth factors as a response to such a large number of injections. Does it have a stimulating or healing effect, i.e. regeneration by administering cellular material?

In order to avoid this sort of speculations, Stangel-Wójcikiewicz et al. decided to use one system of injection (*Bulkamid® System*) and only three points, at the 3, 12 and 9 o'clock around the urethra sphincter (Figure 1) [19].

Its endoscopic imaging allows to keep the procedure comfortable, consisting, e.g., in control of the potential bleeding from the injection points, control of the amount of administered suspension. Due to the anatomy of the female urethra, they used a short, 11 cm optics with 0 degree angle.




Figure 1. Bulkamid® System.

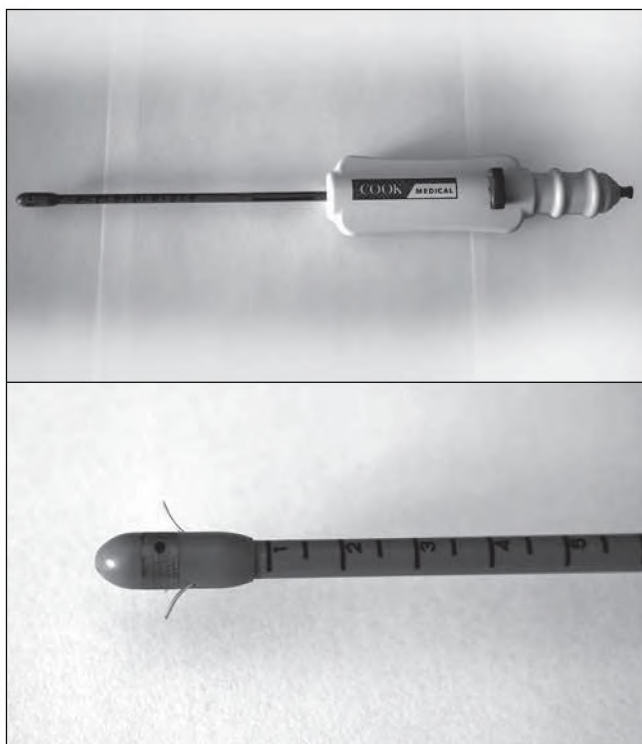


Figure 2 (a, b). Injection system (Cook Medical)

The available literature suggests that there is no single perfect, standard method of administration. This diversity results from anatomic difficulties and phenotypic variability in the scope of urethra. Urethral sphincter has two primary components: internal sphincter, formed from smooth muscle layer, situated in the wall of the near section of urethra, which is probably an extension of the detrusor muscle, and external sphincter, which surrounds the distal section of the urethra and the vagina. On an outpatient basis, Stangel-Wójcikiewicz et al. accessed to few diagnostic methods which imperfectly represent both the aforesaid urethra sphincter and assess its functioning based on pressure changes. Ultrasonography (USG) and urodynamics (urethral pressure

profile) only allow to determine the area which is anatomically referred to as the urethral sphincter.

The CookMedical system (Figure 2) uses the known length of the urethra of the given patient (measurement made earlier) and the assumption that the sphincter is located at one-third of its length. The injection is made after manual activation of three needles at the height of the mace-tipped guide. The syringe with the cellular material is connected to the system handle. One advantage of this system may be the fact, that is a disposable system, and of simple structure. Yet, its structure prevents any manoeuvring in the area of the urethral sphincter and change of the injection angle, it also seems unusable in the case of male patients.

In 2012, the engineers from the AGH Department of Robotics and Mechatronics in Krakow have initiated cooperation in order to jointly develop the technique for administration of cell suspension. The objective of the project entitled "Micromanipulation with surgical instruments for assisting in intracorporeal procedures with the use of vision imaging" – MACHWIZ (NCBiR), is the development of practical methods of designing devices for precise manipulation of surgical instruments with visual feedback for handling the tools and additional imaging methods for location of tissues or organs to be subjected to the treatment. The work is focus on procedures within pelvis minor, performed with endoscopic tools through natural body orifices. Injecting stem cells in the urethral sphincter in treating stress urinary incontinence in female patients will be an example of this type of procedure, used for verification of the developed method. The proper course of use of the designed tool will be verified in experimental tests conducted in a demonstration set fitted with a urologic phantom.

Robot aided MDC injection

Essential for the efficacy of MDC treatment is the proper cells administration. This raises two problems: determination of the correct place of cell administration, and injection of cell suspension precisely into the urethral sphincter. Solution of the first problem is to choose an appropriate imaging method that allows for localisation, and preferably also for determine the spatial shape of the urethral sphincter. Precise injection of cell suspension exactly into the selected spot might be possible with the use of the endoscopic assisting robot [20, 21].

To provide data in a digital format the use of static USG images will be acquired before the procedure of MDC injection. On-line, endoscopic vision system provide base imaging source. The automatic image processing collect data for tool navigation along the urethra. Actuators of the needle extension and tool rotation allow for performing injection at the required depth and in the required place on the circumference of the urethra. Urethral profilometry will be performed by the robot, just before injection, in a single tool insertion.

The designed instrument integrates endoscope optics, a custom detachable sheath and a drive mechanism for needle penetrating movement (Figure 3).

The chosen endoscope optics is the 7229 BA HOPKINS II forward-oblique version telescope, featuring a roller lens optic system, with incorporated fibre optics light transmission, offered by Karl Storz GmbH and Co. KG [22].

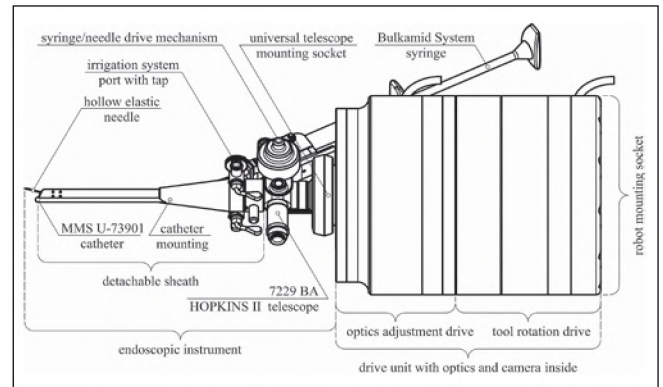


Figure 3. The developed endoscopic robot tool – side view.




Figure 4. The developed robot endoscopic tool for MDC suspension injection – isometric view.

The detachable sheath has three internal leak-proof channels. One of them acts as a guide for an elastic hollow 23 Gauge needle, purposed for MDC injection. The two remaining conduits are responsible for wide-angle fluids dispersion (e.g. to inflate a collapsed urinary bladder), draining purposes or both.

The movement of the needle is achieved by a precise and sophisticated mechanism. It is driven by a servomotor, consisting of a low voltage DC motor, a suitable planetary gearbox and a rotary encoder[23]. The needle is guided in the sheath's internal channel and bends in such a way that it leaves the tool at a steep angle to the urethral wall, piercing the mucous membrane and penetrating the urethral mucosa.

The endoscopic instrument can serve as a manual tool for surgeons if attached to a telecam endoscope (20212030 endoscope, Storz). If integrated with the custom designed drive unit, it becomes an efficient end-effector for the pelvic surgery assisting robot (Figure 4).

The drive unit has two main objectives: to ensure a secure and reliable clutch between the instrument and the robot, and to provide rotation for the entire endoscopic tool, mimicking the swivel movement of a human wrist. The unit is equipped with an adequate digital camera and an optic system, replacing the normally used telecams with no loss of usage flexibility. It is also fitted with a universal socket for telescope mounting. The telescope can be quickly and easily detached at any time, without any additional tools [24].

Klaudia Stangel-Wojcikiewicz et al. *Regenerative medicine- techniques and methods of administering autologous derived stem cells in urinary incontinence.*

All the assembly elements of the designed sheath are made of the martensitic, precipitation-strengthened, corrosion-resistant X46Cr13 stainless steel [25], same as modern surgical instruments. The material and shape make the sheath fully autoclavable. The endoscopic instrument and drive units have low voltage electromechanical components located relatively far from both: the patient and the surgeon, ensuring safety against any electrical shocks. To ensure even further contamination safety, all the elements (beside the sheath) can be fitted within an elastic protective sleeve.

Conclusion

Scientific centres which researched the methods of using cellular material for SUI treatment report (even within the scope of a single research) various methods of obtaining muscle tissue, as well as different ways of injecting the cellular suspension into the urethra sphincter, with variable number of insertions and quantity of administered cells. The proper and repeatability administration technique might determinate the final results of stem cells base SUI treatment.

Oświadczenie autorów:

1. Klaudia Stangel-Wójcikiewicz – autor koncepcji i założeń pracy, przygotowanie manuskryptu i piśmiennictwa – autor zgłaszający i odpowiedzialny za manuskrypt.
2. Maciej Petko – zebranie materiału, przygotowanie manuskryptu.
3. Konrad Kobus – współautor tekstu pracy i protokołu, korekta i aktualizacja literatury.
4. Marcin Majka – autor założeń pracy, analizy i interpretacji wyników, przygotowanie, korekta i akceptacja ostatecznego kształtu manuskryptu.
5. Tomasz Gołąbek – współautor tekstu pracy, aktualizacja literatury.
6. Piotr Chłosta – ostateczna weryfikacja i akceptacja manuskryptu.
7. Antoni Basta – autor założeń pracy, ostateczna weryfikacja i akceptacja manuskryptu.

Źródło finansowania:

projekt finansowy z grantu PBS K/NCB/000003.

Konflikt interesów:

Autorzy nie zgłaszają konfliktu interesów oraz nie otrzymali żadnego wynagrodzenia związanego z powstawaniem pracy.

References

1. Abrams P, Andersson KE, Birdler L, [et al.]. Fourth International Consultation on Incontinence Recommendations of the International Scientific Committee: Evaluation and treatment of urinary incontinence, pelvic organ prolapse, and fecal incontinence. *Neurourol Urodyn.* 2010, 29 (1), 213-240.
2. Garely AD, Noor N. Diagnosis and surgical treatment of stress urinary incontinence. *Obstet Gynecol.* 2014, 124 (5), 1011-1027.
3. Yonguc T, Aydogdu O, Bozkurt IH, [et al.]. Long-term outcomes of transobturator tape procedure in women with stress and mixed urinary incontinence: 5-year follow-up. *Minerva Urol Nefrol.* 2015, Jan 13. [Epub ahead of print]
4. Hart ML, Izeta A, Herrera-Ibroda B, [et al.]. Cell therapy for stress urinary incontinence. *Tissue Eng Part B Rev.* 2015; , 21: , 365-376.
5. Hakim L, De Ridder D, Van der Aa F. Slings for urinary incontinence and the application of cell-based therapy. *Adv Drug Deliv Rev.* 2015; , 82-83: , 22-30.
6. Bauer RM, Bastian PJ, Gozzi C, Stief CG. Postprostatectomy incontinence: all about diagnosis and management. *Eur Urol.* 2009, 55 (2), 322-333.
7. Herschorn S, Bruschini H, Comiter C, Grise P, Hanus T, Kirschner-Hermanns R, Abrams P, [et al.]. Committee of the International Consultation on Incontinence. Surgical treatment of stress incontinence in men. *Neurourol Urodyn.* 2010, 29 (1), 179-190.
8. Radomski SB. Practical evaluation of post-prostatectomy incontinence. *Can Urol Assoc J.* 2013, 7 (9-10 Suppl 4), S186-188.
9. Adamakis I, Vasileiou I, Constantinides CA. The treatment of iatrogenic male incontinence: latest results and future perspectives. *Rev Recent Clin Trials.* 2013, 8 (1), 36-41.
10. Herschorn S. The artificial urinary sphincter is the treatment of choice for post-radical prostatectomy incontinence. *Can Urol Assoc J.* 2008, 2 (5), 536-539.
11. Mitterberger M, Marksteiner R, Margreiter E, [et al.]. Myoblast and fibroblast therapy for post-prostatectomy urinary incontinence: 1-year followup of 63 patients. *J Urol.* 2008, 179 (1), 226-231.
12. Cornu JN, Doucet C, Sèbe P, [et al.]. Prospective evaluation of intrasphincteric injections of autologous muscular cells in patients with stress urinary incontinence following radical prostatectomy. *Prog Urol.* 2011, 21 (12), 859-865.
13. Yamamoto T, Gotoh M, Kato M, [et al.]. Perirethral injection of autologous adipose-derived regenerative cells for the treatment of male stress urinary incontinence: Report of three initial cases. *Int J Urol.* 2012, 19 (7), 652-659.
14. Gotoh M, Yamamoto T, Kato M, [et al.]. Regenerative treatment of male stress urinary incontinence by perirethral injection of autologous adipose-derived regenerative cells: 1-year outcomes in 11 patients. *Int J Urol.* 2014, 21 (3), 294-300.
15. Stangel-Wojcikiewicz K. Medycyna regeneracyjna w leczeniu nietrzymania moczu. Wydawnictwo Uniwersytetu Jagiellońskiego, Kraków, 2014.
16. Carr LK, Steele D, Steele S, [et al.]. 1-year follow-up of autologous muscle-derived stem cell injection pilot study to treat stress urinary incontinence. *Int Urogynecol J Pelvic Floor Dysfunct.* 2008, 19, 881-883.
17. Peters K, Dmochowski R, Carr LK, [et al.]. Autologous muscle derived cells for treatment of stress urinary incontinence in women. *J Urol.* 2014, 192 (2), 469-476.
18. Blaganje M, Lukanović A. Intrasphincteric autologous myoblast injections with electrical stimulation for stress urinary incontinence. *Int J Gynaecol Obstet.* 2012, 117 (2), 164-167.
19. Stangel-Wojcikiewicz K, Jarocho D, Piwowar M, [et al.]. Autologous Muscle-Derived Cells for the Treatment of Female Stress Urinary Incontinence: A 2-Year Follow-Up of a Polish Investigation. *Neurourol Urodyn.* 2014, 33 (3), 324-330.
20. Hibner M, Marianowski P, Szymusik I, [et al.] [Robotic surgery in gynecology]. *Ginekol Pol.* 2012, 83 (12), 934-938. Polish.
21. Stangel-Wójcikiewicz K, Basta A, Piwowar M, [et al.]. Operative procedures supported with robotics systems and available endoscope procedures in operative gynecology. *Bio-Algorithms Med-Syst.* 2014, 10 (3), 139-149.
22. Digital Imaging and Communications in Medicine (DICOM). National Electrical Manufacturers Association.; 2006. <http://medical.nema.org/>.
23. Petko M. Wybrane metody projektowania mechatronicznego. Radom: Wydawnictwo Naukowe Instytutu Technologii Eksploatacji – PIB, Radom, 2008.
24. Yu T, Luo J, Singhal A, [et al.]. Shape regularized active contour based on dynamic programming for anatomical structure segmentation. In: Proc SPIE 5747, Medical Imaging 2005: Image Processing, . 2005.
25. Rosemann P, Kauss N, Müller C, [et al.]. Influence of solution annealing temperature and cooling medium on microstructure, hardness and corrosion resistance of martensitic stainless steel X46Cr13 Article first published online: 29 JAN 2015