

**Joanna Kosalka¹, Katarzyna Wawrzycka-Adamczyk¹, Paweł Jurkiewicz², Wiesław Pawlik²,
Mamert Milewski¹, Jacek Musiał¹**

¹Division of Allergy and Immunology, ²nd Department of Medicine, Jagiellonian University Medical College, Cracow, Poland

²Division of Radiology, ²nd Department of Medicine, Jagiellonian University Medical College, Cracow, Poland

Cough-induced lung intercostal hernia

The authors declare no financial disclosure

Abstract

A 73-year-old male with marked emphysema was admitted to the 2nd Department of Internal Medicine, University Hospital in Krakow because of chronic obstructive pulmonary disease (COPD) exacerbation. His medical history was significant for total laryngectomy due to laryngeal cancer in 2010.

Key words: intercostal hernia, chronic obstructive pulmonary disease, cough

Pneumonol Alergol Pol 2016; 84: 119–120

Case report

A 73-year-old male with marked emphysema was admitted to the 2nd Department of Internal Medicine, University Hospital in Krakow because of chronic obstructive pulmonary disease (COPD) exacerbation. His medical history was significant for total laryngectomy due to laryngeal cancer in 2010.

On admission, the patient was complaining of cough, dyspnea and a sensation of “airway obstruction”. Physical examination revealed rales, wheeze and prolonged forced expiratory time. Aspiration through tracheostomy revealed bloody — purulent secretions. After nebulizations with beta-2-agonists and a course of antibiotics, the patient’s condition was improved, however, on the 4th day, the patient reported sharp pain on the left side of the thorax, aggravated by inspiration and cough. Physical examination was normal. As the symptoms imitated pleurisy anti-inflammatory agents were added and the treatment was continued. Two days later a large hematoma on the left side of the chest and abdomen was observed. Laboratory results revealed a reduction

of the hemoglobin level by approx. 4 g%. CT scan showed lung hernia (43 × 22 × 32 mm) in the VIII intercostal space in the left posterior axillary line; hernia gate was 20 × 26 mm in diameter (Fig. 1A–C). Moreover, in this region a rupture of the intercostal muscles as well as active bleeding together with a large abdominal hematoma were detected. Due to patient’s poor performance status, thoracic surgeon decided to postpone any operation. In the following days the patient was not improving and a new CT scan was performed and revealed massive subcutaneous emphysema covering the left half of the chest and left lumbar and supraclavicular regions with inflammatory reaction below the hernia (Fig. 1A, B). In the next days the patient deteriorated even more. He refused to take medication and food, and died on the 50th hospital day.

Lung hernia is a rare condition defined as the protrusion of pulmonary tissue and pleura through an abnormal gap in the thoracic wall, diaphragm or mediastinum [1]. Based on etiology, it is classified to congenital and acquired. Most commonly secondary lung hernia is related to chronic conditions such as trauma, inflammatory or neoplastic processes, COPD or steroid use in combina-

Address for correspondence: Joanna Kosalka, Division of Allergy and Immunology, 2nd Department of Medicine, Jagiellonian University Medical College, Cracow, e-mail: joanna.kosalka@gmail.com

DOI: 10.5603/PIAP.2016.0011

Received: 28.11.2015

Copyright © 2016 PTChP

ISSN 0867–7077

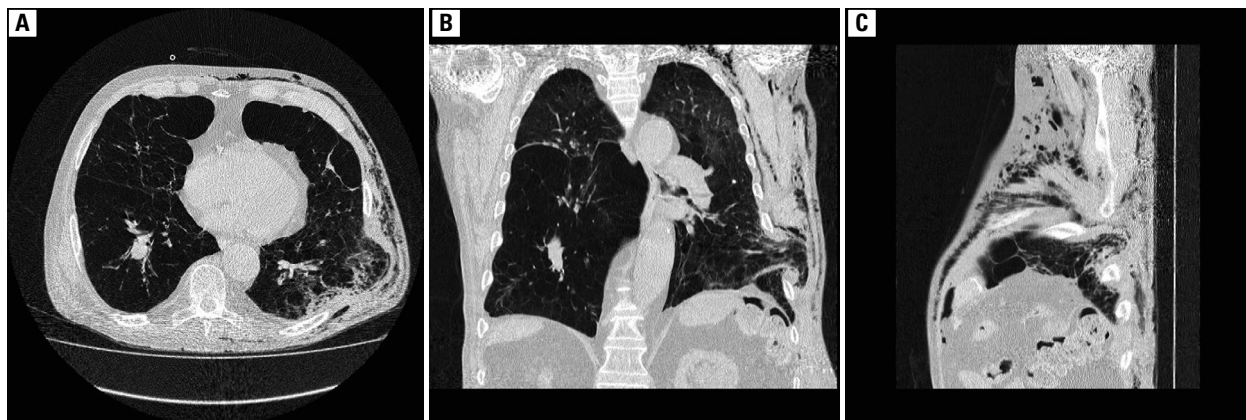


Figure 1A–C. Lung hernia (43 × 22 × 32 mm) in the VIII intercostal space in the left posterior axillary line, subcutaneous emphysema on the left side. Pneumonia in the hernia gate area. Pulmonary emphysema

tion with temporary increased intrathoracic pressure, e.g. during coughing and weight lifting [2]. A role of imaging in diagnosis and treatment of pulmonary hernia was highlighted in previous case reports [3].

Conflict of interest

The authors declare no conflict of interest.

References:

1. Detorakis EE, Androulidakis E. Intercostal lung herniation—the role of imaging. *J Radiol Case Rep* 2014; 8: 16–24. doi: 10.3941/jrcr.v8i4.1606.
2. Sheka KP, Williams LG. Spontaneous intercostal lung hernia. *J Natl Med Assoc* 1984; 76: 1210, 1212–13.
3. Gómez PE, Ferreiro S, Esteban SM, Fodor R, Palavecino ME, Ríos FG. Spontaneous pulmonary hernia: a case report. *Respir Care*. 2013; 58: 119–122. doi: 10.4187/respcare.02125.