

FOLIA MEDICA CRACOVIENSIA

Vol. LV, 2, 2015: 5–13

PL ISSN 0015-5616

Morphology of tributaries of coronary sinus in humans — corrosion casting study

MAŁGORZATA MAZUR, MATEUSZ HOŁDA, MATEUSZ KOZIEJ, WIESŁAWA KLIMEK-PIOTROWSKA,
MARCIN KUNIEWICZ, ALEKSANDRA MATUSZYK, MONIKA KONARSKA, JOANNA JAWOREK,
IZABELA MRÓZ

Department of Anatomy, Jagiellonian University Medical College
ul. Kopernika 12, 31-034 Kraków, Poland

Corresponding author: Małgorzata Mazur MD, PhD, Department of Anatomy, Jagiellonian University Medical College
ul. Kopernika 12, 31-034 Kraków, Poland; Phone/Fax +48 12 422 95 11; E-mail: mazurmalg@poczta.onet.pl

Abstract: The study was carried out on 80 human hearts obtained during autopsies. The vascular beds were filled with synthetic resin and next corroded. In all 80 hearts we have been found both: great, middle and small cardiac veins. In two out of 80 hearts we did not find oblique vein of the left atrium. Posterior vein of the left ventricle was double in four hearts. Right marginal vein was found in 5 hearts, left marginal vein was seen in 9 hearts. We also compared the dimensions of all of the above mentioned tributaries of the coronary sinus.

Key words: veins of the heart, great cardiac vein, middle cardiac vein, small cardiac vein, injection study, corrosion casts.

Introduction

Anatomy of the human and laboratory animal venous coronary tree is still a subject of many interests, of both anatomists and clinicians [1–6]. The modern treatment of the cardiac diseases requires deep anatomical knowledge of the cardiac veins and their possible variations [7–9]. Numerous studies dealing with anatomy of coronary venous tree have been undertaken [10–13] although their results seem to vary a lot. Some studies concentrated on venous coronary tree, however considered other aspects, too, i.e. dominance of the coronary arteries [14].

From anatomical point of view however it is still dissection aided by corrosion casting technique which seems to be the leading method of macroscopic investigations. The researches

on the vascular system are still commonly carried out on vessels which are filled with different masses — it allows to join traditional model of anatomical dissection with the clinical requirements i.e. studies on heart blood vessels still focus on the course and blood supply, although there is much attention put now to the access to different locations using vascular approach. There is still a necessity to investigate special aspects of vascular system i.e. orifice of pulmonary veins into left atrium or sinus venarum of the right atrium. Intervention cardiologists show recently great interest in studies of the venous coronary tree of human heart [6–8].

Filling different natural body channels with different masses followed by corrosion casting has a long history in anatomical studies. From the times of earliest anatomical researchers numerous substances have been used to receive casts of bronchial, biliary or vascular trees. It is worth to mention here L.K. Teichmann who was one of the last gross anatomists and invented his own mass and method of injection, used subsequently to produce his valuable and magnificent specimens. Also nowadays different kinds of plastic masses, i.e. resins, Mercocox, Batson's mass, Duracryl plus, Liquitex R, are being used [15–18].

Material and methods

The venous coronary tree of 80 human hearts obtained during autopsies were injected with the acrylic mass — Duracryl plus (Spofa, Dental, Czechy) dyed with blue pigment through the coronary sinus, filling its tributaries. The mass was made by mixing the powder Duracryl plus with the liquid Duracryl plus in 1 : 3 ratio of proportions, to slow down the solidification and allow appropriate filling even of the minute vessels. The whole project was approved by the Ethical Committee of Jagiellonian University — nr KBET/40/B/2007. After solidification of the mass the specimens were washed in running tap water and next in the distilled water. Next the whole hearts were macerated in 10–15% solution of KOH for three weeks. After that the casts were cleaned of the remnants of tissues in 3% solution of trichloric acid. Next they were rinsed in the distilled water again. Thus obtained specimens were analyzed. The tributaries of the coronary sinus were measured using electronic caliper.

Results

3-dimensional casts of venous coronary tree were first of all analyzed generally — to identify particular tributaries of the coronary sinus. In all 80 specimens we found both great cardiac, middle cardiac as well as small cardiac veins. In all specimens great cardiac vein emptied into the coronary sinus. Also the middle cardiac vein communicated with the coronary sinus.

Oblique vein of the left atrium (OVLA) was found in 78 hearts studied. In two remaining hearts (40 and 64 years old males) we did not manage to find this vessel. Despite that fact it wasn't difficult to establish the beginning of the coronary sinus because it was significantly dilated comparing to the great cardiac vein. In one case studied OVLA emptied into the great cardiac vein. In remaining specimens it emptied normally into the coronary sinus.

It was the posterior vein of the left ventricle (PVLV) which varied both according to the number and orifice the most. In 4 hearts (45-years old female, 48-years old male, and two

58 years old males) double PVLV was observed. In one case additional vessel emptied into coronary sinus. In one heart (63 years old male) PVLV emptied into the great cardiac vein, in all remaining cases they emptied into the coronary sinus directly.

There were some rare tributaries of coronary sinus observed, i.e. right and left marginal veins. Right marginal vein was observed in 5 hearts (one female and four male). In all cases it was a tributary of small cardiac vein. Left marginal vein was found in 9 hearts (all male). In majority of cases (6 hearts) this vein was a tributary of the great cardiac vein. Only in one case it emptied directly into the coronary sinus.

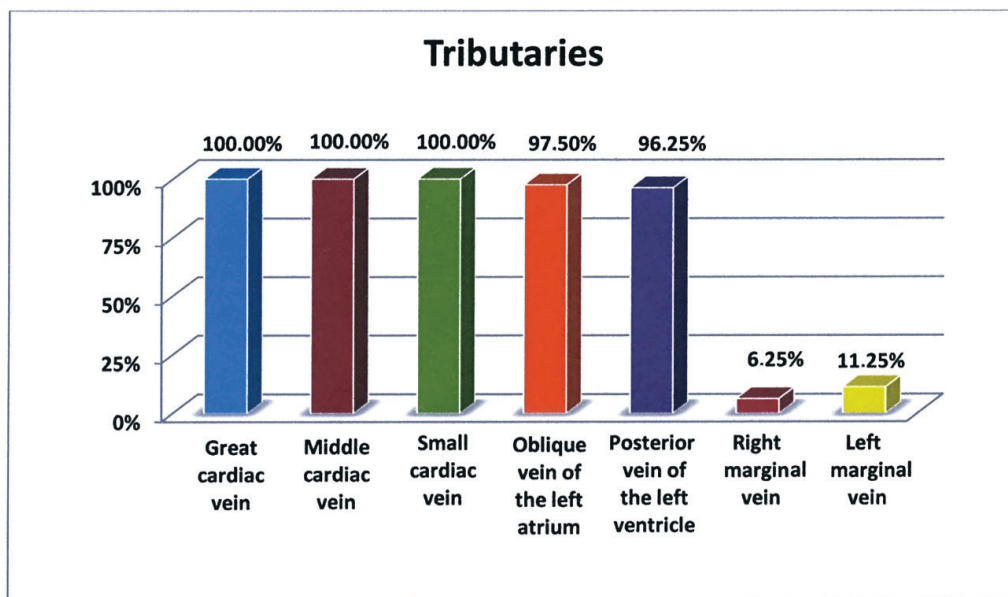


Table 1. Frequency of tributaries of the coronary sinus.

It was rather characteristic that tributaries of coronary sinus created numerous anastomoses each to other. The most numerous connections were found in the vicinity of the heart apex and there were mainly junctions between great and middle cardiac veins, while posterior vein of the left ventricle anastomosed both with the middle cardiac vein as well as with the left marginal vein.

Great cardiac vein

Great cardiac vein apart from the middle cardiac vein was the most stable tributary of the coronary sinus. We found it in all specimens. The beginning of this vessel was located next to the heart apex, where it anastomosed with the middle cardiac vein. Next the vein ran across the anterior interventricular groove embedded in fat. It received numerous small tributaries from both ventricles entering next the coronary sulcus, emptying finally into the coronary

sinus. In the whole material studied it received in 8 cases the left marginal vein directly. Also posterior vein of the left ventricle was not permanent tributary of the great cardiac vein — but in one heart only. We measured the caliber of the great cardiac vein next to its orifice to coronary sinus — the results varied between 2.5 and 5 mm.

Middle cardiac vein

In all hearts studied using injection and corrosion casting we found the middle cardiac vein which emptied into the coronary sinus. Its beginning was placed next to the heart apex, from which the string stem of the vein ran across the posterior interventricular groove toward coronary sinus.

Similarly to the great cardiac vein it created numerous anastomoses with neighboring veins. At the beginning it united with the great cardiac vein, next with the posterior vein of the left ventricle, and along the right side also with anterior cardiac veins. Its lumen next to the orifice into the coronary sinus measured around 2.7 ± 1.5 mm.

Small cardiac vein

The presence of the small cardiac vein was stated in all specimens studied. This relatively small vessel originated in the antero-inferior portion of the coronary sulcus. Next it ran across the right side of the coronary sulcus between the right auricle and the right ventricle, in company with the right coronary artery. Small cardiac vein in all cases studied was a tributary of the coronary sinus and emptied into its right circumference. During the course it received numerous nameless tributaries mainly from the diaphragmatic surface of the right half of the heart. In five cases it received one bigger tributary running along the right border of the heart — right marginal vein.

Posterior vein of the left ventricle

Posterior vein of the left ventricle (PVLV) might be clinically important because of its location and it may serve as a path for placing the electrode during cardiologic procedures. It is variable. This variability considered both number of vessels as well as the orifice. It was present in 77 specimens out of 80. Lack of PVLV was observed in 3 hearts (58-year old female and 40- and 64-year old male). In one heart (63-year old male) PVLV emptied into the great cardiac vein directly. In remaining cases it was a direct tributary of the coronary sinus. Its caliber varied from 2.24 to 3.48 mm. In 32 hearts we found a single PVLV. In remaining hearts it created numerous anastomoses mainly with the middle cardiac vein. It anastomosed with the left marginal vein, too. In 4 hearts we found double PVLV. In one specimen (of 48-year old male) additional vein emptied into a “bigger” PVLV, and through it into the coronary sinus. In remaining three cases (45 year old female and two of 58-year old males) both PVLV emptied into the coronary sinus directly.

Oblique vein of the left atrium

Small, but topographically important oblique vein of the left atrium was found in 78 out of 80 hearts studied. We did not find this vein in two specimens (40 and 64 year old male). The vein begun slightly below the left inferior pulmonary vein and next it ran obliquely downwards. In one heart (of 44 year old female) oblique vein of the left atrium emptied into the great cardiac vein. In remaining 77 hearts it was a direct tributary of the coronary sinus. The caliber of its orifice was 1.5 ± 0.5 mm.

Discussion

In the entire material studied we found the presence of all typical tributaries of the coronary sinus, i.e. great, middle and small cardiac veins, posterior vein of the left ventricle and oblique vein of the left atrium. We have observed the left and right marginal veins, too. Grzybiak studied 200 hearts and he observed that small cardiac vein was present only in 50%. PVLV was highly variable, and in almost half of cases it was double. He put much attention to the middle cardiac vein, considering it to be the right place for implantation of the ablation electrode. In 2.5% of cases this vein emptied into the right atrium directly, while in remaining it emptied into the coronary sinus at different angle $44\text{--}90^\circ$ [19]. Singh *et al.* postulated that the most stable point of venous coronary tree is the coronary sinus, although its tributaries are variable, what may cause difficulties during invasive procedures in this region [20]. These authors used the term anterior interventricular vein which does not exist in the *Nomina Anatomica*, although it is quite easy to find that it considers the great cardiac vein [21]. Left marginal vein was described by these authors a large vessel what is quite surprising, because it is normally minute and variable vein [22], although they confirmed variability of its orifice. In 81% it was a tributary of the great cardiac vein, and only in 19% of the coronary sinus. Besides they put attention to the fact that patients suffering from cardiomyopathy have rotated and rebuilt hearts, so it is difficult to use classical anatomical descriptions here. The frequency of the lateral and posterior tributaries of the coronary sinus was determined by Gerber *et al.* little below 50%, while the great cardiac vein was present in 90% of hearts studied [20]. New data was obtained thank to invasive procedures carried out by clinicians. Blendea *et al.* found coronary sinus in 100% of patients who undergone coronarography, they found also posterior vein of the left ventricle and the middle cardiac vein in 76% [23]. Tributaries of the coronary sinus which drain the posterior wall of the heart are main locations of electrode implantation and that is why there is no information on remaining tributaries of the coronary sinus in this publication. Studies of Mao *et al.* confirmed 100% of presence of the coronary sinus, great cardiac vein, middle cardiac vein and the posterior vein of the left ventricle [24]. They found the left marginal vein in 81% of patients studied. Similar results and conclusions were obtained by Gilard *et al.*, who found that coronary sinus, great and middle cardiac veins are the most permanent vessels of the venous coronary tree [25]. It must be taken into consideration that classical anatomical descriptions are made based on dissections, where studies are carried out on hearts which died because of diseases not related to heart disorders, and differ from hearts observed by clinicians — hearts with car-

diomyopathy, arrhythmias and insufficiency [26–28]. These differences consider mostly the frequency and size of the left marginal vein. It must be also considered the structure of the coronary sinus and its tributaries may change because of the chronic heart diseases. It may be caused by hypoxia which is found to be the strongest among proangiogenic factors — this may lead to adaptation and remodeling of the venous tree.

In our material of 80 hearts we found the great, middle and small cardiac veins in all specimens. We did not find the oblique vein of the left atrium in two cases.

In most of the studies the frequency of the great cardiac vein was estimated for 100% [19, 20, 24, 25, 29]. Kaczmarek and Czerwiński in their article found it to empty into coronary sinus in all cases. They have described in 9 out of 36 hearts connections between the middle and the great cardiac veins in the vicinity of the heart apex which created an arch surrounding the left ventricle [30]. These results are similar to our observations.

In all specimens studied we found the middle cardiac vein which emptied into the coronary sinus. We think that it should be considered as an appropriate location for electrode implantation during ablation procedures because of its frequency, permanent connection to coronary sinus and caliber. During injection we noticed that it's been the first and easiest of the vessels filled with the mass. Its clinical importance was also postulated by Grzybiak [19]. In studies by Gilard the caliber of the middle cardiac vein was similar to our results and was 2.62 ± 1.26 mm [25].

Observations on the small cardiac vein are little different from earlier studies, probably because of the number of hearts investigated. It was present in all hearts dissected and it emptied into the coronary sinus. Adachi found it in 46% of the entire material observed, having at disposal 160 hearts [22], while Grzybiak found it in 100 out of 200 hearts [19].

PVLV was a variable vessel both according to a number, size and orifice. Similar findings were confirmed by Grzybiak and Gilard [19, 25]. They described lack of this vessel, as well as double or triple form. In majority of cases it was a tributary of the coronary sinus, but sometimes it ended in the great cardiac vein. In our material lack of the PVLV was found in 3 hearts. In four specimens we observed double form. Not always it emptied into the coronary sinus — in one heart it emptied into the great cardiac vein. The caliber of the orifice varied from 2.24 to 3.48 mm. Besides it had numerous anastomoses mostly with the middle cardiac vein. It seems to be obvious that despite its variability the vein may serve as the location for invasive cardiac procedures. Similar to the middle cardiac vein, PVLV quickly filled with the injection mass during preparation of the specimens. It seems that even duplication of the vessel shouldn't be a problem during catheterization, rather opposite — it may be a facility. Clinical limitation in application of this vein is certainly its absence, but Gilard described the PVLV smaller than 2 mm (caliber) so impossible for catheterization [25].

OVLA was found in 98% of the hearts studied by Adachi [22]. A precise description of the OVLA was made by Cendrowska-Pinkosz [31]. She found this vessel in 97% of hearts studied. It was a minute branch with the length no more than 20 mm. Besides she distinguished several morphological types of the vein: tree-like, simple and branching pattern. Clinician paid attention to another aspect of its significance — this vein is located next to the orifice of the great cardiac vein where most of the invasive procedures occur [32]. In the studies based on procedures carried out during cardiologic invasions the frequency

of the OVLA was lower — since it was found in 77% of the hearts [32] and in 37 out of 51 patients [23]. In the material studied the vein of Marshall, as it is named, was found in 78 out of 89 hearts — in one heart it emptied into the great cardiac vein, in remaining cases into the coronary sinus. The caliber of its orifice was around 1.5 ± 0.5 mm.

Studying the rare tributaries of the coronary sinus Adachi found the right marginal vein in 33 out of 160 hearts studied. In 24 cases it ended in the right atrium directly, while the remaining opened into the small cardiac vein [22]. Mierzwa and Kozielc found this vein in 82%, but they studied 50 hearts only [33]. In our material the right marginal vein was present in 5 hearts only and it ended in the small cardiac vein.

Clinicians put more attention to the left marginal vein. We think that it shouldn't be assumed as a rare vessel. Mao *et al.* found it in 81% [24], Tada *et al.* in 84% [34], and Blendea *et al.* in 91% [23]. It must be considered however that all these observations were made on persons suffering from various cardiac disorders. Studies of Adachi carried out on 160 normal hearts revealed this vein in 42 out of 160 hearts observed [22]. We found left marginal vein in 9 out of 89 hearts, but only in one example it opened into the coronary sinus directly. Considering anatomical observation this vessel seems to be useless for cardiologic procedures — normally it is a minute vessel, but in insufficient hearts it changes. Artherosclerotic coronary arteries may impinge comitant veins, i.e. branches of the left coronary artery may press the great cardiac vein, causing even a reflux of the blood what in result may lead to swelling of the left marginal vein and other tributaries [7]. Macroscopic analysis showed numerous anastomoses between the great and middle cardiac veins at the heart apex, also with the PVLV and anterior cardiac veins. PVLV has anastomoses with the left marginal vein as well. Ratajczyk-Pakalska described arterio-venous anastomoses predominantly in the left ventricle and interventricular septum. It must be emphasized that such connections were seen in hearts where arteries were sclerotic [35–38]. It is possible that this natural ability of creation of the anastomoses by the tributaries of the coronary sinus is an alternative way of flow of blood from the heart during cardiac insufficiency.

Some clinicians do not select the coronary sinus willingly as a place of invasive procedures considering numerous complications [39–41]. Location of the orifice of the coronary sinus may be difficult, its opening may be relatively small, what makes catheterization relatively difficult or even impossible. Perforation of the coronary sinus isn't so rare. A special challenge for cardiologists is so called “bald” coronary sinus (no tributaries) or generally the variability of the venous coronary tree. It is mostly thought that implantation of the electrode is most convenient along the margin of the heart — that is why so big interest is put onto the left marginal vein [41]. In some studies [20, 42] the middle cardiac vein is supposed to be the location which guarantees the success of the procedure. It seems also that PVLV is easy accessible for catheterization [41].

Conflict of interest

None declared.

References

1. Nitta T.: Anatomy and ablation of the coronary sinus and the mitral valve annulus. *Nihon Geka Gakkai Zasshi*. 2015; 116 (1): 62–63.
2. Aiello V.D., Ferreira F.C., Scanavacca M.I., Anderson R.H., D'Avila A.: The morphology of the coronary sinus in patients with congenitally corrected transposition: implications for cardiac catheterisation and re-synchronisation therapy. *Cardiol Young*. 2015; 3: 1–6.
3. Krešáková L., Purzyc H., Schusterová I., Fulton B., Maloveská M., Vdoviaková K., Kravcová Z., Boldižár M.: Variability in the cardiac venous system of Wistar rats. *J Am Assoc Lab Anim Sci*. 2015; 54 (1): 10–16.
4. Hilbert S., Kosiuk J., John S., Hindricks G., Bollmann A.: A guide to the porcine anatomy for the interventional electrophysiologist. Fluoroscopy and high density electroanatomical mapping. *J Cardiovasc Transl Res*. 2015; 8 (1): 67–75.
5. Młynarski R., Młynarska A., Sosnowski M.: Coronary venous system in cardiac computer tomography: Visualization, classification and role. *World J Radiol*. 2014; 28, 6 (7): 399–408.
6. Ibrahim W.G., El Khouli R.H., Abd-Elmoniem K.Z., Matta J.R., McAreavey D., Gharib A.M.: Optimization of free-breathing whole-heart 3-dimensional cardiac magnetic resonance imaging at 3 tesla to identify coronary vein anatomy and to compare with multidetector computed tomography. *J Comput Assist Tomogr*. 2014; 38 (6): 941–948.
7. von Lüdinghausen M.: Clinical anatomy of cardiac veins, Vv. cordiacae. *Surg Radiol Anat*. 1987; 9 (2): 159–168.
8. Cendrowska-Pinkosz M.: The variability of the small cardiac vein in the adult human heart *Folia Morphol*. 2004; 63 (2): 159–162.
9. Spencer J.H., Sundaram C.C., Iaizzo P.A.: The relative anatomy of the coronary arterial and venous systems: implications for coronary interventions. *Clin Anat*. 2014; 27 (7): 1023–1029.
10. Duda B., Grzybiak M.: Main tributaries of the coronary sinus in the adult human heart. *Folia Morphol*. 1998; 57 (4): 363–369.
11. Kaczmarek M., Czerwiński F.: Assessment of the course of the great cardiac vein in a selected number of human hearts. *Folia Morphol*. 2001; 60 (4): 293–296.
12. Ortale J.R., Gabriel E.A., Iost C., Márquez C.Q.: The anatomy of the coronary sinus and its tributaries. *Surg Radiol Anat*. 2001; 23 (1): 15–21.
13. Christiaens L., Ardilouze P., Ragot S., Mergy J., Allal J.: Prospective evaluation of the anatomy of the coronary venous system using multidetector row computed tomography. *Int J Cardiol*. 2008; 126 (2): 204–208.
14. Fukushima T.: Morphological study of cardiac veins that drain into the coronary sinus, with special reference to the coronary artery dominant pattern. *Nihon Ika Daigaku Zasshi*. 1995; 62 (5): 482–500.
15. Konerding M.A., Miodonski A.J., Lametschwandtner A.: Microvascular corrosion casting in the study of tumor vascularity: a review. *Scanning Microsc*. 1995; 9 (4): 1233–1243.
16. Pityński K., Litwin J.A., Nowogrodzka-Zagórska M., Miodoński A.J.: Vascular architecture of the human fetal adrenal gland: a SEM study of corrosion casts. *Ann Anat*. 1996; 178 (3): 215–222.
17. Banya Y., Ushiki T., Takagane H., Aoki H., Kubo T., Ohhori T., Ide C.: Two circulatory routes within the human corpus cavernosum penis: a scanning electron microscopic study of corrosion casts. *J Urol*. 1989; 142 (3): 879–883.
18. Walocha J.A., Szczepański W., Miodoński A.J., Gorczyca J., Skrzat J., Bereza T., Ceranowicz P., Lorkowski J., Stachura J.: Application of acrylic emulsion Liquitex R (Binney and Smith) for the preparation of injection specimens and immunohistochemical studies-an observation. *Folia Morphol (Warsz)*. 2003; 62 (2): 157–161.
19. Grzybiak M.: Morphology of the coronary sinus and contemporary cardiac electrophysiology. *Folia Morph (Warsz)*. 1996; 55: 272–273.
20. Singh J.P., Houser S., Heist K., Ruskin J.: The coronary venous anatomy. *J Amer Coll Cardiol*. 2005; 1: 68–74.

21. Aleksandrowicz R., Gołąb B., Narkiewicz O.: Mianownictwo Anatomiczne. PZWL, Warszawa, 1989.
22. Adachi B.: Das Venensystem der Japaner. Druckanstalt Kenkyusha, Tokyo, 1933; 41–64.
23. Blendea D., Shah R.V., Auricchio A., Namdigam V., Orencole M., Heist E.K., Reddy V.Y., Mc Pherson C.A., Ruskin J.N., Singh J.P.: Variability of coronary venous anatomy in patients undergoing cardiac resynchronization therapy: a high-speed rotational venography study. *Heart Rhythm*. 2007; 49: 1155–1162.
24. Mao S., Shinbane J.S., Girsky M.J., Child J., Carson S., Oudiz R.J., Budoff M.J.: Coronary venous imaging with electron beam computed tomographic angiography: three-dimensional mapping and relationship with coronary arteries. *Am Heart J*. 2005; 150: 315–322.
25. Gilard M., Mansourati J., Etienne Y., Larlet J.M., Troung B., Boschat J., Blanc J.J.: Angiographic anatomy of the coronary sinus and its tributaries. *Pacing Clin Electrophysiol*. 1998; 21: 2280–2284.
26. Lu Dinghausen M.: Clinical anatomy of cardiac veins. *Surg Radiol Anat*. 1987; 9: 156–168.
27. Otrale J.R., Gabriel E.A., Rost C., Marquez C.Q.: The anatomy of coronary sinus and its tributaries. *Surg Radiol Anat*. 2001; 23: 15–21.
28. Silver M.A., Rowley N.E.: The functional anatomy of the human coronary sinus. *Am Heart J*. 1988; 115: 1080–1083.
29. Cendrowska-Pinkosz M., Burdan F., Bełżek A.: Variation in morphology of the valve of the great cardiac vein in the human hearts. *Ann Univer Mariae Curie-Skłodowska Lublin*. 2004; 33: 189–192.
30. Kaczmarek M., Czerwiński F.: Assessment of the course of the great cardiac vein in selected number of the human hearts. *Folia Morph (Warsz.)*. 2007; 66: 190–193.
31. Cendrowska-Pinkosz M., Urbanowicz Z.: Analysis of the course and ostium of the oblique vein of the left atrium. *Folia Morph (Warsz.)*. 2000; 59: 163–165.
32. de Oliveira I.M., Scanavacca M.I., Correia A.T., Sosa E.A., Aiello V.D.: Anatomic relations of the Marshall vein: importance for catheterization of the coronary sinus in ablation procedures. *Europace*. 2007; 10: 915–919.
33. Mierzwa J., Koziolec T.: Variation of the anterior cardiac veins and their orifices in the right atrium in man. *Folia Morph (Warsz.)*. 1975; 34: 125–132.
34. Tada H., Kurosaki K., Naito S., Koyama K., Itoi K., Ito S., Ueda M., Shinbo G.: Three-dimensional visualization of the coronary venous system using multidetector row computed tomography. *Circ J*. 2005; 2: 165–170.
35. Ratajczyk-Pakalska E.: Veins of the interventricular septum in the human heart. *Folia Morph (Warsz.)*. 1973; 3: 331–338.
36. Ratajczyk-Pakalska E.: Arteriovenous anastomoses in the human myocardium. *Folia Morph (Warsz.)*. 1975; 3: 285–292.
37. Ratajczyk-Pakalska E.: Blood vessels supplying the left-ventricular cardiac muscle in man. *Folia Morph (Warsz.)*. 1977; 36: 99–106.
38. Zieliński K., Koktyś R.: An analysis of the extramuscular branches of the coronary arteries in the relation to size and weight of heart. *Folia Morph (Warsz.)*. 1989; 48: 157–164.
39. Kutarski A., Wójcik M., Oleszczak K.: Optymalna konfiguracja elektrod dla stałej stymulacji dwuprzedsionkowej. *Folia Cardiol*. 2001; 8: 41–60.
40. Langberg J.L., Kim Y.N., Goyal R., Kou W., Calkins H., Sousa J., El-Atasi R., Morday F.: Conversion of typical to atypical atrioventricular nodal reentrant tachycardia after radiofrequency catheter modification of the atrioventricular junction. *Am J Cardiol*. 1992; 69: 503–508.
41. Lewicka-Nowak E., Sterliński M., Dąbrowska-Kugacka A., Maciąg A.: Problemy i niepowodzenia związane ze stosowaniem stymulacji dwukomorowej u pacjentów z zaawansowaną niewydolnością serca. *Cardiol J*. 2005; 5: 343–348.
42. Kozłowski D., Koźluk E., Grzybiak M., Adamowicz M.: Morfologia części dystalnej zatoki wieńcowej i jej znaczenie kliniczne. *Kardiologia Pol*. 1995; 43: 304–307.