

FOLIA MEDICA CRACOVIENSIA
Vol. LV, 3, 2015: 5–13
PL ISSN 0015-5616

Morphometric parameters of human coronary sinus — based on study of 80 human hearts

BRYGIDA WANDZEL-LOCH¹, MAŁGORZATA MAZUR², KLAUDIA WALOCHA²,
MARCIN KUNIEWICZ², MONIKA KONARSKA², TOMASZ BEREZA², ALEKSANDRA KUCHARSKA²

¹Klinika Kardiologii, 5 Wojskowy Szpital Kliniczny z Polikliniką w Krakowie
ul. Wroclawska 1–3, 30-901 Kraków, Poland

²Department of Anatomy, Jagiellonian University Medical College
ul. Kopernika 12, 31-034 Kraków, Poland

Corresponding author: Małgorzata Mazur MD, PhD, Department of Anatomy, Jagiellonian University Medical College
ul. Kopernika 12, 31-034 Kraków, Poland; Phone/fax +48 12 422 95 11; E-mail: mazurmalg@poczta.onet.pl

Abstract: The study was carried out on 80 human hearts (64 male and 16 female). The whole material has been divided into 4 groups: I — aged 19–40; II — aged 41–50; III — aged 51–60 and IV — aged 61–70. The venous vascular bed of 80 hearts was injected through the coronary sinus with Duracryl plus (Spora Dental, Czech Republic) and next corroded. Thus obtained specimens were measured using electronic caliper (MAU-a E 0-150, Horex, Poland). The length of the coronary sinus varied from 15–50 mm (with the mean value of 30 mm in male hearts and 25 mm in female hearts). The caliber of the vessels varied from 7–13 mm. The length of the coronary sinus is not age-dependent, however it is longer in male than female hearts. Generally the caliber of male coronary sinus is bigger than in the female, although it isn't statistically significant.

Key words: coronary sinus, anatomy, corrosion casting, morphology.

Introduction

Coronary sinus acts recently as one of the main paths through which electrocardiologists may perform complicated cardiac procedures. It empties into right atrium of the heart directly. Proper positioning of the orifice of this vessel is especially important, since it may decrease the number of unhappy events during cardiac catheterization [1–4]. Multiple variations considering both structure, location and course of the vessel and its tributaries may be advantages for specialists on intervention cardiology. The study describes the main

morphological parameters of the coronary sinus, based on measurements carried out on obtained corrosion casts.

Material and methods

80 human hearts were obtained from 16 female and 64 male cadavers aged 19–70 years. The whole material has been divided into 4 age groups > Group I included hearts of individuals aged 19–40 years; group II — 41–50 years; group III — 51–60 years and group IV — 61–70 years. The distribution is presented in Table 1:

Table 1. Distribution of age groups.

Age	Number	Percentage
17–40	16	20.00
41–50	24	30.00
51–60	28	35.00
61–70	12	15.00
Total	80	100.00

The hearts were washed in running tap water to remove clots and next injected with saline (0,9% solution of NaCl — Baxter Terpol, Poland) at room temperature. Also the cardiac veins were simultaneously washed.

To measure the coronary sinus (the length and the width), the connective and fat tissues were removed to expose the vessel. The length was evaluated using electronic caliper. The beginning of the vessel was considered to be at the junction of the oblique vein of the left atrium into coronary sinus, while the end was at the orifice of the coronary sinus in the right atrium. Also using electronic caliper we measured the width of the coronary sinus in the middle of its course.

To obtain 3-D cast of cardiac venous tree, the specimens were injected with acrylic mass (Duracryl plus (Spofa Dental, Czech Republic), dyed with blue ink, through the orifice of the coronary sinus, filling this vessel and its tributaries. Thus obtained specimens were washed in running tap water and corroded in 10% solution of potassium hydroxide. Corrosion process last about 3 weeks. Next the specimens were washed again in distilled water. The remnants of the tissues were removed in a 3% solution of trichloroacetic acid. Next the casts were analyzed and documented. Statistical analysis was based on Kruskal-Wallis test, t-student test, Mann-Whitney test, Spearman test.

Results

In all 80 hearts the coronary sinus was found and it emptied into the right atrium of the heart. The vessel was located within posterior part of the coronary sulcus, between left ventricle and the left atrium.

Using electronic caliper the length of the coronary sinus was measured, assuming that it is the distance between the orifice of the oblique vein of the left atrium into coronary sinus and the orifice of the coronary sinus into the right atrium of the heart. In 78 specimens the beginning of the coronary sinus was seen evidently, as a significant dilatation of the vessel comparing to the great cardiac vein. In two hearts (one male aged 38 and one female aged 45) it was difficult to establish the beginning of the coronary sinus, since the dilatation was absent. In these cases the orifice of the oblique vein of the left atrium was decisive.

The length of the coronary sinus measured from the orifice of the oblique vein of the left atrium until the orifice into the right atrium varied from 15 mm (minimal length) to 50 mm (maximal length). In all age groups the shortest coronary sinus measured 15 mm. The longest coronary sinus was found in the III group (50 mm); in the group I and II it was equal and measured 37 mm; in group IV it was 46 mm (Table 2).

Table 2. Length of the coronary sinus in particular age groups.

Age (years)	N important	Mean value	Minimum	Maximum	Standard deviation
17–40	16	27.94	15.00	37.00	5.95
41–50	24	28.54	15.00	37.00	5.99
51–60	28	30.14	15.00	50.00	9.18
61–70	12	30.17	15.00	46.00	10.78

The mean value of the length of the coronary sinus in particular age groups was similar and varied from 28–30 mm.

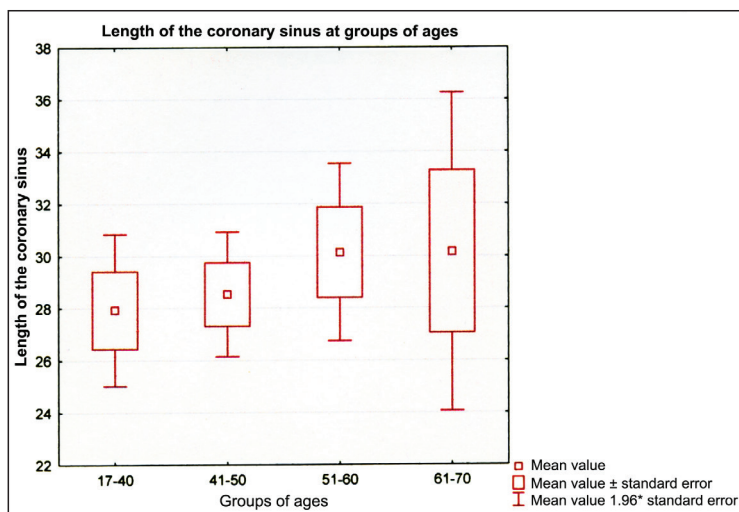


Fig. 1. Mean length of the coronary sinus in age groups.

In majority of the hearts studied (14 specimens) the coronary sinus measured 25 mm. Only in one heart the length was 44 mm. The longest vessels was found in two male hearts — 50 mm.

We analyzed the length of the coronary sinuses considering the sex: in male hearts the length of the vessel varied from 15–50 mm, while in female hearts it measured 15–37 mm respectively (Table 3).

Table 3. The length of the coronary sinus considering the sex.

Sex	N important	Mean value	Minimum	Maximum	Standard deviation
Male	64	30.17	15.00	50.00	8.05
Female	16	25.44	15.00	37.00	6.39

The mean length of the coronary sinus in males was 30 mm, while in females it was 25 mm (Fig. 2).

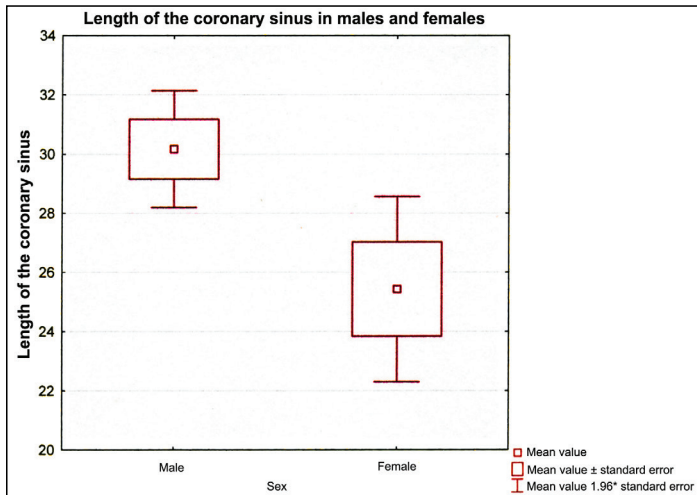


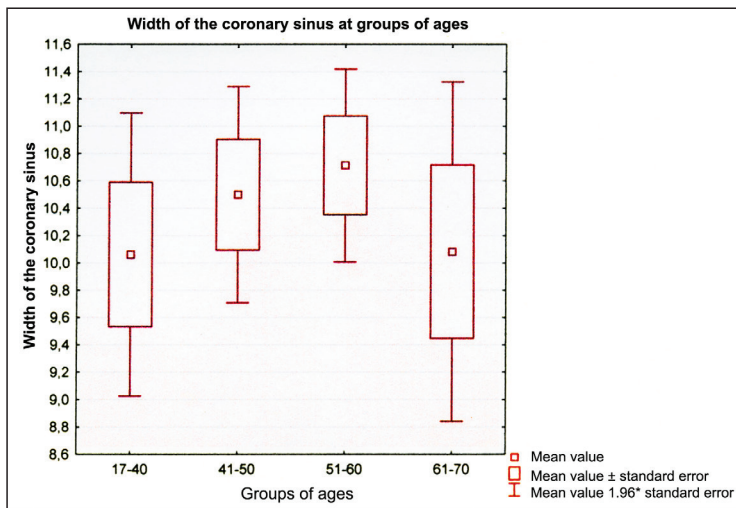
Fig. 2. The mean length of the coronary sinus in males and females.

To study the relevance of the differences between the length of the coronary sinus in females and males we applied t-student test for independent variables. Its result ($p = 0.0320$) indicates that differences are statistically significant. In the males the coronary sinus is significantly longer than in the females.

The width of the coronary sinus was measured in the midlength. The results varied from 7 to 13 mm. The most frequent (18 hearts — 16 male and 2 female) caliber was 10 mm. The results of measurements are presented in Table 4.

Table 4. The width of the coronary sinus in particular age groups.

Age (years)	N important	Mean value	Minimum	Maximum	Standard deviation
17–40	16	10.06	7.00	13.00	2.11
41–50	24	10.50	7.00	13.00	1.98
51–60	28	10.71	7.00	13.00	1.90
61–70	12	10.08	7.00	13.00	2.19

**Fig. 3.** Relationship between the mean width of the coronary sinus and age of individuals.

The width of the coronary sinus was included into the frames between 7 and 13 mm, although the mean width in male hearts was slightly bigger (10.45 mm), while in females it measured 10.31 mm (Table 5).

Table 5. The width of the coronary sinus in male and female hearts.

Sex	N important	Mean value	Minimum	Maximum	Standard deviation
Male	64	10.45	7.00	13.00	1.93
Female	16	10.31	7.00	13.00	2.30

Thus obtained results were next analyzed, to study the differences in the mean length of the coronary sinus in particular age groups, using Kruskal-Wallis test. Its results indicate lack of differences statistically important considered to the mediana of the length of the coronary sinuses ($p = 0.8910$). Medianae in the following age groups are: group I, II and

III — 28; IV — 28.5. This is why one can state that the length of the coronary sinus is independent on the age.

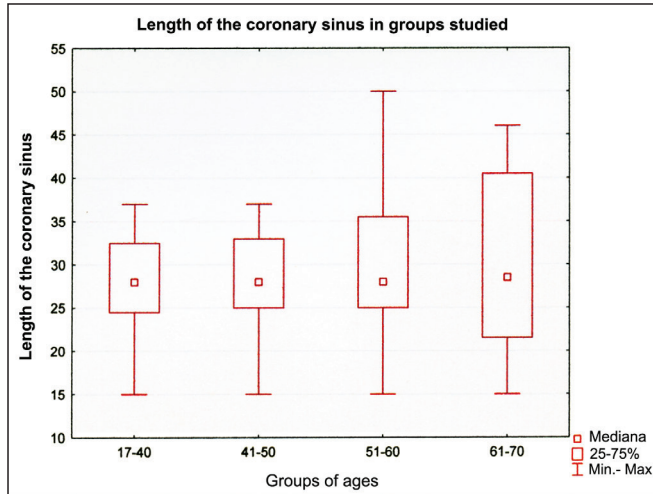


Fig. 4. Medianae of the length of coronary sinuses in groups studied.

The study of the mean width of the coronary sinuses in different age groups was carried out using Kruskal-Wallis test — its result ($p = 0.7271$) indicates lack of statistically significant differences in the medianane of the width of coronary sinus : in group I and IV — 10; in group III — 10.5; and in group II — 11.

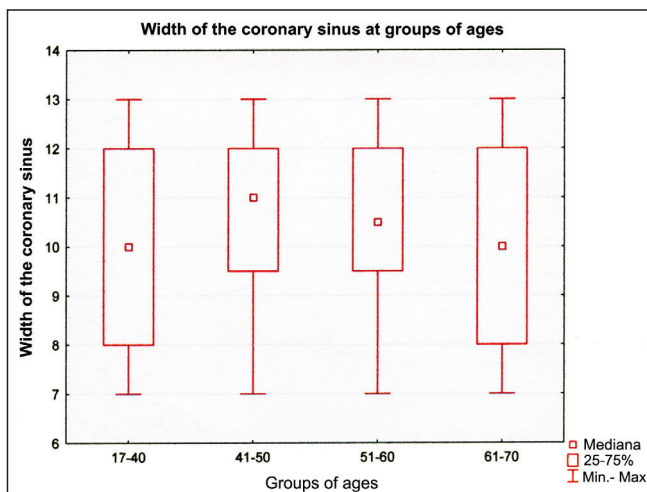


Fig. 5. The width of the coronary sinus in groups studies (medianae).

To study the relevance of the differences between the width of the coronary sinuses in the males and females we used Mann-Whitney test. Its result ($p = 0.9233$) indicates lack of statistical significance of the differences between width of male and female coronary sinuses.

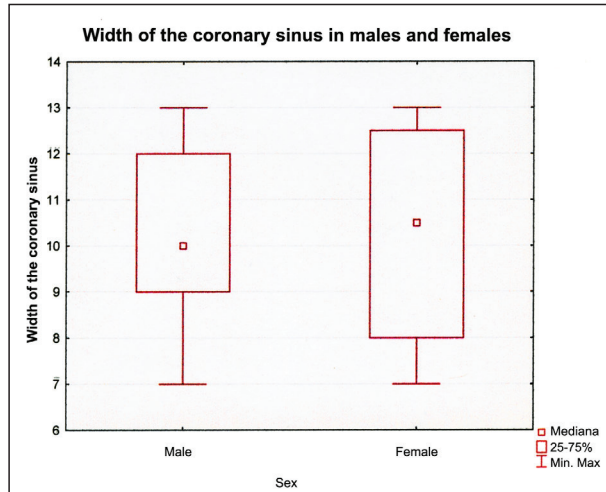


Fig. 6. The width of the female and male coronary sinuses (medianae).

We tried to calculate the dependency between the length and the width of the coronary sinus, using Spearman rank correlation factor. Based on the results we established relatively strong correlation between the length and the width of the coronary sinus. This dependency is positive, what means that increase of one of the features causes increase of another one ($R = 0.4625$, $p = 0.0000$) — Fig. 7.

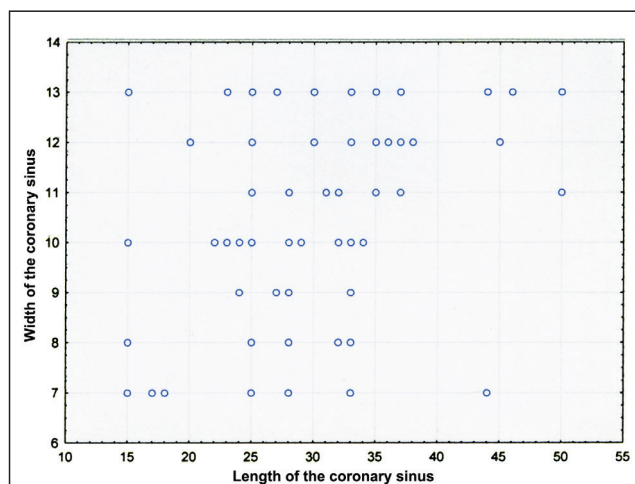


Fig. 7. Width and length of the coronary sinus.

Discussion

In the literature quite different descriptions of the coronary sinus were found. Based on the study of 160 hearts, Adachi found coronary sinus emptying into the right atrium of the heart in all cases studied [5]. Also studies carried out on 200 human hearts aged 18–97 by Grzybiak proved that coronary sinus was a single vessel [6]. The coronary sinus did not always open into right atrium. Ratajczyk-Pakalska *et al.* described abnormal opening of the coronary sinus into the left atrium in 39-year old female. This anomaly was accompanied by abnormal course of the great cardiac vein. This malformation did not disturb heart action and were disclosed accidentally during autopsy, while the death was caused by car accident [7]. Our knowledge on the coronary sinus is enriched by observation made during invasive procedures on hearts. During an implantation of electrodes for biventricular stimulation Anh *et al.* found coronary sinus in 98 out of 100 patients [8]. In 2 patients they did not manage to visualize the vessel. Donal *et al.* and Luik *et al.* described three cases of coronary sinus atresia in patients subjected to ablation. Catheterization was ineffective and the cause was the blockage of the vessel. The venous flow occurred through the persistent left superior vena cava [9, 10]. Yamada *et al.* found double coronary sinus in 48-year old female [11]. Interesting are the studies of Blendea *et al.* who found coronary sinus in 100% of studied hearts, but noticed that it is bigger in males than in females, both in patients with coronary and cardiac insufficiency, more than in patients suffering from cardiomyopathy [12]. It seems also that diseases affecting the arterial blood supply may have influence on venous coronary tree.

In our material, consisted of 80 hearts, we found coronary sinus in all cases studied. It was placed in the posterior fragment of the coronary sulcus, enveloped by connective (fat) tissue. In all cases it emptied into the right atrium of the heart. It is interesting however that different anomalies of the coronary sinus are predominantly found in individuals subjected to invasive cardiologic procedures. It doesn't seem to be a rule however since this malformations are usually clinically asymptomatic [13].

There are some controversies regarded to designation of the beginning and the end of the vessel. Adachi [5] initially established the border between the great cardiac vein and the coronary sinus based on the caliber of these two vessels. He found that in 33% of studied hearts the caliber of coronary sinus was bigger than that of the great cardiac vein, but only in 3% the difference was large enough to serve as orientation point. This is why he accepted that the length of the coronary sinus will be measured from the orifice of the oblique vein of the left atrium until the orifice of the coronary sinus into the right atrium of the heart. Thus measured coronary sinus varied in length from 5 to 45 mm [5]. Koźluk *et al.* accepted that length of the coronary sinus is the distance between two points: one is the orifice of the left marginal vein into the great cardiac vein and the second is the orifice of the coronary sinus into the right atrium. His results varied from 26–93 mm [14]. In our study we accepted Adachi's criteria, since the presence of the left marginal vein is not confirmed in all hearts. Our results varied from 15–50 mm so they were similar to other results [5, 14, 15]. The width of the coronary sinus measured in the middle of the vessel agreed with Blendea's observation [12].

Conclusions

The length of the coronary sinus is independent on the age, but males have statistically longer vessels than females, so the parameter is sex-dependent. Probably this is a result of a trend of generally bigger male hearts than female. The width of the coronary sinus is both age- and sex-independent. A strong correlation between length and the width of the vessels was shown. The longer coronary sinus is, the wider it is. It seemed that males should have wider coronary sinus than females — and this is truth, however differences in the width of the vessels are not so well visible as seen concerning the length, and for this reason they are statistically insignificant.

Conflict of interest

None declared.

References

1. Swartz J., Tracy C., Fletcher R.: Radiofrequency endocardial catheter ablation of accessory atrioventricular pathway atrial insertion sites. *Circ.* 1993; 87: 487–499.
2. Taka-aki M., Hatsue I., Yoshiko I., Yuko Y.: The positional relationship between the coronary sinus musculature and the atrioventricular septal junction. *Europace.* 2010; 12: 719–725.
3. Tracy C., Swartz J., Fletcher R., Wetson L., Soloman A., Karasik K.: Atrial endocardial radiofrequency ablation of accessory pathways. *J Am Coll Cardiol.* 1991; 17: 368–368.
4. Van de Vire N.R., Schuijff J.D., Bleeker G.B., Schaliq M.J., Bax J.J.: Magnetic resonance imaging and computed tomography in assessing cardiac veins and scar tissue. *Europace.* 2008; 10: 110–113.
5. Adachi B.: *Das Venensystem der Japaner.* Druckanstalt Kenkyusha, Tokyo, 1933; 41–64.
6. Grzybiak M.: Morphology of the coronary sinus and contemporary cardiac electrophysiology. *Folia Morph (Warsz.).* 1996; 55: 272–273.
7. Ratajczyk-Pakalska E., Bloch P., Kulig A.: Termination of the coronary sinus in the left atrium *Folia Morph (Warsz.).* 1980; 48: 151–155.
8. Anh D.J., Eversull C.S., Chen H.A., Mofrad P., Mourlas N.J., Mead R.H., Zei P.C., Hsia H.H., Wang P.J., Al-Ahmad A.: Characterization of human coronary sinus valves by direct visualization during biven-tricular pacemaker implantation. *Pacing Clin Electrophysiol.* 2008; 1: 78–82.
9. Donal E., de Chillou C., Magnin-Poull I., Leclercq C.: Imaging in cardiac resynchronization therapy: what does the clinical need? *Europace.* 2008; 3: 70–72.
10. Luik A., Deisenhofer I., Estner H., Ndrepepa G., Pflaumer A., Zrenner B., Schmitt C.: Atresia of the coronary sinus in patients with supraventricular tachycardia. *Pacing Clin Electrophysiol.* 2006; 29: 171–174.
11. Yamada T., McElderry H.T., Plumb V.J., Doppalapudi H., Epstein A.E.: Duplicated coronary sinus with a connecting branch. *Europace.* 2008; 7: 880–889.
12. Blendea D., Shah R.V., Auricchio A., Namdigam V., Orencole M., Heist E.K., Reddy V.Y., Mc Pherson C.A., Ruskin J.N., Singh J.P.: Variability of coronary venous anatomy in patients undergoing cardiac resynchro-nization therapy: a high-speed rotational venography study. *Heart Rhythm.* 2007; 49: 1155–1162.
13. Chou M.C., Wu M.T., Chen C.H., Lee M.H., Tzeng W.S.: Multidetector CT findings of a congenital coronary sinus anomaly: a report of two cases. *Korean J Radiol.* 2008; 9: 1–6.
14. Koźluk E., Koźlowski D., Adamowicz M., Walczak E.: Coronary sinus topography and its dependency from weight and diameters of the heart. *Pace.* 1995; 18: 2–5.
15. Loukas M., Bilinsky S., Bilinsky E., el-Sedfy A., Anderson R.H.: Cardiac veins: a review of the literature. *Clin Anat.* 2009; 22 (1): 129–145.