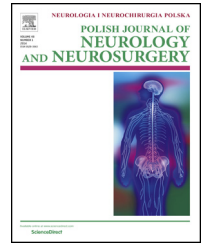


Available online at www.sciencedirect.com

ScienceDirect

journal homepage: <http://www.elsevier.com/locate/pjnns>

Case report

Neurological presentation of hemophagocytic lymphohistiocytosis

Żur-Wyrozumska Kamila ^{a,*}, Rog Teresa ^a, Mensah-Glanowska Patrycja ^b,
Szczudlik Andrzej ^a

^aDepartment of Neurology, Jagiellonian University Medical College, Krakow, Poland

^bDepartment of Hematology, Jagiellonian University Medical College, Krakow, Poland

ARTICLE INFO

Article history:

Received 4 March 2014

Accepted 3 July 2015

Available online 28 July 2015

Keywords:

Hemophagocytic

lymphohistiocytosis

Epstein-Barr virus infection

Polyneuropathy

ABSTRACT

Hemophagocytic lymphohistiocytosis (HLH) is an inflammatory disorder arising from defects in critical regulatory pathways responsible for termination of inflammatory response.

We are presenting a case report of a 20-year-old male, admitted to the Department of Neurology because of left lower limb weakness and balance disturbances. After a few days of hospitalization, fever occurred. Laboratory tests revealed anemia, neutropenia, lymphopenia, and thrombocytopenia. The clinical course and laboratory tests results confirmed the diagnosis of HLH. In our opinion, the disorder in the presented case occurred due to severe chronic active Epstein-Barr virus infection syndrome. We are presenting the case of pure neurological onset of hemophagocytic lymphohistiocytosis in an adult patient.

Hemophagocytic lymphohistiocytosis, initially presenting with neurological symptoms, can occur in adult patients with irrelevant family history. It is a life-threatening but potentially curable condition requiring proper diagnostic and treatment management.

© 2015 Polish Neurological Society. Published by Elsevier Sp. z o.o. All rights reserved.

1. Introduction

Hemophagocytic lymphohistiocytosis (HLH) is an inflammatory disorder arising from defects in critical regulatory pathways responsible for termination of inflammatory response. The disease leads to a multisystem inflammation and organ infiltration. HLH is a rare disorder affecting mostly young children, but also occurs in adult patients with an incidence proportion estimated at approximately 1/1,000,000/per year

[1]. Neurological onset may be observed in up to 20% of the cases in children [2]. HLH is a medical condition of immediate death risk.

2. Case report

A 20-year-old male with irrelevant family history was admitted to the Department of Neurology University Hospital in Krakow because of left lower limb weakness and balance

* Corresponding author at: Department of Neurology, Jagiellonian University Medical College, ul. Botaniczna, 31-503 Krakow, Poland. Tel.: +48 93 57 77 67; fax: +48 12 24 86 26.

E-mail address: kamilaanna@op.pl (&.-W. Kamila).

<http://dx.doi.org/10.1016/j.pjnns.2015.07.001>

0028-3843/© 2015 Polish Neurological Society. Published by Elsevier Sp. z o.o. All rights reserved.

disturbances. 22 months before the onset of the symptoms, he underwent mononucleosis. A neurological examination of the right lower limb paresis revealed ataxia of lower limbs, proprioceptive disturbances in the right lower limb up to the ankle joint and a positive Romberg's test. Initial laboratory tests results did not show any abnormalities.

The brain MRI indicated hyperintensity in subcortical nuclei of the left hemisphere and in the matter next to the anterior horn of the right ventricle.

Following a few days of hospitalization, the patient developed fever of up to 40 °C. Laboratory tests (Table 1) revealed anemia, neutropenia, lymphopenia, thrombocytopenia and subsequent thrombocytosis of $937 \times 10^3/\mu\text{L}$, hypertriglyceridemia, high ferritin level and hyponatremia. Additionally, there were decreased levels of natural killer (NK) cells activity (1%), increased levels of liver enzymes, lactate dehydrogenase (LDH) and D-Dimers. In physical examination, hepatosplenomegaly was noted.

Cerebrospinal fluid examination revealed the following results: protein 83 mg/dL (20–40 mg/dL), cytos 23/3; glucose 2.8 (2.2–4.16 mM/L); EBV DNA 1400 copies/ μL ; serum IgG antibodies against Epstein-Barr virus (EBV) (EBV anti VCA/EA IgG TV index 4.29 and EBV anti EBNA IgG TV index 4.49), but IgM were absent. In the electromyography and the electro-neurography, attitudes of sensory-motor demyelinating peripheral polyneuropathy were described. The diagnosis of chronic EBV infection was determined.

On the 12th day of hospitalization, a massive nasal hemorrhage occurred and subsequent 20-min episodes of biocular blindness. The brain MRI performed the following day revealed no additional abnormalities.

Based on the clinical course and laboratory tests results, the diagnosis of HLH according to HLH criteria established by the HLH Study Group of the Histiocyte Society was made [1,7]. HLH in the presented case was, in our opinion, induced by severe chronic active EBV infection syndrome (SCAEBV). Bone marrow aspiration has shown histiomonocytoid cells. The treatment with cyclosporine, etoposide and dexamethasone, as prescribed in the HLH 2004 protocol, was administrated [7]. The patient was discharged from our department in a good state, with no abnormalities in laboratory results, and distal weakness of lower right limb. He was sent to the Hematological Department for further treatment.

3. Discussion

We are reporting the case of the pure neurological onset of hemophagocytic lymphohistiocytosis secondary to severe chronic active EBV infection syndrome in an adult patient.

The HLH encompasses the inherited hemophagocytic lymphohistiocytosis affecting young children and secondary HLH associated with infections (predominantly EBV), auto-immunological disease (juvenile arthritis) and malignancies [1]. In a study reported by Park et al., secondary HLH in adults was 69.6% caused by EBV infection [3]. Mutation in the perforin gene was the underlying cause of the disease in 20–40% of familial HLH. Clinical presentation includes high fever, hepatosplenomegaly, lymphadenopathy, cytopenia, hypertriglyceridemia, hypofibrinogenemia, hemofagocytosis and hyponatremia. The pathogenesis of the disease is due to impairment in natural killer and cytotoxic T-lymphocyte cellular cytotoxicity. It is associated with an accumulation of non-malignant macrophages (histiocytes) and T-lymphocytes in lymph nodes, spleen, liver and other organs. Hemophagocytosis is a classical finding but not always demonstrated [1,2].

Diagnostic criteria were established by the Histiocyte Society. According to HLH-2004 protocol of the Histiocyte Society, the condition can be successfully controlled with a combination of etoposide, dexamethasone, and cyclosporine A [2].

The Epstein-Barr virus infection causes a wide range of immunological disorders. Severe chronic active EBV infection syndrome is a serious form of this infection that shows severe clinical and hematological features associated with high antibody titers to EBV-related antigens. The SCAEBV infection syndrome has a high mortality rate, estimated at up to 40%, because of life-threatening complications such as hemophagocytic lymphohistiocytosis. B-cells are the general site of the EBV infection. During persisted infection, virus infects T cells and natural killer cells, leading to hypercytokinemia [4].

Neurological symptoms and signs may be extremely variable and include seizures, irritability, cranial nerve palsies, ataxia, hemiplegia or tetraplegia and coma [1,2]. The study conducted by Horne et al. suggests that 63% of patients with HLH have neurological symptoms and/or abnormal CSF findings at the time of diagnosis. Additionally, children with abnormal CSF and neurological symptoms fared worse with higher incidence of neurological sequelae in long-term survivors and increased risk of mortality. Abnormal CSF bears

Table 1 – Laboratory results.

Parameter	Result	Unit	Reference range
RBC	3.05	10^6 L^{-1}	4.5–6.5
Hb	8.1	g/L	12–17
Htc	23.4	%	40.0–54.0
Neu	0.8	$10^3/\mu\text{L}$	2.4–7.0
Lymph	0.4	$10^3/\mu\text{L}$	0.8–4.0
PLT	50	$10^3/\mu\text{L}$	125–340
TG	3.3	mM/L	<2.26
Sodium	127	mM/L	136–145
Ferritin	1909	$\mu\text{g/L}$	30–400
ALT	57	U/L	10–41
AST	143	U/L	10–37
LDH	2798	U/L	240–480
CPK	72	U/L	0–190
INR	1.49		0.8–1.2
PT	16.8	seconds	10–14
Fibrinogen	5.0	g/L	1.8–3.5
D-Dimers	>35.2	mg/L	<0.5
CRP	160	mg/L	<5

Abbreviations: RBC – red blood cells; Hb – hemoglobin; Htc – hematocrit; Neu – neutrophils; Lymph – lymphocytes; PLT – platelets; TG – triglycerides; ALT – alanine aminotransferase; AST – aspartate aminotransferase; ALP – alkaline phosphatase; LDH – lactate dehydrogenase; CPK – creatine phosphokinase; INR – international normalized ratio; PT – prothrombin time; CRP – c-reactive protein.

a significant, independent adverse prognostic value with regard to late sequelae and mortality [2].

HLH can lead to demyelinating peripheral polyneuropathy due to the entry of macrophages into Schwann cell cytoplasm with dissociation of myelin sheaths [5]. The central nervous system may be involved to diffuse infiltration of leptomeninges by lymphocytes and histiocyte in early stage of advances. In more severe involvement, infiltration extends into the perivascular spaces. In advanced stages, massive tissue infiltration may follow, particularly affecting the white matter, and may result in perifocal gliosis, areas of necrosis and demyelination [2,6]. Shinoda et al. has reported a case of HLH limited to CNS without the involvement of other systemic organs or inflammatory response [6].

Without treatment, the disease is fatal in 100% of cases. For HLH associated with EBV infection treated with HLH-2004 protocol, overall survival rates is 55–78% [2,3].

4. Conclusion

Hemophagocytic lymphohistiocytosis, initially presenting with neurological symptoms, can occur in adult patients with irrelevant family history. The disease is a life-threatening but potentially curable condition requiring proper diagnosis and treatment management.

Conflict of interest

None declared.

Acknowledgement and financial support

None declared.

Ethics

The work described in this article has been carried out in accordance with The Code of Ethics of the World Medical Association (Declaration of Helsinki) for experiments involving humans; Uniform Requirements for manuscripts submitted to Biomedical journals.

REFERENCES

- [1] Jędrzejczak W. Hemophagocytic lymphohistiocytosis – rarely recognized curable syndrome of immediate risk of death occurring also in adults. *Acta Haematol Pol* 2008;39:515–26.
- [2] Horne A, Trottestam H, Aricò M, Egeler RM, Filipovich AH, Gadner H, et al. Frequency and spectrum of central nervous system involvement in 193 children with haemophagocytic lymphohistiocytosis. *Br J Haematol* 2008;140:327–35.
- [3] Park HS, Kim DY, Lee JH, Lee JH, Kim SD, Park YH, et al. Clinical features of adult patients with secondary hemophagocytic lymphohistiocytosis from causes other than lymphoma: an analysis of treatment outcome and prognostic factors. *Ann Hematol* 2012;91(6):897–904.
- [4] Takahashi K, Kunishige M, Shinohara M, Kubo K, Inoue H, Yoshino H, et al. Guillain-Barré syndrome and hemophagocytic lymphohistiocytosis in a patient with severe chronic active Epstein-Barr virus infection syndrome. *Clin Neurol Neurosurg* 2005;108(1):80–3.
- [5] De Armas R, Sindou P, Gelot A, Routon MC, Ponsot G, Vallat JM. Demyelinating peripheral neuropathy associated with hemophagocytic lymphohistiocytosis. An immuno-electron microscopic study. *Acta Neuropathol* 2004;108(4):341–4.
- [6] Shinoda J, Murase S, Takenaka K, Sakai N. Isolated central nervous system hemophagocytic lymphohistiocytosis: case report. *Neurosurgery* 2005;56(1):187.
- [7] Henter JI, Horne A, Arico M, Egeler RM, Filipovich AH, Imashuku S, et al. HLH-2004: Diagnostic and therapeutic guidelines for hemophagocytic lymphohistiocytosis. *Pediatr Blood Cancer* 2007;48:124.