

Quiz

CORRECT ANSWER TO THE QUIZ. CHECK YOUR DIAGNOSIS

PERITONEAL “MELANOSIS”

EA-SLE CHANG¹, PIOTR BACHUL^{1,2}, MIROSLAW SZURA¹, JOANNA SZPOR³, KRZYSZTOF OKOŃ³,
JERZY A. WALOCHA²

¹First Department of General, Oncological and Gastroenterological Surgery, Jagiellonian University Medical College, Krakow, Poland

²Department of Anatomy, Jagiellonian University Medical College, Krakow, Poland

³Department of Pathomorphology, Jagiellonian University Medical College, Krakow, Poland

A case of a 23 year old female with peritoneal melanosis associated with adenocarcinoma of the rectum is reported. During laparoscopic anterior resection of the rectum, diffuse black pigmentations on the parietal peritoneum, greater omentum, mesenteric lymph nodes and ovaries were discovered. The histopathological findings revealed the presence of macrophages packed with black pigment. These results together with clinical data excluded metastatic melanoma and confirmed the diagnosis of the rare condition called peritoneal melanosis. Due to the benign character of the lesions the laparoscopic treatment was continued. There were no remissions or progression of the peritoneal lesions observed. There have only been 14 cases of peritoneal melanosis reported in English literature and this is the second case of peritoneal melanosis that has been associated with adenocarcinoma of the large intestine.

Key words: peritoneal melanosis, adenocarcinoma of the rectum.

Introduction

Peritoneal melanosis is a rare, benign condition, with only 14 cases reported in the English literature. It is characterized by diffuse or focal, grey to black or brown pigmentation of the peritoneum. The etiology and pathogenesis of this lesion remains controversial and numerous hypotheses have been proposed [1, 2, 3]. We present the second case in the English literature of peritoneal melanosis associated with adenocarcinoma of the rectum [2].

Case description

A 23 year-old female with anemia presented with several episodes of fresh blood in the stools. During

elective colonoscopy, a 5 cm sessile polyp located 15 cm from the anal verge was discovered and partially resected. Histopathological examination showed an adenomatous polyp with high-grade dysplasia and small foci of adenocarcinoma, consequently the patient was qualified for laparoscopic anterior resection of the rectum. During the laparoscopic procedure, diffuse black discoloration of the parietal peritoneum, greater omentum, mesenteric lymph nodes and ovaries (Fig. 1) was discovered. Because of the suspicion of advanced metastatic intraperitoneal melanoma, biopsies of the lesions were taken and the laparoscopic anterior rectal resection was postponed. The history of the patient was negative for other malignancies and physical examination of the skin as well as ophthalmological examination did not reveal any lesion

suspicious for melanoma. The patient was not taking iron therapy or anthraquinone-containing laxatives. She also did not undergo endoscopic tattooing of intestinal lesions using India ink.

The histopathological findings revealed the presence of cells containing black pigment within the cytoplasm (Fig. 2). These pigment did not stain with Fontana-Masson or Prussian blue. Immunohistochemical studies demonstrated that pigment containing cells were positive for CD68, but negative for melan-A and HMB-45. Based on these results, melanoma was excluded, and the diagnosis of rare condition called peritoneal melanosis was established.

After confirmation of the benign character of the lesions the laparoscopic treatment was continued. During this procedure no remissions or progression of the peritoneal lesions were observed. The surgery was uneventful. Final histopathological examination of the excised tumour of the rectum disclosed a well-differentiated adenocarcinoma, with muscularis propria invasion, without nodal metastases (pT2

N0). The adenocarcinoma of the rectum developed on the background of a sessile serrated adenoma/polyp with cytological dysplasia, according to WHO 2010 classification. Similarly to the previous specimens, collections of cells containing black pigment were seen within the peritoneum and lymph nodes (Figs. 3 and 4).

After discharge, the patient was closely followed-up by the oncologist. Extensive imaging and laboratory workup (USG, CT scan, tumor markers) did not indicate any signs of cancer recurrence. In subsequent follow-up's, the patient remains asymptomatic and the endoscopic examination showed complete healing of anastomotic area, without any pathological findings on the mucosa.

Discussion

To our knowledge only 14 cases of peritoneal melanosis have been reported in the English literature with various associated conditions: five with ovarian

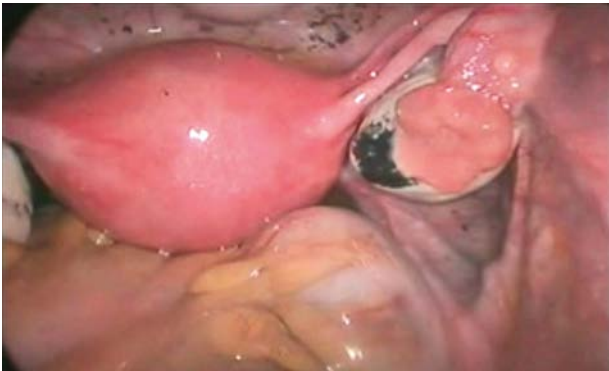


Fig. 1. Black discoloration of the ovary seen during the laparoscopic procedure

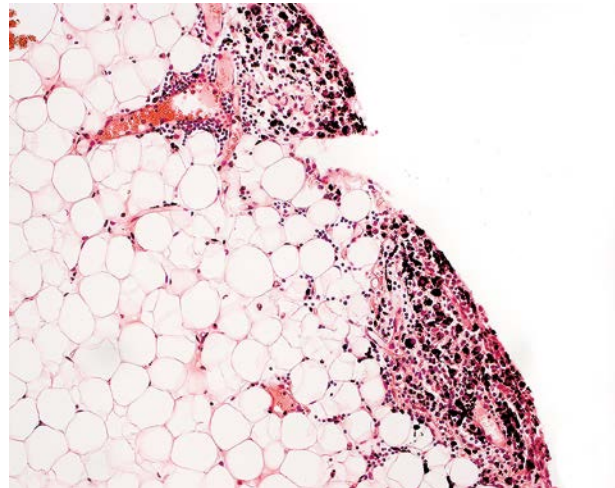


Fig. 2. Collections of cells containing black pigment within the greater omentum. HE, objective magnification 20×

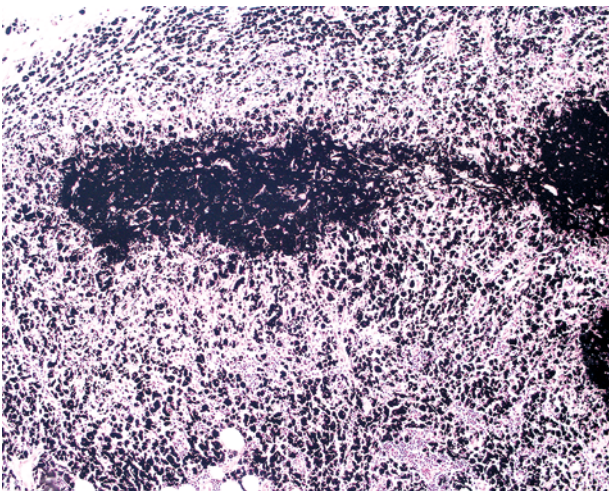


Fig. 3. Numerous collections of cells containing black pigment within the lymph node. HE, objective magnification 10×

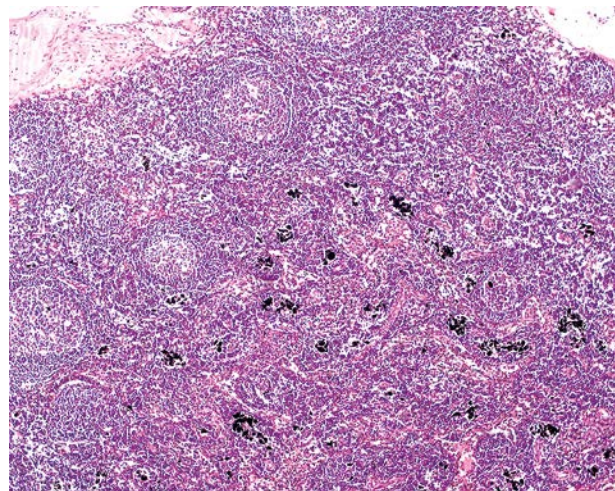


Fig. 4. Smaller collections of cells containing black pigment within the lymph node. HE, objective magnification 10×

cystic teratomas [4, 5, 6, 7, 8], two with enteric duplication [9, 10], one with gastric triplication [11], one with peritoneal cyst [12], one with serous cystadenoma of the ovary [1], one with mucinous cystadenoma of the ovary and adenocarcinoma in the colon [2], one with Peutz-Jeghers syndrome [13] and two with metastatic melanoma [3, 14].

Afonso *et al.* reported the first case of peritoneal melanosis secondary to ruptured bilateral ovarian cystic teratoma in 1962 [4]. Peritoneal melanosis has been found to be most commonly associated with ovarian dermoid cysts. It usually affects female patients, aged 18 to 28 years. The nature of the pigment has been melanin in four cases, while the sixth one contained hemosiderin. In cases associated with ovarian teratoma it was proposed that the melanin was produced in the cystic teratoma and with its rupture, the spilled pigment was phagocytosed by histiocytes and deposited within the peritoneum [4, 5, 6, 7, 12]. This theory is most widely accepted, however, does not explain cases not associated with cystic teratomas as well as cases with unruptured teratomas [1]. A second explanation was proposed by Drachenberg and Papadimitriou. In their case a peritoneal cyst presented pigmented mesothelial cells and dendritic melanocytes, which was thought to be caused by excessive migration of the neural crest cells prior to 10th week of development [12]. This developmental theory was also supported by one of the two studies associated with enteric duplication [9]. Similarly, Mondragon *et al.* also explained the pigmentation to be originated from neural crest cells. However, instead of migration, they speculated that defect in regression of neuroenteric canal leaves residual neural crest cells [11]. Kim *et al.* suspected the involvement of mesothelial cells which pinched-off during the developmental period might be the source of pigment producing cells [1]. In the second case associated with enteric duplication authors hypothesized that the source of melanin was the basal cells of esophageal mucosa within the ruptured enteric cyst. This was supported by the observation that melanoblasts may be derived from not only neural crest epithelium, but also from stem cells of esophageal mucosa [10]. Lastly, Jaworski *et al.* postulated that the pigment derived from hemorrhage associated with cystic teratoma containing gastric mucosa and peptic ulceration, as supported by their finding on iron-rich pigment from heme breakdown [8]. In two cases of peritoneal melanosis associated with metastatic melanoma, melanin within the macrophages was proposed to derive from tumor cells pigment [3, 14].

Differential diagnosis of peritoneal pigmentation includes metastatic melanoma, which is actually rarely associated with peritoneal melanosis [3, 12, 14]. Metastatic melanoma and peritoneal melanosis might resemble each other on gross evaluation and,

therefore, they must be differentiated as the prognosis for the two conditions are strikingly different. The presence of one condition does not rule out the other, as they may occur simultaneously [3]. Metastatic melanoma might have similar gross appearance, but usually forms large masses with frank hemorrhage rather than discrete nodules [15]. Histologically, neoplastic nature of the lesion is usually obvious, as the neoplastic cells are readily identified in haematoxylin and eosin stained sections. Their melanocytic differentiation can be confirmed immunohistochemically (S100, melan-A or HMB-45) [3, 14]. Peritoneal melanosis must also be differentiated from endometriosis and peritoneal lipofuscinosis. Endometriosis involving peritoneum has usually dark brown colour, but is usually easily diagnosed histologically based on the presence of glands surrounded by endometrial stroma and hemosiderin-laden macrophages. Rarely reported peritoneal lipofuscinosis can also be confirmed by histochemical methods [1, 2]. Finally, peritoneal pigmentation might be caused by intraperitoneal spillage and spread of India ink from preoperative endoscopic tattooing. These finding is not of pathological significance. A helpful clue to the proper diagnosis is location of pigmentation, which can be detected at both injection and extraintestinal sites [16].

Composition of the pigment in peritoneal melanosis is not known, although melanin and iron compounds have been reported [1, 2, 3, 4, 5, 6, 7, 8, 9, 10, 11, 12, 13, 14]. In the presented case we were not able to determine the nature of the pigment, but some possible causes of black tissue deposits were excluded including melanosis from anthraquinone-containing laxatives, melanin from metastatic melanoma, iron deposits from iron ingestion, charcoal from charcoal ingestion, tissue necrosis and intraperitoneal spillage and spread of India ink from preoperative endoscopic tattooing [16]. Probably the term peritoneal pigmentation would be a more appropriate term for our case as well as for similar cases, where the nature of the pigment is not known.

Conclusions

Peritoneal melanosis is a rare benign condition of unknown origin, which may resemble and should be differentiated from metastatic melanoma. In the presented case, this finding was the cause of the deferment of the rectal adenocarcinoma resection.

References

1. Kim NR, Suh YL, Song SY, Ahn G. Peritoneal melanosis combined with serous cystadenoma of the ovary: A case report and literature review. *Pathol Int* 2002; 52: 1724-1729.
2. Kim SS, Nam JH, Kim SM, et al. Peritoneal melanosis associated with mucinous cystadenoma of the ovary and adenocarcinoma of the colon. *Int J Gynecol Pathol* 2010; 29: 113-116.

3. Lim CS, Thompson JF, McKenzie PR, et al. Peritoneal melanosis associated with metastatic melanoma involving the omentum. *Pathology* 2012; 44: 255-257.
4. Afonso JF, Martin G, Nisco FS, De Alvarez RR. Melanogenic ovarian tumors. *Am J Obstet Gynecol* 1962; 84: 667-676.
5. Lee D, Pontifex AH. Melanosis peritonei. *Am J Obstet Gynecol* 1975; 122: 526-527.
6. Fukushima M, Sharpe L, Okagaki T. Peritoneal melanosis secondary to a benign dermoid cyst of the ovary: a case report with ultrastructural study. *Int J Gynecol Pathol* 1984; 2: 403-409.
7. Sahin AA, Ro JY, Chen J, Ayala AG. Spindle cell nodule and peptic ulcer arising in a fully developed gastric wall in a mature cystic teratoma. *Arch Pathol Lab Med* 1990; 114: 529-531.
8. Jaworski RC, Boadle R, Greg J, Cocks P. Peritoneal 'melanosis' associated with a ruptured ovarian dermoid cyst: report of a case with electron-probe energy dispersive X-ray analysis. *Int J Gynecol Pathol* 2001; 20: 386-389.
9. Nada R, Vaiphei K, Rao KL. Enteric duplication cyst associated with melanosis peritonei. *Indian J Gastroenterol* 2000; 19: 140-141.
10. Jung YC, Chen CJ, Tzeng CC. Melanosis peritonei associated with enteric duplication cyst. *Am J Surg Pathol* 1996; 20: 181-186.
11. De la Torre Mondragón L, Daza DC, Bustamante AP, Fascinetto GV. Gastric triplication and peritoneal melanosis. *J Pediatr Surg* 1997; 32: 1773-1775.
12. Drachenberg CB, Papadimitriou JC. Melanotic peritoneal cyst: light-microscopic and ultrastructural studies. *Arch Pathol Lab Med* 1990; 114: 463-467.
13. Hirasawa A, Akahane T, Tsuruta T, et al. Lobular endocervical glandular hyperplasia and peritoneal pigmentation associated with Peutz-Jeghers syndrome due to a germline mutation of STK11. *Ann Oncol* 2012; 23: 2990-2992.
14. Reccia I, Pisanu A, Podda M, Uccheddu A. An uncommon presentation of metastatic melanoma: a case report. *Medicine (Baltimore)* 2015; 94: e319.
15. Levy AD, Shaw JC, Sobin LH. Secondary tumors and tumor-like lesions of the peritoneal cavity: imaging features with pathologic correlation. *Radiographics* 2009; 29: 347-373.
16. Cappell MS, Courtney JT, Amin M. Black macular patches on parietal peritoneum and other extraintestinal sites from intraperitoneal spillage and spread of India ink from preoperative endoscopic tattooing: an endoscopic, surgical, gross pathologic, and microscopic study. *Dig Dis Sci* 2010; 55: 2599-2605.

Address for correspondence

Krzysztof Okoń MD PhD
Department of Pathomorphology
Jagiellonian University Collegium Medicum
Grzegórzecka 16
31-531 Krakow, Poland
e-mail: mpokon@cyf-kr.edu.pl