

## CLINICAL IMAGE

# *Aspergillus* endocarditis in a 33-year-old patient with bone marrow aplasia

Agnieszka Olszanecka<sup>1</sup>, Wiktoria Wojciechowska<sup>1</sup>, Patrycja Mensah-Glanowska<sup>2</sup>, Beata Piątkowska-Jakubas<sup>2</sup>, Aleksander Skotnicki<sup>2</sup>, Danuta Czarnecka<sup>1</sup>

<sup>1</sup> 1st Department of Cardiology, Interventional Electrophysiology, and Hypertension, Jagiellonian University Medical College, Kraków, Poland

<sup>2</sup> Department of Hematology, Jagiellonian University Medical College, Kraków, Poland

A 33-year-old patient was diagnosed with bone marrow aplasia on the basis of trephine biopsy. He was initially treated with steroids without any improvement. Thereafter, he was put on a combination of steroids and cyclosporine. While on immunosuppressive therapy, the patient was hospitalized in a district hospital because of sepsis. His blood cultures were positive for *Salmonella enteritidis*. The sepsis was complicated by acute renal failure. The patient was treated conservatively and showed a slow but gradual improvement. After 1 month of treatment, granulocytopenia was observed; however, there were persistent thrombocytopenia and anemia. During this hospitalization, for the first time, the cavitory lesions were found on chest radiographs, possibly an *Aspergillus* abscess. However, further diagnostic workup of the lung lesions was not performed. The patient did not receive preemptive therapy focused on fungal infection. Five months after the initial manifestation of the disease, the patient was admitted to the Department of Hematology. A chest radiograph showed thick-walled cavities (FIGURE 1A). A high serum concentration of galactomannan antigen was detected (diagnostic workup was based on the guidelines for managing *Aspergillus* infection).<sup>1,2</sup> On physical examination, a loud murmur was audible at the base of the heart. Echocardiography revealed a large mobile mass in the left ventricular outflow tract, attached to the bicuspid aortic valve, and moderate aortic regurgitation (FIGURE 1B). The clinical picture was suggestive of vegetation. Because of the size of the vegetation, the risk of arterial embolization, and the high probability of fungal endocarditis, surgical intervention was considered and the patient was consulted by a heart team. However, because of high perioperative risk, conservative therapy was recommended. Since systemic

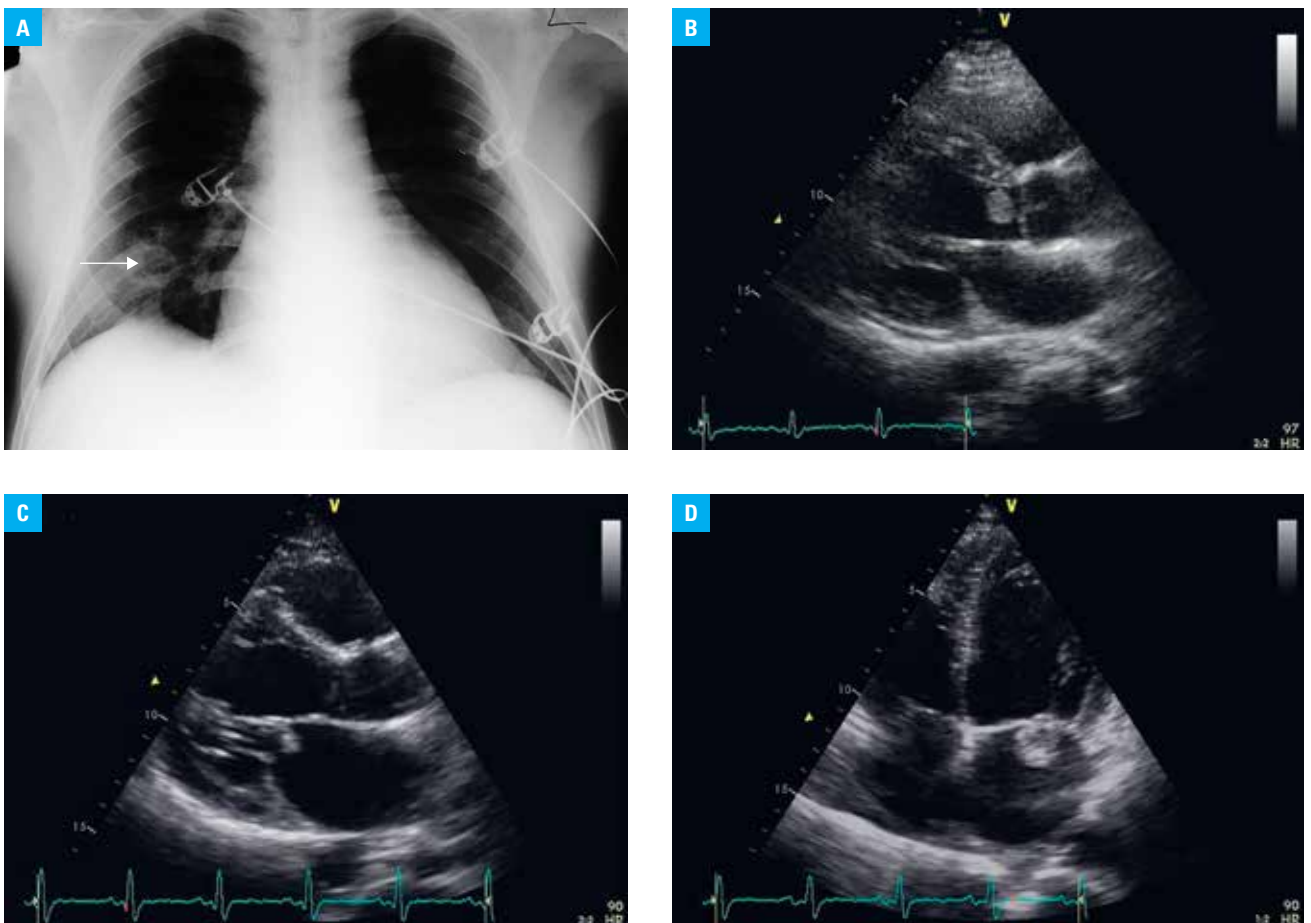
aspergillosis was suspected, rescue combination therapy of intravenous voriconazole and caspofungin was initiated.

After 8 weeks of antifungal salvage therapy, control echocardiography revealed the regression of lesions in the aortic valve; however, it showed the progression of regurgitation and left ventricular enlargement. Small vegetation was persisting in the anterior mitral leaflet (FIGURE 1C). Antifungal therapy was continued. The next echocardiogram was scheduled after 4 weeks. It revealed the progression of the lesion in the anterior mitral leaflet along with a large mobile vegetation of about 2 cm in diameter (FIGURE 1D). The patient was again consulted by the heart team, but surgical intervention was again excluded. Over the next 2 weeks, the patient developed signs of lower limb ischemia, probably due to thromboembolism to the bifurcation of the aorta, and died of progressive multiorgan failure.

Fungi are uncommon causes of infective endocarditis. Previous studies have reported fungi as the cause of infective endocarditis in 1.3% to 6% of cases.<sup>3-5</sup> Infective endocarditis related to the *Aspergillus* species (most commonly *Aspergillus fumigatus*) accounts for about 30% of cases with fungal endocarditis. In the majority of these cases, it affects immunocompromised patients. The risk factors for endocarditis in these patients are structural heart disease, prosthetic valve, and prolonged antibiotic or steroid therapy. Confirmatory diagnosis requires tissue histology and culture. Optimal treatment involves aggressive surgical debridement in conjunction with prolonged antifungal therapy.<sup>4</sup> Mortality in *Aspergillus* endocarditis is generally high, reaching almost 100% in the absence of surgical intervention.<sup>3,4</sup>

## Correspondence to:

Agnieszka Olszanecka, MD, PhD,  
I Klinika Kardiologii i Elektrokardiologii  
Interwencyjnej oraz Nadciśnienia  
Tętniczego, Uniwersytet Jagielloński,  
Collegium Medicum, ul. Kopernika 17,  
31-501 Kraków, Poland,  
phone: +48 12 424 73 00,  
fax: +48 12 424 73 20,  
e-mail: [olszane@su.krakow.pl](mailto:olszane@su.krakow.pl)  
Received: April 15, 2015.  
Accepted: June 11, 2015.  
Published online: June 15, 2015.  
Conflict of interest: none declared.  
Pol Arch Med Wewn. 2015;  
125 (7-8): 586-587  
Copyright by Medycyna Praktyczna,  
Kraków 2015



**FIGURE 1** **A** – a chest radiograph showing thick-walled cavities (arrow) in the right lung suggestive of *Aspergillus* infection in an immunocompromised patient; **B** – echocardiography (parasternal long-axis view) showing an abnormal echo in the left ventricular outflow tract (clinical picture suggestive of vegetation); **C** – echocardiography (parasternal long-axis view) showing a small vegetation in the left ventricular outflow tract and an additional vegetation attached to the atrial surface of the anterior mitral leaflet; **D** – echocardiography (4-chamber view) showing a large vegetation attached to the atrial surface of the mitral valve

The presented case illustrates the problem of late diagnosis and delayed implementation of antifungal therapy in a patient with bone marrow aplasia and invasive aspergillosis. Aspergillosis should be considered in a patient with prolonged neutropenia or immunosuppression, especially when typical features are found on chest radiography.

#### REFERENCES

- 1 Walsh TJ, Anaissie EJ, Denning DW, et al. Treatment of aspergillosis: clinical practice guidelines of the Infectious Diseases Society of America. *Clin Infect Dis*. 2008; 46: 327-360.
- 2 Maertens J, Marchetti O, Herbrecht R, et al. European guidelines for antifungal management in leukemia and hematopoietic stem cell transplant recipients: summary of the ECIL 3–2009 update. *Bone Marrow Transplant*. 2011; 46: 709-718.
- 3 Antinori S, Ferraris L, Orlando G, et al. Fungal endocarditis observed over an 8-year period and a review of the literature. *Mycopathologia*. 2014; 178: 37-51.
- 4 Lázaro M, Ramos A, Ussetti P, et al. *Aspergillus* endocarditis in lung transplant recipients: case report and literature review. *Transpl Infect Dis*. 2011; 13: 186-191.
- 5 Kalokhe AS, Roupael N, El Chami MF, et al. *Aspergillus* endocarditis: a review of the literature. *Int J Infect Dis*. 2010; 14: e1040-e1047.