

## Original paper

# 21-year retrospective study of the prevalence of *Scopulariopsis brevicaulis* in patients suspected of superficial mycoses

Anna B. Macura, Magdalena Skóra

Department of Mycology, Chair of Microbiology, Jagiellonian University Medical College, Krakow, Poland  
Head of the Department: Paweł Krzyżciak PhDPostep Derm Alergol 2015; XXXII (3): 189–194  
DOI: 10.5114/pdia.2014.40965

## Abstract

**Introduction:** In the genus *Scopulariopsis*, *Scopulariopsis brevicaulis* is the most common aetiological agent of infections in humans. It usually affects nails and is one of the commonest moulds associated with onychomycoses. Other forms of infections (skin, subcutaneous, deep tissues, and disseminated infections) have also been described.

**Aim:** To examine the prevalence of *S. brevicaulis* in clinical materials obtained from patients suspected of keratinized tissues mycoses.

**Material and methods:** The analysis of the prevalence of *S. brevicaulis* in clinical specimens was based on mycological test's results carried out for patients who were referred with a suspicion of superficial mycoses to the Department of Mycology, Chair of Microbiology, Jagiellonian University Medical College from 1992 till 2012.

**Results:** In the years 1992–2012 16,815 clinical samples (nail scrapings, nail swabs, skin scrapings, skin swabs, hair) were collected. Pathogenic fungi were detected in 7193 samples and *S. brevicaulis* was present in 255 (3.5%). The prevalence of *S. brevicaulis* in males and females was comparable. The species was most often isolated from toenails (80%), both from males and females. In the analysed period we observed a decrease in the prevalence of *S. brevicaulis*. In most cases (60%) *S. brevicaulis* occurred alone in 40% of *S. brevicaulis* positive cultures, other fungi were also isolated. The fungi most frequently isolated with *S. brevicaulis* were *Trichophyton rubrum*, *T. mentagrophytes*, *Penicillium* sp., *Candida* sp., and *Aspergillus* sp.

**Conclusions:** *Scopulariopsis brevicaulis* is not a common cause of superficial fungal infections of keratinized tissues, but is a typical mould associated with toenail onychomycosis. A proper identification of this species in onychomycoses is essential for the implementation of effective antifungal therapy.

**Key words:** *Scopulariopsis brevicaulis*, superficial mycoses, onychomycosis.

## Introduction

Fungi from the genus *Scopulariopsis* occur in soil, air, organic waste, food, feed, plants, animals, and humans [1–6]. In humans they have been mainly associated with superficial infections of keratinized tissues, especially with onychomycoses [7–17]. They have also been described as a cause of cutaneous, subcutaneous, and deep tissues mycoses, e.g. endocarditis, pulmonary infection, bronchial infection, keratitis, endophthalmitis, sinusitis, otomycosis, meningitis, and disseminated infections [18–26]. These invasive infections are relatively rare but during the last two decades have been increasingly reported, particularly in immunocompromised patients.

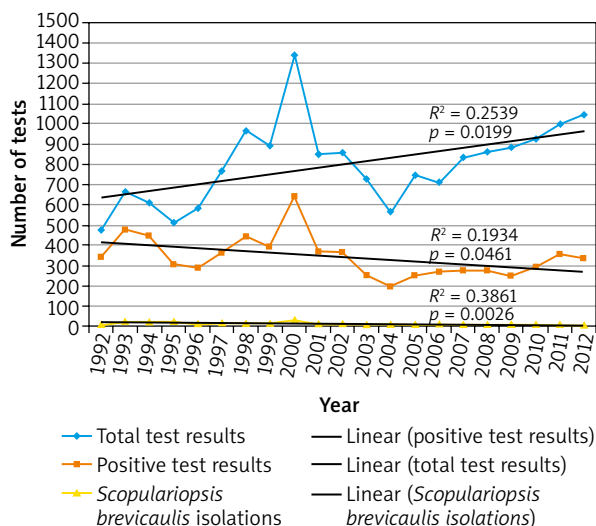
In the genus *Scopulariopsis*, *S. brevicaulis* is the most common aetiological agent of infections in humans. *Scopulariopsis brevicaulis* is considered to be resistant to most antifungal drugs currently available, including amphotericin B and azole compounds [27–29]. The treatment of infections due to this species might be ineffective and invasive infections can directly threaten patient's life.

## Aim

The aim of this study was to examine the prevalence of *S. brevicaulis* in clinical specimens obtained from patients suspected of superficial mycoses.

**Address for correspondence:** Magdalena Skóra PhD, Department of Mycology, Chair of Microbiology, Jagiellonian University Medical College, 18 Czysła St, 31-121 Krakow, Poland, phone: +48 12 633 08 77, e-mail: magdalena.skora@uj.edu.pl

**Received:** 5.06.2013, **accepted:** 2.01.2014.



**Figure 1.** Number of test results obtained during the analysed period

**Material and methods**

The retrospective analysis of the mycological test results was performed.

Samples for mycological examination were collected from patients suspected of superficial mycoses who were referred to the Department of Mycology, Chair of Microbiology, Jagiellonian University Medical College from 1 January 1992 to 31 December 2012. The collected materials contained nail scrapings, nail swabs, skin scrapings, skin swabs, and hair.

The isolation and identification of the fungi were made in accordance with conventional mycological procedures.

**Statistical analysis**

The data were processed statistically using GRETL, version 1.9.11, and Statistica 10. The results were considered significant when  $p \leq 0.05$ .

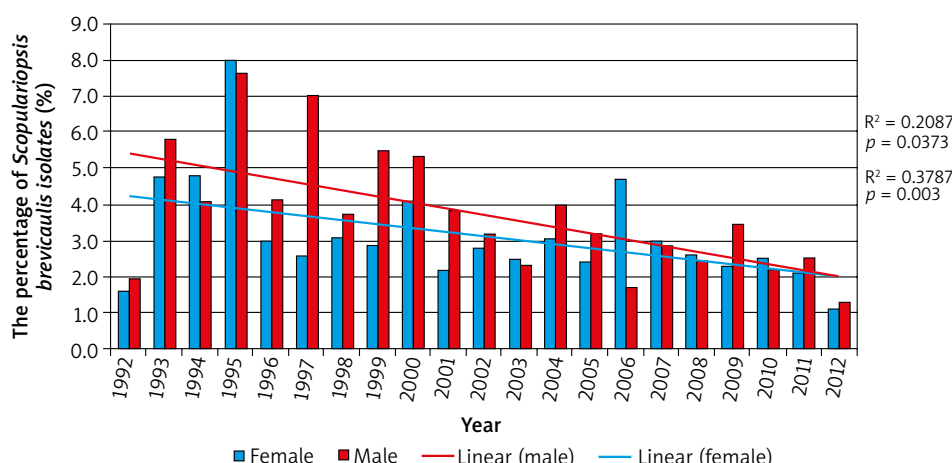
**Results**

A total of 16,815 test results were analysed: 9600 from females and 7215 from males. Seven thousand one hundred and ninety-three (42.8%) samples were positive for fungi, 3837 (40%) in females and 3356 (46.5%) in males. Out of 7193 fungi-positive specimens, 255 (3.5%) yielded *Scopulariopsis brevicaulis*. The number of *S. brevicaulis* isolates was comparable in females and males – 125 (49%) vs. 130 (51%) isolates, respectively. The comparison of the mean prevalence of *S. brevicaulis* in positive materials in males and females yielded no statistically significant difference ( $p = 0.242106$ ).

During the 21-year observation period the total number of mycological test results was increasing, while the number of positive test results and the number of *S. brevicaulis* isolates was decreasing (Figures 1 and 2). The trends were statistically significant ( $p < 0.05$ ).

The prevalence of *S. brevicaulis* in various clinical materials is shown in Figure 3. The most common localization for this species was toenails (80%), both for females and males (respectively 80.8% and 79.2% of total *S. brevicaulis* isolates for each of the sex). The other localizations were as follows: fingernails (7%), hand (6%), foot (5%), trunk (1%), groin (1%) for women, and foot (9%), fingernails (4%), hand (2%), face (2%), trunk (2%), and groin (1%) for men.

In the analysed period 10,470 nail samples were collected. Onychomycosis was diagnosed in 4806 (45.9%) cases. Moulds were reported as an aetiological agent of



**Figure 2.** Percentage of *Scopulariopsis brevicaulis* isolates in fungi-positive specimens for each sex. The lines show a statistically significant ( $p < 0.05$ ) decrease in the *S. brevicaulis* prevalence in fungi-positive specimens, both in females and males

those infections in 1080 (22.5%) cases and *S. brevicaulis* was identified in 218 – which comprised 4.5% of total onychomycoses and 22.5% of total mould-related onychomycoses. In the analysed period, the mean prevalence of *S. brevicaulis* in nail samples was 2.4%. The percentage of *S. brevicaulis* isolates from nails in females and males was comparable – the mean prevalence for females was 2% and for males 2.9%.

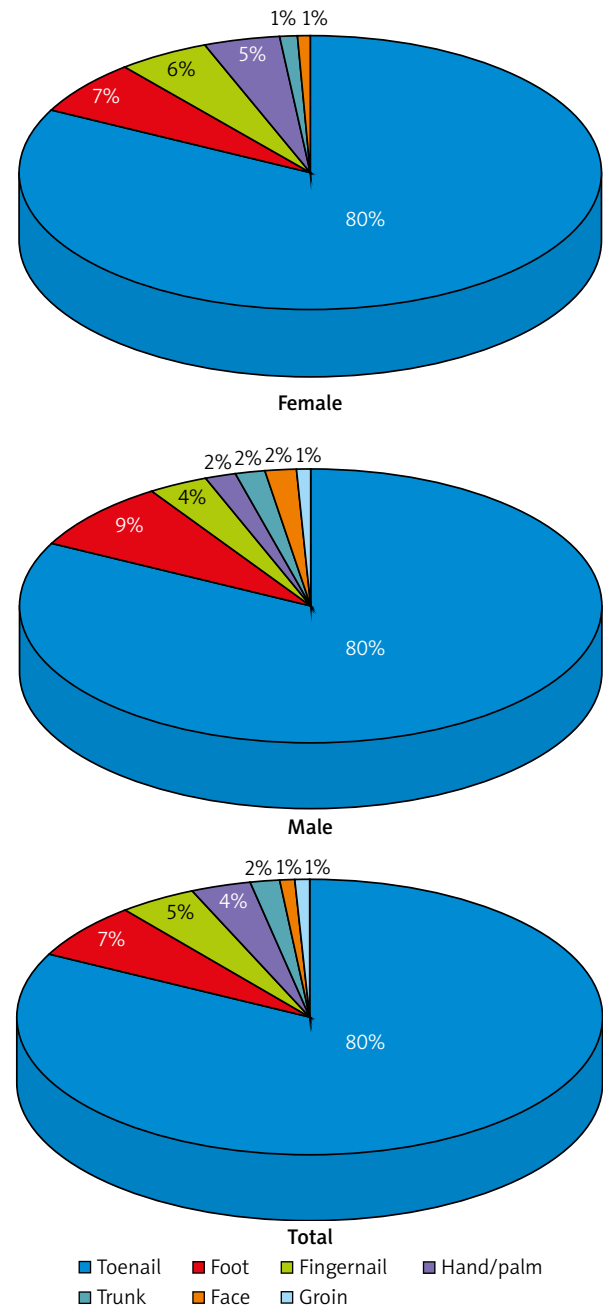
*Scopulariopsis brevicaulis* was mainly isolated from toenails (about 94% of nail isolates), occasionally from fingernails (about 6% of nail isolates). The prevalence of *S. brevicaulis* in toenails during the analysed period was 2.5% (mean: 3.1%), and the species was responsible for 5.5% (mean: 5.7%) of total toenail mycoses and 23.4% (mean: 28.3%) of moulds-related toenail infections. The mean prevalence of *S. brevicaulis* in fungi-positive toenails samples was 5.6% in females and 5.8% in males, and the mean prevalence of this species in mould-related toenail mycoses was 24.2% and 32.9%, respectively. In both cases the differences between the sexes were not statistically significant ( $p = 0.489039$  and  $p = 0.597148$ , respectively). We noticed a decrease in the prevalence of *S. brevicaulis* in toenails, both in females and males, what was statistically significant ( $p < 0.05$ ) (Figure 4).

*Scopulariopsis brevicaulis* was isolated from 14 fingernail samples and the mean prevalence of the species in this clinical material was 0.6%. There were no differences in the prevalence between the sexes (0.6% and 0.5% in females and males, respectively). *Scopulariopsis brevicaulis* was an aetiological agent of 1.3% of total fingernail mycoses (mean: 1.5%). The mean prevalence of *S. brevicaulis* in fingernail mycoses was comparable in females and males (1.2% and 2%, respectively;  $p = 0.343876$ ). In the analysed period, *S. brevicaulis* was identified as a cause of 6.8% of mould-related fingernail mycoses (mean: 11%) – the mean prevalence of this species in females was 15.1% and in males 6.9%, and the difference was not statistically significant ( $p = 0.164926$ ).

*Scopulariopsis brevicaulis* was isolated predominantly as the sole aetiological agent. In 40.4% of cases also other fungi were cultured. *Scopulariopsis brevicaulis* coexisted both with dermatophytes, other moulds, and yeasts. The predominant coexisting species was *Trichophyton rubrum*. The list of fungi isolated together with *S. brevicaulis* is shown in Table 1.

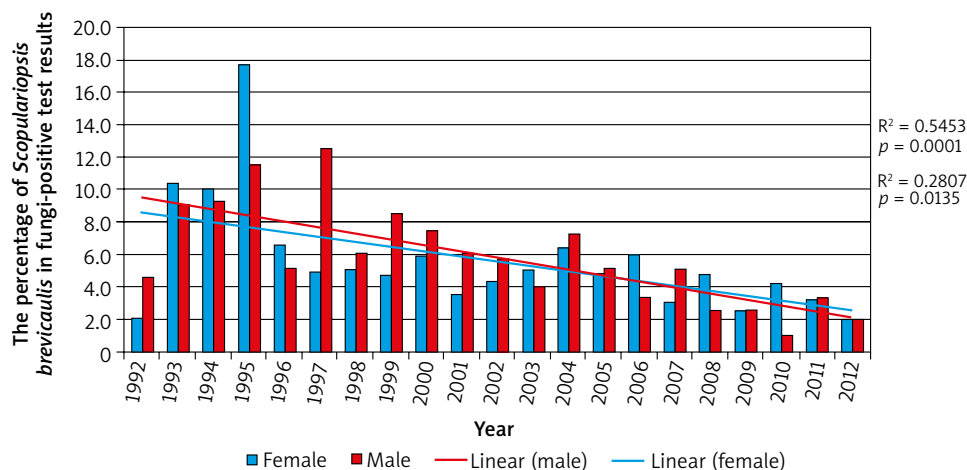
## Discussion

*Scopulariopsis brevicaulis* may cause various infections in humans – from superficial to life-threatening invasive mycoses. Superficial infections are usually caused by dermatophytes or yeasts, however, *S. brevicaulis* is one of the predominant species among nondermatophytic filamentous fungi in onychomycoses [7–15].



**Figure 3.** Prevalence of *Scopulariopsis brevicaulis* isolates in different clinical materials

Information about the prevalence of *S. brevicaulis* in superficial infections is sparse. Most of the information refers only to the occurrence of this species in onychomycoses, which are the most common clinical form of *S. brevicaulis* infections. We found only two retrospective analyses of the prevalence of *S. brevicaulis* in dermatomycosis. Petanović *et al.* investigated the presence of *S. brevicaulis* in nail, skin and scalp scrapings in the Croatian population [30]. Issakainen *et al.* performed



**Figure 4.** Percentage of *Scopulariopsis brevicaulis* in toenails. The lines show a statistically significant ( $p < 0.05$ ) decrease in the *S. brevicaulis* prevalence in fungi-positive toenails samples, both in females and males

**Table 1.** Other fungi isolated with *Scopulariopsis brevicaulis*

Group of fungi	Genus/species (number of isolates)	Total number of isolates (% of <i>S. brevicaulis</i> positive samples)
Dermatophytes	<i>Trichophyton rubrum</i> (24)	42
	<i>Trichophyton mentagrophytes</i> (17)	(16.5%)
	<i>Epidermophyton floccosum</i> (1)	
Moulds	<i>Penicillium</i> sp. (22)	44
	<i>Aspergillus</i> sp. (11)	(17.3%)
	<i>Cephalosporium</i> (3)	
	<i>Alternaria</i> sp. (2)	
	<i>Mucor</i> sp. (2)	
	<i>Trichoderma</i> sp. (2)	
	<i>Acremonium</i> sp. (1)	
	<i>Trichothecium roseum</i> (1)	
Yeasts	<i>Candida</i> sp. (20)	26
	<i>Rhodotorula</i> sp. (3)	(10.2%)
	<i>Trichosporon</i> sp. (3)	

a multicentre study for *Scopulariopsis* and *Scedosporium* occurrence in nails and skin of Finnish patients [31].

In our study, *S. brevicaulis* was found in 3.5% of fungi-positive clinical specimens collected from patients suspected of superficial mycoses. Onychomycoses related to *S. brevicaulis* yielded 4.5% of total fungal infections of nails and 22.5% of onychomycoses caused by moulds. Petanović *et al.* isolated during 7 years isolated this species in 39 cases of dermatomycosis, what comprised 2.2% of mycologically positive samples [30]. Most isolates (85.5%) in our study were cultured from nails, similarly to Issakainen *et al.*, while Petanović *et al.* isolated *S. brevicaulis* mainly from skin – in total 39 isolates, 29 (74.4%) were cultured from various skin localizations, only 10 (25.6%) from nails [30, 31]. Jankowska-Konsur *et al.* in the 5-year survey of dermatomycoses in southwest Poland obtained similar results – *S. brevicaulis* was found in 2.5% of all fungi-positive clinical samples. It comprised 25.2% of all isolated moulds and was a cause of 4.2%

of toenail onychomycoses [32]. The Korean group, who analysed 59 cases of onychomycosis due to nondermatophytic moulds during 10 years' period, found *S. brevicaulis* in 6 patients (10.2%), only in toenails. That was the second most commonly isolated species, next to *Aspergillus* species [33]. In the study of onychomycoses carried out by Tosti *et al.*, *S. brevicaulis* was isolated in 3.9% of positive test results and in 28.8% of mould infections [13]. Other authors showed an even higher percentage of *S. brevicaulis* in mould-related onychomycoses. Mügge *et al.* and Bonifaz *et al.* found this species as an aetiological agent of nail infections caused by moulds in 42.8% and 43.5%, respectively [10, 11].

There have been also reports which indicate that *S. brevicaulis* is rather rare cause of moulds-related onychomycoses. The Turkish investigators out of 33 cases of mould onychomycosis found only one (3%) *Scopulariopsis* isolate [34]. As well Dhib *et al.* in the 22 years' retrospective study of onychomycoses in Tunisia yielded

*Scopulariopsis* in a low percentage – 0.3% of fungi-positive nail samples [35]. The causative agents of onychomycoses were studied also by Bokhari *et al.* on Lahore (Pakistan) population and Gupta *et al.* on patients from Himachal Pradesh (India). They revealed the presence of *S. brevicaulis* in 2% and 2.1% of positive test results, respectively [36, 37]. Bassiri-Jahromi and Khaksar in the study of aetiological agents of fungal nail infections found *S. brevicaulis* to be a cause of 2.1% cases of whole nondermatophytic onychomycoses [9].

*Scopulariopsis brevicaulis* predominantly affects toenails, especially the big toe nail. It is rarely isolated from fingernails [10, 11, 13, 30, 31]. Our study confirms these data – 93.6% of nail isolates were cultured from toenails and 6.4% from fingernails.

Despite the fact that *S. brevicaulis* is not considered to be a typical skin pathogen, several case reports of skin infections due to this species have been reported. *Scopulariopsis brevicaulis* has been described as an aetiological agent of skin infections of: face [16, 17, 38, 39], lower limbs (including foot) [40, 41], and trunk [42]. Petanović *et al.* found this species in the following skin locations: limbs, head, trunk, and armpits [30]. In the study by Issakainen *et al.* *Scopulariopsis* was isolated from similar parts of the skin – feet, hands, upper body [31]. In our study, skin infections due to *S. brevicaulis* occurred sporadically. During a 21-year study we isolated from the skin only 37 (14.5%) strains, mainly from the foot or hand/palm.

*Scopulariopsis brevicaulis* could be a primary pathogen or a co-pathogen of the skin and nails, but usually it has been reported as a secondary pathogen with dermatophytes [43]. The results of our study do not support these data. About 60% of *S. brevicaulis* isolates were identified as the sole aetiological agent of infection and only about 17% were cultured together with dermatophytes. Similarly in Issakainen *et al.*'s study, 30% of cases of *Scopulariopsis* isolations were associated with dermatophytes [31].

The pathogenicity of *S. brevicaulis* in superficial mycoses is unclear and still disputable. Keratin degradation which determines the ability of fungi to cause skin and nail mycoses does not appear to be species specific in *S. brevicaulis*. Some *S. brevicaulis* strains are keratinolytic while others are not [44]. Isolation and identification of *S. brevicaulis* in nail and skin samples is not equivocal to infection. As other saprotrophic fungi, *S. brevicaulis* could be only the colonizer of the skin and nails, or a contaminant of a clinical material or culture. Therefore, to make a proper diagnosis, the clinical picture of the lesion and mycological test result should be considered. The isolation of *S. brevicaulis* from clinical materials collected from skin or nails, as well as other moulds, should be repeated in consecutive cultures from additional samples. In the mixed cultures, particular attention should be paid to the presence of other pathogenic fungi, especially dermatophytes, which are an undisputed cause of superfi-

cial mycoses. In simultaneous isolation of *S. brevicaulis* and dermatophytes, *S. brevicaulis* is usually considered as a secondary invader.

## Conclusions

*Scopulariopsis brevicaulis* is not a common cause of superficial fungal infections of keratinized tissues, but is a typical mould associated with toenail onychomycosis. A proper diagnosis of a causative agent of mycosis is essential to implement appropriate treatment. In the case of *S. brevicaulis* infection, this is of particular importance, because the species has been reported to be resistant *in vitro* to broad-spectrum antifungal agents available today and responds more poorly to a variety of treatment methods than dermatophytes [27–29].

## Acknowledgments

We would like to thank Mrs Kinga Przewoźniak, M.Sc. for statistical processing of the data.

The study was financed by the National Science Centre (grant number: N N401 548140).

The results, Figure 1, Figure 2, Figure 4, and Table 1 with some modifications were included in Magdalena Skóra's doctoral thesis (Skóra M. *In vitro* evaluation of factors influencing the pathogenicity of fungi of the genus *Scopulariopsis*. Jagiellonian University Medical College, Krakow, 2013).

## Conflict of interest

The authors declare no conflict of interest.

## References

1. Ropars J, Cruaud C, Lacoste S, Dupont J. A taxonomic and ecological overview of cheese fungi. *Int J Food Microbiol* 2012; 155: 199-210.
2. Chen AJ, Huang LF, Wang LZ, et al. Occurrence of toxigenic fungi in ochratoxin A contaminated liquorice root. *Food Addit Contam Part A Chem Anal Control Expo Risk Assess* 2011; 28: 1091-7.
3. Plewa K, Lone E. Seasonal biodiversity of pathogenic fungi in farming air area. Case study. *Wiad Parazytol* 2011; 57: 118-22.
4. Rota A, Calicchio E, Nardoni S, et al. Presence and distribution of fungi and bacteria in the reproductive tract of healthy stallions. *Theriogenology* 2011; 76: 464-70.
5. Awad MF, Kraume M. Mycological survey of activated sludge in MBRs. *Mycoses* 2011; 54: e493-8.
6. Roigé MB, Aranguren SM, Riccio MB, et al. Mycobiota and mycotoxins in fermented feed, wheat grains and corn grains in Southeastern Buenos Aires Province, Argentina. *Rev Iberoam Micol* 2009; 26: 233-7.
7. Lee MH, Hwang SM, Suh MK, et al. Onychomycosis caused by *Scopulariopsis brevicaulis*: report of two cases. *Ann Dermatol* 2012; 24: 209-13.
8. Moreno G, Arenas R. Other fungi causing onychomycosis. *Clin Dermatol* 2010; 28: 160-3.
9. Bassiri-Jahromi S, Khaksar AA. Nondermatophytic moulds as a causative agent of onychomycosis in Tehran. *Indian J Dermatol* 2010; 55: 140-3.

10. Bonifaz A, Cruz-Aguilar P, Ponce RM. Onychomycosis by molds. Report of 78 cases. *Eur J Dermatol* 2007; 17: 70-2.
11. Mügge C, Haustein UF, Nenoff P. Causative agents of onychomycosis – a retrospective study. *J Dtsch Dermatol Ges* 2006; 4: 218-28.
12. Boukachabine K, Agoumi A. Onychomycosis in Morocco: experience of the parasitology and medical mycology laboratory from Rabat children hospital (1982-2003). *Ann Biol Clin* 2005; 63: 639-42.
13. Tosti A, Piraccini BM, Lorenzi S. Onychomycosis caused by nondermatophytic molds: clinical features and response to treatment of 59 cases. *J Am Acad Dermatol* 2000; 42: 217-24.
14. García-Martos P, Domínguez I, Marín P, et al. Onychomycoses caused by non-dermatophytic filamentous fungi in Cádiz. *Enferm Infect Microbiol Clin* 2000; 18: 319-24.
15. López-Jodra O, Torres-Rodríguez JM. Unusual fungal species causing onychomycosis. *Rev Iberoam Micol* 1999; 16: S11-5.
16. Chung WK, Sung H, Kim MN, et al. Treatment-resistant *Scopulariopsis brevicaulis* infection after filler injection. *Acta Derm Venereol* 2009; 89: 636-8.
17. Wu CY, Lee CH, Lin HL, Wu CS. Cutaneous granulomatous infection caused by *Scopulariopsis brevicaulis*. *Acta Derm Venereol* 2009; 89: 103-4.
18. Jain D, Oberoi JK, Shahi SK, et al. *Scopulariopsis brevicaulis* infection of prosthetic valve resembling aspergilloma on histopathology. *Cardiovasc Pathol* 2011; 20: 381-3.
19. Satyavani M, Viswanathan R, Harun NS, Mathew L. Pulmonary *Scopulariopsis* in a chronic tobacco smoker. *Singapore Med J* 2010; 51: e137-9.
20. Yang Q, Wei J, Chen Z. Fatal bronchial invasion of *Scopulariopsis brevicaulis* in an acute monocytic leukemia patient. *Diagn Microbiol Infect Dis* 2012; 73: 369-71.
21. Bunya VY, Hammersmith KM, Rapuano CJ, et al. Topical and oral voriconazole in the treatment of fungal keratitis. *Am J Ophthalmol* 2007; 143: 151-3.
22. Aydin S, Ertugrul B, Gultekin B, et al. Treatment of two post-operative endophthalmitis cases due to *Aspergillus flavus* and *Scopulariopsis* spp. with local and systemic antifungal therapy. *BMC Infect Dis* 2007; 7: 87.
23. Beltrame A, Sarmati L, Cudillo L, et al. A fatal case of invasive fungal sinusitis by *Scopulariopsis acremonium* in a bone marrow transplant recipient. *Int J Infect Dis* 2009; 13: e488-92.
24. Besbes M, Makni F, Cheikh-Rouhou F, et al. Otomycosis due to *Scopulariopsis brevicaulis*. *Rev Laryngol Otol Rhinol (Bord)* 2002; 123: 77-8.
25. Nwabuisi C, Salami AK, Abdullahi NA, Agbede OO. *Scopulariopsis* associated meningitis in adult Nigerian AIDS patient – a case report. *West Afr J Med* 2003; 22: 364-5.
26. Vignon M, Michonneau D, Baixench MT, et al. Disseminated *Scopulariopsis brevicaulis* infection in an allogeneic stem cell recipient. *Bone Marrow Transplant* 2011; 46: 1276-7.
27. Carrillo-Muñoz AJ, Cárdenas CD, Carrillo-Orive B, et al. In vitro antifungal activity of voriconazole against dermatophytes and superficial isolates of *Scopulariopsis brevicaulis*. *Rev Iberoam Micol* 2005; 22: 110-3.
28. Cuenca-Estrella M, Gomez-Lopez A, Buitrago MJ, et al. In vitro activities of 10 combinations of antifungal agents against the multiresistant pathogen *Scopulariopsis brevicaulis*. *Antimicrob Agents Chemother* 2006; 50: 2248-50.
29. Skóra M, Macura AB, Bulanda M. In vitro antifungal susceptibility of *Scopulariopsis brevicaulis* isolates. *Med Mycol* 2014; 52: 723-7.
30. Petanović M, Tomić Paradzik M, Kristof Z, et al. *Scopulariopsis brevicaulis* as the cause of dermatomycosis. *Acta Dermatovenerol Croat* 2010; 18: 8-13.
31. Issakainen J, Heikkilä H, Vainio E, et al. Occurrence of *Scopulariopsis* and *Scedosporium* in nails and keratinous skin. A 5-year retrospective multi-center study. *Med Mycol* 2007; 45: 201-9.
32. Jankowska-Konsur A, Dyląg M, Hryniewicz-Gwóźdź A, et al. A 5-year survey of dermatomycoses in southwest Poland, years 2003-2007. *Mycoses* 2011; 54: 162-7.
33. Hwang SM, Suh MK, Ha GY. Onychomycosis due to nondermatophytic molds. *Ann Dermatol* 2012; 24: 175-80.
34. Hilmioglu-Polat S, Metin DY, Inci R, et al. Non-dermatophytic molds as agents of onychomycosis in Izmir, Turkey – a prospective study. *Mycopathologia* 2005; 160: 125-8.
35. Dhib I, Fathallah A, Yaacoub A, et al. Clinical and mycological features of onychomycosis in central Tunisia: a 22 years retrospective study (1986-2007). *Mycoses* 2013; 56: 273-80.
36. Bokhari MA, Hussain I, Jahangir M, et al. Onychomycosis in Lahore, Pakistan. *Int J Dermatol* 1999; 38: 591-5.
37. Gupta M, Sharma NL, Kanga AK, et al. Onychomycosis: clinico-mycologic study of 130 patients from Himachal Pradesh, India. *Indian J Dermatol Venereol Leprol* 2007; 73: 389-92.
38. Oh BJ, Chae MJ, Cho D, et al. Infection with *Scopulariopsis brevicaulis* after cosmetic surgery of the face. *Korean J Lab Med* 2006; 26: 32-5.
39. Bruynzeel I, Starink TM. Granulomatous skin infection caused by *Scopulariopsis brevicaulis*. *J Am Acad Dermatol* 1998; 39: 365-7.
40. Anandan V, Nayak V, Sundaram S, Srikanth P. An association of *Alternaria alternata* and *Scopulariopsis brevicaulis* in cutaneous phaeoerythromycosis. *Indian J Dermatol Venereol Leprol* 2008; 74: 244-7.
41. Ginarte M, Pereiro M Jr, Fernández-Redondo V, Toribio J. Plantar infection by *Scopulariopsis brevicaulis*. *Dermatology* 1996; 193: 149-51.
42. Dhar J, Carey PB. *Scopulariopsis brevicaulis* skin lesions in an AIDS patient. *AIDS* 1993; 7: 1283-4.
43. Stefanato CM, Verdolini R. Histopathologic evidence of the nondermatophytic mould *Scopulariopsis brevicaulis* masking the presence of dermatophytes in a toenail infection. *J Cutan Pathol* 2009; 36: 8-12.
44. Filippello Marchisio V, Fusconi A, Querio FL. *Scopulariopsis brevicaulis*: a keratinophilic or a keratinolytic fungus? *Mycoses* 2000; 43: 281-92.