

FOLIA MEDICA CRACOVIENSIA  
Vol. LIV, 2, 2014: 47–54  
PL ISSN 0015-5616

ARTUR MAJER<sup>1</sup>, JAKUB KENIG<sup>1</sup>

## IDIOPATHIC RECTAL NECROSIS IN 72-YEAR-OLD WOMEN: REPORT OF A CASE AND A LITERATURE REVIEW

**Abstract:** Rectal necrosis is a rare pathology, with little reports published in the literature. There are nonspecific symptoms, but clinical course may be dramatic, with necessity of urgent surgery and intensive care.

A 72-year-old female was admitted to hospital with complaints of bloody stool and dull abdominal pain. Symptoms started one week before and aggravated progressively. Physical examination revealed abdominal tenderness and flatulence, with no signs characteristic for peritonitis. Digital rectal examination demonstrated ulceration on the anterior rectal wall. Laboratory tests showed anemia, hypokalemia and elevated inflammatory parameters, whereas stool cultures revealed presence of *Salmonella*. During endoscopy, large rectal narrowing has been demonstrated. Because of this lesion and deteriorated clinical state, patient was qualified to urgent surgery. Necrotizing changed rectum has been observed intraoperatively. Additionally, extensive ischemia of the colon was present. Surgeons decided to perform proctocolectomy with end ileostomy.

Although rectal necrosis occurs greatly seldom, it can be associated with life-threatening clinical course. Symptoms of this entity are untypical and it is easy to misdiagnose patient with necrosis of the rectum. Treatment of necrotic rectal injury is predominantly surgical and consists in segmental bowel resection.

**Key words:** necrosis, bloody stool, *Salmonella*, bowel resection.

### INTRODUCTION

Necrosis refers to form of tissue injury, which results in premature death of cells by autolysis [1]. It always occurs in living organism and is associated with inflammatory process and detrimental effects [2]. Necrosis can occur in every tissue in the body and can be caused by many factors, include ischemia, infection, toxins or mechanical injury. One of the most common and serious instance of necrosis in the clinical practice is myocardial infarction, caused by ischemia, mainly due to thrombosis in the coronary arteries.

Necrosis of the rectum is very rare entity. Because of abundant vasculature derived from inferior mesenteric and internal iliac artery, ischemia occurs greatly seldom, with little cases published in the literature [3–5]. Another potential

causes may include vascular surgery, autoimmune disorders, radiation-induced damage or mesenteric veins insufficiency [6–8]. Rectal necrosis can manifest with abdominal pain, diarrhea and symptoms of lower gastrointestinal bleeding as well. On account of both intraperitoneal and extraperitoneal location, signs typical for peritonitis not always are present [5]. The current paper reports such case with untypical clinical course, followed by review of the literature.

## CASE REPORT

A 72-year-old woman has been admitted to hospital, complaining about abdominal pain and bloody stools, that sometimes were diarrheal. These symptoms have started approximately seven days earlier and deteriorated gradually. Patient lost roughly five kilograms of weight during last month. Two weeks before, she has been discharged from Department of Infectious Diseases, where she was hospitalized due to acute infectious diarrhea caused by Salmonella. Her co-morbidities include rheumatoid arthritis, left adrenal adenoma, depression and osteoporosis. She undergone four surgeries (hysterectomy, subtotal thyroidectomy, left knee replacement procedure and left pleural tumor excision) and radiotherapy of the pelvis in the past. Hysterectomy and pelvic radiotherapy have been performed twenty years earlier, in the treatment of cervical cancer. Thyroidectomy and pleural surgery have been accomplished because of nodular goiter and benign fibrous tumor, respectively.

During physical examination, patient presented flatulence and minor tenderness above entire abdominal surface. Rebound tenderness or abdominal guarding was absent. Digital rectal examination revealed an increased anal sphincter tone and ulceration with raised margins on the front side of the rectum. Basic laboratory blood test showed several abnormalities: anemia (RBC — 2 670 000/ $\mu$ L, Hemoglobin — 7.5 g/dL, Hematocrit — 22.9%), increased level of inflammatory markers (WBC — 19 500/ $\mu$ L, CRP — 173.1 mg/L), hypokalemia ( $[K^+]$  — 3.1 mmol/L) and slightly elevated serum concentration of amylase, lipase, urea and glucose. Patient has not presented with symptoms indicative of acute abdomen, so she was admitted to Department of Internal Diseases for further diagnostic. Samples of the feces have been examined microbiologically once again. Stool culture revealed Salmonella. Colonoscopy has also been performed and demonstrated two alarming changes: cylindrical infiltration with ulcer (Fig. 1) and swollen narrowing of the rectal wall (Fig. 2), roughly five and seven centimeters from the anal verge, respectively. Examination of the other parts of the colon was impossible.

Patient's condition deteriorated. Because of the narrowing, septic signs and severe abdominal pain, decision about urgent surgery was made. Intraoperatively, necrotic changed rectum has been observed (Fig. 3). Moreover, necrosis spread to the terminal segment of the sigmoid colon and left iliopsoas muscle, forming an

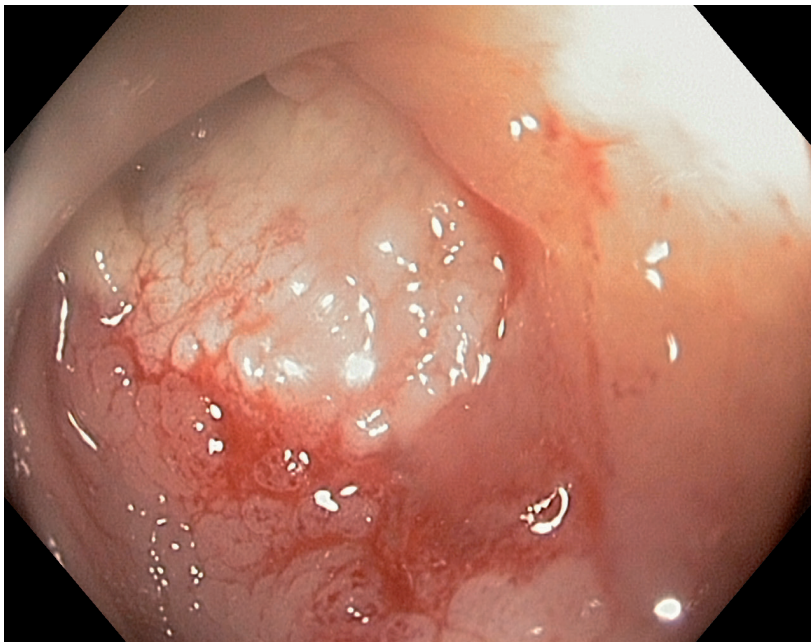

Fig. 1. Cylindrical infiltration with ulceration.

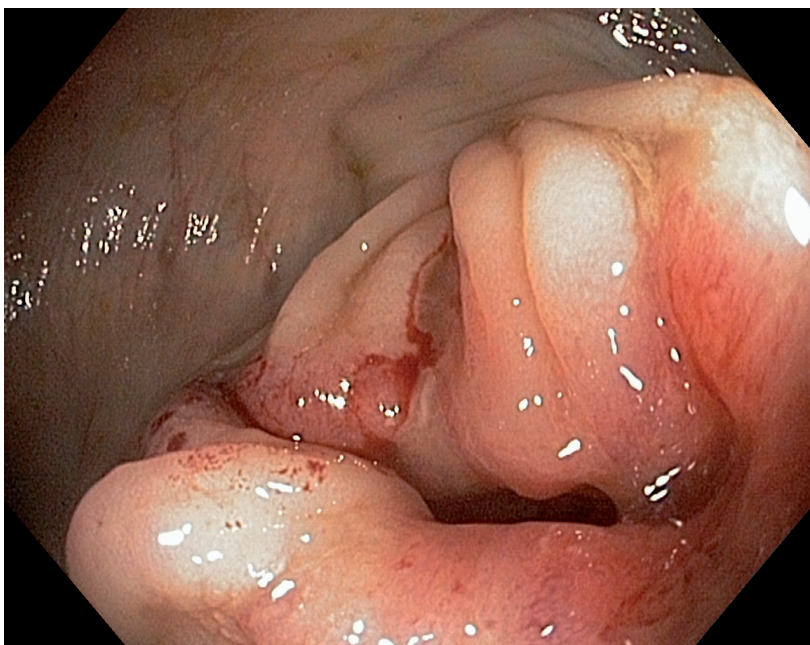


Fig. 2. Swollen narrowing, closing the rectal lumen significantly.

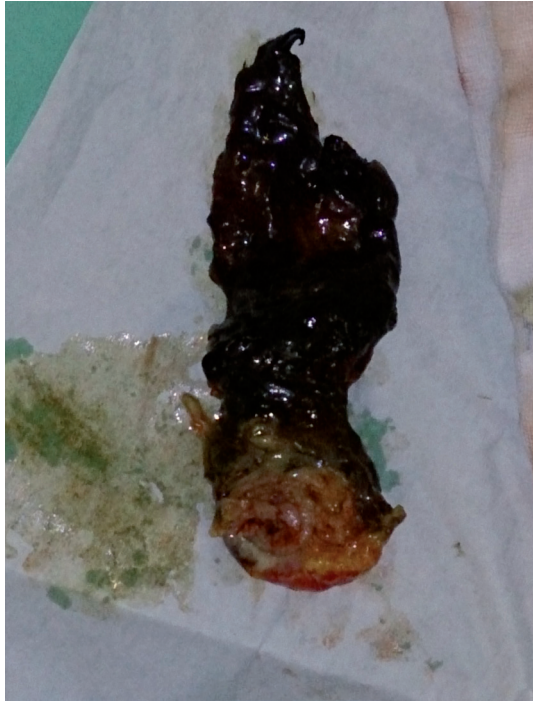

Fig. 3. Necrotic rectum.

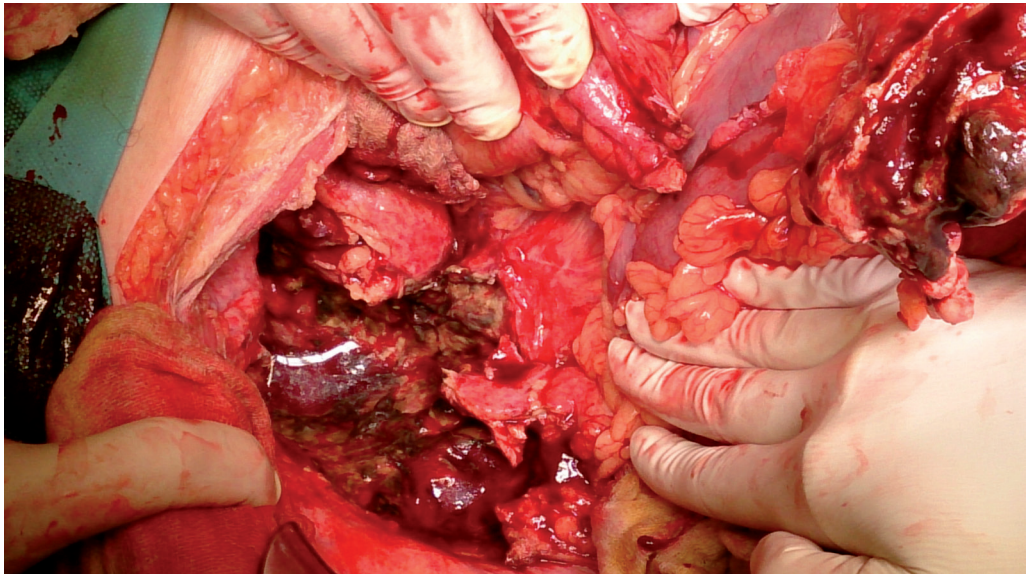


Fig. 4. Pelvic and lower abdominal region with much purulent effusion and gangrene (rectum already removed).

abscess in the latter. Much purulent effusion and gangrene was present in the pelvic region (Fig. 4). Initially, surgeons made decision about low anterior resection, but due to extensive ischemia in the entire colon, they decided to perform proctocolectomy with end ileostomy. Histopathological examination of the excised specimen revealed infiltration typical for ulcerative colitis in the transverse colon. Patient has been discharged at eighth hospital stay with good general state. She is candidate to restore gastrointestinal continuity after several months.

## DISCUSSION

The exact pathogenesis of necrotic rectal inflammation described above remains unknown. There are little published articles, which reports about possible causes and risk factors of rectal necrosis. Rectal ischemia seems to be the most important mechanism, while atherosclerosis together with aortic aneurysm surgery constitutes the leading risk factors (8). Whereas ischemic colitis is well recognized pathology, ischemic proctitis occurs greatly seldom [8–10]. Azimuddin *et al.* reported a series of three cases of rectal necrosis entailed by ischemia. Each of these patients was in old age and presented with cardiovascular risk factors, include hypertension, hypercholesterolemia and a history of stroke or TIA. These clinical features prove advanced atherosclerosis that can occur in any part of the arterial system, not only in the most common sites, such as coronary or cerebral vascular bed [5]. Maun *et al.* present case series of rectal necrosis in four patients, provoked by atherosclerotic ischemia as well. Each of them presented with cardiovascular disease, include thoracic aorta aneurysm, myocardial infarction in two patients and peripheral arterial occlusive disease. Each patient required cardiac or vascular surgery. Rectal necrosis occurred approximately two weeks after surgical intervention [3]. These cases could confirm decompensation of the atherosclerotic disease after surgeries, which are associated with extensive blood loss. Everybody of these seven patients described in above case series, presented with rectal bleeding, abdominal pain and hemodynamic instability as well. Each patient has been treated surgically by segmental large bowel resection, mainly proctectomy with end colostomy.

Not only arterial occlusion, but also venous insufficiency can lead to ischemia and necrosis of the tissue. Shank ulcer in the course of deep vein thrombosis is the simple example of this entity. Just as arterial supply, rectum has abundant venous drainage both to portal and caval system. Occlusion of the mesenteric veins, which drain the blood from the upper part of the rectum, is the basis in the pathogenesis of idiopathic myointimal hyperplasia of mesenteric veins (IMHMV). This is greatly uncommon disease with only twelve cases described in the literature. The microscopic pathology shows non-thrombotic and non-embolic occlusion of the veins, caused by hyperplasia of the vein medial layer and progressive

narrowing of the vessel lumen. Patients with IMHNV are predominantly young adults and typically presents with dull abdominal pain, alternating bowel habits and blood-tinged stools [11]. Only one patient described by Genta *et al.* presented with necrosis of the rectum and sigmoid colon and signs of septic shock that required laparotomy and segmental bowel excision [7].

There is one published article about necrosis of the rectum caused by bacterial infection. Barnham *et al.* reported a case about necrotizing proctitis caused by *Streptococcus pyogenes*. It occurred in an older male admitted with signs of peritonitis and septic shock. Explorative laparotomy was performed and visualized necrotic changed rectum and a part of the sigmoid colon. Blood cultures revealed the presence of *Streptococcus pyogenes* type T28R28 carrying genes encoding for streptococcal pyrogenic exotoxins B and C. Rectal necrosis in this case was a part of Streptococcal Toxic Shock Syndrome (STSS). Another presentation of this general infection was necrotizing fasciitis with scrotal necrosis as well [12]. According to role of infection, there are also many surgical complications caused by Salmonella. These include neonatal necrotizing enterocolitis, intussusception, toxic megacolon, gastrointestinal perforation and aortic aneurysm as well [13–16]. However, there is no any published report about the influence of Salmonella on rectal necrosis.

Rectal injury is also quite frequent side effect of pelvic radiotherapy, commonly used in the treatment of prostate, urinary bladder and uterine cancer. This entity is called radiation proctitis that manifests with abdominal pain and bloody diarrhea [6]. Although it is relatively common disorder, there is only one article about rectal necrosis as a complication of pelvic radiotherapy, reported by Luna-Perez *et al.* It describes a group of twenty women after pelvic radiotherapy because of uterine malignancy (eighteen cervical and two endometrial cancers). All of them developed typical symptoms of radiation proctitis approximately eight months after treatment. Nineteen was successfully cured by endoscopic formalin instillation, but one developed diffuse peritonitis caused by perforation of necrotic rectum [17].

Each described case of radiation-induced rectal injury occurred within two years after beginning of pelvic radiotherapy, which is much different of case reported in this paper.

Necrotic rectal inflammation with life threatening clinical course has also been described in the course of systemic lupus erythematosus. That occurred in female with a history of this disease, who was admitted to hospital with exacerbation of arthritis and abdominal pain. During hospital stay, she developed peritonitis caused by rectal perforation. Surgery with resection of the rectosigmoid was needed. Histopathological examination of the specimen revealed changes characteristic for vasculitis that is relatively often present in the autoimmune diseases [18]. There is no report about similar clinical course in rheumatoid arthritis, which is also disorder from autoimmunity.

Ulcerative colitis was diagnosed postoperatively in patient described in this case report. Abdominal pain and diarrhea with blood-tinged stool are the most common symptom of this disease. On the other hand, beginning of ulcerative colitis with its typical manifestation occurs mainly between 20 and 40 year of age. Furthermore, only 1.1% patients with ulcerative colitis are asymptomatic in the beginning of the disease and they are predominantly males. Those patients have also better prognosis. Additionally, there are no any reports about rectal necrosis in the clinical course of ulcerative colitis in both symptomatic and asymptomatic patients [19].

### CONCLUSIONS

Rectal necrosis is rare clinical entity, poorly described in the literature. It can present with variable and nonspecific symptoms, so it is easy to misdiagnose those patients. Clinical course may be life-threatening, because almost always lead to bowel obstruction or diffuse peritonitis, which are surgical emergencies. The really cause of rectal necrosis in case reported in this paper is unknown. There are only possible risk factors that include ischemia, Salmonella infection or untypical course of ulcerative colitis. It seems very important to remember, that inflammation with necrosis can occur everywhere in the body, also in organs with great blood supply. Imaging and endoscopic studies are always helpful in such cases.

### ACKNOWLEDGEMENTS

None.

### FUNDINGS

None.

### CONFLICT OF INTEREST

None declared.

### REFERENCES

1. Proskuryakov S.Y., Konoplyannikov A.G., Gabai V.L.: Necrosis: a specific form of programmed cell death? *Exp Cell Res.* 283 (1): 1–16. —
2. Kasper D.L., Zaleznik D.F.: Gas gangrene, antibiotic associated colitis, and other Clostridial infections. In Stone RM. *Harrison's principles of internal medicine self-assessment and board review* (15<sup>th</sup> ed.). New York: McGraw-Hill, Medical Pub. Division. pp. 922–927. —
3. Maun D., Silverberg D., Steinhagen R.: Acute Ischemic Proctitis: Report of Four Cases. *Dis*

Colon Rectum. 2006; 50: 1082–1086. — **4.** Nassif M., Ameer A., Meterissian S.H., Meguerditchian A.: A Case of Unresectable Rectal Necrosis. Case Reports in Medicine, Volume 2011. — **5.** Azimuddin K., Raphaeli T.: Acute ischemic gangrene of the rectum: Report of 3 cases and review of literature. International Journal of Surgery Case Reports 4 (2013): 1120–1123. — **6.** Kennedy G.D., Heise C.P.: Radiation colitis and proctitis. Clin Colon Rectal Surg. 2007 Feb; 20 (1): 64–72. — **7.** Genta R.M., Haggitt R.C.: Idiopathic myointimal hyperplasia of mesenteric veins. Gastroenterology. 1991; 101: 533–539. — **8.** Ruckert R.F, Bauchmann P.: Ischemic colon and rectum necrosis after resection of the abdominal aorta. Chirurg. 1982 Sep; 53 (9): 556–562. — **9.** Abhishek K., Kaushik S., Kazemi M.M., El-Dika S.: An Unusual Case of Hematochezia: Acute Ischemic Proctosigmoiditis. J Gen Intern Med. 23 (9): 1525–1527. — **10.** Hubler M., Isbister W.H.: Rectal necrosis following anterior resection of the rectum. Aust N Z J Surg. 1995 Aug; 65 (8): 614–616.

**11.** Savoie L.M., Abrams A.V.: Refractory Proctosigmoiditis Caused by Myointimal Hyperplasia of Mesenteric Veins. Dis Colon Rectum. 1999; 42: 1093–1096. — **12.** Barnham M., Al-Dabbagh A.K., Gray C., Dyke G.W.: Necrotizing Proctitis Caused by Streptococcus pyogenes. Journal of Infection. 2000; 40: 285–290. — **13.** Borioni R., Fratticci L., Di Roma M., et al.: Emergency treatment of a salmonella-infected abdominal aortic aneurysm associated with spondylodiscitis. Ann Ital Chir. 2012 Jul–Aug; 83 (4): 343–346. — **14.** Maier U.E.: The etiology of necrotizing enterocolitis in the newborn. Fortschr Med. 1979 Feb 15; 97 (7): 289–294. — **15.** Chaudhuri A., Bekdash B.A.: Toxic megacolon due to Salmonella: a case report and review of the literature. Int J Colorectal Dis. 2002, Jul; 17 (4): 275–279. — **16.** Altun H., Banli O., Karakoyun R.: Intestinal intussusception as a complication of typhoid fever. Acta Chir Belg. 2011 May–Jun; 111 (3): 174–175. — **17.** Luna-Perez P., Rodriguez-Ramirez S.E.: Formalin Instillation for Refractory Radiation-Induced Hemorrhagic Proctitis. Journal of Surgical Oncology. 2002; 80: 41–44. — **18.** Lazaris A.Ch., Papanikolaou I.S., Theodoropoulos G.E., Petraki K., Davaris P.S.: Ischemic necrosis of the rectum and sigmoid colon complicating systemic lupus erythematosus. Acta Gastroenterol Belg. 2003 Apr–Jun; 66 (2): 191–194. — **19.** Park S.K., Ye B.D., Yang S.K., et al.: Clinical features and course of ulcerative colitis diagnosed in asymptomatic subjects. J Crohns Colitis. 2014 Mar 21.

<sup>1</sup> 3<sup>rd</sup> Department of General Surgery  
Jagiellonian University Medical College  
ul. Piłsudnicka, 35–37 31-202 Kraków, Poland  
Head: prof. Wojciech Nowak MD, PhD

**Corresponding author:**

Artur Majer  
ul. Koszyka 2, 46-070 Komprachcice, Poland  
Phone: +48 783 247 413  
E-mail: artmaj9540@gmail.com