

# CLINICAL CASES

Dent. Med. Probl. 2014, 51, 4, 546–552  
ISSN 1644-387X

© Copyright by Wrocław Medical University  
and Polish Dental Society

KATARZYNA GAWRON<sup>1, A-F</sup>, KATARZYNA ŁAZARZ-BARTYZEL<sup>2, A-B,F</sup>,  
MARIA CHOMYSZYN-GAJEWSKA<sup>2, A-F</sup>

## Clinical Presentation and Management of a Rare Case of Unilateral Idiopathic Gingival Fibromatosis

### Obraz kliniczny i leczenie rzadkiego przypadku jednostronnej, idiopatycznej włókniakowatości dziąseł

<sup>1</sup> Microbiology Department, Jagiellonian University, Faculty of Biochemistry, Biophysics and Biotechnology, Kraków, Poland

<sup>2</sup> Department of Periodontology and Oral Medicine, Jagiellonian University, Collegium Medicum, Kraków, Poland

A – research concept and design; B – collection and/or assembly of data; C – data analysis and interpretation; D – writing the article; E – critical revision of the article; F – final approval of article

#### Abstract

Gingival fibromatosis is a painless enlargement within the gingiva, and may cause speech disturbances and difficulty in chewing and impede the maintenance of good oral hygiene. The most common forms of treatment are gingivectomy and gingivoplasty. The ultimate cause of the complaint is still not known, and makes it difficult to choose appropriate treatment.

This case report describes a patient diagnosed with localized idiopathic gingival fibromatosis. A 35-year-old male reported to the clinic with an enlargement distributed in the posterior maxillary region of the gingiva and the palate. The treatment consisted of scaling and root planing, and internal bevel incision performed under local anesthesia, excision of the excess tissue, mobilization of the flap and then suturing. According to the medical history, clinical findings and histological evaluation, the patient was diagnosed with localized gingival fibromatosis. The modified surgical procedure performed in the current case significantly reduced the lesion and improved the quality of the patient's life. There were no postoperative complications, and recovery was uneventful, as was determined by a follow-up visit one month after surgery. There was no recurrence in the twelve months following surgery. Internal bevel incision may be highly effective in some cases of gingival enlargement and result in significant clinical improvement. Attention should be drawn to every modification of surgical procedures in this high-risk location (palatal artery) for overgrowths (**Dent. Med. Probl. 2014, 51, 4, 546–552**).

**Key words:** gingiva, gingival fibromatosis, therapeutics.

#### Streszczenie

Włókniakowatość dziąseł jest niebolesnym powiększeniem tkanki dziąsła, która może powodować zaburzenia mowy, trudności w żuciu pokarmów, a także utrudniać utrzymanie właściwej higieny jamy ustnej. Najczęstszą metodą leczenia jest gingiwektomia i gingiwoplastyka. Ostateczna przyczyna patologii nie jest znana, co utrudnia wybór prawidłowego leczenia.

Opisano przypadek pacjenta z rozpoznaniem zlokalizowanej, idiopatycznej włókniakowatości dziąseł. 35-letni mężczyzna zgłosił się do leczenia z przerostem tkanki w szczęcie – w okolicy tylnej części podniebienia i dziąsła po stronie prawej. Przeprowadzono skaling, a następnie w znieczuleniu miejscowym zabieg chirurgiczny polegający na wycięciu nadmiaru tkanki (cięcie wewnętrzne skośne, mobilizacja płata, szwy). Rozpoznanie postawiono na podstawie wywiadu, badania klinicznego oraz oceny histologicznej. Zabieg chirurgiczny doprowadził do znacznego zmniejszenia zmiany i wpłynął na jakość życia pacjenta. Wizyta kontrolna po miesiącu wykazała prawidłowe gojenie rany i brak powikłań. Po 12 miesiącach nie stwierdzono wznowy. Cięcie wewnętrzne skośne może być pomocne w niektórych przypadkach włókniakowatości dziąseł w uzyskaniu znacznej poprawy klinicznej. Należy brać pod uwagę każdą możliwą modyfikację metod chirurgicznych stosowanych w zmianach umiejscowionych w obszarach dużego ryzyka (tętnica podniebienne) (**Dent. Med. Probl. 2014, 51, 4, 546–552**).

**Słowa kluczowe:** dziąsło, włókniakowatość, leczenie.

Gingival overgrowth (GO) is a condition characterized by abnormal growth in the maxillary and/or mandibular gingiva. This group includes gingival fibromatosis (GF), which is a diffuse or localized, progressive enlargement within the gingiva [1–5].

GO may occur in individuals treated with anti-seizure, immunosuppressive or anti-hypertensive medications. Phenytoin, cyclosporin A, and nifedipine, respectively, being the representatives of the above-mentioned groups, have been noted as the most frequent causative agents of GO. Clinical symptoms of this condition found in particular groups of patients do not differ significantly [6–9].

Hereditary types of gingival overgrowth are associated with several genetic *loci* within the human population [10–12]. As an inherited disorder, fibromatosis may be a part of a Cowden syndrome with multiple hamartomas, Murray-Puretic-Drescher syndrome with multiple dental hyaline tumors, and Rutherford syndrome, which is a form of oculodental syndrome (corneal dystrophy). Fibromatosis may also co-exist in patients with bone, nail, and ear defects who suffer from Zimmermann-Laband syndrome [13]. GF may also be associated with dental abnormalities that include generalized hypoplastic amelogenesis imperfecta, intrapulpal calcifications, delayed tooth eruption, periapical radiolucencies in unerupted teeth, dental agenesis and root dilacerations. An association with mental retardation has also been reported recently [14, 15].

In some conditions, gingival enlargement can develop rapidly into destructive periodontal disease as a result of the altered immune response of the gingiva to the bacterial biofilm. It may also co-exist with several forms of blood dyscrasias, i.e. acute monocytic, lymphocytic or myelocytic leukemia, thrombocytopenia and thrombocytopeny. Some reports indicate that gingival overgrowth may also be associated with hormonal disturbances [1, 6, 16].

Many clinical cases of GF are of unknown etiology and defined as idiopathic gingival fibromatosis or gingivomatosis [2, 17–19]. There is also the possibility that in such cases a trauma and/or irritating factor could be a contributory cause.

Basically, GF manifests itself as a firm, non-inflammatory and non-hemorrhagic enlargement of the gingiva. Although the process is usually not painful, the overgrown gingiva may affect oral cavity hygiene and eventually induce bone loss. The patients frequently complain of difficulties with speech and mastication as well [18–20]. Some data revealed an enhanced risk of caries and periodontal disorders in patients with gingival fi-

bromatoses [21–24]. The most commonly considered treatment is a complete resection of the enlarged gingiva. For this purpose gingivectomy and gingivoplasty are carried out [19, 20].

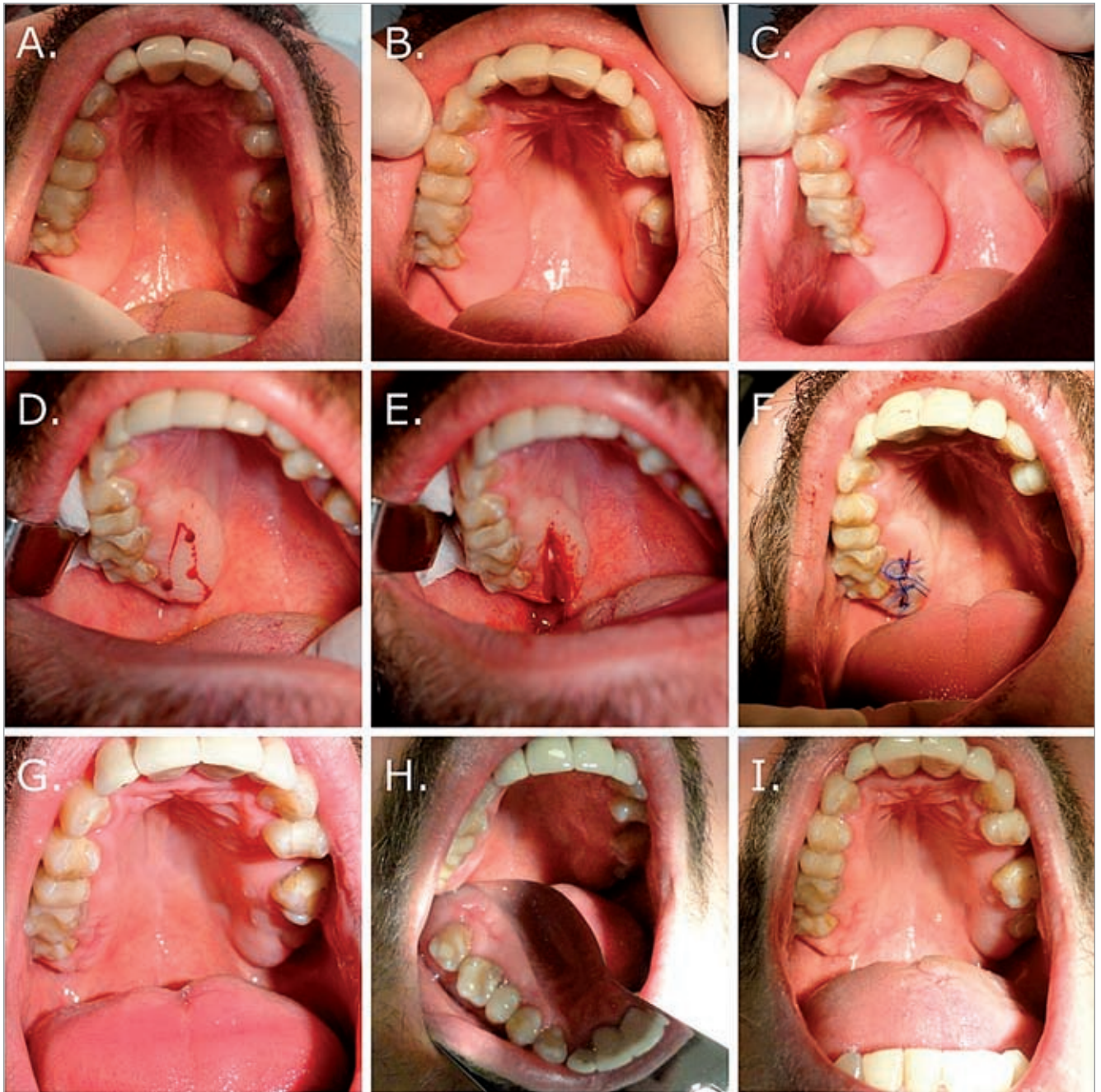
## Case Report

The study was carried out in accordance with the Declaration of Helsinki and the consent of the patient was obtained prior to the study, as approved by the Bioethical Committee of the Jagiellonian University, Medical College in Kraków (KBET/133/B/2012).

A 35-year-old patient reported to the Department of Periodontology and Oral Medicine, Jagiellonian University, complaining of overgrowth in the upper right part of maxillary gingiva associated with bleeding when brushing teeth as well as with problems in keeping oral hygiene. Clinical examination disclosed a lesion along the first, second and third upper molars within the right part of the jaw (Fig. 1 A–C). The enlargement was solid, dense, sessile and painless on palpation and measured  $1.5 \times 4$  cm.

An initial intraoral examination revealed moderate levels of calculus and carious lesions in teeth no. 15, 16, 36 and 46. Dental calculus was removed by means of routine hygienic procedures. Teeth no. 15, 16 and 36 were treated because of caries, while tooth no. 46 was later extracted. A pre-operative panoramic radiograph showed no alveolar bone loss in the area of the enlarged gingival tissue (Fig. 2). The patient did not use any drugs which would induce overgrowth of the gingival tissue and his family history appeared insignificant. All diagnostic tests were within normal limits, therefore any conditions that would contribute to gingival enlargement were ruled out.

In the current case, the complete excision of the lesion was considered first of all. However, the high risk of complications during intervention caused by the location of the lesion in close proximity to the palatal artery required a modification of the standard surgical procedure (Fig. 1 A–C). First, a small piece of the excised gingival lesion was evaluated by a pathologist to exclude the presence of cancer. In brief, the surgery was performed under local anesthesia (Septanest with adrenalin, 1 : 200; Septodont) and comprised an internal bevel incision, a partial, wedge-shaped excision of the overgrown gingiva, mobilization of the flap and suturing. A parallel excision was made along the second premolar up to the third upper molar (teeth 15, 16, 17, 18) in the right part of the maxilla and palate (Fig. 1 D–F). The excised part of the



**Fig. 1.** Isolated gingival enlargement in the posterior maxillary region of the *gingivae*: A–C – before surgery; D–F – during surgery; G–I – follow-up visit 12 months after surgery

**Ryc. 1.** Przerost tkanki umiejscowiony w dystalnym regionie dziąsła szczęki: A–C – przed zabiegiem; D–F – w trakcie zabiegu; G–I – 12 miesięcy po zabiegu

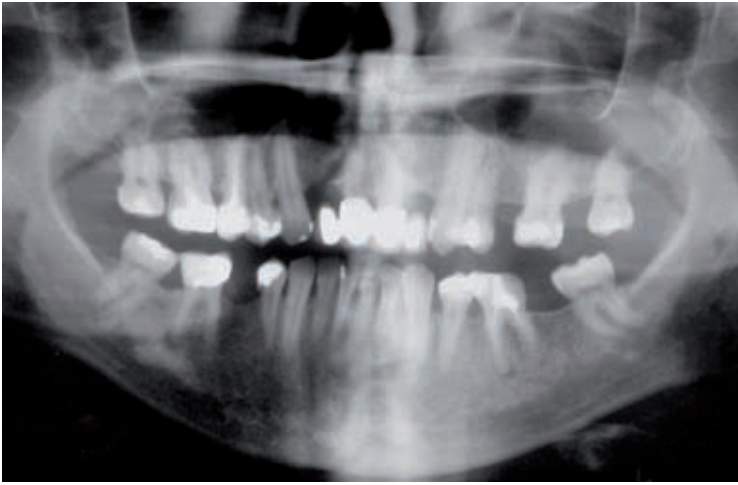gingival tissue measured 0.7 cm in diameter and 3 cm lengthwise (Fig. 4).

Histopathological evaluation of the gingival specimens revealed mild epithelial hyperplasia with topically elongated rete pegs extending into underlying connective tissue stroma. The elongated connective tissue *papillae* featured diffuse, moderate inflammation (Fig. 3 A–B). Visible in the dense, thickened connective stroma were irregular and dense collagen fibrils and enlarged ve-

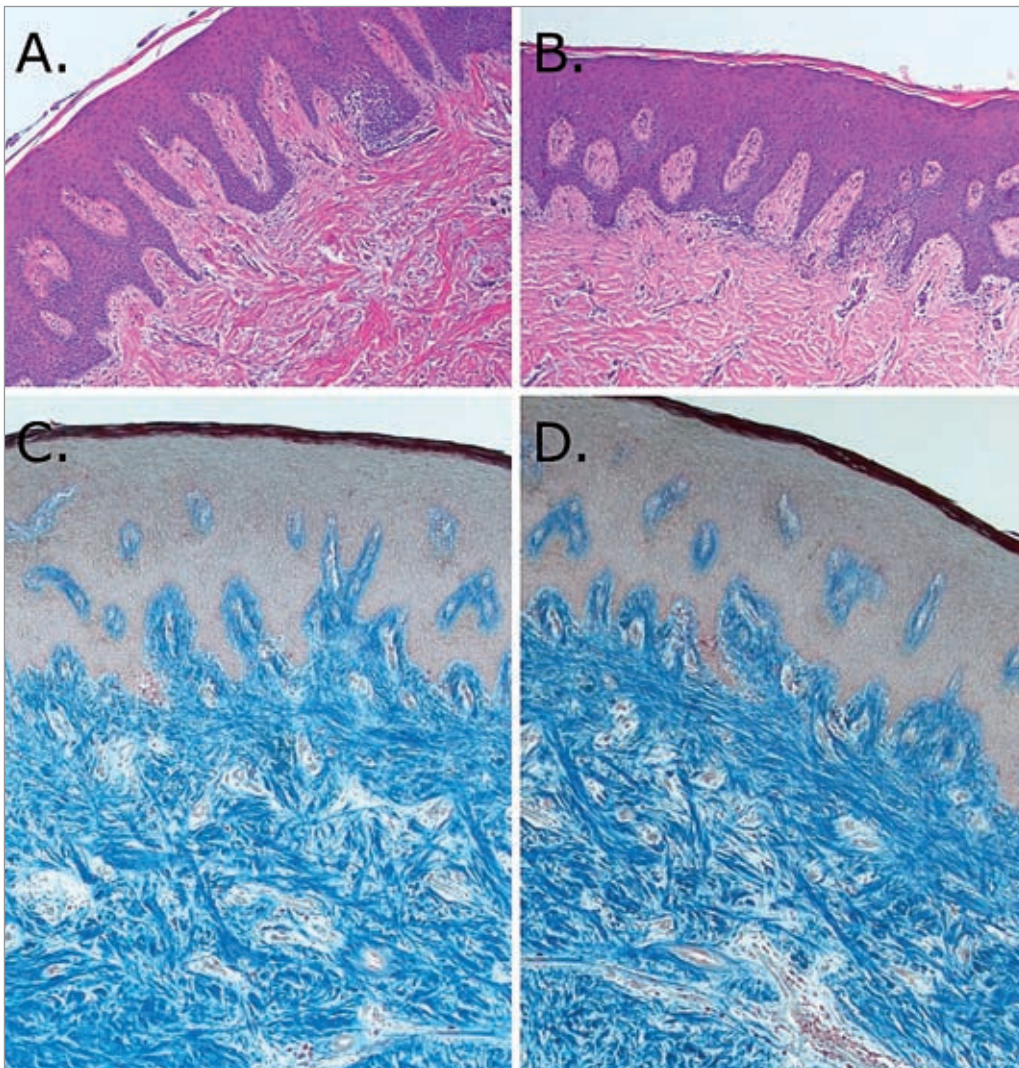
nous vessels. Well-developed collagen bundles oriented in all directions were considerably stained with Heidenhain's trichrome (Fig. 3 C–D). Gingival fibroblasts were arranged abundantly under the epithelium.

Taken together, the medical history, clinical findings and histopathological evaluation confirmed the diagnosis of idiopathic gingival fibromatosis. The patient was advised to visit the dental clinic one month after surgery to examine his oral





**Fig. 2.** Panoramic radiograph  
**Ryc. 2.** Zdjęcie pantomograficzne



**Fig. 3.** Epithelium and *lamina propria* of gingival overgrowth: A–B – hematoxylin and eosin staining, original magnification 100×; C–D – Heidenhain's trichrome staining, magnification 100×

**Ryc. 3.** Nabłonek i podścielisko łącznotkankowe przerośniętej tkanki dziąsła: A–B – barwienie H/E (hematoksyliną i eozyną), powiększenie 100×; C–D – barwienie trichromem wg Heidenhaina, powiększenie 100×

hygiene and monitor healing of the gingiva following excision of the tissue. There were no postoperative complications, and healing was uneventful, as

was determined by a follow-up visit one month after surgery. There was no recurrence in the twelve months following surgery (Fig. 1 G–I).

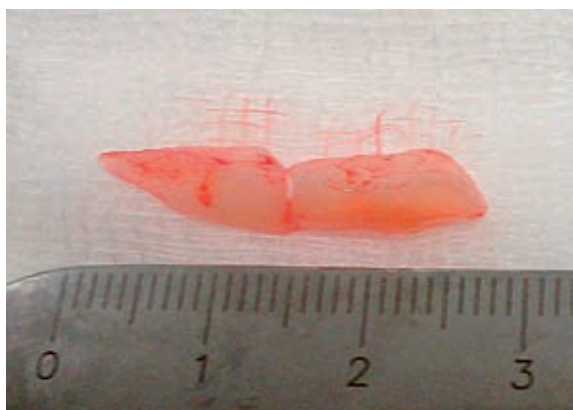


Fig. 4. Surgically excised part of enlarged *gingivae*

Ryc. 4. Fragment przerośniętego dziąsła usunięty chirurgicznie

## Discussion

GF is the fibrous enlargement of gingiva. There are multiple factors involved in the development of this condition; several reports show that it may be hereditary or drug-induced. In some cases, when the etiological factor cannot be defined, it is considered to be idiopathic. There is also the possibility that trauma and/or irritating factor could be a contributory cause.

In the present case, a histopathological evaluation of the gingival biopsy revealed abnormal, thickened collagen fibers with irregular orientation throughout the connective tissue. The presence of atypical, irregular collagen fiber bundles may result from abnormal growth of fibroblasts residing in the gingival connective tissue, an increased synthesis of pro-fibrogenic cytokines, disturbances in the enzymes processing collagen molecules within cells, or the enzymes involved in collagen triple-helices modification after their secretion into extracellular space. The precise cellular and molecular mechanism responsible for fibrous overgrowth, in particular fibrous overgrowth located in the oral cavity, is poorly understood and may differ depending on the type of etiological factor inducing abnormal growth within the gingiva [25, 26]. Histopathological evaluation also revealed mild epithelial hyperplasia with singular elongated rete pegs extending into the underlying connective tissue. The inflammatory infiltrate consisted mostly of mononuclear cells and was observed in areas surrounding the epithelial rete pegs. In dense, thickened connective stroma, dilated venous vessels were also visible (Fig. 3 A–D). Similar histopathological characteristics of gingival overgrowth were reported by others as gingival fibromatosis [2, 5, 18, 23]. These observations suggest that inflamed lesions are chronic in character in the gingival overgrowth presented in this case.

The most common condition resulting from the permanent influence of irritating or traumatic factors in the oral cavity is irritation fibroma. This is a tumor-like, asymptomatic, moderately firm lesion which in most cases represents reactive focal fibrous hyperplasia with typically dense stroma abundant in randomly arranged collagen fibers. In contrast to oral fibromatosis, which develops exclusively within the gingiva, fibroma may occur in any oral site. It is most commonly seen in the buccal mucosa along the plane of occlusion, the tongue, lips and the palate. Less frequently, fibromas appear in the gingiva, and have sometimes been called “peripheral ossifying fibroma”, “peripheral cementifying fibroma”, or “peripheral odontogenic fibroma” since areas of diffuse or focal calcification or even ossification are visible in these lesions. The surface of fibromas is covered with a layer of stratified squamous epithelium, which frequently appears stretched and with shortening and flattening of the rete pegs. Fibroma is also characterized by the relative acellularity of the connective tissue. In contrast, histopathological picture of gingival fibromatosis reveals the presence of elongated rete pegs which extend into underlying connective tissue as well as the proliferation of mature spindle cells arranged in interlacing fascicles [27].

The relevant treatment modality for gingival overgrowth is adjusted depending on the type, severity (localized or general) and occurrence period of the condition. Adequate oral hygiene and scaling are satisfactory for localized and minor lesions, whereas long-drawn and/or diffuse GO require surgical treatment. Various excision techniques used for gingival overgrowth include external or internal bevel gingivectomy followed by gingivoplasty, apically positioned flaps, electrocautery and carbon dioxide lasers. In the current case, the complete excision of the lesion was considered first of all. However, because of the high risk of complications during surgery we decided to modify the procedure and perform an internal bevel incision, excise the excess tissue, mobilize the flap and then suture the wound.

The finest and suggested treatment modality for GF is external or internal gingivectomy [17–19, 28–30]. However, surgical procedures demand a close follow-up because of relatively high recurrence rate. In the case presented here, the healing was uneventful and no recurrence was observed one year after treatment. Accordingly, in several other cases, surgical treatment resulted in uneventful healing and no recurrence was observed, respectively, after a 1-year [28, 30], 2-year [18] or 5-year [19, 29] follow-up. The outcome of the treatment should restore the functional, masticatory and esthetic needs of the patient, and finally should be chosen according to the individual case.



Partial excision of the gingival tissue, and modifications of the alternative recommended surgical treatments may be highly effective and result in significant clinical improvement in

some cases of gingival enlargement. It is, in particular, applicable in cases involving a high risk because of the location of the pathological overgrowth.

## References

- [1] HASSELL T.M., HEFTI A.F.: Drug induced gingival overgrowth: old problem, new problem. *Crit. Rev. Oral Biol. Med.* 1991, 2, 103–137.
- [2] GAGLIANO N., MOSCHENI C., DELLAVIA C., MASIERO S., TORRI C., GRIZZI F., STABELLINI G., GIOIA M.: Morphological and molecular analysis of idiopathic gingival fibromatosis: a case report. *J. Clin. Periodontol.* 2005, 32, 1116–1121.
- [3] SENGUN D., HATIPOGLU H., HATIPOGLU M.G.: Long-term uncontrolled hereditary gingival fibromatosis: a case report. *J. Contemp. Dent. Pract.* 2007, 8, 90–96.
- [4] KOLTE A.P., KOLTE R.A., SHRIRAO T.S.: Focal fibrous overgrowths: a case series and review of literature. *Contemp. Clin. Dent.* 2010, 1, 271–274.
- [5] MARTELLI JR H., SANTOS S.M., GUIMARAES A.L., PARANAIBA L.M., LARANJEIRA A.L., COLETTA R.D., BONAN P.R.: Idiopathic gingival fibromatosis: description of two cases. *Minerva Stomatol.* 2010, 59, 143–148.
- [6] SEYMOUR R.A., JACOBS D.J.: Cyclosporin and the gingival tissues. *J. Clin. Periodontol.* 1992, 19, 1–11.
- [7] DONGARI A., McDONNELL H.T., LANGLAIS R.P.: Drug-induced gingival overgrowth. *Oral Surg. Oral Med. Oral Pathol.* 1993, 76, 543–548.
- [8] BRUNET L., MIRANDA J., FARRE M., BERINI L., MENDIETA C.: Gingival enlargement induced by drugs. *Drug Saf.* 1996, 15, 219–231.
- [9] HUANG J.S., HO K.Y., CHEN C.C., WU Y.M., WANG C.C., HO Y.P., LIU C.S.: Collagen synthesis in idiopathic and dilantin-induced gingival fibromatosis. *Kaohsiung J. Med. Sci.* 1997, 13, 141–148.
- [10] HART T.C., PALLOS D., BOWDEN D.W., BOLYARD J., PETTENATI M.J., CORTELLI J.R.: Genetic linkage of hereditary gingival fibromatosis to chromosome 2p21. *Am. J. Hum. Genet.* 1998, 62, 876–883.
- [11] SHASHI V., PALLOS D., PETTENATI M.J.: Genetic heterogeneity of gingival fibromatosis on chromosome 2p. *J. Med. Genet.* 1999, 36, 683–686.
- [12] HART T.C., PALLOS D., BOZZO L., ALMEIDA O.P., MARAZITA M.L., O'CONNELL J.R., CORTELLI J.R.: Evidence of genetic heterogeneity for hereditary gingival fibromatosis. *J. Dent. Res.* 2000, 79, 1758–1764.
- [13] GORLIN R.J., PINBORG J.J., COHEN JR M.M.: *Syndromes of the head and neck.* 2nd edition, New York: McGraw Hill, 1976, 329–336.
- [14] MARTELLI-JUNIOR H., BONAN P.R., DOS SANTOS L.A., SANTOS S.M., CAVALCANTI M.G., COLETTA R.D.: Case report of a new syndrome associating gingival fibromatosis and dental abnormalities in a consanguineous family. *J. Periodontol.* 2008, 79, 1287–1296.
- [15] MARTELLI-JUNIOR H., SANTOS C.O., BONAN P.R., MOURA P.F., CAVALCANTE B.C., LEON J.E., COLETTA R.D.: Minichromosome maintenance 2 and 5 expressions are increased in the epithelium of hereditary gingival fibromatosis associated with dental abnormalities. *CLINICS (Sao Paulo)* 2011, 66, 753–757.
- [16] SAKAMOTO R., NITTA T., KAMIKAWA Y., KONO S., KAMIKAWA Y., SUGIHARA K., TSUYAMA S., MURATA F.: Histochemical, immunohistochemical, and ultrastructural studies of gingival fibromatosis: a case report. *Med. Electron. Microsc.* 2002, 35, 248–254.
- [17] TAVARGERI A.K., KULKARNI S.S., BASAVPRABHU S.P.: Idiopathic gingival fibromatosis – a case report. *J. Indian Soc. Pedod. Prev. Dent.* 2004, 22, 180–182.
- [18] JAJU P.P., DESAI A., DESAI R.S., JAJU S.P.: Idiopathic gingival fibromatosis: case report and its management. *Int. J. Dent.* 2009, 153603. Accessed Mar 10, 2010.
- [19] SEKI K., SATO S., ASANO Y., AKUTAGAWA H., ITO K.: Improved pathologic teeth migration following gingivectomy in a case of idiopathic gingival fibromatosis. *Quintessence Int.* 2010, 41, 543–545.
- [20] GONTIYA G., BHATNAGAR S., MOHANDAS U., GALGALI S.R.: Laser-assisted gingivectomy in pediatric patients: a novel alternative treatment. *J. Indian Soc. Pedod. Prev. Dent.* 2011, 29, 264–269.
- [21] SALINAS C.F.: Oro-dental findings and genetic disorders. *Birth Defects* 1982, 18, 79–120.
- [22] CASAVECCHIA P., UZEL M.I., KANTARCI A., HASTURK H., DIBART S., HART T.C., TRACKMAN P.C., VAN DYKE T.E.: Hereditary gingival fibromatosis associated with generalized aggressive periodontitis: a case report. *J. Periodontol.* 2004, 75, 770–778.
- [23] CHATURVEDI R.: Idiopathic gingival fibromatosis associated with generalized aggressive periodontitis: a case report. *J. Can. Dent. Assoc.* 2009, 75, 291–295.
- [24] SANDHU S.P., KAKAR V., GOGIA G., NARULA S.C.: Unilateral gingival fibromatosis with localized aggressive periodontitis (involving first molars): An unusual case report. *J. Indian Soc. Periodontol.* 2009, 13, 109–113.
- [25] KATAOKA M., KIDO J.I., SHINOHARA Y., NAGATA T.: Drug-induced gingival overgrowth – a review. *Biol. Pharm. Bull.* 2005, 28, 1817–1821.
- [26] GUO F., CARTER D.E., LEASK A.: Mechanical tension increases CCN2/CTGF expression and proliferation in gingival fibroblasts via TGF $\beta$ -dependent mechanism. *PLoS ONE* 2011, 6, e19756.
- [27] RANGEETH B.N., MOSES J., KISHORE V., REDDY K.: A rare presentation of mucocele and irritation fibroma of the lower lip. *Contemp. Clin. Dent.* 2010, 1, 111–114.

- [28] RAMNARAYAN B.K., SOWMYA K., REMA J.: Management of idiopathic gingival fibromatosis: report of a case and literature review. *Pediatr. Dent.* 2011, 33, 431–436.
- [29] LOBAO D.S., SILVA L.C., SOARES R.V., CRUZ R.A.: Idiopathic gingival fibromatosis: a case report. *Quintessence Int.* 2007, 38, 699–704.
- [30] AKCA A.E., ORTAKOGLU K., PIKDOKEN L., DEVECİ S.: Histopathological evaluation of five unusual gingival enlargement cases. *Mil. Med.* 2005, 170, 986–990.

### **Address for correspondence:**

Maria Chomyszyn-Gajewska  
Department of Periodontology and Oral Medicine  
Jagiellonian University  
Medical College  
Montelupich 4  
30-387 Krakow  
Poland  
Tel./fax: +48 12 4245420  
E-mail: mdgajews@cyf-kr.edu.pl

Conflict of Interest: None declared

Received: 16.05.2014

Revised: 13.06.2014

Accepted: 8.08.2014

Praca wpłynęła do Redakcji: 16.05.2014 r.

Po recenzji: 13.06.2014 r.

Zaakceptowano do druku: 8.08.2014 r.