

Anomalous origin and interarterial course of the right coronary artery: diagnostic and therapeutic dilemmas

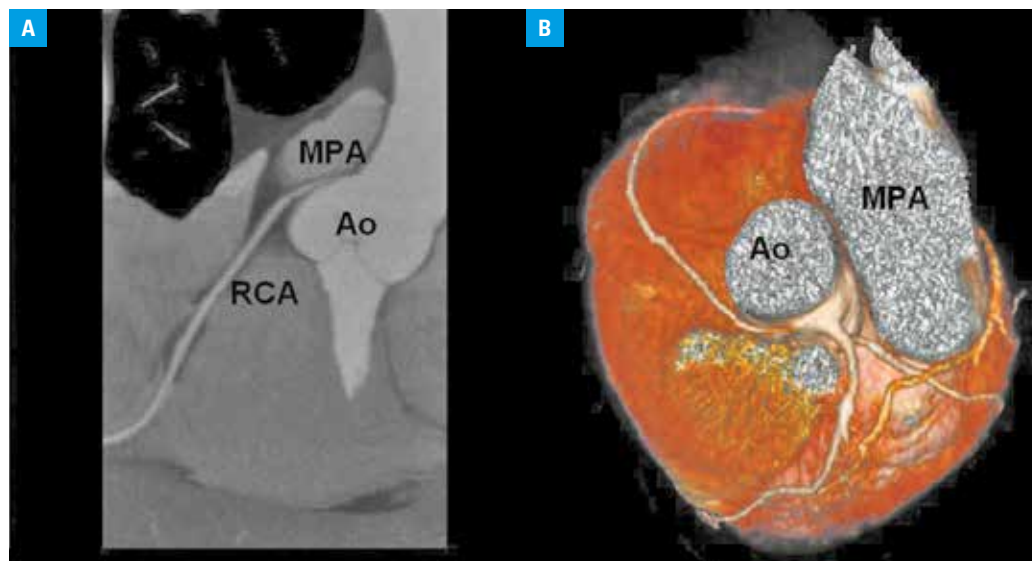
Agnieszka Skrzypek¹, Andrzej Gackowski¹, Wojciech Szot², Robert Banyś², Jadwiga Nessler¹, Grzegorz Gajos¹

¹ Department of Coronary Disease, Institute of Cardiology, Jagiellonian University Medical College, Kraków, Poland

² Centre for Diagnosis, Prevention and Telemedicine, John Paul II Hospital, Kraków, Poland

A 41-year-old woman with a history of arterial hypertension, hypercholesterolemia, positive family history, and atypical chest pain was referred for an exercise stress test. It was clinically negative, but electrocardiography was positive. The results of an echocardiographic examination were normal. To exclude coronary artery disease, multislice computed tomography of the coronary arteries was performed (FIGURE 1A–C). The scan revealed an anomalous origin of the right coronary artery (RCA) from the left sinus of Valsalva. The initial 5-mm part of the artery was found to course intramurally in the wall of the aorta, and critical ostial stenosis was suspected (FIGURE 1A–C). Therefore, conventional coronary angiography was performed. It confirmed coronary anomaly and demonstrated a borderline (50%–60%) stenosis at the ostium of the RCA (FIGURE 1D). An

origin of the RCA from the left sinus of Valsalva is an extremely rare anomaly found in approximately 0.019% to 0.49% of patients undergoing coronary angiography.¹ An abnormal RCA origin may be either a benign and asymptomatic finding or a high-risk anatomical feature. Patients with the abnormal RCA origin may have a slit-like orifice and intramural or interarterial course (between the aorta and pulmonary artery).² The artery may be compressed, and acute ischemia may occur.^{1,3} Moreover, an acute take-off angle and compression of the intramural segment narrowing the orifice may cause flow limitation. For this reason, such anatomic variants are considered potentially malignant. However, not all cases of the abnormal RCA origin have clinical implications because sudden cardiac death is rare in asymptomatic patients with this anomaly.



Correspondence to:

Agnieszka Skrzypek, MD, PhD,
Klinika Choroby Wierćcowej
i Niewydolności Serca, Krakowski
Szpital Specjalistyczny im.
Jana Pawła II, ul. Prądnicza 80,
31-202 Kraków, Poland,
phone: +48-12-614-22-18,
fax: +48-12-614-22-19, e-mail:
agnieszka.skrzypek@gmail.com
Received: December 9, 2014.

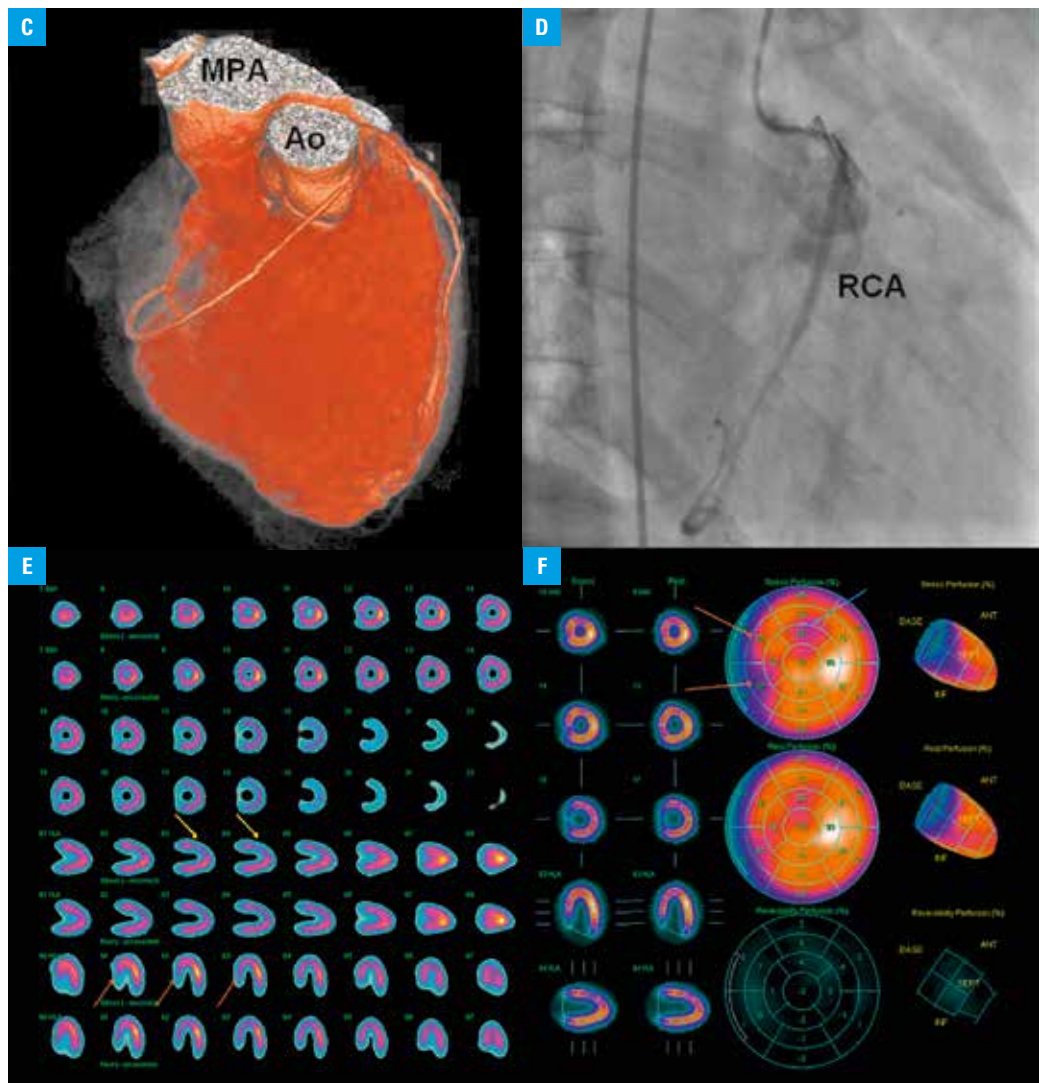
Revision accepted:
December 10, 2014.

Published online:
December 10, 2014.

Conflict of interest: none declared.
Pol Arch Med Wewn. 2014;
124 (12): 746-747
Copyright by Medycyna Praktyczna,
Kraków 2014

FIGURE 1 **A** – coronary angiography of the right coronary artery (RCA); **B**, **C**, **D** – computed tomography: RCA originating intramurally from the left sinus of Valsalva; **E** – discrete, nonsignificant perfusion defects in anteroseptal (yellow arrows) and inferoseptal segments (orange arrows); **F** – discrete, nonsignificant perfusion defects in the septal (orange arrows) and anterior segments (blue arrow)

Abbreviations: Ao – aorta, MPA – main pulmonary artery



Moreover, no sudden death occurs in children under 10 years of age or adults over 30 years of age.¹ Therefore, the treatment of an anomalous RCA with an interarterial course from the left coronary sinus is controversial.

It is suggested that young patients (<35 years of age) with anginal symptoms or ischemia on noninvasive testing should undergo surgery, but if no anginal symptoms or ischemia is present, the therapy is uncertain. Older patients without anginal symptoms or ischemia do not need surgical therapy.¹ These patients may be treated medically with an excellent long-term follow-up and no documentation of cardiac ischemia.³ It is important to limit strenuous exercise.

In our patient, we performed myocardial perfusion scintigraphy to assess the extent of ischemia. During submaximal exercise, there were only discrete perfusion defects localized outside the RCA myocardial blood supply (FIGURE 1E,F). After heart team consultation, we decided to treat the patient with medical therapy (β -blocker). No complaints and adverse events were noticed during a 1-year follow-up.

REFERENCES

- 1 Lee BY. Anomalous right coronary artery from the left coronary sinus with an interarterial course: is it really dangerous? *Korean Circ J*. 2009; 39: 175-179.
- 2 Krupiński M, Urbańczyk-Zawadzka M, Laskowicz B, et al. Anomalous origin of the coronary artery from the wrong coronary sinus evaluated with computed tomography: "High-risk" anatomy and its clinical relevance. *Eur Radiol*. 2014; 24: 2353-2359.
- 3 De Pooter J, Van Driessche L, Bartunek J. Aberrant right coronary artery arising from the left sinus of Valsalva with an interarterial course. *Acta Cardiol*. 2014; 69: 185-188.
- 4 Cho SH, Joo HC, Yoo KJ, Youn YN. Anomalous Origin of Right Coronary Artery from Left Coronary Sinus: Surgical Management and Clinical Result. *Thorac Cardiovasc Surg*. 2014; 6: 9.