

Prostate cancer in patients from rural and suburban areas – PSA value, Gleason score and presence of metastases in bone scan

Wojciech Szot^{1,2}, Magdalena Kostkiewicz^{2,3}, Joanna Zając¹, Alfred Owoc⁴, Iwona Bojar⁵

¹ Hygiene and Diet Department, Jagiellonian University Medical College, Cracow, Poland

² Nuclear Medicine Department, John Paul II Hospital, Cracow, Poland

³ Cardiovascular Diseases Department, Jagiellonian University Medical College, Cracow, Poland

⁴ Higher School of Public Health, Zielona Góra, Poland

⁵ Department for Health Problems of Ageing, Institute of Rural Health, Lublin, Poland

Szot W, Kostkiewicz M, Zając J, Owoc A, Bojar I. Prostate cancer in patients from rural and suburban areas – PSA value, Gleason score and presence of metastases in bone scan. *Ann Agric Environ Med*. 2014; 21(4): 888–892. doi: 10.5604/12321966.1129953

Abstract

Introduction. Prostate cancer is the second most common neoplasm among men both worldwide and in Poland.

In prostate cancer, bone metastasis is related to a poorer prognosis. A diagnosis of metastatic bone disease is important in prostate cancer patients prior to therapy. Prostate specific antigen (PSA) serum value is used both as a screening tool and for staging of prostate cancer.

Aim. To evaluate whether there is a link between symptoms presented by patients, pain in particular, and the presence, number and location of bone metastases as assessed by bone scan scintigraphy in concordance with PSA values and Gleason scores.

Material. A group of 186 patients (aged: 68.38±6.16) diagnosed with prostate cancer, from rural and suburban areas of Małopolska province, that was directed for bone scan scintigraphy to the Nuclear Medicine Dept, John Paul II Hospital in Kraków.

Methods. Analysis of all laboratory findings (including PSA value) and a biopsy were performed. Then, bone scan scintigraphy was done with the use of methylene diphosphonate (MDP) labeled with Tc-99m.

Results. In patients with a Gleason value ≤7 and a PSA value ≤20 ng/ml, the cutoff value for a negative bone scan with a confidence interval of 0.95 was established at a PSA value below 10 ng/ml ($p < 0.01$). Correlations were established between PSA value and presence of metastases in bone scan ($r = 0.45$, $p = 0.05$), the number of metastases ($r = 0.66$, $p < 0.01$), and their presence in particular body regions.

Conclusions. The correlation between PSA value and both presence and number of metastases confirms the usefulness of bone scan scintigraphy in prostate cancer staging. The cutoff value for negative bone scan with a 95% confidence interval was established at PSA = 10 ng/ml.

Key words

Prostate cancer, bone scan, metastases, PSA value

INTRODUCTION

Prostate cancer is still the most prevalent type of malignancy among males, with an incidence rate of 214 cases per 1000 men, outnumbering lung and colorectal cancer and, while progress has been made towards improved methods of therapy, it is still the sixth-leading cause of cancer deaths among men (6.1% of total) [1], with an estimated 258,000 deaths in 2008. Incidence rates based on PSA screening of prostate cancer vary by a factor of more than 25 worldwide (the highest rates are in Australia/New Zealand (104.2 per 100,000), western and northern Europe, and North America, largely because the practice of prostate specific antigen (PSA) testing and subsequent biopsy has become widespread in those regions). Mortality rates are generally high in predominantly black populations (the Caribbean, 26.3 per 100,000 and sub-Saharan Africa, 18–19 per 100,000),

very low in Asia and intermediate in the rest of Europe and Oceania (IARC data) [1, 2]

There are three well-established risk factors for developing prostate cancer: aging, ethnic origin (black population) and genetic predisposition. Clinical and epidemiological data also suggest roles for diet, pattern of sexual behavior, excessive alcohol consumption, exposure to ultraviolet radiation and occupational exposure in rural areas to chemicals and pesticides used in agriculture that may also play a role in the risk of developing prostate cancer. Patterns of behavior reported to have preventive properties include certain diets (low-fat diet, use of plant-based fats) and regular physical exertion [3].

The choice of most appropriate therapy among patients with prostate cancer is based on the proper staging of the disease at the time of diagnosis. Clinical staging procedures include digital serum PSA measurements, rectal examination, bone scan scintigraphy, and, if necessary in the case of enlarged adenoma and high probability of metastases other than to bone in some patients, computer tomography or magnetic resonance imaging studies. Bone is considered the second most common site, after lymph nodes, for metastases from

Address for correspondence: Iwona Bojar, Department for Health Problems of Ageing, Institute of Rural Health, Jaczewskiego 2, 20-090 Lublin, Poland
E-mail: iwonabojar75@gmail.com

Received: 27 May 2013; accepted: 24 June 2013

prostate cancer. Around 5% to 15% of patients first diagnosed with prostate cancer already have bone metastases as well. In patients who actually die of prostate cancer, metastases to the skeleton are found in more than 80% of patients. Thus proper staging and screening for the presence of bone metastases have a major impact on both the prognosis and choice of treatment for each individual patient [3, 4,5].

Bone scan scintigraphy with the use of Tc-99m-labeled methylene diphosphate is superior to all other imaging modalities and, thanks to its high accuracy in the detection of metastatic bone disease, is considered the most sensitive staging method for prostate cancer [2, 4, 5].

One of the routinely used methods in prostate cancer staging is prostate gland biopsy. The Gleason grading system is used for proper evaluation. Basically, a Gleason score is given to prostate cancer based upon its microscopic appearance in material obtained via biopsy. Cancers with higher Gleason scores tend to be more aggressive and have a worse prognosis than those with lesser scores. According to current international convention, the Gleason score of cancers detected in a prostate biopsy consists of the Gleason grade of the dominant (most extensive) carcinoma component plus the highest grade detected in other material, regardless of its extent. Then the two grades are added together to make a total Gleason score. The Gleason grade ranges from 1 to 5 and the Gleason score from 2 to 10, with 10 indicating the worst prognosis [5].

Among published papers on early detection and staging of prostate cancer, much stress is placed on the low value of baseline bone scan scintigraphy if PSA levels are less than 10 ng/ml [6], or on the suggestion to avoid bone scintigraphy when combined PSA values are less than 10 ng/ml and the Gleason score is less than 7 [7, 8]. Other papers suggest avoiding bone scan scintigraphy in the case of PSA levels less than 15 ng/ml [9]. It has also been stated in current guidelines [4] that "skeletal metastasis (M staging) is best assessed by bone scan. This may not be indicated in asymptomatic patients if the serum PSA level is <20 ng/ml in the presence of well-differentiated or moderately differentiated tumors. "The cited guidelines are based on well-conducted clinical studies, but without randomized clinical trials and have recommendation grade B.

However, to the authors' knowledge, many patients sent to undergo a bone scan scintigraphy are asymptomatic, while having visible bone metastases.

Toward this end, our aims for the study were:

- To evaluate whether there are links between PSA values and presence and number and location of bone metastases as assessed by bone scan scintigraphy.
- To evaluate whether there is a link between Gleason score and presence, number and location of bone metastases as assessed by bone scan scintigraphy.
- To evaluate whether there is a link between symptoms presented by patients, pain in particular, and presence, number and location of bone metastases as assessed by bone scan scintigraphy in concordance with PSA values and Gleason score.

MATERIAL AND METHODS

A group of 186 patients (aged: 68.38 ± 6.16) from rural and suburban areas of Małopolska province, with newly-diagnosed, untreated prostate cancer, directed for bone scan scintigraphy to the Nuclear Medicine Dept., John Paul II Hospital in Kraków from January 2010 to December 2012, were included in this study. The average time since diagnosis in the studied group was 1.24 ± 1.3 months. For all patients, adenocarcinoma had been confirmed by core biopsies (obtained from pathology reports, the medical charts of each patient, or both) resulting in an average Gleason score from biopsy results of 6.49 ± 1.1 . Serum PSA determinations were obtained within 2 months prior to the bone scan with an average value of 20.84 ± 21.12 ng/ml within the studied group.

Following a careful review of their history, all patients answered a questionnaire regarding pain localization and intensity in regard to general pain and localized pain, using the Universal Pain Assessment tool and 10-point scale [10] in which 0 equals "no pain" and 10 equals "worst pain possible" as well as Activity Tolerance Scale, in which 0 equals "no pain" and 10 equals "bedrest required".

Next, whole-body scintigraphy bone scans were performed 3 to 4 hours after intravenous injection of 700–840 MBq Tc-99m methylene diphosphate. All images were obtained using a large-field-of-view SIEMENS E.CAM dual-head gamma camera equipped with a parallel-hole, Low Energy-High Resolution (LEHR) collimator. The bone scans were evaluated independently by two nuclear medicine physicians (WS and MK) and were interpreted as negative or positive for scintigraphic evidence of bone metastases. The presence of skeletal metastasis in a bone scan was defined when either solitary or multiple asymmetric areas of increased uptake of the tracer occurred, excluding tracer accumulations related to previous trauma and degenerative bone diseases. All lesions suspected of being metastases were counted and evaluated in additional studies such as radiographs, CT or MRI performed to confirm the presence of bone metastases. Data were also compared with each patient's history, excluding tracer accumulations related to previous trauma and degenerative bone diseases. Sometimes, in patients with disseminated bone metastases, because of substantial uptake of the radiotracer in multiple metastatic bone lesions, the kidneys were not visualized in the bone scan. This pattern is termed "superscan" and is associated with a poor prognosis. Patients with "superscan" were excluded from the study. No patient was on hormonal therapy at the time of the data acquisition.

The gathered data were used to establish the final interpretation of the bone scans. In addition, bone scans were divided into areas (skull, spinal column, ribs, pelvis and extremities) to match areas previously identified using the Universal Pain Assessment questionnaire.

Bone scan findings were confirmed with plain radiographs, CT or MRI studies. Pain intensity scores and locations from patients' anamnesis, serum PSA levels and Gleason scores were correlated with the bone scan findings. Statistical comparisons were made using a student t-test or a chi-squared test; correlations were established using Pearson's test. Values of $p < 0.05$ were considered significant.

RESULTS

The average BMI in studied group was 26.13 ± 2.87 (min.: 21.38, max. 36.29, median: 25.79). Gleason score and PSA values for the studied group are shown in Table 1 and Fig. 1.

Table 1. Characteristics of the study group

Gleason score	Number of patients	%
5	34	18.28
6	61	32.8
7	53	28.49
8	29	15.59
9	9	4.84
PSA value	Number of patients	%
0–10	72	38.71
10.1–20.0	60	32.26
20.1–40.0	21	11.29
>40.1	33	17.74

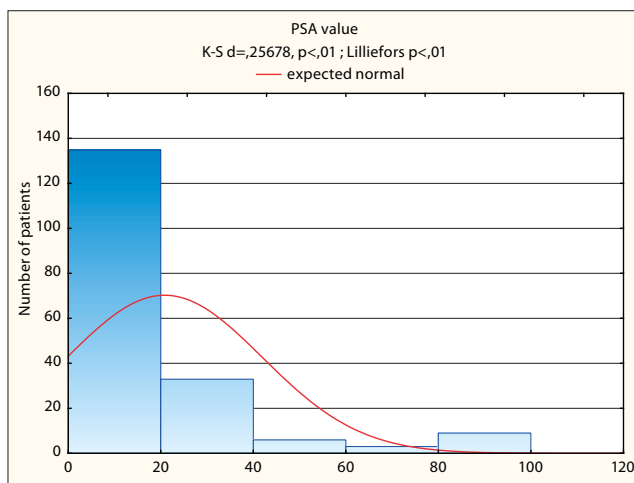


Figure 1. PSA value in studied group

A positive bone scan result for the presence of metastases was found in 87 patients (46.77%) from the studied group.

Of the patients with PSA values below 10 ng/ml (of 72 patients: 22 with a Gleason score of 5; 30 with a score of 6; 20 with a score of 7), 37 had no evidence of skeletal metastasis, while in 32 single suspected lesions were excluded in CT or MRI from being of metastatic origin. In the remaining 3 patients (4.16%), all of them with Gleason scores of 7, lesions were confirmed as metastatic. Of the remaining patients, 32 of 60 patients (53.33%) with a serum PSA 10.1–20.0 ng/ml, 19 of 21 patients (90.48%) with a serum PSA 20.1–40.0 ng/ml, and 33 of 33 patients (100%) with a serum PSA >40 ng/ml had positive bone scans for presence of metastases.

Of the 32 patients with positive bone scan results and serum PSA level 10.1–20.0 ng/ml, 10 patients had Gleason scores of 6; 16 had scores of 7; 3 had scores of 8; and 3 had scores of 9.

Based on the above-mentioned data, in the group of 132 with PSA value <20 ng/ml (35 of them with positive result of bone scan), the cutoff value for negative bone scan with a confidence interval of 0.95 was established at a PSA value below 10 ng/ml ($p < 0.01$). When combining PSA value and Gleason score <7 and a negative bone scan with a confidence

interval of 0.95, the cutoff value was established at a PSA value below 13 ng/ml ($p < 0.01$).

As a separate analysis, we evaluated a group of 95 men with Gleason scores ≤ 6 . Of this group, 19 (20%) were confirmed to have a positive bone scan, 10 (10.53%) of them with a PSA level <20 ng/ml. The cutoff value for this group, with a confidence interval of 0.95, was established at a PSA value below 12 ng/ml ($p < 0.01$).

In the studied group, a correlation was found ($r = 0.66$, $p < 0.05$ – fig. 2) between PSA value and the number of metastases on the bone scan, as well as a correlation between PSA serum and Gleason score in the studied group ($r = 0.45$, $p < 0.05$).

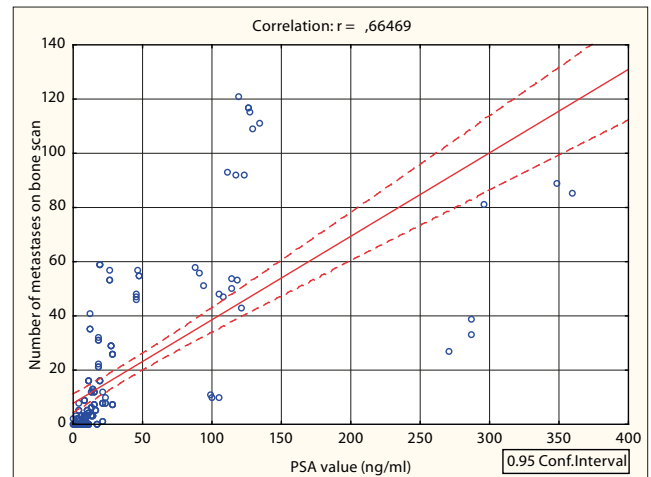


Figure 2. Correlation between PSA values and number of metastases on bone scan

Correlations were also found between both PSA value and Gleason score and the presence of metastases in particular regions (table 2).

Table 2. Correlations between PSA values and Gleason score with presence of metastases in particular regions (r values, all $p < 0.05$)

	Skull	Vertebral column	Ribs, sternum	Pelvis	Extremities
PSA value	0.31	0.61	0.60	0.70	0.53
Gleason score	0.38	0.61	0.62	0.58	0.47

No correlation was found between pain intensity and both PSA value and presence of metastases. Neither did we find any correlations between localization of symptoms presented by patients and the actual localization of bone metastases in bone scan.

DISCUSSION

The foremost aim of our study was to determine whether a PSA cutoff of 20 ng/ml, as suggested in the European Association of Urology Guidelines, is warranted. Toward this end we studied a group of patients suffering from newly-diagnosed prostate cancer. Our gathered data from performed bone scans support previously published studies demonstrating the close relationship between serum PSA level and bone scan positivity [6, 11, 12]. In our study, 35 of 132 patients with a serum PSA <20 ng/ml had a positive bone scan. Therefore, for the study group, the cutoff value

for negative bone scan with a confidence interval of 0.95 was established at a PSA value below 10 ng/ml ($p < 0.01$). When combining PSA value and Gleason score < 7 , the negative bone scan with a confidence interval of 0.95 was established at a PSA value below 13 ng/ml ($p < 0.01$). Based on data from our study, we conclude that the European Association of Urology guidelines warrant further discussion and trials including populations from different regions.

The European Association of Urology guidelines [4, 5] recommend staging baseline bone scan scintigraphy in all patients with poorly differentiated tumors (Gleason score > 7) and locally advanced disease ($\geq cT3$) irrespective of the serum PSA value. Conversely, in patients with PSA < 20 ng/ml, the guidelines indicate the need for a staging bone scan only in the presence of poorly differentiated prostate cancer and in symptomatic patients.

Liu et al. [7] suggested that for patients with PSA ≤ 10 ng/ml or simultaneous PSA ≤ 50 ng/ml and Gleason score ≤ 7 and clinical stage $\leq T2$, a bone scan is not necessary. Bantis et al. [13] propose even broader criteria, stating that a combination of Gleason score > 8 and PSA > 20 ng/ml is a significant predictor of the presence of bone metastases. Others, like Briganti et al. and De Nunzio et al. [8, 14] proposed a novel classification and regression tree (CART) model, including PSA, clinical stage and biopsy Gleason score as covariates. Using this model, they stratified patients into low risk (biopsy Gleason ≤ 7 , $cT1-T3$, and PSA < 10 ng/ml), intermediate risk (biopsy Gleason ≤ 7 , $cT2/T3$, and PSA > 10 ng/ml), and high risk of positive bone scan results (biopsy Gleason > 7). When compared by Briganti and De Nunzio with the European Association of Urology guidelines, the CART model was significantly more accurate. We neither had access to data regarding local advance of the disease, nor could we establish it ourselves at the Nuclear Medicine Dept., but apart from that our data seem to be in agreement with that of Briganti and De Nunzio.

Tanaka et al. [15] presented a large group of patients with even lower Gleason scores for which the incidences of bone metastases in patients with a prostate-specific antigen level of ≤ 20 ng/ml and Gleason score of ≤ 6 were reasonably low. They conclude that a bone scan is not necessary as a routine examination for these patients at the initial staging of prostate cancer. In our group the cutoff value with a confidence interval of 0.95 was established at a PSA value below 12 ng/ml ($p < 0.01$), which is lower than the group studied by Tanaka et al. We took into consideration, however, the fact that in our group, from suburban and rural areas of Małopolska region, probably due to lesser awareness of the disease and lesser availability of screening tests, low-grade prostate cancers may have gone unrecognized for years, allowing more time for the development of bone metastases. Such situation among people from suburban and rural areas is not unheard of, and have been reported by other authors in case of, for example, breast cancer or lung cancer [16,17].

Gleason scores have been suggested by many authors as useful predictors of positive bone scans [6,18]. It has been stated that the risk of a positive bone scan increases with advanced stages and higher grades of prostate cancer. As a result of the introduction and wide usage of PSA as a readily-available tumor marker for prostate cancer, the majority of patients now have low serum PSA levels. However, in our group, from suburban and rural areas of the Małopolska region, many initial PSA results were quite high. Thus, in

our study, working with a broad range of PSA values at the time of diagnosis, we confirmed the existence of a correlation between both PSA values and Gleason score with positive bone scan results and the number of metastases present.

Pal et al. [19] suggest that a bone scan is of limited value in asymptomatic prostate cancer patients with PSA < 20 ng/ml, which is in agreement with the European Association of Urology guidelines. Furthermore, digital rectal examination findings, biopsy Gleason score and age are not helpful in predicting who might harbor bone metastasis [19]. Analysis performed during the course of our study regarding symptoms presented by patients and possible correlation with presence of bone metastases did not yield any significant results. This may have been due to the so-called "community background" (rural environment: most men in our study were farmers used to hard physical work while suffering pain of various degrees from previous traumas and degenerative diseases). Thus, we conclude that symptomatology may play a lesser role in the diagnostic criteria for application of bone scan scintigraphy.

Finally we'd like to stress, that bone scan scintigraphy, remains in our opinion, an important tool for staging prostate cancer, as previously confirmed, along with Gleason score and PSA values [4, 5, 7, 20, 21]. We disagree with some authors [22] statements of limited value of bone scan as a first staging test. It's our opinion that there are still regions, in which patients may harbor the disease for surprisingly long period of time, thus making bone scan scintigraphy a necessity.

CONCLUSIONS

The correlation between PSA value and both presence and number of metastases confirms the usefulness of bone scan scintigraphy in prostate cancer staging. The cutoff value for negative bone scan in studied group with a 95% confidence interval was established at PSA = 10 ng/ml, which is a lower value than that recommended by the European Association of Urology. A Gleason score established through biopsy material examination is an independent predictor of metastatic bone disease. Pain intensity and localization do not correlate with the presence or number of metastases.

LIMITATION OF THE STUDY

Most patients referred for a bone scan by urologists or oncologists did not have any information in their medical history regarding local advance of the disease. These data could provide us with additional information regarding the influence of local advance, in addition to Gleason score results, on the presence of metastatic bone disease.

REFERENCES

1. Ferlay J, Shin HR, Bray F, Forman D, Mathers C, Parkin DM. GLOBOCAN 2008. Cancer Incidence and Mortality Worldwide: IARC CancerBase No. 10 Lyon. International Agency for Research on Cancer, France 2010 <http://globocan.iarc.fr/Default.aspx> (access: 2013.05.27).
2. Schröder FH, Wildhagen MF. Rotterdam Study Group of the 'European Randomised Study of Screening for Prostate Cancer' (ERSPC). Screening for prostate cancer: evidence and perspectives. *BJU Int* 2001; 88: 811–817.

3. Parnes HL, House MG, Tangrea JA. Prostate cancer prevention: strategies for agent development. *Curr Opin Oncol*. 2013; 25(3): 242–251.
4. Heidenreich A, Bellmunt J, Bolla M, Joniau S, Mason M, Matveev V, et al. European Association of Urology. EAU guidelines on prostate cancer. Part I: screening, diagnosis, and treatment of clinically localised disease. *Eur Urol*. 2011; 59(1): 61–71.
5. Heidenreich A, Aus G, Bolla M, Joniau S, Matveev VB, Schmid HP, et al. (2008) EAU guidelines on prostate cancer. *Eur Urol*. 2008. 53:68–80.
6. Kosuda S, Yoshimura I, Aizawa T, Koizumi K, Akakura K, Kuyama J, et al. Can initial prostate specific antigen determinations eliminate the need for bone scans in patients with newly diagnosed prostate carcinoma? A multicenter retrospective study in Japan. *Cancer* 2002; 94: 964–972.
7. Liu D, Wang W, Qiao LD, Zheng YP, Liu YX, Zhang GY, et al. The indication of bone scan for patients with newly diagnosed prostate cancer. *Zhonghua Wai Ke Za Zhi*. 2012; 50: 443–445.
8. De Nunzio C, Leonardo C, Franco G, Esperto F, Brassetti A, Simonelli G, et al. When to perform bone scan in patients with newly diagnosed prostate cancer: external validation of a novel risk stratification tool. *World J Urol*. 2013; 31(2): 365–369.
9. O'Sullivan JM, Norman AR, Cook GJ, Fisher C, Dearnaley DP. Broadening the criteria for avoiding staging bone scans in prostate cancer: a retrospective study of patients at the Royal Marsden Hospital. *BJU Int*. 2003; 92: 685–919.
10. Misailidou V, Malliou P, Beneka A, Karagiannidis A, Godolias G. Assessment of patients with neck pain: a review of definitions, selection criteria, and measurement tools. *J Chiropr Med*. 2010; 9: 49–59.
11. Ataus S, Citçi A, Alici B, Onder AU, Sönmezoğlu K, Erözenci A, et al. The value of serum prostate specific antigen and other parameters in detecting bone metastases in prostate cancer. *Int Urol Nephrol*. 1999; 31: 481–489.
12. Rydh A, Tomic R, Tavelin B, Hietala SO, Damber JE. Predictive value of prostate-specific antigen, tumour stage and tumour grade for the outcome of bone scintigraphy in patients with newly diagnosed prostate cancer. *Scand J Urol Nephrol*. 1999; 33: 89–93.
13. Bantis A, Grammaticos P. Prostatic specific antigen and bone scan in the diagnosis and follow-up of prostate cancer. Can diagnostic significance of PSA be increased? *Hell J Nucl Med*. 2012; 15(3): 241–246.
14. Briganti A, Passoni N, Ferrari M, Capitanio U, Suardi N, Gallina A, et al. When to perform bone scan in patients with newly diagnosed prostate cancer: external validation of the currently available guidelines and proposal of a novel risk stratification tool. *Eur Urol*. 2010; 57: 551–558.
15. Tanaka N, Fujimoto K, Shinkai T, Nakai Y, Kuwada M, Anai S, et al: Bone scan can be spared in asymptomatic prostate cancer patients with PSA of ≤ 20 ng/ml and Gleason score of ≤ 6 at the initial stage of diagnosis. *Jpn J Clin Oncol*. 2011; 41: 1209–1213
16. Maślach D, Krzyżak M, Szpak A, Owoc A, Gębska-Kuczerowska A, Bielska-Lasota M. Differences in results of breast cancer curative treatment between urban/rural female population in Podlaskie Voivodship of Poland before introduction of the National Cancer Control Programme. *Ann Agric Environ Med*. 2013; 20(1): 68–71.
17. Sawicki M, Szczyrek M, Krawczyk P, Rybojad P, Jablonka A, Milanowski J. Reasons for delay in diagnosis and treatment of lung cancer among patients in Lublin Voivodeship who were consulted in Thoracic Surgery Department. *Ann Agric Environ Med*. 2013; 20(1): 72–76.
18. Lee N, Fawaaz R, Olsson CA, Benson MC, Petrylak DP, Schiff PB. et al. Which patients with newly diagnosed prostate cancer need a radionuclide bone scan? An analysis based on 631 patients. *Int J Radiat Oncol Biol Phys*. 2000; 48: 1443–1446.
19. Pal RP, Thirudaian T, Khan MA. When is a bone scan study appropriate in asymptomatic men diagnosed with prostate cancer? *Asian J Androl*. 2008; 10: 890–895.
20. Hricak H, Choyke PL, Eberhardt SC, Leibel SA, Scardino PT. Imaging prostate cancer: a multidisciplinary perspective. *Radiology* 2007; 243: 28–53.
21. Stenman UH, Abrahamsson PA, Aus G, Lilja H, Bangma C, Hamdy FC, et al: Prognostic value of serum markers for prostate cancer. *Scand J Urol Nephrol Suppl*. 2005; 216: 64–81.
22. Carmona Echeverria LM, Drudge-Coates L, Wilkins CJ, Muir GH. Bone scan is of doubtful value as a first staging test in the primary presentation of prostate cancer. *ISRN Oncol*. 2012; 2012: 585017.