

**Aim of the study:** The objective of the study was to present the preliminary results of proton radiotherapy as a method for treating 15 patients with choroidal melanoma.

**Material and methods:** The proton radiotherapy was administered using beams providing energy levels of 60 MeV, which ensures a clinical range of 28.4 mm. In addition, the beam has a very narrow penumbra of 1.3 mm and a sharp distal dose fall-off. All patients received the dose of 60 CGE (cobalt gray equivalent) given to the PTV (planning target volume). This dose was administered in 4 fractions over 4 successive days of treatment.

**Results:** The tumour had regressed in 8 patients (53.3%) and remained stable in 3 patients (20%). The large tumours in another 3 patients (20%) were removed during vitrectomy (endoresection), which increased the number of patients with tumour regression up to 11 (73.3%). In the case of 1 patient, despite intraocular tumour regression occurring the choroidal melanoma had spread multifocally into the orbit, which necessitated orbit exenteration. The results ensured that the eyeballs of 14 patients (93.3%) could be saved. The follow-up period for the 15 patients ranged between 8 and 26 months (average: 17.4 months, median: 19 months). In this period some side effects were noted: an increase in intraocular pressure, retinal detachment, cataract, maculopathy, neuropathy and vitreous haemorrhaging.

**Conclusions:** The preliminary results confirm that proton radiotherapy is an effective method for treating patients with choroidal melanoma. This method ensures an eyeball preservation rate of 93%, with the vision function of 80% of the patients being saved.

**Key words:** ocular melanoma, choroidal melanoma, proton radiotherapy.

*Contemp Oncol (Pozn)* 2014; 18 (5): 359–366  
DOI: 10.5114/wo.2014.42233

# Preliminary results of proton radiotherapy for choroidal melanoma – the Kraków experience

Beata Sas-Korczyńska<sup>1,2</sup>, Anna Markiewicz<sup>2</sup>, Bożena Romanowska-Dixon<sup>2</sup>, Elżbieta Pluta<sup>2,3</sup>

<sup>1</sup>Department of Oncology, Maria Skłodowska-Curie Memorial Cancer Center and Institute of Oncology, Krakow Branch, Poland

<sup>2</sup>Department of Ophthalmology and Ocular Oncology Clinic, Jagiellonian University, *Collegium Medicum*, Krakow, Poland

<sup>3</sup>Department of Radiotherapy, Maria Skłodowska-Curie Memorial Cancer Center and Institute of Oncology, Krakow Branch, Poland

## Introduction

Ocular melanoma is a rare malignant neoplasm with the incidence rate estimated at 6–8 cases per one million [1, 2]. This translates into 3.7% of all cases of melanoma and makes it the second most frequent location for this neoplasm (after skin melanomas [1, 3]). On the other hand, choroidal melanoma is one of the most common primary intraocular malignant tumours affecting the eyeball and in most cases (82.5%) develops in the uvea.

The following are predisposing factors for choroidal melanoma: congenital ocular or oculodermal melanocytosis (nevus of Ota) and uveal nevus [4]. Furthermore, more than half of all patients have somatic mutations of the following genes: GNAQ, PTEN, GNA11 [5–10]. This carcinoma is most commonly diagnosed in persons aged 50–80 with fair skin colour, light eye colour and with reduced tolerance to sunlight.

Symptoms of choroidal melanoma depend on the location and dimensions of the tumour. They include the following: various visual disturbances (impaired vision with varying degrees of severity up to visual loss in the affected eye), photopsia, irritation and pain. It is important to note that 30% of tumours are asymptomatic and are only detected by accident during eye examinations [11, 12].

The basic treatment methods applied to patients with ocular choroidal melanoma are surgery and radiotherapy. The choice of treatment for patients with ocular choroidal melanoma depends on the location and size of the tumour, its local advancement, the effectiveness of a given method and its impact on maintaining the patient's visual function.

Possible surgical treatment includes procedures aimed at preserving the eyeball (endoresection or exoresection of the tumour) as well as more extensive operations such as enucleation of the eyeball [3].

Radiotherapy treatment is aimed at preserving the eyeball. It can take the form of either brachytherapy or teletherapy.

In the case of brachytherapy applicators are used (in the form of plaques) with a radioactive isotope (iodine-125, ruthenium-106, palladium-103) [13, 14]. This method has been practised since the 1930s and its 5-year survival rate of around 80% is comparable with the results observed for enucleation [15, 16]. Thanks to these factors and the possibility of preserving the eyeball, brachytherapy has become the standard procedure for patients with choroidal melanoma. However, the method has certain limitations due to post-radiation reaction and the risk of complications occurring in the healthy tissue surrounding tumours. This is the case with tumours located in the region of the macula and the optic disc, those that infiltrate the sclera and which are large in size.

The second radiotherapy method for treating patients with choroidal melanoma is teleradiotherapy, which makes use of stereotactic techniques (e.g. a gamma knife) together with intensity-modulated radiation therapy (IMRT) or a proton beam [3, 17, 18].

Local treatment makes it possible to preserve the eyeball and its functioning. However, it does have some effect on the survival rate [19, 20]. A particular role is played here by proton radiotherapy, which has been used to treat choroidal melanoma since the 1970s as an alternative procedure to enucleation (in the case of large tumours) or brachytherapy (in the case of tumours located close to the macula or the optic disc) [19, 21–24].

According to data from the PTCOG (Particle Therapy Co-Operative Group), patients with ocular melanoma make up 20% of all patients treated with proton radiotherapy [25].

In February 2011 in Kraków patients with choroidal melanoma began to be treated with proton radiotherapy.

### Aim of the study

The objective of the study was to present the preliminary results of proton radiotherapy as a method for treating patients with choroidal melanoma.

### Material and methods

Between February 2011 and March 2012 a total of 15 patients with choroidal melanoma underwent proton radiotherapy.

This group consisted of 7 women (46.7%) and 8 men (53.3%). The patients ranged in age between 38 and 74 with an average age of 56.1 (median 57 years).

The location and size of the tumour in the eyeball were determined in eye examinations conducted at the Depart-

ment of Ophthalmology and Ocular Oncology Clinic, Jagiellonian University.

### Patients

Presented in Table 1 are the characteristics of choroidal melanoma in the 15 patients.

In 10 of the 15 patients (66.7%) the tumour was located in the right eyeball. The tumour was predominantly located in the temporal quadrants of the choroid (53.3% of patients). Advanced T3 stage cancer was observed in 40% of the patients. The average distance of the margin of the tumour from the optic disc was 3.5 mm, and from the macula it was 2.21 mm. The average dimensions of the transverse (crosswise) and longitudinal (lengthwise) base of the tumour were 11.24 mm and 11.44 mm, respectively. The tumour thickness varied between 1.4 mm and 10.6 mm and was on average 5.05 mm.

### Proton radiotherapy procedure

The proton radiotherapy was administered using beams emitted from an AIC-144 isochronic cyclotron at the Institute of Nuclear Physics PAN in Kraków. These beams provide energy levels of 60 MeV, which ensures a clinical range of 28.4 mm. In addition, the beam has a very narrow penumbra of 1.3 mm and a sharp distal dose fall-off.

Prior to administering proton radiotherapy tantalum markers were sown to the sclera of the eyeball (an example is presented in Fig. 1) and the distance was measured between the markers and the corneal limbus as well as between the markers and the edge of the tumour. The position of the markers was verified using imaging tests (USG, CT, MRI). Figure 2 shows an example of marker position verification using magnetic resonance imaging (MRI).

**Table 1.** Characteristics of 15 patients with choroidal melanoma

Clinical features	No. of patients	%		
Treated eye				
right	10			55.7
left	5			33.3
Tumour localization – part of fundus:				
temporal	3			20.0
temporal – upper	3			20.0
temporal – lower	2			13.3
nasal – upper	3			20.0
nasal – lower	1			6.7
lower	2			13.3
optic disc	1			6.7
Tumour stage according to TNM system				
T1	4			26.7
T2	5			33.3
T3	6			40.0
<b>Values of distance and diameters</b>	<b>Range</b>	<b>Mean</b>	<b>Median</b>	<b>Standard deviation</b>
Tumour distance to:				
optic disc [mm]	0–7.50	3.50	3.30	2.13
macula [mm]	0–5.25	2.21	2.50	1.97
Tumour diameters [mm]				
transverse basal	8.10–17.40	11.24	10.50	2.59
longitudinal basal	7.80–16.20	11.44	10.60	2.75
tumour thickness	1.40–10.30	5.05	3.50	2.98

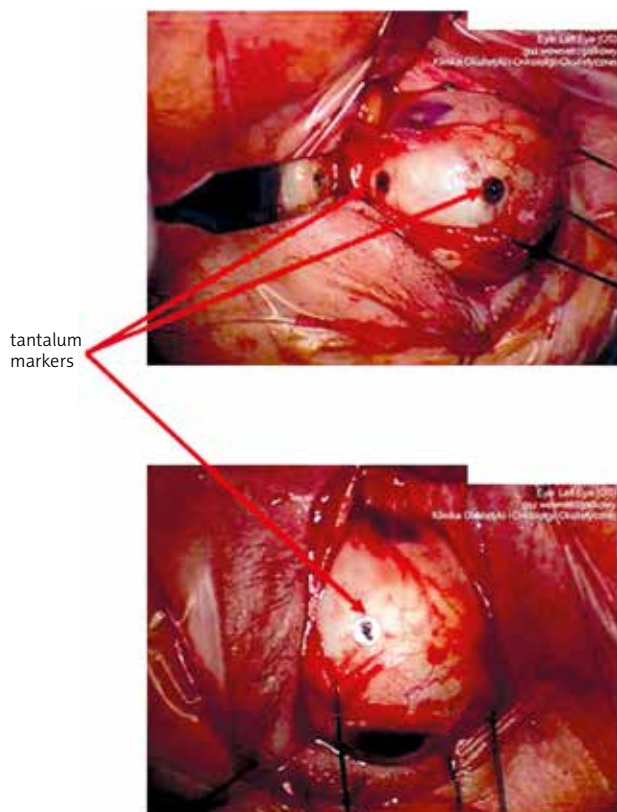


Fig. 1. The example of tantalum markers on the sclera of the eyeball

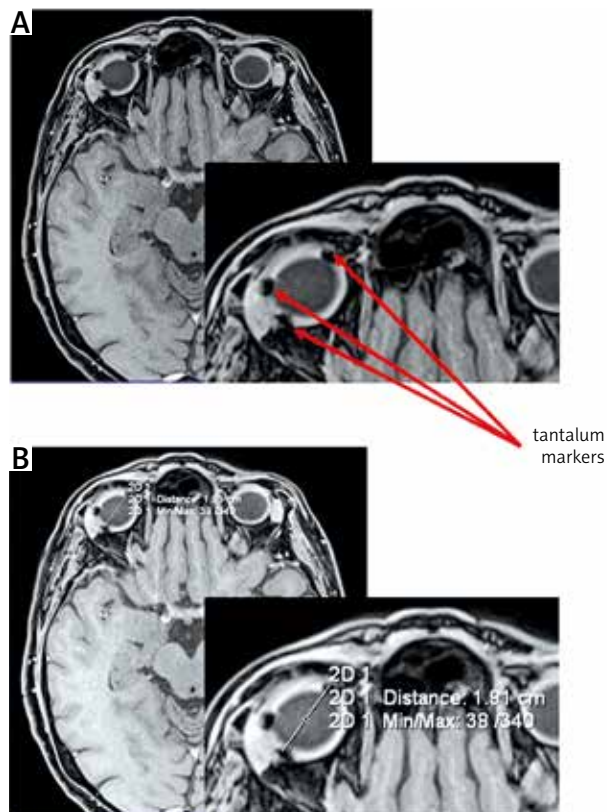


Fig. 2. The example of verification (A) and measurement of distance (B) of markers using MRI

Based on the measurements and the clinical data and using a computerised treatment planning system, we created a virtual model of the eyeball with a reconstructed tumour. Radiotherapy planning was based on the Eclipse Ocular Proton Planning system developed by the company Varian Medical Systems.

The plan was to cover 90% of the planning target volume (PTV) content (tumour with margin of 2.5 mm) with isodose.

Figure 3 presents the dose distribution in PTV and dose-volume histograms in PTV and critical organs.

To ensure that the beam had the appropriate range and achieved a homogeneous dosage in PTV, we used individually selected beam modifiers (range discriminator, power modulator and collimator).

A dose of 60 CGE was administered in 4 fractions over 4 successive days of treatment.

## Methods

At the end of the treatment the patients continued to be monitored as outpatients at the Department of Ophthalmology and Ocular Oncology Clinic, Jagiellonian University. During the study the clinical effects of proton radiotherapy were measured in terms of effectiveness and toxicity.

The effectiveness of proton radiotherapy was assessed as the degree of tumour regression while taking into account changes in the dimensions of the tumour. During the follow-up the side effects of the treatment and the patient's vision function were also monitored.

Student's *t*-test was used to compare the sizes of tumours and change of vision function prior to and after treatment, adopting  $\alpha = 0.05$  as the level of statistical significance.

## Results

The effects of the treatment, assessed as the frequency of regression and change in tumour size and change of vision function, are presented in Table 2.

Measurements of the tumours (their transverse and longitudinal base as well as their thickness) showed a significant reduction in size following proton radiotherapy.

Figure 4 presents an example of a USG image taken before and after proton radiotherapy.

Following proton radiotherapy the tumour had regressed in 8 patients (53.3%) and remained stable in 3 patients (20%). The large tumours in another 3 patients (20%) were removed during vitrectomy (endoresection), which increased the number of patients with tumour regression up to 11 (73.3%). In the case of 1 patient, despite intraocular tumour regression occurring the choroidal melanoma had spread multifocally into the orbit, which necessitated orbit exenteration.

The results ensured that the eyeballs of 14 patients (93.3%) could be saved.

After proton radiotherapy distant best corrected visual acuity (BCVA) increased in 1 case, was stable in 5 and decreased in 9 patients.

The follow-up period for the 15 patients ranged between 8 and 26 months (average: 17.4 months, median

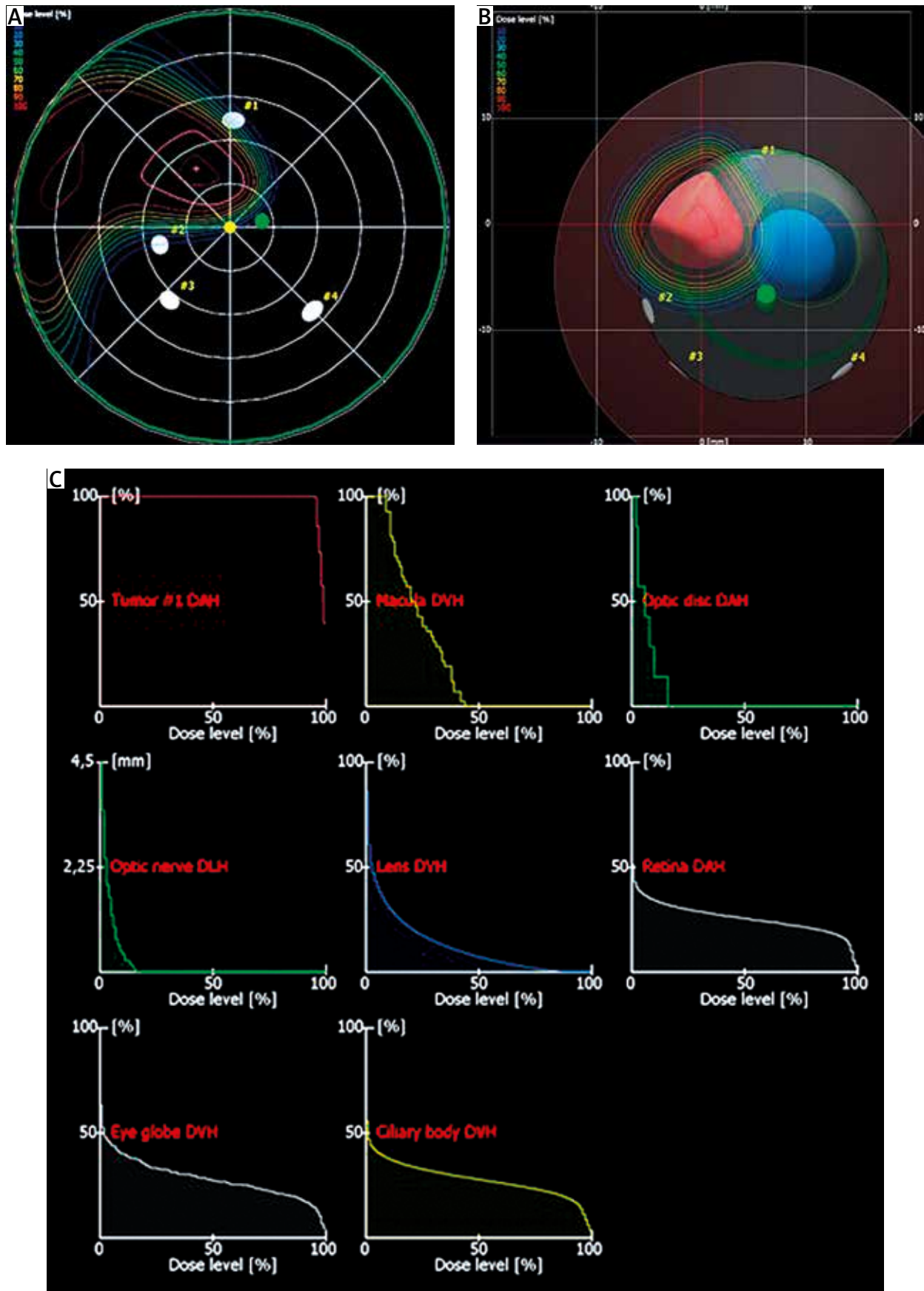
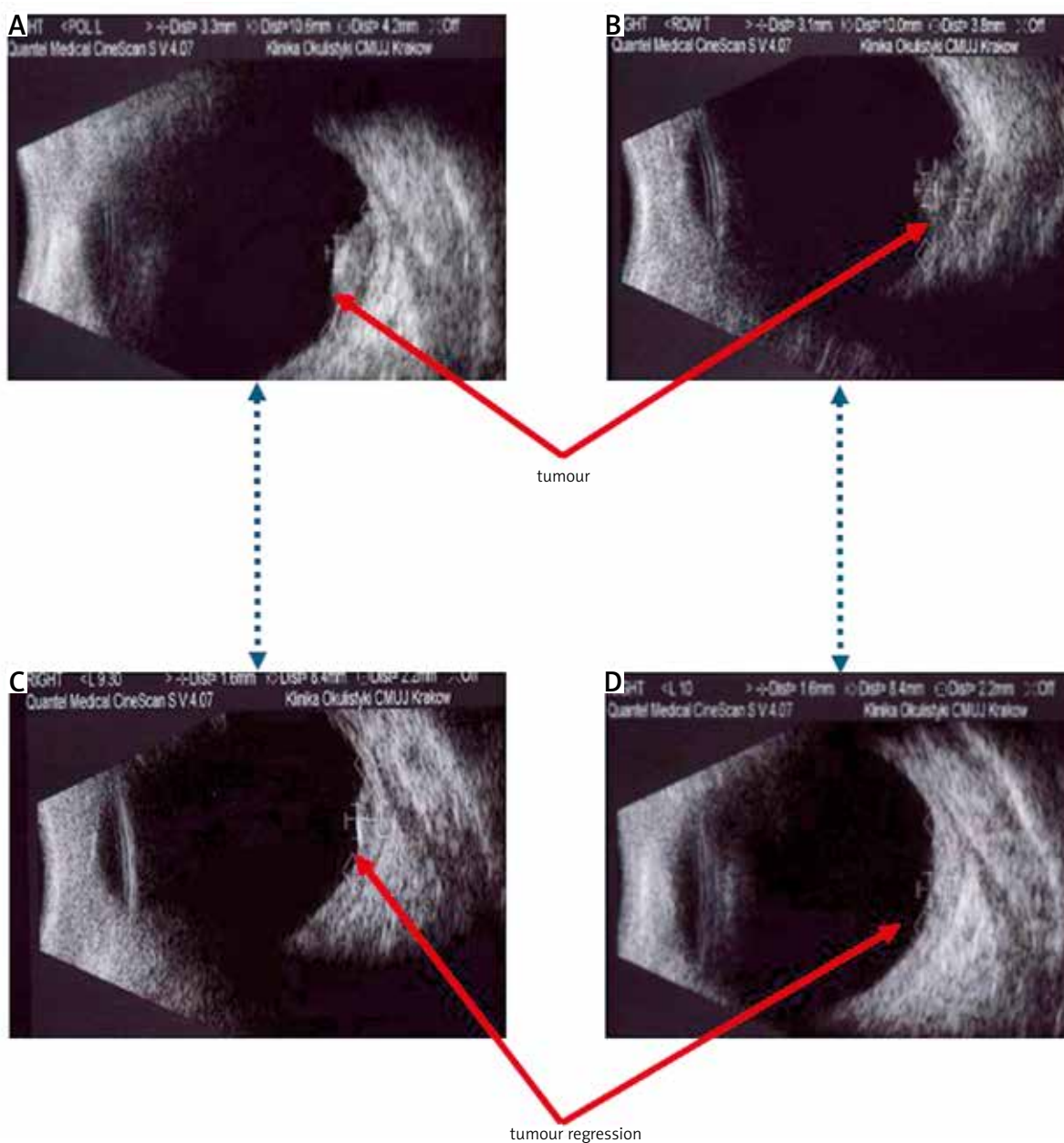


Fig. 3. The dose distribution in PTV: A) isodoses distribution, B) Beam's eye view, and dose-volume histograms of tumour and critical organs (C)

**Table 2.** Results after proton radiotherapy in a group of 15 patients with choroidal melanoma

Results	No. of patients		%	
Clinical results				
regression	11*		73.3	
stabilization	3		20.0	
progression (metastases)	1		6.7	
Vision function				
improvement	1		6.7	
stabilization	5		33.3	
deterioration	9		60.0	
Tumour diameters (mean values)	Before treatment	After treatment	p (Student's t-test)	95% confidence interval
transverse basal [mm]	11.24	9.30	0.0003	2.06–2.30
longitudinal basal [mm]	11.44	8.83	0.0246	0.36–4.24
tumour thickness [mm]	5.05	2.67	0.0061	0.49–2.28

\*In 3 of these patients tumour endoresection was performed



**Fig. 4.** The examples of USG images performed before (A, B) and after (C, D) proton radiotherapy in one of patients. There are corresponding pictures A with C and B with D

value: 19 months). In this period some side effects were noted in the observation period, which are presented in Table 3.

An increase in intraocular pressure was observed in 9 of the patients (60%). This increase amounted on average to 2.8 mm Hg (range 1–6 mm Hg) compared with the pre-treatment levels. On the other hand, in certain individual cases other complications developed, such as retinal detachment, cataract, maculopathy, neuropathy and vitreous haemorrhaging.

## Discussion

Proton radiotherapy treatment for patients with uveal melanoma is a conservative local method that has been employed since the 1970s and is regarded as one of the basic approaches to treating such patients [21].

Proton beams are used in radiotherapy due to their physical properties (limited range, sharp lateral penumbra, no increased dose effect on beam entry and practically no dose on beam exit), thanks to which it is possible to achieve a homogeneous distribution of a large dose in a limited volume (tumour with margin) while simultaneously ensuring excellent protection for healthy tissue and the vital organs by limiting the dose and irradiated volume [26, 27].

This method offers very good results in terms of local control (89–99%), with the eyeball preserved in more than 90% of cases and vision function maintained in more than 50% [19, 23, 28–38].

In the case of our own material, tumour regression was achieved in 73% of patients, the eyeball was saved in 93% and vision function in 90% of cases. It is important to note that these are only preliminary results for a group of 15 patients and were obtained over a relatively short observation period (median 19 months).

Proton radiotherapy represents an alternative to brachytherapy as a means of treating tumours located close to the macula or optic disc. Better results in terms of local control were observed following proton radiotherapy than was the case with brachytherapy, with no significant differences in survival rates [13, 39, 40]. The positive impact of proton radiotherapy on treatment can be seen in the reduced frequency of relapses or complications (primarily retinopathy and cataracts) following such treatment [41]. This translates into fewer cases requiring enucleation. The risk of enucleation due to complications is reduced by 47% after proton radiotherapy compared with brachytherapy [13].

In turn, Wilson *et al.* observed greater vision impairment with proton radiotherapy than was the case with brachytherapy [14].

A very important factor to consider is proton radiotherapy's impact on the patient's vision. According to data from the literature, the chances of preserving the patient's sight depends on the location of the tumour. The vision function of 33–47% of the patients had deteriorated 1–2 years after proton radiotherapy when the tumour was located in the region of the macula or optic disc and in 17–28% of cases when the tumour was in a different location [24, 33].

**Table 3.** Side effects of proton radiotherapy observed in group of 15 patients with choroidal melanoma

Complication	No. of patients	%
glaucoma	9	60.0
worsening of visual acuity	1	6.7
retinopathy	1	6.7
cataract	2	13.3
neuropathy	1	6.7
maculopathy	1	6.7
vitreous haemorrhaging	1	6.7

In our material choroidal melanoma were located close to the macula and/or optic disc in 9 of 15 cases and it explains the visual acuity of 60% of patients during an average 17.4-month observation period.

The clinical effectiveness of proton radiotherapy (local control) can be improved by ensuring possible endoresection of the remaining part of the tumour [42]. This helps improve the outcome of treatment while at the same time preserving the eyeball.

Through local control and limiting the frequency of complications the eyeball can be saved, which is a very important argument in favour of proton radiotherapy.

Egger *et al.* analysed the material from 15 years ago (1984–1999) covering 2648 eyes in 2645 patients. They demonstrated that the most common reasons for enucleation were the following: loss of function, glaucoma, inflammation and cancer relapse. According to these researchers, the size of the tumour has a significant influence on whether the eyeball can be preserved. The 5- and 10-year eyeball preservation rates were 100% and 96.1% (for small tumours) and 99.7% and 64.8% (for large tumours), respectively [19].

Aziz *et al.* noted the following complications following proton radiotherapy: retinopathy (39%), cataracts (20%), inflammation of the uvea (17%), neuropathy (16%) and maculopathy (4%). Despite this fact, when the results in terms of local control are considered, the authors believe that proton radiotherapy is an effective method for treating patients with choroidal melanoma [15].

The most common side effect of proton radiotherapy revealed in our own material was increased intraocular pressure (60% of patients), while other complications only occurred in individual cases. As mentioned earlier, it is important to bear in mind that the observation period for the group in the present study was short and the group itself comprised 15 patients.

One advantage of proton radiotherapy is that it ensures a homogeneous dose distribution in a limited volume. The application of advanced photon radiotherapy techniques (stereotactic, gamma knife, IMRT) makes it possible to achieve a comparable high dose distribution [17, 18]. The differences lie in the excellent protection of healthy tissue and the critical organs, and it is precisely here where proton radiotherapy has the edge.

In summary, our preliminary results concerning a small group of 15 patients with a median observation

period of 19 months confirm that proton radiotherapy is an effective method for treating patients with choroidal melanoma.

This method ensures an eyeball preservation rate of 93%, with the vision function of 80% of the patients being saved.

Nevertheless, our preliminary results and those published in the literature confirm that proton radiotherapy is an effective and safe method for treating patients with choroidal melanoma.

*The authors declare no conflict of interest.*

## References

- McLaughlin CC, Wu XC, Jemal A, Martin HJ, Roche LM, Chen VW. Incidence of noncutaneous melanomas in the U.S. *Cancer* 2005; 103: 1000-7.
- Isager P, Ehlers N, Overgaard J. Have choroidal and ciliary body melanomas changed during the period 1955-2000. *Acta Ophthalmol Scand* 2004; 82: 509-16.
- Jovanovic P, Mihajlovic M, Djordjevic-Jocic J, Vlajkovic S, Cekic S, Stefanovic V. Ocular melanoma: an overview of the current status. *Int J Clin Exp Pathol* 2013; 6: 1230-44.
- Weis E, Shah CP, Lajous M, Shields JA, Shields CL. The association between host susceptibility factors and uveal melanoma: a meta-analysis. *Arch Ophthalmol* 2006; 124: 54-60.
- Van Raamsdonk CD, Bezrookove V, Green G, et al. Frequent somatic mutations of GNAQ in uveal melanoma and blue naevi. *Nature* 2009; 457: 599-602.
- Van Raamsdonk CD, Griewank KG, Crosby MB, et al. Mutations in GNA11 in uveal melanoma. *N Engl J Med* 2010; 363: 2191-9.
- Onken MD, Worley LA, Long MD, Duan S, Council ML, Bowcock AM, Harbour JW. Oncogenic mutations in GNAQ occur early in uveal melanoma. *Invest Ophthalmol Vis Sci* 2008; 49: 5230-4.
- Bauer J, Killic E, Vaarwater J, et al. Oncogenic GNAQ mutations are not correlated with disease-free survival in uveal melanoma. *Br J Cancer* 2009; 101: 813-5.
- Dratviman-Storobinsky O, Cohen Y, Frenkel S, Pe'er J, Goldenberg-Cohen N. Lack of oncogenic GNAQ mutations in melanocytic lesions of the conjunctiva as compared to uveal melanoma. *Invest Ophthalmol Vis Sci* 2010; 51: 6180-2.
- Abdel-Rahman MH, Yang Y, Zhou XP, Craig EL, Davidorf FH, Eng C. High frequency of submicroscopic hemizygous deletion is a major mechanism of loss of expression of PTEN in uveal melanoma. *J Clin Oncol* 2006; 24: 288-95.
- Eskelin S, Kivelä T. Mode of presentation and time of treatment of uveal melanoma in Finland. *Br J Ophthalmol* 2002; 86: 333-8.
- Damato EM, Damato BE. Detection and time to treatment of uveal melanoma in the United Kingdom: an evaluation of 2,384 patients. *Ophthalmology* 2012; 119: 1582-9.
- Wang Z, Nabhan M, Schild SE, Stafford SL, Petersen IA, Foote RL, Murad MH. Charged particle radiation therapy for uveal melanoma: a systematic review and meta-analysis. *Int J Radiat Oncol Biol Phys* 2013; 86: 18-26.
- Wilson MW, Hungerford JL. Comparison of episcleral plaque and proton beam radiation therapy for the treatment of choroidal melanoma. *Ophthalmology* 1999; 106: 1579-87.
- Aziz S, Taylor A, McConnachie A, Kacperek A, Kemp E. Proton beam radiotherapy in the management of uveal melanoma: clinical experience in Scotland. *Clin Ophthalmol* 2009; 3: 49-55.
- Diener-West M, Earle JD, Fine SL, Hawkins BS, Moy CS, Reynolds SM, Schachat AP, Straatsma BR; Collaborative Ocular Melanoma Study Group. The COMS randomized trial of iodine 125 brachytherapy for choroidal melanoma. III. Characteristics of patients enrolled and not enrolled. COMS report no. 17. *Arch Ophthalmol* 2001; 119: 951-65.
- Weber DC, Bogner J, Verwey J, et al. Proton beam radiotherapy versus fractionated stereotactic radiotherapy for uveal melanomas: a comparative study. *Int J Radiat Oncol Biol Phys* 2005; 63: 373-84.
- Hein PA, Gladstone DJ, Bellerive MR, Hug EB. Importance of protocol target definition on the ability to spare normal tissue: an IMRT and 3D-CRT planning comparison for intraorbital tumors. *Int J Radiat Oncol Biol Phys* 2005; 62: 1540-8.
- Egger E, Zografos L, Schalenbourg A, Beati D, Böhringer T, Chamot L, Goitein G. Eye retention after proton beam radiotherapy for uveal melanoma. *Int J Radiat Oncol Biol Phys* 2003; 55: 867-880.
- Virgili G, Gatta G, Ciccolallo L, Capocaccia R, Biggeri A, Crocetti E, Lutz JM, Paci E; EUROCARE Working Group. EUROCARE Working Group. Survival in patients with uveal melanoma in Europe. *Arch Ophthalmol* 2008; 126: 1413-8.
- Gragoudas ES, Goitein M, Koehler AM, Verhey L, Tepper J, Suit HD, Brockhurst R, Constable IJ. Proton irradiation of small choroidal malignant melanomas. *Am J Ophthalmol* 1977; 83: 665-73.
- Gragoudas ES, Goitein M, Verhey L, Munzenreider J, Suit HD, Koehler A. Proton beam irradiation – an alternative to enucleation for intraocular melanomas. *Ophthalmology* 1980; 87: 571-81.
- Allen AM, Pawlicki T, Dong L, et al. An evidence based review of proton beam therapy: the report of ASTRO's emerging committee. *Radiation Oncol* 2012; 103: 8-11.
- Gragoudas ES, Munzenreider JE, Lane AM, Collier JM. Eye. In: Proton and Charged particle radiotherapy. DeLaney TF, Kooy HM (eds.). Wolters Kluwer Pippincott Williams & Wilkins, Philadelphia 2008.
- www.ptcog.com.
- Mourtada F, Koch N, Newhauser W. <sup>106</sup>Ru/<sup>106</sup>Rh plaque and proton radiotherapy for ocular melanoma: a comparative dosimetric study. *Radiat Prot Dos* 2005; 116: 454-60.
- Engelsman M, Schwarz M, Dong L. Physics controversies in proton therapy. *Semin Radiat Oncol* 2013; 23: 88-96.
- Egger E, Schalenbourg A, Zografos L, Bercher L, Boehringer T, Chamot L, Goitein G. Maximizing local tumor control and survival after proton beam radiotherapy of uveal melanoma. *Int J Radiat Oncol Biol Phys* 2001; 51: 138-47.
- Dendale R, Lumbroso-Le Rouic L, Noel G, et al. Proton beam radiotherapy for uveal melanoma: results of Curie Institut – Orsay proton therapy center (ICPO). *Int J Radiat Oncol Biol Phys* 2006; 65: 780-7.
- Munzenreider JE. Uveal melanomas. Conservation treatment. *Hematol Oncol Clin North Am* 2001; 15: 389-402.
- Courdi A, Caujolle JP, Grange JD, et al. Results of proton therapy of uveal melanomas treated in Nice. *Int J Radiat Oncol Biol Phys* 1999; 45: 5-11.
- Egger E, Schalenbourg A, Zografos L, Bercher L, Boehringer T, Chamot L, Goitein G. Maximizing local tumour control and survival after proton beam radiotherapy of uveal melanoma. *Int J Radiat Oncol Biol Phys* 2001; 51: 138-47.
- Brada M, Pijls-Johannesma M, De Ruyscher D. Proton therapy in clinical practice: current clinical evidence. *J Clin Oncol* 2007; 25: 965-70.
- Li W, Gragoudas ES, Egan KM. Metastatic melanoma death rates by anatomic site after proton beam irradiation for uveal melanoma. *Arch Ophthalmol* 2000; 118: 1066-70.
- Munzenreider JE, Verhey LJ, Gragoudas ES, et al. Conservative treatment of uveal melanoma: local recurrence after proton beam therapy. *Int J Radiat Oncol Biol Phys* 1989; 17: 493-8.
- Munzenreider JE, Gragoudas ES, Seddon JM, et al. Conservative treatment of uveal melanoma: probability of eye retention after proton treatment. *Int J Radiat Oncol Biol Phys* 1988; 15: 553-8.
- Gragoudas ES, Marie Lane A. Uveal melanoma: proton beam irradiation. *Ophthalmol Clin North Am* 2005; 18: 111-8.
- Correa-Pérez ME, Saornil MA, García-Álvarez C, et al. Bilateral episcleral brachytherapy in simultaneous choroidal melanoma and circumscribed hemangioma. *J Contemp Brachytherapy* 2013; 5: 258-62.
- Seddon JM, Gragoudas ES, Egan KM, et al. Relative survival rates after alternative therapies for uveal melanoma. *Ophthalmology* 1990; 97: 769-77.
- Mosci C, Lanza FB, Barla A, Mosci S, Héroult J, Anselmi L, Truini M. Comparison of clinical outcomes for patients with large choroidal melanoma after primary treatment with enucleation or proton beam radiotherapy. *Ophthalmologica* 2012; 227: 190-6.

41. Olsen DR, Bruland OS, Frykholm G, Norderhaug IN. Proton therapy – a systematic review of clinical effectiveness. *Radiother Oncol* 2007; 83: 123-32.
42. Tran BK, Schalenbourg A, Bovey E, Zografos L, Wolfensberger TJ. Role of vitreoretinal surgery in maximizing treatment outcome following complications after proton therapy for uveal melanoma. *Retina* 2013; 9: 1777-83.

**Address for correspondence**

**Beata Sas-Korczyńska** MD, PhD  
Clinic of Oncology – Department of Breast and Chest Cancer  
Centre of Oncology – Maria Skłodowska-Curie Memorial Institute  
Krakow Branch  
Garncarska 11  
31-115 Krakow, Poland  
e-mail: z5korczy@cyf-kr.edu.pl

**Submitted:** 25.10.2013

**Accepted:** 3.02.2014