

Transoesophageal echocardiography reduces invasiveness of cavoatrial tumour thrombectomy

Robert Sobczyński¹, Tomasz Golabek², Piotr Mazur^{1,3}, Piotr Chłosta²

¹Department of Cardiovascular Surgery and Transplantology, Institute of Cardiology, Jagiellonian University Medical College, Krakow, Poland

²Department of Urology, Jagiellonian University Medical College, Krakow, Poland

³Institute of Cardiology, Jagiellonian University Medical College, Krakow, Poland

Videosurgery Miniinv 2014; 9 (3): 479–483

DOI: 10.5114/wiitm.2014.44281

Abstract

The traditional approach to cavoatrial thrombus excision requires median sternotomy, cardiopulmonary bypass with or without hypothermia and circulatory arrest and is associated with significant morbidity and mortality. We describe a transoesophageal echocardiography guided balloon catheter assisted technique for cavoatrial thrombectomy that avoids thoracotomy, extracorporeal circulation and circulatory arrest as an alternative to traditional methods. A 74-year-old man presented with a right solid renal mass confined to the kidney with thrombus extension through the right renal vein and the inferior vena cava into the right atrium. A right radical nephrectomy with cavoatrial thrombectomy under transoesophageal echocardiography guidance was successfully achieved using a balloon catheter-assisted technique with minimal intra- and postoperative morbidity. Cavoatrial tumour thrombectomy can be successfully performed without cardiopulmonary bypass, hypothermia and circulatory arrest.

Key words: cavoatrial thrombus, renal cancer, thrombectomy, surgical management.

Introduction

Approximately 4–10% of renal cell carcinoma (RCC) cases are complicated by the presence of tumour thrombus (TT) in the inferior vena cava (IVC) [1]. Although the extension of thrombus is limited to the infra-diaphragmatic segment of the IVC in most cases, it can reach the right atrium in up to 1% of patients [2]. Treatment of advanced renal tumours still represents a great surgical challenge [3]. The presence of renal cancer with thrombus is associated with venous congestion, distal embolism and the development of neovascularization, as well as collaterals that form as a result of the inferior vena cava occlusion and, in consequence, increase of the technical difficulty of surgery. The operative treatment depends on the level of thrombus and the extent of thrombus propagation

throughout the IVC. In cases with TT of low volume, simple thrombus excision, IVC endoluminal occlusion and thrombus stripping with a venous catheter, minimal access technique and laparoscopic approaches all have been used [4–6]. The traditional approach to cavoatrial thrombus excision requires median sternotomy, cardiopulmonary bypass with or without hypothermia and circulatory arrest, and is associated with significant morbidity and mortality [1, 7].

Aim

We describe a transoesophageal echocardiography (TOE) guided balloon catheter-assisted technique for cavoatrial thrombectomy not requiring thoracotomy, extracorporeal circulation and circulatory arrest as an alternative to the traditional approach.

Address for correspondence

Tomasz Golabek MD, PhD, Department of Urology, Jagiellonian University Medical College, 18 Grzegorzeczka St, 31-531 Krakow, Poland, phone: +48 690 999 122, e-mail: elementare@op.pl

Case report

A 74-year-old male presented with frank haematuria and anaemia with a haemoglobin level of 11.5 g/dl. His past medical history included a disseminated coronary artery disease not requiring invasive treatment. Computed tomography (CT) of the abdomen revealed a right solid renal mass confined to the kidney, measuring 10 cm in maximal diameter with thrombus extension through the right renal vein into the IVC, and no evidence of metastasis.

Preoperative transthoracic echocardiography identified tumour thrombus extending up to the level of the Eustachian valve, and subsequent, intraoperative two-dimensional transoesophageal echocardiography, performed at the beginning of the procedure, revealed an approximate 5 mm right intra-atrial thrombus involvement (Photo 1).

Transoesophageal echocardiography was used throughout the surgery to monitor tumour thrombus, gas or tumour emboli, to locate the balloon of the catheter in the heart and the IVC, and to ascertain complete thrombus removal. Urologic and cardiothoracic surgeons jointly undertook the surgical treatment, a perfusionist was available if needed and a cardiopulmonary machine was primed and ready for possible use.

The patient received general anaesthesia with endotracheal intubation. Premedication consisted of oral midazolam (7.5 mg), whereas general anaesthesia was induced with 200 mg of propofol, 150 µg of fentanyl and 10 mg of pancuronium. Anaesthesia was maintained with isoflurane in oxygen/air mixture supplemented with fentanyl. A central venous

catheter and a radial artery catheter were introduced prior to the induction for continuous blood pressure monitoring.

A transoesophageal echocardiography probe was placed after the commencement of mechanical ventilation. The probe was positioned behind the endotracheal tube and gently advanced until it reached a position enabling adequate heart examination. Transoesophageal echocardiography revealed normal function of both ventricles and normal valves. There was a tumour thrombus noted extending proximally into the right atrium for approximately 5 mm in length.

The laparotomy was carried out by way of a chevron incision. The inferior vena cava, approximately 3 cm below the renal veins and up to the level of the heart, the infrarenal aorta, and both renal veins were exposed with a medial colon reflection, Kocher manoeuvre, liver mobilisation and pericardial cavity opening. The right renal artery was ligated. The left renal vein, the infra-renal inferior vena cava and the hepatic porta were encircled with Rommel tourniquets. The right kidney was fully mobilised, leaving it attached only by the renal vein. The patient was placed in the Trendelenburg position to reduce the risk of air embolism. The infra-renal IVC and the left renal vein were clamped using Rommel tourniquets. Portal compression was not required, as the degree of back bleeding from the liver during thrombus removal allowed for safe procedure completion. However, the Rommel tourniquet placed around the hepatic porta enabled the procedure to be performed at any moment should the bleeding be too heavy. A short cavotomy was performed at the level of the ostium of the right renal vein. A 22 Fr Foley catheter (siliconised 2-way catheter, maximum inflatable volume of the balloon of 30 ml, Unomedical, Sdn. Bhd., Denmark) was introduced via cavotomy and passed up to the right atrium under direct transoesophageal echocardiographic guidance. The balloon of the catheter was then inflated with physiological saline solution (approximately 15 ml) within the right atrium above the tumour thrombus (Photo 2 and Figure 1). The balloon volume was adjusted to the IVC diameter continuously while withdrawing the catheter to maintain sufficient IVC occlusion allowing for *en bloc* cavoatrial thrombus and renal specimen removal. This procedure was assessed by real-time two-dimensional transoesophageal echocardiography. The cavotomy was closed with a 4/0 prolene double-run-

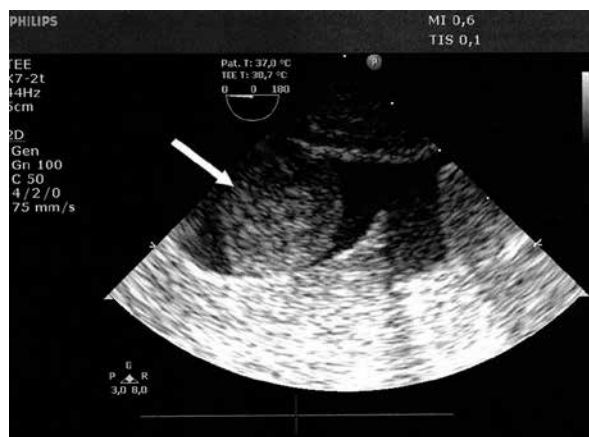

Photo 1. Two-dimensional transoesophageal echocardiographic image of atrial tumour thrombus (arrow)

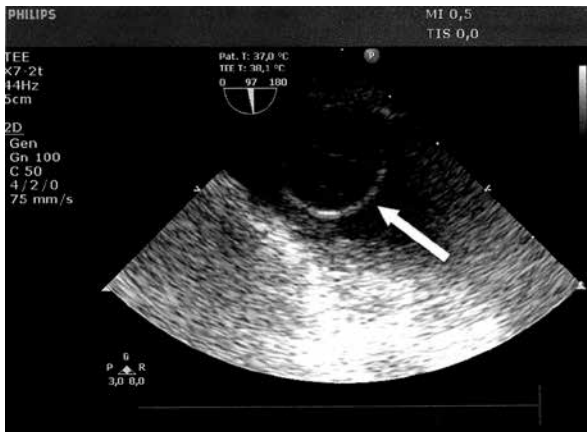

Photo 2. Two-dimensional transoesophageal echocardiographic image of inflated balloon of the catheter within the right cardiac atrium (arrow)

ning suture. The patient remained haemodynamically stable with no evidence of emboli noted on TOE. The total vessel occlusion time was 90 s. The blood loss, measured from the time of the IVC incision until the cavotomy closure, was approximately 1000 ml. The first 200 ml of blood was lost at the time of catheter positioning into the right atrium with a balloon just above the tumour thrombus. Minimal bleeding (< 50 ml) occurred during catheter-guided thrombus withdrawal and approximately 750 ml of blood was lost during cavotomy closure. No Pringle’s manoeuvre was required to control the hepatic backflow. The total surgical time was 220 min.

The patient’s postoperative recovery was uneventful, and he was discharged home 7 days after the surgery. His creatinine level and liver function tests were normal. The final pathology revealed a T3cN0M0, Fuhrman grade 2 clear cell (conventional) carcinoma.

Discussion

Nephrectomy with IVC thrombectomy is often a challenging procedure. Surgical difficulty and risk increase with the level of inferior vena caval involvement. While simple thrombus excision, endoluminal occlusion and thrombus stripping with a venous catheter, as well as minimal access technique and laparoscopic approaches have been successfully used for infra-hepatic thrombi removal, cavoatrial thrombus requires more complex procedures [3–5]. Median sternotomy, cardiopulmonary bypass with or without hypothermia and circulatory arrest, as well

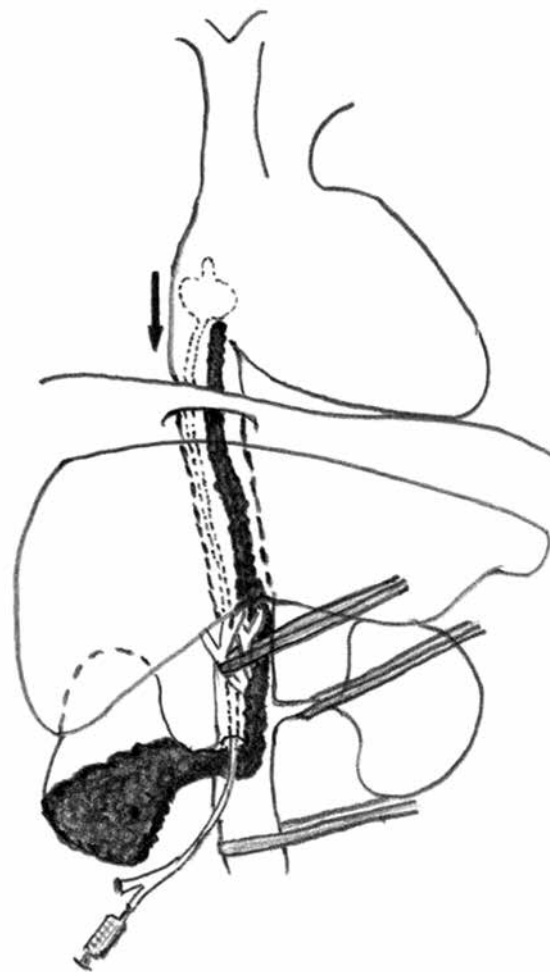


Figure 1. Schematic view of Foley catheter balloon-assisted cavoatrial thrombectomy. The left renal vein, the infra-renal inferior vena cava and the hepatic porta are encircled with the Rommel tourniquets. Tumour thrombus extends through the inferior vena cava into the right atrium. The balloon within the right atrium is inflated. Arrow indicates the direction of the Foley catheter and thrombus withdrawal

as a right atriotomy have been used [1, 7]. However, these procedures increase the operating time, as well as blood loss, and are associated with significant morbidity and mortality [8, 9]. The resultant systemic heparinisation along with associated platelet dysfunction may cause coagulopathy, which can lead to postoperative haemorrhage [10]. Deep hypothermia with cardiac arrest is associated with transient or permanent neurologic deficits, including delirium and

stroke [11]. Clamping the descending aorta above the diaphragm with avoidance of deep hypothermic circulatory arrest requires sternotomy, cardiopulmonary bypass and dissection through the left pericardium into the posterior mediastinum with possible oesophageal or vagal injury [12], whereas pushing the tumour thrombus back with a finger through a small atriotomy has a high risk of intra-operative pulmonary embolism by dislodged thrombi [1].

Instead, faced with the aforementioned problems, we chose to employ a relatively simple transoesophageal echocardiography guided balloon catheter-assisted technique for cavoatrial thrombectomy not requiring thoracotomy with a potential risk for sternotomy dehiscence, chest tube drainage, extracorporeal circulation and circulatory arrest. We found this method to work effectively and without difficulty. With this approach, TOE was of the utmost importance as it helped to identify a thrombus and to control inflation of a catheter balloon within the atrium and finally to guide the retrieval of the catheter and the thrombus from the heart.

The major disadvantage of this technique is that it is not applicable to those with the IVC wall invasion by the tumour thrombi or in cases of thrombus extending into the right ventricle. The main risk of the balloon technique is a potential failure in achieving adequate thrombus control with the inflated balloon. Moreover, tumour thrombus fragmentation and/or migration with subsequent acute pulmonary embolism may occur. Although the thrombus was removed in its entirety in our case, the risk of leaving a fragment of the thrombus behind during the extraction procedure remains. Recognizing the risk of the tumour and air migration with subsequent acute pulmonary embolism, we performed continuous TOE during catheter and thrombus withdrawal. We believe that this investigation is of utmost importance as it allows for immediate detection of incomplete tumour removal and significant embolic events, as well as serious heart abnormalities which can further hinder the surgery [13]. Moreover, intensive intraoperative haemodynamic monitoring is required as patients with intraoperative pulmonary emboli exhibit a sudden decrease in O₂ saturation and blood pressure drop [14]. The risk of thrombus fragmentation and pulmonary dissemination seems to be proportional to the magnitude of thrombus extension, with the highest risk encountered in level IV tumours [15, 16]. Moreover, acute pulmonary

emboli can result from blind removal of a thrombus or from an inappropriate tumour-filled IVC handling technique [8]. In addition, liver mobilisation, as well as atrial and caval thrombectomy with the use of hypothermic cardiopulmonary bypass technique, have been associated with a significant risk of thrombus migration, with the latter technique having been reported to carry a 7.5% peri-operative embolic complication rate [17, 18].

Another disadvantage of our balloon technique is a marginal risk of cardiac arrhythmia caused by irritation of the right atrium by the catheter [19]. Furthermore, there is always a possibility that the patient will not be able to tolerate the reduced venous return and an alternative method for thrombus removal may be required. Therefore, a cardiothoracic surgeon with appropriate expertise and a perfusionist should be an integral part of the operating team. Finally, transoesophageal echocardiography needs to be provided throughout the surgery as it offers a significant benefit at every stage of the procedure, including the determination of the upper extent of the thrombus, guidance of the catheter with its balloon, and enhancing anaesthetic monitoring. Moreover, the use of TOE guidance during surgery helps to limit the cavotomy to the diameter of the thrombus and significantly reduce the invasiveness of cavoatrial tumour thrombectomy.

Conclusions

Radical nephrectomy and cavoatrial tumour thrombectomy can be safely and effectively performed with a relatively simple balloon catheter-assisted technique that reduces the risk of potentially hazardous complications associated with other alternative methods used. Transoesophageal echocardiography is of the utmost importance with this approach as it guides the introduction of a catheter into the atrium as well the retrieval of a tumour thrombus from the heart.

References

1. Skinner DG, Pritchett TR, Lieskovsky G, et al. Vena caval involvement by renal cell carcinoma. Surgical resection provides meaningful long-term survival. *Ann Surg* 1989; 210: 387-92.
2. Bissada NK, Finkbeiner AE, Williams GD, Weiss JB. Successful extraction of intracardiac tumor thrombus of renal carcinoma. *J Urol* 1977; 118: 474-5.
3. Stránský P, Eret V, Urge T, et al. Laparoscopic adrenalectomy for metachronous ipsilateral metastasis following nephrectomy for renal cell carcinoma. *Videosurgery Mininv* 2013; 8: 221-5.

4. Zini L, Haulon S, Leroy X, et al. Endoluminal occlusion of the inferior vena cava in renal cell carcinoma with retro- or supra-hepatic caval thrombus. *BJU Int* 2006; 97: 1216-20.
5. Wotkowicz C, Libertino JA, Sorcini A, Mourtziinos A. Management of renal cell carcinoma with vena cava and atrial thrombus: minimal access vs median sternotomy with circulatory arrest. *BJU Int* 2006; 98: 289-97.
6. Varkarakis IM, Bhayani SB, Allaf ME, et al. Laparoscopic-assisted nephrectomy with inferior vena cava tumor thrombectomy: preliminary results. *Urology* 2004; 64: 925-9.
7. Glazer AA, Novick AC. Long-term followup after surgical treatment for renal cell carcinoma extending into the right atrium. *J Urol* 1996; 155: 448-50.
8. Gallucci M, Borzomati D, Flammia G, et al. Liver harvesting surgical technique for the treatment of retro-hepatic caval thrombosis concomitant to renal cell carcinoma: perioperative and long-term results in 15 patients without mortality. *Eur Urol* 2004; 45: 194-202.
9. Lubahn JG, Sagalowsky AI, Rosenbaum DH, et al. Contemporary techniques and safety of cardiovascular procedures in the surgical management of renal cell carcinoma with tumor thrombus. *J Thorac Cardiovasc Surg* 2006; 131: 1289-95.
10. Baumgartner F, Scott R, Zane R, et al. Modified venovenous bypass technique for resection of renal and adrenal carcinomas with involvement of the inferior vena cava. *Eur J Surg* 1996; 162: 59-62.
11. Ergin MA, Griep EB, Lansman SL, et al. Hypothermic circulatory arrest and other methods of cerebral protection during operations on the thoracic aorta. *J Card Surg* 1994; 9: 525-37.
12. Ruel M, Bedard P, Morash CG, et al. Resection of right atrial tumor thrombi without circulatory arrest. *Ann Thorac Surg* 2001; 71: 733-4.
13. Schallner N, Wittau N, Kehm V, et al. Intraoperative pulmonary tumor embolism from renal cell carcinoma and a patent foramen ovale detected by transesophageal echocardiography. *J Cardiothorac Vasc Anesth* 2011; 25: 145-7.
14. Kwon TW, Kim H, Moon KM, et al. Surgical treatment of inferior vena cava tumor thrombus in patients with renal cell carcinoma. *J Korean Med Sci* 2010; 25: 104-9.
15. Karnes RJ, Blute ML. Surgery insight: management of renal cell carcinoma with associated inferior vena cava thrombus. *Nat Clin Pract Urol* 2008; 5: 329-39.
16. Boorjian SA, Sengupta S, Blute ML. Renal cell carcinoma: vena caval involvement. *BJU Int* 2007; 99: 1239-44.
17. Tomita Y, Kurumada S, Takahashi K, Ohzeki H. Intraoperative transesophageal sonographic monitoring of tumor thrombus in the inferior vena cava during radical nephrectomy and thrombectomy for renal cell carcinoma. *J Clin Ultrasound* 2003; 31: 274-7.
18. Sweeney P, Wood CG, Pisters LL, et al. Surgical management of renal cell carcinoma associated with complex inferior vena caval thrombi. *Urol Oncol* 2003; 21: 327-33.
19. Sigman DB, Hasnain JU, Del Pizzo JJ, Sklar GN. Real-time transesophageal echocardiography for intraoperative surveillance of patients with renal cell carcinoma and vena caval extension undergoing radical nephrectomy. *J Urol* 1999; 161: 36-8.

Received: 24.10.2013, **accepted:** 20.04.2014.