

Sex determination based on the analysis of a contemporary Polish population's palatine bones: a computed tomography study of 1,200 patients

I.M. Tomaszewska¹, P. Frączek², M. Gomulska², M. Pliczko², A. Śliwińska², K. Sałapa³, R. Chrzan⁴, P. Kowalski⁵, M. Nowakowski¹, J.A. Walocha²

¹Department of Medical Education, Jagiellonian University Medical College, Krakow, Poland

²Department of Anatomy, Jagiellonian University Medical College, Krakow, Poland

³Department of Bioinformatics, Jagiellonian University Medical College, Krakow, Poland

⁴Department of Radiology, Jagiellonian University Medical College, Krakow, Poland

⁵Department of Forensic Medicine, Jagiellonian University Medical College, Krakow, Poland

[Received 24 March 2014; Accepted 9 April 2014]

Background: The aims of the present study were to assess whether the hard palate reveals any measurable sex-related differences, and to create a mathematical model which would differentiate between males and females using hard palate measurements alone.

Materials and methods: The present study was conducted on 1,200 archived sinus computed tomography (CT) scans. Each cranial measurement was taken twice by the same observer, and in cases of any discrepancies, the mean of the two values was recorded. Twenty per cent of randomly chosen samples were re-measured by an observer who did not partake in assessing the samples the first time. Logistic regression was used to derive two mathematical formulas which would calculate the probability of a skull being male.

Results: The studied group comprised 1,200 head CT's (627 female; 52.3%). The mean age of the group was 43.5 ± 17.4 years — no age difference between sexes was noted ($p = 0.37$). All of the performed measurements were significantly ($p < 0.0001$) larger in males than in females. The mathematical formula based on the "orale-spina nasalis posterior" (O-SNP) distance alone had a reliability rate of 68.35%. The equation based on the depth of the right greater palatine canal (GPC), the O-SNP distance and the anterior width of the palatal arch (AWPA) had a reliability rate of 78.37%.

Conclusions: The most prominent sexually dimorphic parameters were the O-SNP, the GPC depth and the AWPA. The mathematical models presented in the current study can be used to successfully distinguish between sexes during forensic examination. (*Folia Morphol* 2014; 73, 4: 462–468)

Key words: computed tomography, craniometrics, forensic analysis, hard palate, palatine bone, sex determination, sexing, sexual dimorphism

INTRODUCTION

Sex determination of unidentified remains is often a challenging procedure, and at the same time the first and most important step in forensic examination. The pelvis is normally the most reliable [24] gender indicator, however not always available for analysis, especially if the remains were exposed to outdoor conditions for a long time [19]. There is much debate over which elements to use for sex identification when only the skull and the long bones (femur, humerus, and radius) are present. Many authors indicate that the skull is the second most reliable gender indicator [7, 13–19], however there are also numerous studies showing otherwise [2, 14, 17]. Not only entire bones, but even chosen bone features (e.g. linea aspera of the femur, foramen magnum of the skull or the styloid process of the skull) may be enough to differentiate between sexes [4, 6, 9, 16].

The hard palate is very often well preserved in human remains and its sutures are a well-known feature allowing to estimate an individual's age [1, 23]. Taking into account that the latter is the most difficult part of the forensic examination, the hard palate might also be suitable for gender determination, as it has a number of characteristic anatomical points which allow conducting easy and repeatable measurements.

Over the last decade computed tomography (CT) has gained acceptance as a noninvasive method for conducting forensic examinations (e.g. gender determination, trauma analysis, age estimation) [18, 22]. Sex determination using CT scans has already been used in many studies [4, 6, 14, 18]. However, further studies are still necessary, as not all skeletal features have been investigated this way — including the hard palate. The potential benefits of using CT scans for sex determination are numerous — they allow to save time and effort (do not require time-consuming maceration of specimens), are nondestructive, produce a detailed 3-dimensional reconstruction, and allow to analyse large datasets from different populations in a relatively short period of time [18, 20].

Taking into account the abovementioned facts, we decided to study whether hard palate measurements may have a potential use in forensic anthropology, dentistry and medicine. To perform this we used a large dataset consisting of sinus CT scans of a contemporary Polish population.

Thus, the first aim of the present study was to assess whether the hard palate reveals any measurable sex-related differences. The second aim was

to create a mathematical model which could be used in forensic medicine and anthropology to differentiate between males and females using only hard palate measurements.

MATERIALS AND METHODS

Study material

The present study was conducted on 1,200 archived sinus CT scans (Department of Radiology, Jagiellonian University Medical College and Department of Radiology and J. Dietl's Specialistic Hospital, Krakow, Poland). The CT images were acquired using a Siemens Somatom Sensation 16 and a Toshiba Aquilion 64. The following study parameters were applied — exposure 120 kV, 74 mA, 60 mAs; rotation time: 0.5 s; slice thickness: 0.5 mm.

Study inclusion criteria were participant age over 21 years, and absence of any pathological (including developmental and traumatic) changes in the region of the maxilla.

Measurements

The measurements were performed using the eFilm Workstation 3.4 (Merge Healthcare). All measurements were recorded to the nearest 0.01 mm and, after statistical analysis, rounded up to the nearest 1.0 mm for data presentation, and to facilitate clinical usage. All bilateral measurements were performed symmetrically. Each measurement was taken twice by the same observer, and in cases of any discrepancies, the mean of the two values was recorded. After all of the samples were measured, 20% of randomly chosen samples were re-measured by an observer who did not partake in assessing the samples the first time. Inter-class correlations (ICC) were calculated. The level of agreement between the assessments was very high (ICC = 0.92–0.96).

The following, easy to replicate, measurements and assessments were performed (Fig. 1A–D):

- “orale-spina nasalis posterior” distance (O-SNP) (Fig. 1A);
- anterior width of the palatal arch (AWPA) — the distance between the transverse sulci of the first premolars or the distance between the centres of the dental alveoli where the first premolars were located (in their absence) (Fig. 1B);
- posterior width of the palatal arch (PWPA) — the distance between the intersection of the transverse and buccal sulci of second molars or the distance between the centres of the dental alveoli

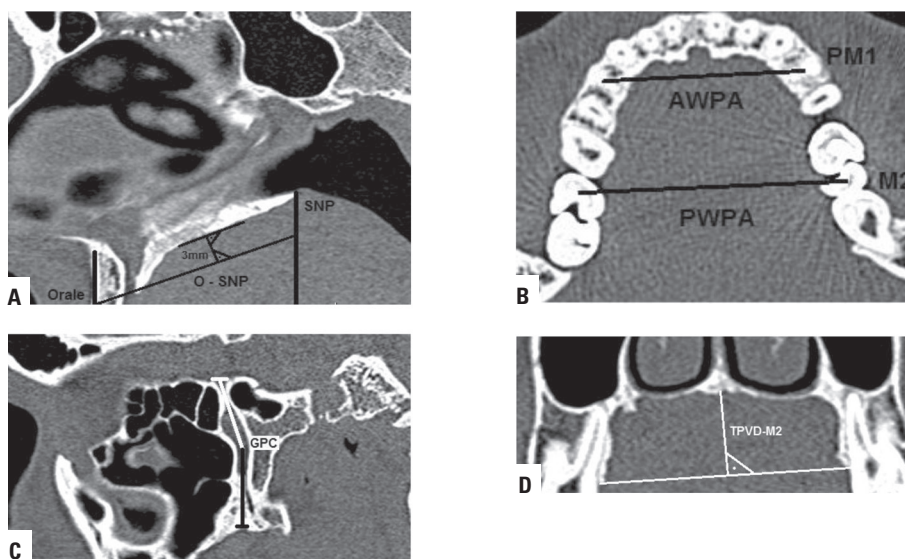


Figure 1. Performed measurements; **A.** O-SNP — the “orale-spina nasalis posterior” distance; **B.** AWPA — anterior width of the palatal arch (at the level of the first premolar — PM1); PWPA — posterior width of the palatal arch (at the level of the second molar — M2); **C.** GPC — the depth of the greater palatine canal (measured bilaterally); **D.** TPVD-M2 — total palatal vault depth at the level of the second molar.

where the second molars were located (in their absence) (Fig. 1C);

- greater palatine canal (GPC) length on both the right (R) and left (L) sides. The length of the GPC was measured according to the methodology of Howard-Swirzynski et al. [10]. The superior aspect of the GPC was set at the centre of the pterygoid canal (the centre point of the pterygopalatine fossa). The inferior aspect of the GPC was marked at the inferior surface of the hard palate. The greater palatine canal was then measured from the marked vertical level to the apparent opening at the greater palatine foramen on the hard palate in the sagittal section. The inferior limit of the GPC was measured to the posterior wall of the great palatine foramen (Fig. 1C);
- total palatal vault depth at the level of the second molar (TPVD-M2) (Fig. 1D);
- calculation of the palatine index (palatine breadth to palatine length ratio expressed in per cent — PWPA to O-SNP ratio) and the palatal height index (palatine height to palatine breadth ratio expressed in per cent — TPVD-M2 to PWPA).

This study has been approved by the Jagiellonian University Medical College Bioethics Committee (registry no KBET/161/B/2013), and has been performed in accordance with the ethical standards laid down in the 1964 Declaration of Helsinki and its later amendments.

Statistical analysis

Statistical analysis was conducted using Statistica 10PL (StatSoft, USA). Elements of descriptive statistics were used (mean, standard deviation, percentage distribution). Side- and sex-related differences were evaluated using the Mann-Whitney U-test or the Student's t-test as appropriate. Spearman's correlation was used to evaluate ICC's and inter-measurement relations. Logistic regression was used to derive two mathematical formulas which calculate the probability of a skull being male. A p-value < 0.05 was considered statistically significant.

RESULTS

The studied group comprised 1,200 head CT's (627 female; 52.3%). The mean age of the group was 43.5 ± 17.4 years — no age difference between sexes was noted ($p = 0.37$).

Table 1 presents the results of the performed measurements. Significant gender-related differences ($p < 0.0001$) were noted in all of the measurements. Table 2 shows inter-measurement correlations.

Figures 2 and 3 depict the relation between the length (O-SNP) of the hard palate, and the anterior (AWPA) (Fig. 2) and posterior (PWPA) (Fig. 3) width of the palatal arch in both males and females. Figure 4 depicts the relation between the depth of the hard palate (TPVD-M2) and its posterior width (PWPA) in males and females.

Table 1. Measurements of the studied group

Distance [mm]	Male (n = 573)		Female (n = 627)		P
	Mean (SD)	Min–Max	Mean (SD)	Min–Max	
O-SNP	48.7 (3.9)	36–60	45.3 (3.7)	34–55	< 0.0001
AWPA	37.8 (2.3)	31–43	35.9 (2.4)	30–42	< 0.0001
PWPA	47.8 (3.1)	40–55	45.7 (3.0)	37–53	< 0.0001
GPC(R)	32.4 (3.3)	10–44	29.8 (3.0)	8–38	< 0.0001
GPC(L)	32.5 (2.7)	9–42	29.8 (3.5)	8–37	< 0.0001
TPVD-M2	14.1 (2.4)	7–21	12.3 (2.5)	6–18	< 0.0001
PI	98.4 (6.1)	–	102.8 (4.5)	–	< 0.0001
PHI	29.3 (3.6)	–	26.6 (2.4)	–	< 0.0001

p values refer to mean (SD) of male vs. female; SD — standard deviation; Min — minimum value; Max — maximum value; O-SNP — the “orale-spina nasalis posterior” distance; AWPA — anterior width of the palatal arch; PWPA — posterior width of the palatal arch; GPC(R) — the depth of the right greater palatine canal; GPC(L) — the depth of the left greater palatine canal; TPVD-M2 — total palatal vault depth at the level of the second molar; PI — palatal index; PHI — palatal height index

Table 2. Inter-measurement correlations

	GPC(L)	GPC(R)	O-SNP	TPVD-M2	PWPA	AWPA
GPC(L)	–	R = 0.80 p < 0.0001	R = 0.37 p < 0.0001	R = 0.39 p < 0.0001	R = 0.23 p < 0.0001	R = 0.20 p < 0.0001
GPC(R)	R = 0.80 p < 0.0001	–	R = 0.36 p < 0.0001	R = 0.38 p < 0.0001	R = 0.21 p < 0.0001	R = 0.21 p < 0.0001
O-SNP	R = 0.37 p < 0.0001	R = 0.36 p < 0.0001	–	R = 0.26 p < 0.0001	R = 0.27 p < 0.0001	R = 0.32 p < 0.0001
TPVD-M2	R = 0.39 p < 0.0001	R = 0.38 p < 0.0001	R = 0.26 p < 0.0001	–	R = 0.11 p = 0.003	R = 0.13 p = 0.0004
PWPA	R = 0.23 p < 0.0001	R = 0.21 p < 0.0001	R = 0.27 p < 0.0001	R = 0.11 p = 0.003	–	R = 0.73 p < 0.0001
AWPA	R = 0.20 p < 0.0001	R = 0.21 p < 0.0001	R = 0.32 p < 0.0001	R = 0.13 p = 0.0004	R = 0.73 p < 0.0001	–

R — Spearman’s rank correlation coefficient; O-SNP — the “orale-spina nasalis posterior” distance; AWPA — anterior width of the palatal arch; PWPA — posterior width of the palatal arch; GPC(R) — the depth of the right greater palatine canal; GPC(L) — the depth of the left greater palatine canal; TPVD-M2 — total palatal vault depth at the level of the second molar; PI — palatal index; PHI — palatal height index

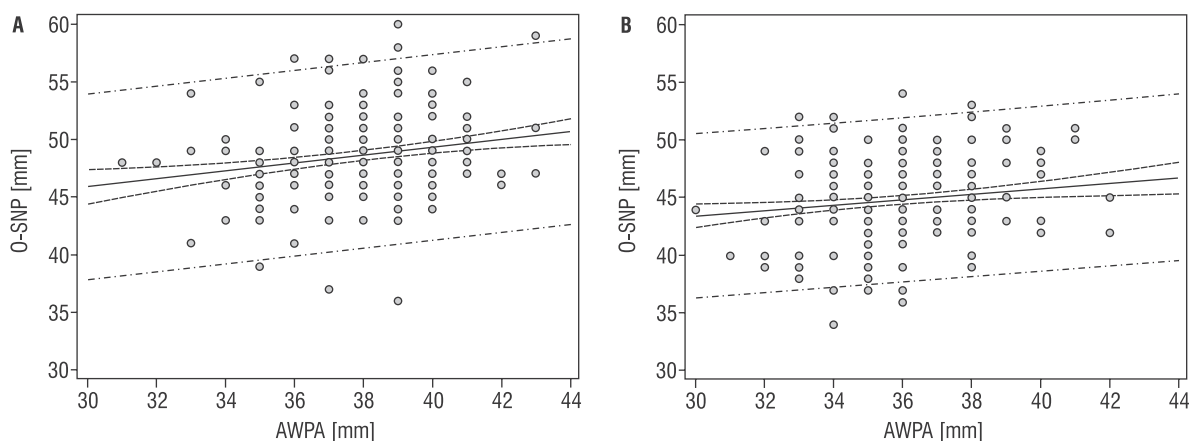


Figure 2. Regression scatter plot — length (O-SNP) vs. anterior width of the palatal arch (AWPA); **A.** Males; $y = 35.6231 + 0.3427x$; $r = 0.04$, $p < 0.0001$; **B.** Females; $y = 36.3866 + 0.2347x$; $r = 0.02$; $p = 0.0041$. The continuous line represents regression. The dash lines represent the 95% confidence intervals of the regression. The dash-dot lines represent the 95% prediction intervals.

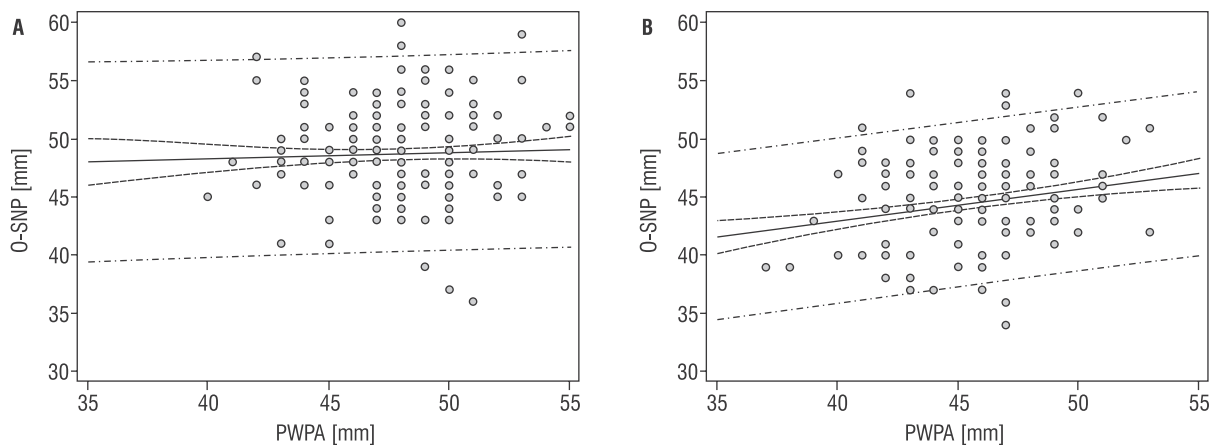


Figure 3. Regression scatter plot — length (O-SNP) vs. posterior width of the palatal arch (PWPA); **A.** Males; $y = 46.1762 + 0.05269x$; $r = 0.0014$, $p = 0.48$; **B.** Females; $y = 32.1028 + 0.2725x$; $r = 0.05$; $p < 0.0001$. The continuous line represents regression. The dash lines represent the 95% confidence intervals of the regression. The das-dot lines represent the 95% prediction intervals.

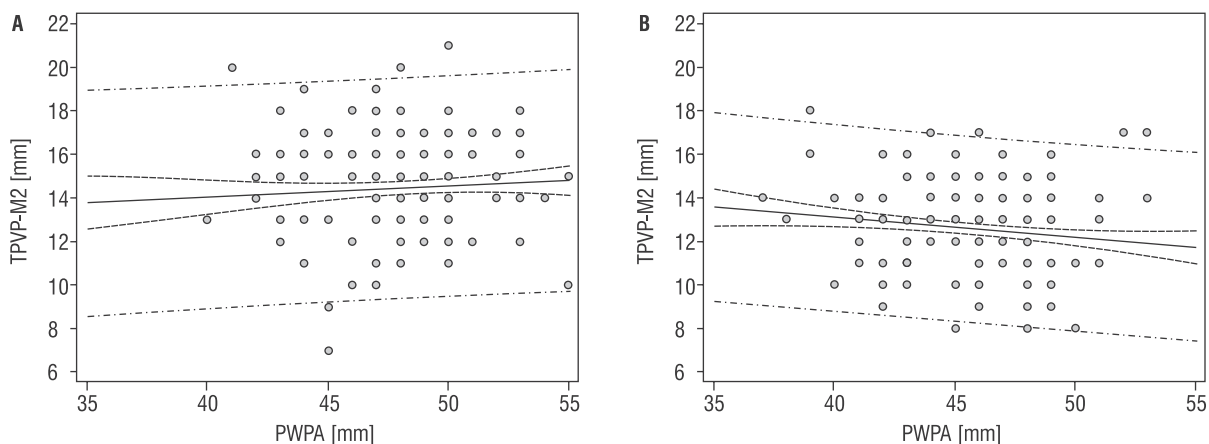


Figure 4. Regression scatter plot — height (TPVD-M2) vs. posterior width of the palatal arch (PWPA); **A.** Males; $y = 12.0047 + 0.05089x$; $r = 0.004$; $p = 0.27$; **B.** Females; $y = 16.8143 + (-0.09281)x$; $r = 0.017$; $p = 0.018$. The continuous line represents regression. The dash lines represent the 95% confidence intervals of the regression. The das-dot lines represent the 95% prediction intervals.

Based on the measured parameters, several mathematical models for sex determination were obtained. We present two of them in this manuscript — the first model (1) as the simplest one in terms of the needed measurements, and the second (2) as the one with the highest reliability.

The formula (1) based on the O-SNP distance alone had the best reliability rate (68.35%) of all of the single parameter equations:

$$P(Y = M | O-SNP) = \frac{e^{-11.58 + 0.240 - SNP}}{1 + e^{-11.58 + 0.240 - SNP}} \quad (1),$$

where: $P(Y = M)$ — probability that the assessed skull is male; O-SNP — the “orale-spina nasalis posterior” distance; e — constant (2.72).

The formula (2) based on the depth of the right GPC, the O-SNP distance and the AWPA had a reliability rate of 78.37% — the highest among all obtained equations based on the measured parameters:

$$P(Y = M | O-SNP, GPC(R), AWPA) = \frac{e^{-1.20 + 0.070 - SNP - 0.13GPC(R) + 0.11AWPA}}{1 + e^{-1.20 + 0.070 - SNP - 0.13GPC(R) + 0.11AWPA}} \quad (2),$$

where: $P(Y = M)$ — probability that the assessed skull is male; O-SNP — the “orale-spina nasalis posterior” distance; GPC(R) — the depth of the right greater palatine canal; AWPA — anterior width of the palatal arch; e — constant (2.72).

DISCUSSION

Though much has been written on traditional and novel (geometric morphometrics) approaches to sexing human bones, the palatine bones themselves received little attention [3, 5, 8]. Recent years have brought about an increase of interest in palatal measurements in forensic medicine, mainly due to the introduction of geometric morphometrics [3, 8].

As mentioned earlier, the skeletal feature that is easiest to sex after the pelvis is the skull [7, 13, 19]. The craniofacial structures have the advantage of being composed largely of hard tissue, which is relatively indestructible [21]. However, sex determination using the skull is not reliable until well after puberty [21].

The aims of the present study were to assess whether the hard palate reveals any measurable sex-related differences, and to create a mathematical model which would differentiate between males and females using hard palate measurements alone. We have chosen the mentioned specific measurements for this study, because the anatomical reference points they base on are simple to identify, both on dry skulls and CT scans, and the measurements themselves are easy to replicate, even if the skull itself is partially damaged. Results of previously published metric analyses basing on CT scans confirmed appropriate agreement between CT-based metrics and classical osteometric studies [18].

The major findings of our study are that single measurement formulas for sex determination have a reliability of about 70%, while complex formulas (composed of three measurements) come close to a reliability of 80%. Numerous previously conducted studies have shown that classical anthropological cranial sexual dimorphism analysis has an accuracy rate of 85–95% [18, 21, 25]. However, in contrast to this study, the previously cited works were based on several cranial measurements not limited to the hard palate itself. This restricts the use of such formulas in cases where the skull is significantly damaged.

Taking into account the general morphometric features, male palates analysed in this study were longer, broader and deeper than the female ones, which generally complies with the findings of other authors [5]. However there are works showing that it is the female palate that is actually wider and longer [3]. The reason for this discrepancy cannot be explained by racial differences alone. We would argue that because of the sample size of our study it is safer to

say that the results of Bigoni et al. [3] are the ones that should be approached with care. However, one has to bear in mind that size-related sexual dimorphism shows significant inter-population variability [13]. Thus, using formulas obtained on different populations than the one that is currently being assessed might lead to misidentification of human remains [3]. Cranium dimorphism is also subject to demographic changes resulting from human migration, which has especially increased in the last two centuries (most seen in North America and Central Europe) [11, 12]. This, combined with significant tourism, and relocations due to e.g. career/family reasons, prevents determination of the population specificity, and thus limits the application of population specific methods. This underlines one of the major drawbacks of purely morphometric studies like this one. As mentioned above, a possible solution to this problem has emerged a few years back as geometric morphometrics [3]. On the other hand, another possible solution to this problem is continuously updating the formulas used to sex a specific population [21].

The assessment of inter-observer agreement has grown in importance recent years [18]. It allows minimising subjectivity and increasing consistency of morphological scoring [15]. However, the majority of previously published studies did not perform such an analysis, either because it was too costly and time-consuming or because the authors assumed that the examination of morphological characteristics is already sufficiently standardised by ordinal scoring. Our work has partially focused on single trait examinations, which could suffer the most because of observational and metric inconsistencies, thus lead to low reliability of sex determination models. The high inter-rater agreement found in this study prevented such mistakes and assured that the reliability of the obtained formulas can be relied on.

CONCLUSIONS

Concluding, the most prominent sexually dimorphic parameters were the O-SNP, the GPC depth and the AWPA. The mathematical models presented in the current study can be used to successfully distinguish between sexes during forensic examination. The hard palate should be considered as an important feature when sexing the entire human skeleton or the human skull alone. Further studies should focus on analysing the palatal bones using geometric morphometrics.

ACKNOWLEDGEMENTS

This work has been partially presented at the XXXI Congress of the Polish Anatomical Society, Dolina Charlotty, 27–30.06.2013.

AUTHOR CONTRIBUTION

Design and planning of the study — IMT, PK, MN, JAW; Data collection (measuring the samples) — IMT, PF, MG, MP, AŚ, MN; Data interpretation — IMT, KS (statistics); IMT, RCh (radiological interpretation); IMT, PK (forensic medicine application); Bibliographic search — IMT, JAW; Drafting and revising the manuscript — IMT; Critical revision of the manuscript — RCh, PK, MN, JAW. All authors have read and approved the final version of the manuscript. All co-authors confirm the above-mentioned contributions and consent to the fact that this study is a part of Iwona M. Tomaszewska's PhD thesis. The co-authors confirm that Iwona M. Tomaszewska has contributed significantly (73% in total) to every part of this study, as stated above.

REFERENCES

1. Beauthier JP, Lefevre P, Meunier M, Orban R, Polet C, Werquin JP, Quatrehomme G (2010) Palatine sutures as age indicator: a controlled study in the elderly. *J Forensic Sci*, 55: 153–158.
2. Berrizbeitia EL (1989) Sex determination with the head of the radius. *J Forensic Sci*, 34: 1206–1213.
3. Bigoni L, Velemínska J, Bruzek J (2010) Three-dimensional geometric morphometric analysis of cranio-facial sexual dimorphism in a Central European sample of known sex. *Homo*, 61: 16–32.
4. Burdan F, Szumiło J, Walocha J, Klepacz L, Madej B, Dworżański W, Klepacz R, Dworżańska A, Czekańska-Chehab E, Drop A (2012) Morphology of the foramen magnum in young Eastern European adults. *Folia Morphol*, 71: 205–216.
5. Chovalopoulou ME, Valakos ED, Manolis SK (2013) Sex determination by three-dimensional geometric morphometrics of the palate and cranial base. *Anthropol Anz*, 70: 407–425.
6. Cullu N, Deveer M, Sahan M, Tetiker H, Yilmaz M (2013) Radiological evaluation of the styloid process length in the normal population. *Folia Morphol*, 72: 318–321.
7. Duric M, Rakocevic Z, Donic D (2005) The reability of sex determination of skeletons from forensic context in the Balkans. *Forensic Sci Int*, 147: 159–164.
8. Franklin D, Freedman L, Milne N, Oxnard CE (2006) A geometric morphometric study of sexual dimorphism in the crania of indigenous southern Africans. *S Afr J Sci*, 102: 229–238.
9. Gapert R, Black S, Last J (2009) Sex determination from the foramen magnum: discriminant function analysis in an eighteenth and nineteenth century British sample. *Int J Legal Med*, 123: 25–33.
10. Howard-Swirzinski K, Edwards PC, Saini TS, Norton NS (2010) Length and geometric patterns of the greater palatine canal observed in cone beam computed tomography. *Int J Dent*, pii: 292753.
11. Jantz RL (2001) Cranial change in Americans: 1850–1975. *J Forensic Sci*, 46: 784–787.
12. Jonke E, Prossinger H, Bookstein FL, Schaefer K, Bernhard M, Freudenthaler JW (2007) Secular trends in the facial skull from the 19th century to the present analyzed with geometric morphometrics. *Am J Orthod Dentofacial Orthop*, 132: 63–70.
13. Kemkes A, Gobel T (2006) Metric assessment of the “mastoid triangle” for sex determination: a validation study. *J Forensic Sci*, 51: 985–989.
14. Kim DI, Kim YS, Lee UY, Han SH (2013) Sex determination from calcaneus in Korean using discriminant analysis. *Forensic Sci Int*, 228: 177. e1–7.
15. Molto JE (1979) The assessment and meaning of intraobserver error in population studies based on discontinuous cranial traits. *Am J Phys Anthropol*, 51: 333–344.
16. Polgaj M, Bliźniewska K, Jędrzejewski K, Majos A, Topol M (2013) Morphological study of linea aspera variations: proposal of classification and sexual dimorphism. *Folia Morphol*, 72: 72–77.
17. Ramadan SU, Türkmen N, Dolgun NA, Gökharman D, Menezes RG, Kacar M, Koşar U (2010) Sex determination from measurements of the sternum and fourth rib using multislice computed tomography of the chest. *Forensic Sci Int*, 197: 120. e1–5.
18. Ramsthaler F, Kettner M, Gehl A, Verhoff MA (2010) Digital forensic osteology: morphological sexing of skeletal remains using volume-rendered cranial CT scans. *Forensic Sci Int*, 195: 148–152.
19. Spradley MK, Jantz RL (2011) Sex estimation in forensic anthropology: skull versus postcranial elements. *J Forensic Sci*, 56: 289–296.
20. Thali MJ, Braun M, Buck U, Aghayev E, Jackowski C, Vock P, Sonnenschein M, Dirnhofer R (2005) VIRTopsy-scientific documentation, reconstruction and animation in forensic: individual and real 3D data based geo-metric approach including optical body/object surface and radiological CT/MRI scanning. *J Forensic Sci*, 50: 428–442.
21. Uthman AT, Al-Rawi NH, Al-Timimi JF (2012) Evaluation of foramen magnum in gender determination using helical CT scanning. *Dentomaxillofac Radiol*, 41: 197–202.
22. Verhoff MA, Ramsthaler F, Krahahn J, Deml U, Gille RJ, Grabherr S, Thali MJ, Kreutz K (2008) Digital forensic osteology-possibilities in cooperation with the Virtopsy project. *Forensic Sci Int*, 174: 152–156.
23. Vodanović M, Dumančić J, Galić I, Savić Pavićin I, Petrovečki M, Cameriere R, Brkić H (2011) Age estimation in archaeological skeletal remains: evaluation of four non-destructive age calculation methods. *J Forensic Odontostomatol*, 29: 14–21.
24. Volk C, Ubelaker DH (2002) A test of the Phenice method for the estimation of sex. *J Forensic Sci*, 47: 19–24.
25. Williams BA, Rogers T (2006) Evaluating the accuracy and precision of cranial morphological traits for sex determination. *J Forensic Sci*, 51: 729–735.