

GRZEGORZ GONCERZ¹, TOMASZ BEREZA¹, JANUSZ SKRZAT¹, JERZY MITUS¹,
MALGORZATA MAZUR¹, DAWID MADUZIA¹, MARCIN KUNIEWICZ¹

ANGIOARCHITECTURE OF UTERINE CERVICAL LEIOMYOMATA — A SEM STUDY

Abstract: Aim: The main goal of this study was assessment of vascular structure of cervical uterine leiomyomata.

Materials and Methods: The study was carried out on ten human uteri collected upon autopsy. Vessels were injected with synthetic resin, next corroded and coated with gold, finally observed using scanning electron microscope.

Results: Most of cervical fibroids were observed in the middle third of the wall of cervix. They were surrounded by relatively dense 'vascular capsule'. consisted of flattened vein, arterioles and capillaries.

Conclusions: Structure of cervical uterine leiomyomata was similar to those observed in initial stage of growth of myometrial fibroids.

Key words: leiomyomata, uterine cervix, blood supply.

INTRODUCTION

Leiomyomata develop from transformation of smooth muscle cell and/or connective tissue components. Molecules that initiate transformation and regulate tumor growth remain unknown. Uterine leiomyomata, the most common benign tumours of the female internal genital system are traditionally classified into: intramural, subserous, or submucous [1]. Following the regulation of the European Society of Hysteroscopy the submucous fibroids are divided depending on the protrusion within the uterine cavity, into types 0, I and II. Growth factors are usually certain molecules that influence growth of cells, their differentiation, growth of new vessels, cellular hypertrophy. Among key growth factors identified in leiomyomata are members of epidermal growth factor family, platelet derived growth factor, vascular endothelial growth factor, fibroblast growth factor, transforming growth factor-beta [2], adrenomedullin [3], insulin-like growth factor, substance P [4], heparin-binding growth factor [5]. Blood supply of normal human uterine cervix was a subject of several studies, using corrosion casting and scanning electron microscopy (SEM) [6]. Most of the reports on leiomyoma blood supply are quali-

tative and consider blood supply within the uterine corpus [7–16]. The purpose for this study was to evaluate the vascular structure of the uterine leiomyomata of less common location, within the uterine cervix, using the microcorrosion technique SEM [17].

MATERIAL AND METHODS

Ten uteri containing intracervical fibroids were obtained upon autopsy of women aged 25–56 years, deceased due to causes not related to disorders of the reproductive system. The material was collected 6–24 h after death. Each uterus together with ovaries and cervical portion of the vagina was removed in such a way that relatively long fragments of uterine and ovarian vessels (arteries and veins) were retained.

Immediately after removal, all uteri were perfused via the afferent arteries with prewarmed (37°C), heparinized saline (12.5 IU/ml heparin; Polfa, Poland, containing 3% dextrane (70kDa) and 0.025% lidocaine (Lignocaine; Polfa, Poland), until the fluid outflowing via the veins was completely transparent (~5 min). Next perfusion was continued using a solution of 0.66% paraformaldehyde/0.08% glutaraldehyde (Sigma, Germany) in 0.1 mol/l cacodylate buffer, pH 7.4 supplemented with 0.2% lidocaine. Finally, the vascular system was injected with 60–80 ml of Mercor CL-2R resin (Vilene Comp. Ltd. Japan) containing 0.0625 mg/ml methyl acrylate polymerization initiator (Vilene Comp. Ltd.) Japan and the uteri were left in a warm water bath (56°C) for several hours to allow polymerization and tempering of the resin.

When the polymerization was completed, the uterine tissues were macerated for 5–6 days by repeated baths in 10% potassium hydroxide at 37°C followed by washing with warm (50–55°C) running tap water. The obtained vascular casts were washed for the next 4–5 days in multiple changes of distilled water under mild vacuum conditions, cleaned in 5% trichloroacetic acid for 1–2 days, washed again in distilled water for 2–3 days and freeze-dried in a lyophilizer (Liovag G2; Aqua Fina, Germany).

The freeze-dried casts were examined macroscopically, gently dissected [18] to expose the vasculature of myomata and stored in an exiccator containing phosphorus pentoxide until the microscopic examination. They were then mounted onto copper plates using colloidal silver and 'conductive bridges' and coated with gold. The casts were examined using a JEOL SEM 35-CF (Jeol, France) scanning electron microscope at 20–25 kV. The study was approved by Ethical Committee of Jagiellonian University (KBET/121/8/2007).

RESULTS

Uterine cervix consists of large amounts of dense collections of connective tissue which is mostly consisting of an extracellular matrix. This matrix may be a source of large quantities of different vascular growth factors, what may promote angiogenesis in the cervical uterine fibroids. Most of observed tumours were however avascular. They were found in the lateral third of the cervical wall. It seems that their development is based mostly on the incorporation of the maternal vascular bed, while their own vessels were not fully formed yet. We did not observe large vessels running through the substance of the leiomyomata, as seen within the intramural fibroids. The peripheral vascular capsule [19–22] was also less dense as seen within the previously described tumours.

Uterine cervix differs structurally from the fundus and corpus of the uterus. Its mucosa is not exfoliated during menstruation. The muscular layer is significantly thinner than this in the corpus and contains relatively high quantities of the connective tissue elements. Such structure and quite permanent anatomical condition cause that vascular network in this area is relatively regular. Rich amounts of connective tissue and less amount of muscular fibers are causative factors of less common frequency of intracervical fibroids, comparing to the leiomyomata of the corpus.

The tumours seen in the cervix were predominantly visible in the muscular layer of this region, quite a large distance from the cervical canal, approximately 13–27 mm away from its long axis (Fig. 1). In the sagittal sections the intracervical fibroids were seen as the cavities, characterized by a loose peripheral “vascular capsule” in comparison to the dense capsule of intramural fibroids (Fig. 2, Fig. 3). Generally at first sight the intracervical fibroids were characterized by an absence of the “vascular capsule” (Fig. 4) [23–26]. The vessels inside the fibroids were absent what could be a result of their true absence, due to the primary stage of their development or an artifact due to poor injection. In the outer surface of such fibroids one could observe large vessels traversing the surface. Large vessels were surrounded by empty regions which might have been the result of condensation of perivascular connective tissue, which was removed during corrosion process. In general the vascular structure of cervical uterine leiomyomata resembled the composition of those tumors seen in myometrium of uterine corpus, but rather in very early stage of their development. Dense vascular capsule (pseudocapsule) is an important region of massive release of different pro- and antiangiogenic proteins which may promote changes in the periphery of the lesion [20, 27].

There have been a number of published studies using gene expression microarrays on leiomyoma tissue, used also gene expression microarray to identify angiogenesis-related genes with a differential expression between leiomyomata and adjacent myometrium [28–31], although in our case they seem to be out of use, since uterine cervix does not contain myometrial tissue. Anyway morpho-

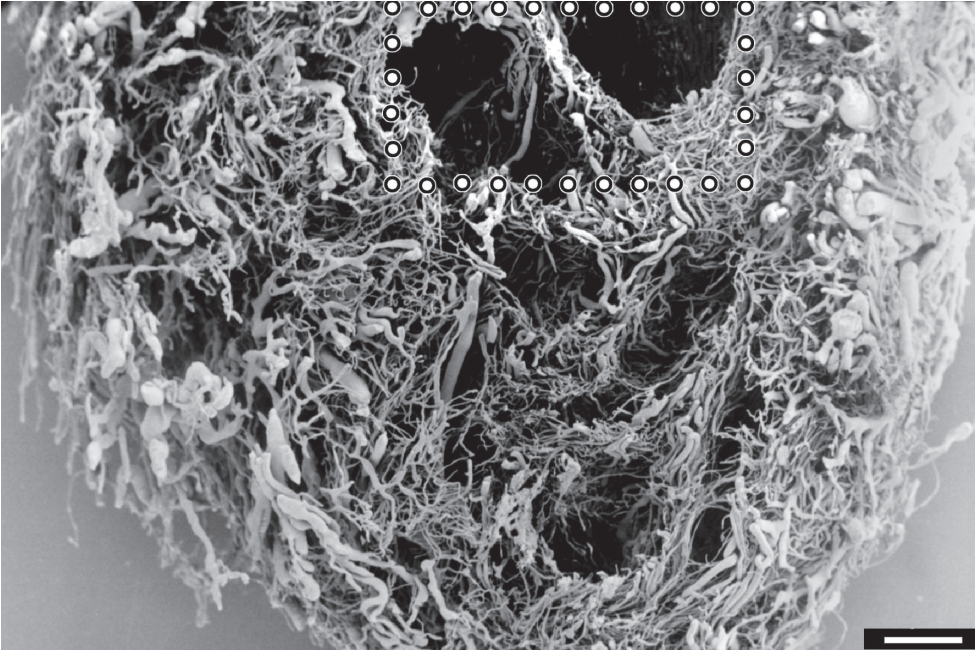


Fig. 1. Corrosion cast of uterine cervix of 39 year old female. SEM. Coronal section. Multiple intracervicalleiomomata. The marked area seen on the Fig. 2. Bar = 1000 μ m.

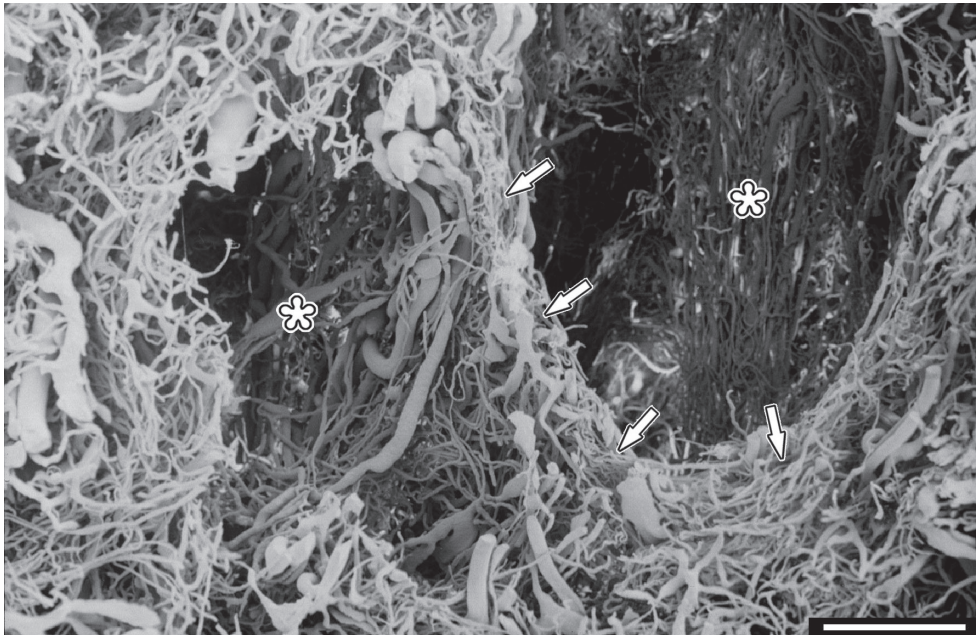


Fig. 2. Corrosion cast of uterine cervix of 39 year old female. SEM. Intracervicalleiomomata [*]. Relatively dense "vascular capsule" [\uparrow]. Bar = 1000 μ m.

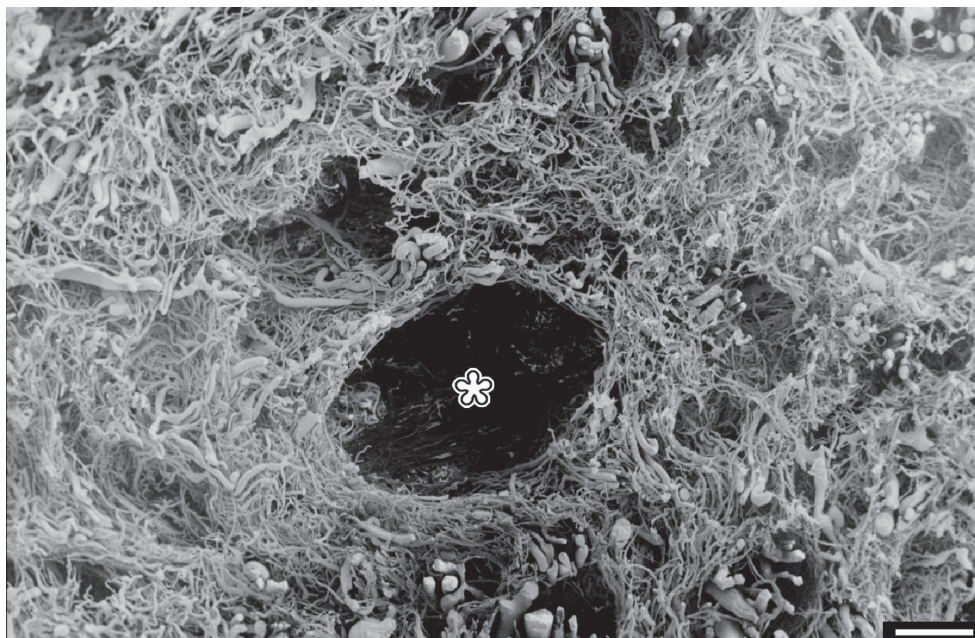


Fig. 3. Corrosion cast of uterine cervix of 45 year old female. SEM. Intracervical leiomyoma [*].
Bar = 1000 μ m.

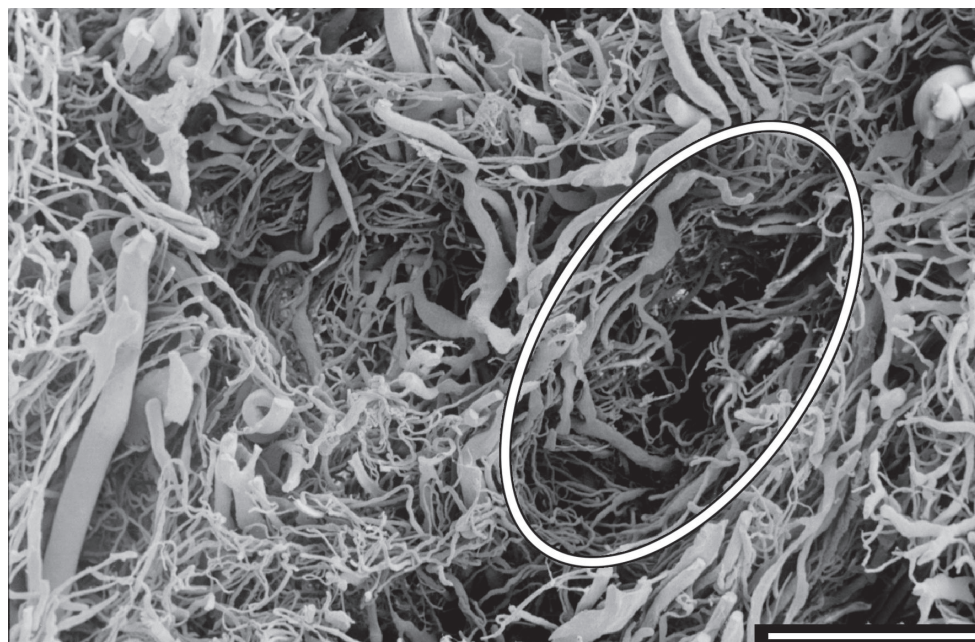


Fig. 4. Corrosion cast of uterine cervix of 47 year old female. SEM. Coronal section.
Loose "vascular capsule" of intracervical leiomyoma. Bar = 1000 μ m.

logical studies presented in this work seem to help to imagine how rich is the reservoir of connective tissue in the cervix (lack of tissue corroded), which may be very valuable source of proangiogenic factors, causing growth of leiomyomata [32, 33]. Further studies on the morphology may have a strong impact on methods of pharmacological and surgical treatment [34].

CONFLICT OF INTEREST STATEMENT

None declared.

REFERENCES

1. *Falcone T., Parker W.H.*: Surgical management of leiomyomas for fertility or uterine preservation. *Obstet Gynecol.* 2013; 121 (4): 856–868. — 2. *Arici A., Sozen I.*: Transforming growth factor-beta3 is expressed at high levels in leiomyoma where it stimulates fibronectin expression and cell proliferation. *Fertil Steril.* 2000; 73: 1006–1011. — 3. *Hague S., Zhang L., Oehler M.K., Manek S., MacKenzie I.Z., Bicknell R., Rees M.C.*: Expression of the hypoxically regulated angiogenic factor adrenomedullin correlates with uterine leiomyoma vascular density. *Clin Cancer Res.* 2000; 6: 2808–2814. — 4. *Malvasi A., Tinelli A., Cavallotti C., Morroni M., Tsin D.A., Nezhad C., Stark M., Mettler L.*: Distribution of substance P (SP) and vasoactive intestinal peptide (VIP) in pseudocapsules of uterine fibroids. *Peptides.* 2011; 32 (2): 327–332. — 5. *Mangrulkar R.S., Ono M., Ishikawa M., Takashima S., Klagsbrun M., Nowak R.A.*: Isolation and characterization of heparin-binding growth factors in human leiomyomas and normal myometrium. *BiolReprod.* 1995; 53: 636–646. — 6. *Bereza T., Tomaszewski K.A., Walocha J., Mizia E., Bachul P., Chmielewski P.*: Vascular architecture of the human uterine cervix, as assessed in light- and scanning electron microscopy. *Folia Morphol.* 2012; 71 (3): 142–147, il. — 7. *Faulkner R.I.*: The blood vessels of myomatous uteri. *Am J Obstet Gynecol.* 1945; 47: 185–197. — 8. *Farrer-Brown G., Beilby J.O.W., Rowles P.M.*: Microvasculature of the uterus: an injection method of study. *Obstet Gynecol.* 1970; 35: 21–30. — 9. *Farrer-Brown G., Beilby J.O.W., Tarbit M.H.*: The vascular patterns in myomatous uteri. *J Obstet Gynaecol Br Commwlth.* 1970; 77: 967–975. — 10. *Farrer-Brown G., Beilby J.O., Tarbit M.H.*: Venous changes in the endometrium of myomatous uteri. *Obstet Gynecol.* 1971; 38: 743–751.
11. *Holmgren B.*: Some observations on the blood vessels of the uterus under normal conditions and in myoma. *ActaObstetGynaec Scand.* 1938; 18: 192–203. — 12. *Sampson J.A.*: The influence of myomata on the blood supply of the uterus with special reference to abnormal uterine bleeding. *Surg Gynecol Obstet.* 1912; 16: 144–180. — 13. *Szamatowicz M., Kotarski J.*: Selective progesterone receptor modulator (ulipristal acetate — a new option in the pharmacological treatment of uterine fibroids in women. *Ginekol Pol.* 2013; 84 (3): 219–222. — 14. *Walocha J.A., Litwin J.A., Miodoński A.J.*: Vascular system of intramural leiomyomata revealed by corrosion casting and scanning electron microscopy. *Hum Reprod.* 2003; 18 (5): 1088–1093. — 15. *Walocha J.A., Miodoński A.J., Szczepański W., Skrzat J., Stachura J.*: Two types of vascularisation of intramural uterine leiomyomata revealed by corrosion casting and immunohistochemical study. *Folia Morphol.* 2004; 63(1): 37–41. — 16. *Walocha J.A., Miodoński A.J., Tsibris J.M., Skrzat J.*: Tworzenie nowych naczyń na terenie mięśniaków macicy zlokalizowanych w błonie mięśniowej narządu. New vessels formation within intramural leiomyomata. *Ginekol Pol.* 2004; 75, 3: 203–208. — 17. *Lametschwandtner A., Lametschwandtner U., Weiger T.*: Scanning electron microscopy of vascular corrosion casts — technique and application: updated review. *Scanning Microsc.* 1990; 4: 889–941. — 18. *Walocha J.A., Miodoński A.J., Nowogrodzka-Zagórska M., Kuciel R., Gorczyca J.*: Application of a mixture of glycol polyethylenes for the preparation of microcorrosion casts — an observation. *Folia*

Morphol. 2002; 61 (4): 313–316. — **19.** De Falco M., Staibano S., Mascolo M., Mignogna C., Improda L., Ciociola F., Carbone I.F., Di Lieto A.: Leiomyomapseudocapsule after pre-surgical treatment with gonadotropin-releasing hormone agonists: relationship between clinical features and immunohistochemical changes. Eur J Obstet Gynecol Reprod Biol. 2009; 144 (1): 44–47. — **20.** Di Tommaso S., Massari S., Malvasi A., Bozzetti M.P., Tinelli A.: Gene expression analysis reveals an angiogenic profile in uterine leiomyomapseudocapsule. Mol Hum Reprod. 2013; 19(6): 380–387.

21. Malvasi A., Cavallotti C., Morroni M., Lorenzi T., Dell'Edera D., Nicolardi G., Tinelli A.: Uterine fibroid pseudocapsule studied by transmission electron microscopy. Eur J Obstet Gynecol Reprod Biol. 2012; 162 (2): 187–191. — **22.** Malvasi A., Tinelli A., Rahimi S., D'Agnes G., Rotoni C., Dell'Edera D., Tsin D.A., Cavallotti C.: A three-dimensional morphological reconstruction of uterine leiomyomapseudocapsule vasculature by the Allen-Cahn mathematical model. Biomed Pharmacother. 2011 Aug; 65(5): 359–363. — **23.** Tinelli A., Hurst B.S., Hudelist G., Tsin D.A., Stark M., Mettler L., Guido M., Malvasi A.: Laparoscopic myomectomy focusing on the myomapseudocapsule: technical and outcome reports. Hum Reprod. 2012; 27(2): 427–435. — **24.** Tinelli A., Malvasi A., Cavallotti C., Dell'Edera D., Tsin D.A., Stark M., Mettler L.: The management of fibroids based on immunohistochemical studies of their pseudocapsules. Expert Opin Ther Targets. 2011; 15 (11): 1241–1247. — **25.** Tinelli A., Malvasi A., Hurst B.S., Tsin D.A., Davila F., Dominguez G., Dell'edera D., Cavallotti C., Negro R., Gustapane S., Teigland C.M., Mettler L.: Surgical management of neurovascular bundle in uterine fibroid pseudocapsule. JSLS. 2012; 16 (1): 119–129. — **26.** Tinelli A., Malvasi A., Rahimi S., Negro R., Cavallotti C., Vergara D., Vittori G., Mettler L.: Myomapseudocapsule: a distinct endocrino-anatomical entity in gynecological surgery. Gynecol Endocrinol. 2009; 25 (10): 661–667. — **27.** Hong T., Shimada Y., Uchida S., Itami A., Li Z., Ding Y., Kaganoi J., Komoto I., Sakurai T., Imamura M.: Expression of the angiogenic and apoptotic factors in leiomyosarcoma and leiomyoma. Int J Mol Med. 2001; 8: 141–148. — **28.** Mehine M., Kaasinen E., Mäkinen N., Katainen R., Kämpjärvi K., Pitkänen E., Heinonen H.R., Bützow R., Kılıpvaara O., Kuosmanen A., Ristolainen H., Gentile M., Sjöberg J., Vahteristo P., Aaltonen L.A.: Characterization of uterine leiomyomas by whole-genome sequencing. N Engl J Med. 2013; 4: 369 (1): 43–49. — **29.** Tsibris J.C., Segars J., Coppola D., Mane S., Wilbanks G.D., O'Brien W.F., Spellacy W.N.: Insights from gene arrays on the development and growth regulation of uterine leiomyomata. Fertil Steril. 2002; 78: 1–8. — **30.** Tsibris J.C., Segars J., Enkemann S., Coppola D., Wilbanks G.D., O'Brien W.F., Spellacy W.N.: New and old regulators of uterine leiomyoma growth from screening with DNA arrays. Fertil Steril. 2003; 80: 279–281.

31. Tsibris J.C., Maas S., Segars J.H., Nicosia S.V., Enkemann S.A., O'Brien W.F., Spellacy W.N.: New potential regulators of uterine leiomyomata from DNA arrays: the ionotropic glutamate receptor GluR2. Biochem Biophys Res Commun. 2003; 5: 312 (1): 249–254. — **32.** Bereza T., Lis G., Mituś J., Sporek M., Chmielewski P., Kolber W., Mazur M., Kuniewicz M.: Blood vessels of the intratumoral septa in uterine leiomyomata. Folia Med Cracov. 2013; 53 (2): 99–106. — **33.** Malvasi A., Cavallotti C., Nicolardi G., Pellegrino M., Dell'Edera D., Vergara D., Kunakiri J., Greco M., Tinelli A.: NT, NPY and PGP 9.5 presence in myometrium and in fibroid pseudocapsule and their possible impact on muscular physiology. Gynecol Endocrinol. 2013; 29(2): 177–181. — **34.** Zhao F., Jiao Y., Guo Z., Hou R., Wang M.: Evaluation of loop ligation of larger myomapseudocapsule combined with vasopressin on laparoscopic myomectomy. Fertil Steril. 2011; 95 (2): 762–766.

¹ Chair of Anatomy

Jagiellonian University Medical College
ul. Kopernika 12, 31-034 Kraków, Poland
Phone/Fax: +48 12 422 95 11

Corresponding author

Marcin Kuniewicz
Chair of Anatomy
Jagiellonian University Medical College
ul. Kopernika 12, 31-034 Kraków, Poland
Phone/Fax: +48 12 422 95 11
E-mail: kuniewicz@gmail.com

