

JANUSZ SKRZAT¹, ANDRZEJ SIOMA², MAGDALENA KOZERSKA¹

MORPHOLOGICAL FEATURES OF THE MACERATED CRANIAL BONES REGISTERED BY THE 3D VISION SYSTEM FOR POTENTIAL USE IN FORENSIC ANTHROPOLOGY

Abstract: In this paper we present potential usage of the 3D vision system for registering features of the macerated cranial bones. Applied 3D vision system collects height profiles of the object surface and from that data builds a three-dimensional image of the surface. This method appeared to be accurate enough to capture anatomical details of the macerated bones. With the aid of the 3D vision system we generated images of the surface of the human calvaria which was used for testing the system. Performed reconstruction visualized the imprints of the dural vascular system, cranial sutures, and the three-layer structure of the cranial bones observed in the cross-section. We figure out that the 3D vision system may deliver data which can enhance estimation of sex from the osteological material.

Key words: osteology, cranial bones, computer vision.

INTRODUCTION

The dry human cranial bones are remnants which are valuable source of information on sex and age of individual, help to explain possible reason of death and even suggests the morphology of the brain and the dural vasculature [1–4]. Cranial traits help also with identifying the ancestry of the individual. Therefore, in recent century different methods of bone investigation were developed to gain maximum number of data which could be useful in forensic anthropology. From the utilitarian point of view scientists need to use objective and accurate methods which allow to find out morphological features when only a fragment of bone is preserved. Morphology of the cranial bones provides vast range of information which can be used for individual assessment of sex and age. The way of evaluation of the gross anatomy of the bones is crucial step in anthropological expertise and forensic medicine [5].

Osteological analysis concentrates usually on the gross morphology or inner structure. However, many external details of the bone may be important for scientific study if they are captured in proper way, and obtained data are proceeded

with the aid of computer software. Thus, one can obtain detailed information on surface topography which can enhance contemporary analysis of the skull aimed not only on morphology but also for analyzing physical and mechanical properties of the cranial bones [6, 7].

In this study we propose usage of the 3D vision system to capture external details of the cranial bones. This is a novel approach to analyze osseous morphology which is not a merely visual inspection but provides numeric data which can be converted into images or become stand alone data used to compute profiles describing the roughness of the bone surface.

MATERIAL AND METHOD

The way of registering morphological features by the 3D vision system was tested on the macerated human calvaria of the male, adult individual. This choice was dictated by the fact that the bones of the cranial calvaria show variable topography determined by many anatomical structures, eg.: elevations of the muscle insertions, depressions caused by the brain gyri, dural sinuses and arterial grooves impressed mainly on the parietal bones. In order to check how the system captures minute osseous structures we removed frontal bone, and remaining edge of the right and left parietal bone was regarded as the test sample of the cranial suture. In this way we could not only registered osseous extensions of the coronal suture in the external and internal surface of the cranium but as well its interface within adjacent bones (frontal and parietal). All the bones of the examined calvaria were well preserved and intact by pathological process. Hence, all anatomical details could have been traced in visual inspection and compared to images generated by the vision system.

Applied 3D vision system was composed of the digital camera and the laser which were oriented towards the studied object. In order to capture surface topography a laser line was projected onto the surface of the cranial vault and recorded by the digital camera (Fig. 1).

During construction of a three-dimensional image, the test station was moved relatively to the camera-laser system along the axis Y of the station. In turn the cross-section of the object seen in the camera as a laser beam projected onto the test object was parallel to axis "Z" in the coordinate system of the test station. Thus, height profiles were obtained for each of the positions of the object in which it was illuminated by the laser beam and put together into a three-dimensional image of the test object (Fig. 2). Resolution in axis X, Y and Z determined for the object was following: $R_x = 0.125$ [mm/pixel], $R_y = 0.18$ [mm/scan], $R_z = 0.18$ [mm/pixel].

Detailed description of building images with the aid of the 3D vision system can be found in the paper written by Kowal and Sioma [8].

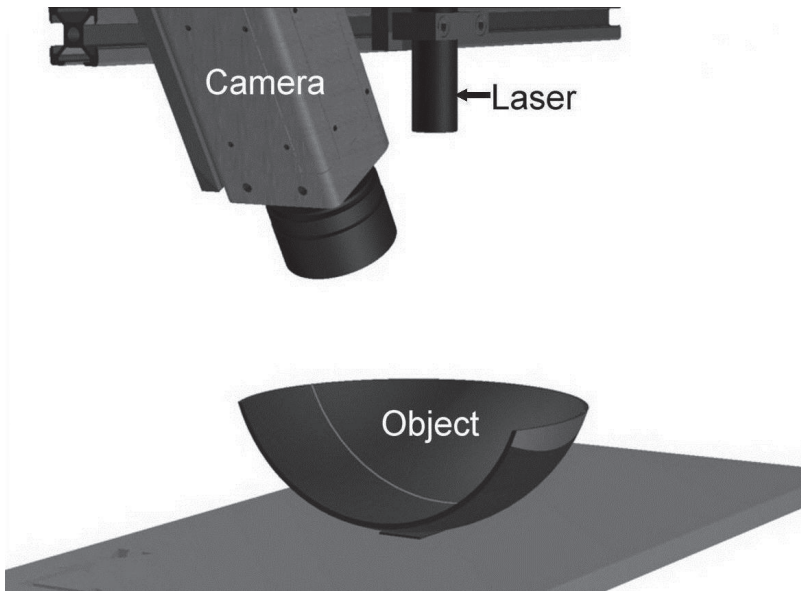


Fig. 1. Schematic drawing of the 3D vision system arranged for registering surface of the object. On the object visible laser line reflecting local surface features towards the camera.

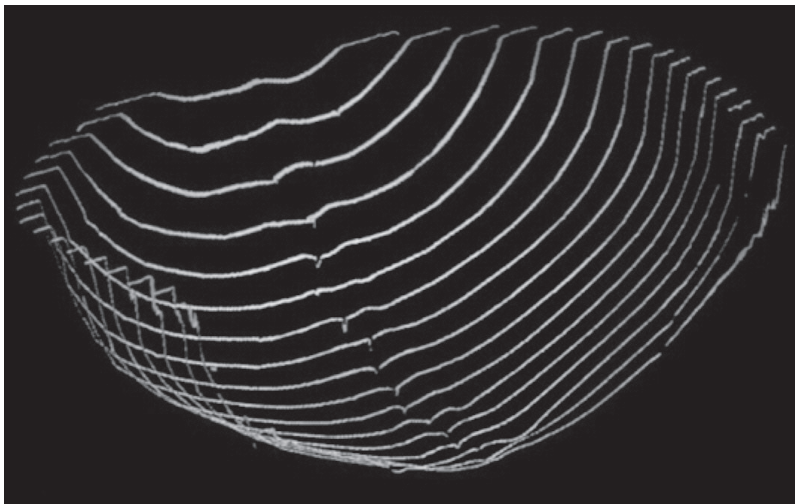


Fig. 2. Registered profiles of the cranial vault which serve to reconstruct its geometry visualized as the three-dimensional image of the surface features.

RESULTS

Hereby we present the most important projections obtained from the 3D vision system applied for registering morphological features of the inner surface of the calvaria.

In the reconstructed images of the inner surface of the calvaria following anatomical structures can recognize: the sagittal suture with the sutural bone, right and left lambdoid suture, and the bilateral edges of the coronal suture, and its interdigitation because the frontal bone was removed. Hence, abundant imprints of the branches of the middle meningeal artery can be perceived in the image from the 3D vision system. In the cross-section of the skull also the diploe can be recognized, the inner and outer layer of the compact bone forming three-layer structure which is typical for the bones of the cranial vault (Fig. 3).

From the endocranial replica (Fig. 4) elevation of the skull can be evaluated, and in this aspect the dural vasculature can be also observed. Both the arterial grooves and the groove for the sagittal sinus including the pits in which the arachnoid granulations are lodged were recognized on the images generated from the data registered by the 3D vision system.

Possibility of reconstruction of small anatomical structures, e.g.: terminal vascular branches of the middle meningeal artery, digitation of the cranial sutures or the granular foveolae suggests that 3D vision system can be helpful in morphological studies not only in gross anatomy but it is capable of registering local conformation of the bone surface.

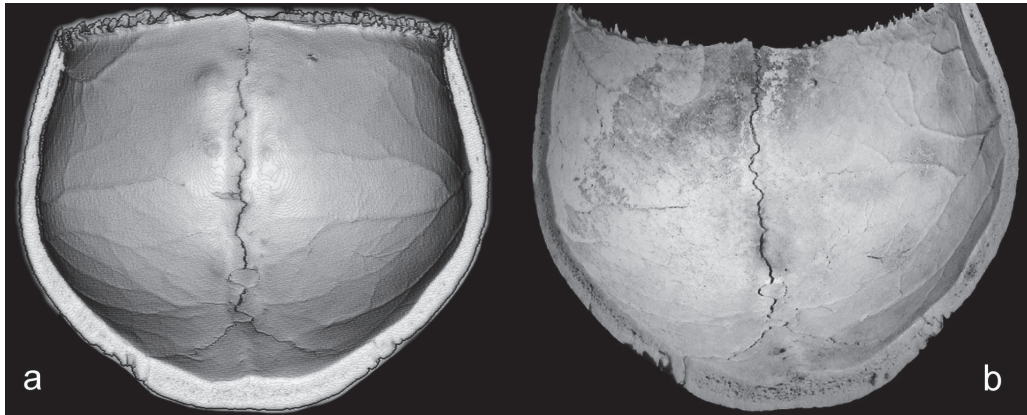


Fig. 3. Reconstructed inner surface of the parietal bones with the aid of the 3D vision system (a) compared to the digital photography of the same cranial region (b). Note a high fidelity in registering anatomical details which are easy to recognize in visual perception. Visualization was performed by the CloudCompare freeware software (<http://www.danielgm.net/cc>), a tool for 3D point cloud and mesh processing.

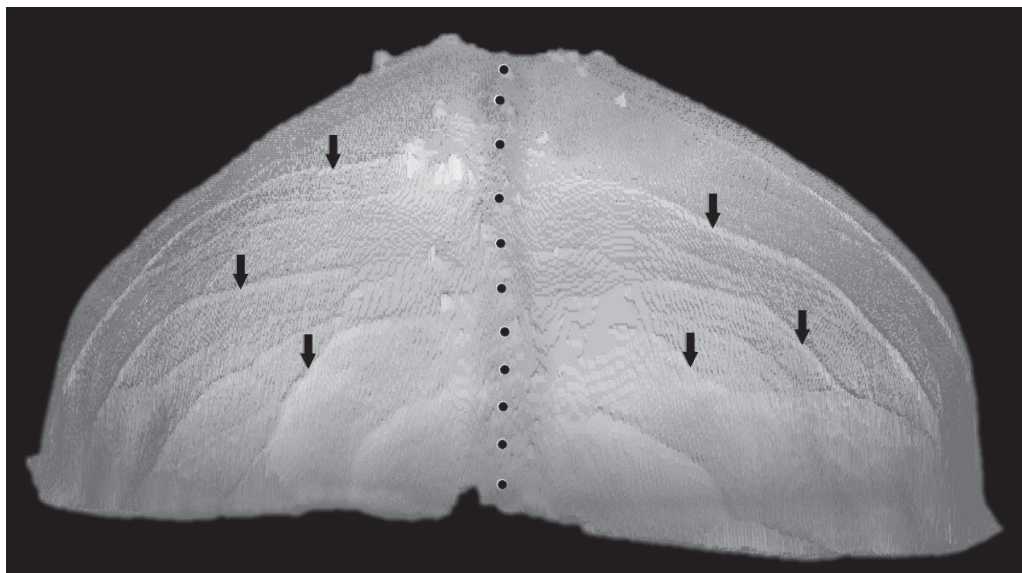


Fig. 4. Endocranial replica generated by the 3D vision system showing the skull elevation in the posterior aspect. Also visible imprints of the vascular system (the branches of the middle meningeal artery — marked by arrows, and the sagittal sinus — marked by a dotted line).

DISCUSSION

Osteological analysis of sex or age of the skeletal remnants are the fundamental in forensic anthropology. One of the crucial steps in this procedure is proper and precise registering of the external properties of the bones, and furthermore their digital imaging for morphometrical and comparative analysis. Up till now the digital photography and laser scanning systems helped to collect visual information of the bones and stored them in the computer files which could be processed in different manner [9, 10].

This paper present another, and novel method which facilitates morphological analysis of the bone surface in three-dimensional aspect. Results obtained from the 3D vision system enable to generate images which present not only overall morphology of the bones reflecting their size and shape but also provide information on the local conformation registered with high accuracy. This feature of the applied technique can be utilized in morphometrical analysis of the pathological processes afflicting small areas of bones (eg. articular surfaces), and assessing sex differences through the cranial morphology [11]. In this respect, roughness of the bone surface and size of muscle attachments were used in visual inspection of the skull as the sex predictors [12, 13]. Application of the 3D vision system for this purpose enables not only visualize the bone surface but also characterize it

numerically. Thus, presented technique can be helpful in developing quantitative methods of sex estimation from the cranial bones based on the digital analysis of the bone surface. Further studies on application of the 3D vision system in osteological analysis may become beneficial for constructing automatic system for sex identification from the skeletal remains.

CONCLUSIONS

3D vision system is able to map precisely surface topography of the macerated bones, and provides images which present anatomical details like grooves and crests. This technique delivers comprehensive reconstructions which can be used in morphological and metrical analysis of the superficial features of the bones. Data obtained from the 3D vision system can help to improve standard procedures of sex determination from the osseous remains.

ACKNOWLEDGEMENTS

The study was conducted with the approval (KBET/109/B/2012) of the Bioethics Committee of the Jagiellonian University.

This study has been funded using Jagiellonian University Medical College statutory funds.

CONFLICT OF INTEREST STATEMENT

There is no authors' conflict of interest.

REFERENCES

1. Meindl R.S., Lovejoy C.O.: Ectocranial suture closure: a revised method for the determination of skeletal age at death based on the lateral-anterior sutures. *Am J Phys Anthropol.* 1985; 68: 57–66.
- 2. Bruner E.: Fossil traces of the human thought: paleoneurology and the evolution of the genus *Homo*. *Rivista di Antropologia Journal of Anthropological Sciences.* 2003; 81: 29–56.
- 3. Bruner E., Averini M., Manzi G.: Endocranial traits. Prevalence and distribution in a recent human population. *Eur J Anat.* 2003; 7: 23–33.
- 4. Richtsmeier J.T., Aldridge K., de Leon V.B., et al.: Phenotypic integration of neurocranium and brain. *J Exp Zool (Mol Dev Evol).* 2006; 306B: 360–378.
- 5. Scheuer L.: Application of osteology to forensic medicine. *Clin Anat.* 2002; 15(4): 297–312.
- 6. Moskalenko Yu.E., Weinstein G.B., Halvorson P. et al.: Biomechanical Properties of Human Cranium: Age related aspects. *J Evol Bioc.* 2008; 44(5): 605–614.
- 7. Turner C.H.: Bone Strength: Current concepts. *Ann. N.Y. Acad. Sci.* 2006; 1068: 429–446.
- 8. Kowal J., Sioma A.: Active vision system for 3D product inspection: Learn how to construct three-dimensional vision applications by reviewing the measurements procedures. *Control Engineering USA.* 2009; 56: 46–48.
- 9. Shearer B.M., Sholts S.B., Garvin H.M., et al.: Sexual dimorphism in human browridge volume measured from 3D models of dry crania: a new digital morphometrics approach. *Forensic Sci Int.* 2012; 222(1–3): 400.e1-5.

— **10.** *Garvin H.M., Ruff C.B.*: Sexual dimorphism in skeletal browridge and chin morphologies determined using a new quantitative method. *Am J Phys Anthropol.* 2012.

11. *Rogers T.L.*: Determining the sex of human remains through cranial morphology. *J Forensic Sci.* 2005, 50(3): 493–500. — **12.** *Weiss E.*: Cranial muscle markers: a preliminary examination of size, sex, and age effects. *Homo.* 2010, 61(1): 48–58. — **13.** *Spradley M.K., Jantz R.L.*: Sex estimation in forensic anthropology: skull versus postcranial elements. *J Forensic Sci.* 2011; 56(2): 289–296; 147(4): 661–670.

¹ Department of Anatomy

Jagiellonian University Collegium Medicum
ul. Kopernika 12, 31-034 Kraków, Poland

² Faculty of Mechanical Engineering and
Robotics, Department of Process Control

AGH University of Science and Technology
al. Mickiewicza 30, 30-059 Kraków, Poland

Corresponding author:

Dr hab. Janusz Skrzat

Department of Anatomy

Jagiellonian University Medical College
ul. Kopernika 12, 31-034 Kraków, Poland

Phone/Fax: +48 12 422 95 11

E-mail: jskrzat@poczta.onet.pl

