

FOLIA MEDICA CRACoviENSIA

Vol. LIII, 1, 2013: 79–85

PL ISSN 0015-5616

MARCIN LIPSKI¹, WERONIKA LIPSKA², SYLWIA MOTYL³, TOMASZ GŁADYSZ⁴, TOMASZ ISKRA¹

ANATOMY OF THE PTERYGOMANDIBULAR SPACE — CLINICAL IMPLICATION AND REVIEW

Abstract: Aim: The aim of this study was to present review of the pterygomandibular space with some referrals to clinical practice, specially to the methods of lower teeth anesthesia.

Conclusions: Pterygomandibular space is a clinically important region which is commonly missing in anatomical textbooks. More attention should be paid to it both from theoretical and practical point of view, especially in teaching the students of first year of dental studies.

Key words: pterygomandibular space, Gow-Gates anesthesia, inferior alveolar nerve.

INTRODUCTION

Numerous cranial regions have been subjects of various anatomical and anthropological studies [1, 2]. Most of them indicate necessity of undertaking of such studies first of all because of clinical importance [3–5].

Inferior alveolar nerve blocs, one of the most common procedures in dentistry requires deep anatomical knowledge of the pterygomandibular space [6, 7]. This space is a narrow gap, which contains mostly loose areolar tissue. It communicates however through the mandibular foramen with the mandibular canal, which is traversed by inferior alveolar nerve, artery and comitant vein (IANAV). Many of the structures placed in this space are of certain importance for local anesthesia. Khoury at al. [8, 9] mention here the following: inferior alveolar nerve, artery and vein, lingual nerve, nerve to mylohyoid and the sphenomandibular ligament. The space contains mostly loose areolar tissue. Pterygomandibular space is currently of great interest — but there is still little known about anatomy of this region and the data in literature vary [10, 11].

DEFINITION OF THE PTERYGOMANDIBULAR SPACE AND ITS COMMUNICATIONS

Mandibular foramen is placed on the internal surface of the mandibular ramus within the pterygomandibular space [12–15]. The space is limited by the following:

- mandibular ramus — laterally
- interpterygoid fascia together with medial pterygoid muscle — medially
- interpterygoid aponeurosis which extends between medial and lateral pterygoid muscles — from above
- buccopharyngeal raphe — anteriorly
- infratemporal fossa and its contents — posteriorly and medially
- retromandibular fossa and its contents — posteriorly

Pterygomandibular space extends anteriorly forming a small recess — superior recess of the pterygomandibular space, which is situated between lateral pterygoid and temporal muscles [11].

Localization of the mandibular foramen is a necessity to perform inferior alveolar nerve bloc. Position of the foramen is associated with the topography of the following structures (Fig. 1): lingula, sphenomandibular ligament, groove of the neck of mandible, endocondyloid crest and endocoronoid crest. Groove of the mandibular neck runs obliquely from the back of the mandibular neck to reach the mandibular foramen. The initial portion of the groove is marked by the significant thickening called endocondyloid crest. Immediately above the lingula endocondyloid crest unifies with endocoronoid crest forming an elevation named triangular torus. Between triangular torus and the mandibular notch one can see the so called triangular plane.

Pterygomandibular space is limited medially by the interpterygoid fascia which may have a great influence on penetration of the anesthetic injected into this compartment.

Interpterygoid fascia arises from the cranial base and its attachment goes through the medial surface of the lateral pterygoid muscle till lateral surface of the medial pterygoid muscle. It ends on the border of the mandibular attachment of the medial pterygoid muscle, near the lingula and the mandibular foramen. Posteriorly the fascia fills the space between inner borders of pterygoid muscles. It arches posterolaterally towards the posterior margin of the mandibular ramus. Fibers of interpterygoid fascia mix with the membrane which extends between the styloid process of temporal and the posterior border of mandibular ramus — the stylomandibular membrane. Interpterygoid fascia is partially thickened, specially this part which is attached to spina ossis sphenoidalis and petrotympanic fissure — this segment is named sphenomandibular ligament.

Posterior fragment of the sphenomandibular space near the condylar process of the mandible is pierced by the auriculotemporal nerve, maxillary artery and vein. Anterior part of interpterygoid fascia is usually quite thin, although it may rarely create a septum between pterygoid muscles and the deep temporal fascia. This membranous septum is named the temporopterygoid fascia. If present — temporopterygoid fascia forms an anterior limitation of the pterygomandibular space and divides it into anterior and posterior (lesser) parts. It may also limit penetration of an anesthetic given into pterygomandibular space.

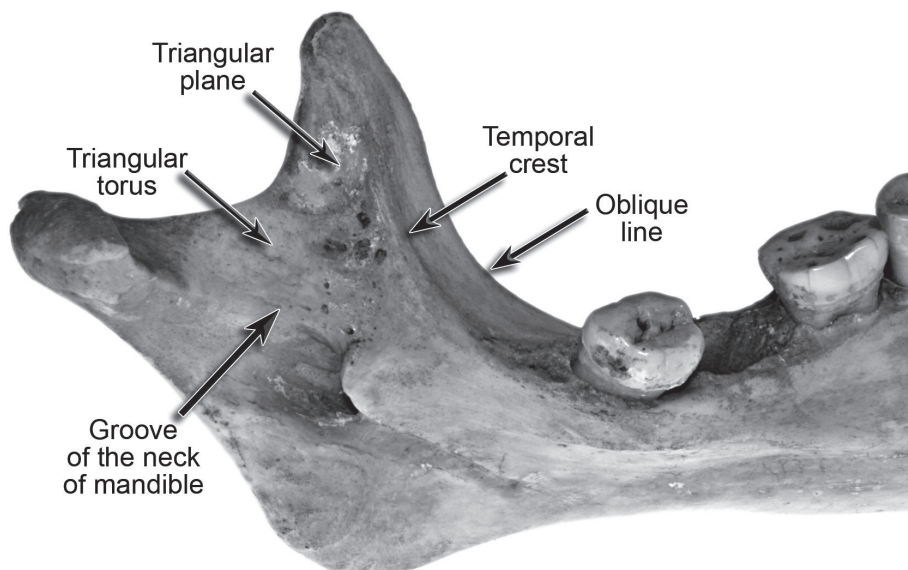


Fig. 1. Mandibular ramus — important topographical landmarks.

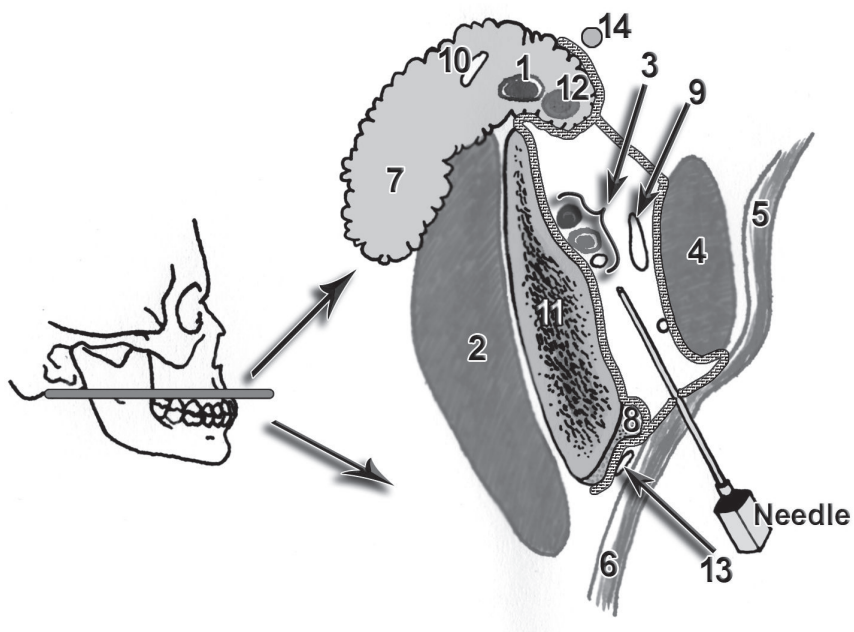


Fig. 2. Course of interpterygoid fascia — needle within pterygomandibular space

1 — retromandibular vein; 2 — masseter muscle; 3 — inferior alveolar nerve, artery and vein; 4 — medial pterygoid muscle; 5 — constrictor pharyngis superior muscle; 6 — buccinator muscle; 7 — parotid gland; 8 — deep portion of temporalis muscle tendon; 9 — sphenomandibular ligament; 10 — facial nerve; 11 — mandibular ramus; 12 — external carotid artery; 13 — buccal nerve; 14 — styloid process of temporal.

The entrance into pterygomandibular space is placed anteriorly, being limited by deep portion of temporalis muscle tendon and medial pterygoid muscle.

The following structures can be located within pterygomandibular space (Fig. 2):

1. neurovascular bundle consisting of: inferior alveolar nerve, artery and vein
2. middle meningeal artery
3. deep temporal arteries
4. numerous, variable muscular branches
5. pterygoid venous plexus
6. communicating vein, which extends between pterygoid venous plexus and the inferior alveolar vein
7. lingual nerve
8. chorda tympani
9. mylohyoid nerve and vessels
10. buccal nerve

Mandibular nerve joins through its course pterygomandibular space and cranial fossa, traversing the foramen ovale. Upper portion of pterygomandibular space is located next to the adipose tissue of the cheek.

REVIEW OF METHODS OF INFERIOR ALVEOLAR NERVE BLOC

Anesthesia of the inferior alveolar nerve can be achieved by:

1. intraoral classical method modo Halsted
2. intraoral method, by Kenneth-Reed
3. intraoral, Gow-Gates.

In classical method proposed by Halsted a fingerbreadth of left index is placed on the anterior border of mandible. The point of injection the needle is placed 1cm above the plane of the lower teeth, between the pterygomandibular fold and the inner aspect of the cheek within the apex of the retromolar triangle. The needle should be inserted parallel to the alveolar arch to the depth of 0.5 cm, where it achieves lingual nerve. Next the syringe is moved toward opposite side so its cylinder is placed in the mouth angle. The needle is inserted deeper until one can feel the bony resistance (mandibular ramus). The cut end of the needle should be directed towards the bone, what enables administration of the anesthetic to the groove of the mandibular neck. All these procedures must be followed by aspiration in at least to planes to avoid intravascular administration of the anesthetic. Next from the second injection the buccal nerve should be anesthetized [16–18].

In Kenneth-Reed technique the needle is inserted about 20 mm (not like in Halsted method — about 10 mm) above the plane of lower teeth with mouth widely opened. The place of injection is proposed to be at the crossing of two lines: first, parallel to the plane of the lower teeth and second which extends between coronoid notch and pterygomandibular raphe, in anterior 2/3 of this line [19, 20].

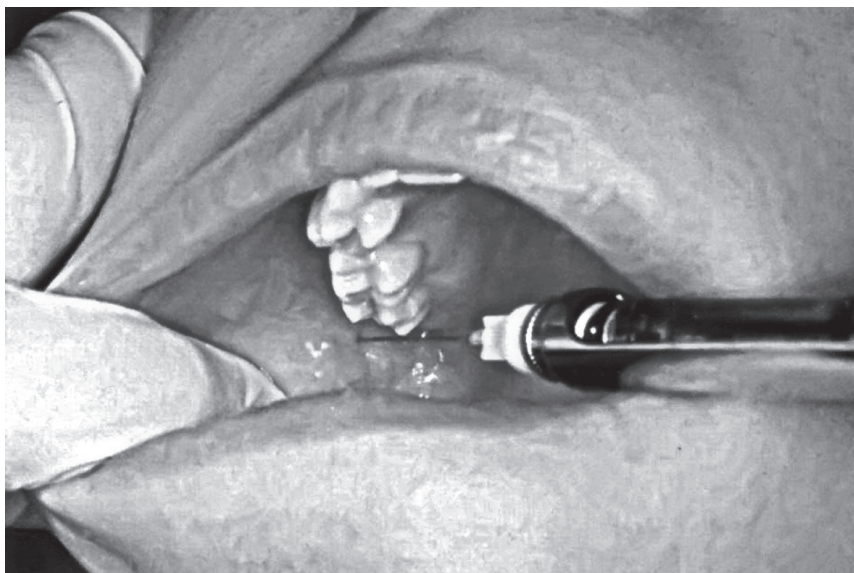

Fig. 3. Trace of a needle while anesthetizing with Gow-Gates method.

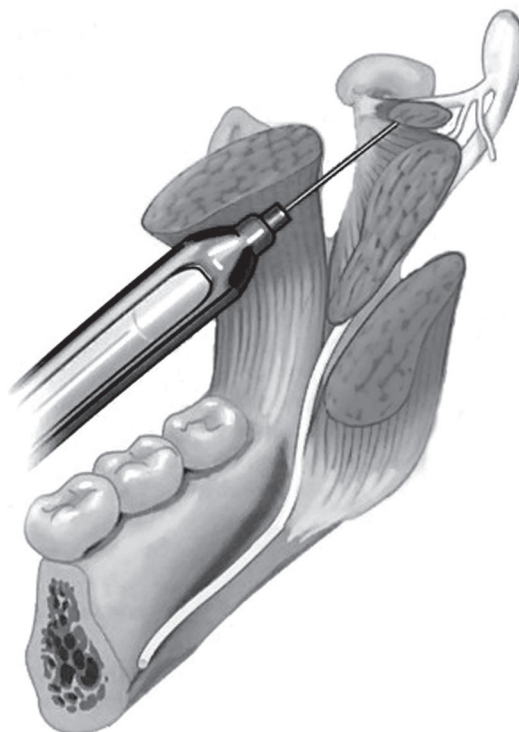


Fig. 4. Insertion of a needle following Gow-Gates method.

Gow-Gates method was proposed in 1973 by Australian dentist who defined the alternative method of anesthetizing all three nerves (inferior alveolar, lingual and buccal) using single injection [21]. George Gow-Gates distinguished two important topographical points: tragus and mouth angle. The needle should be inserted going from the contralateral mouth angle toward the cheek at the mesial palatine tubercle of the second upper molar tooth. The needle should go upwards, externally and posteriorly, reaching the medial surface of the condylar process, where these three mentioned above nerves runs relatively near each to other. Positive aspiration in Gow-Gates method varies, however it never exceed above 2%. Successful anesthesia can be achieved in 95-98%, comparing to to 75–85% obtained by the classical method (Fig. 3–4).

Anesthesia of inferior alveolar nerve in everyday dental practice can be achieved by the help of various modern methods using also computer tools: The Wand, Injex, Periodontal Ligament Injection, and alternative methods, i.e. Vazirani-Akinosi Closed Mouth Mandibular Block [18, 19, 21]. These techniques apply both intra- and extraoral landmarks. Thus detailed anatomical knowledge of the mandibular structure, its variations and topography of the pterygomandibular space may influence defining the right position of the mandibular foramen. Certainly selection of the method should be followed by careful examination of the temporomandibular joint to estimate the wideness of mouth opening in patient. Because of high variability of location of the mandibular foramen and common problems with achieving the full anesthesia using the classical Halsted method, authors postulate application of alternative methods of anesthesia, i.e. Gow-Gates bloc.

REFERENCES

1. Aggarwal V., Singla M., Kabi D. Comparative evaluation of anesthetic efficacy of Gow-Gates mandibular conduction anesthesia, Vazirani-Akinosi technique, buccal-plus-lingual infiltrations, and conventional inferior alveolar nerve anesthesia in patients with irreversible pulpitis. *Oral Surg Oral Med Oral Pathol Oral Radiol Endod.* 2010 Feb; 109 (2): 303–308. —
2. Barker B.C., Davies P.L.: The applied anatomy of the pterygomandibular space. *Br J Oral Surg.* 1972 Jul; 10 (1): 43–55. —
3. Boonsirisetth K., Sirintawat N., Arunakul K., Wongsirichat N.: Comparative study of the novel and conventional injection approach for inferior alveolar nerve block. *Int J Oral Maxillofac Surg.* 2013 Jul; 42 (7): 852–856. —
4. Burdan F., Szumilo J., Walocha J., Klepacz L., Madej B., Dworzański W., Klepacz R., Dworzańska A., Czekańska-Chehab E., Drop A.: Morphology of the foramen magnum in young Eastern European adults. *Folia Morphol (Warsz).* 2012 Nov; 71 (4): 205–216. —
5. Burdan F., Umlawska W., Dworzański W., Klepacz R., Szumilo J., Starostawska E., Drop A.: Anatomical variances and dimensions of the superior orbital fissure and foramen ovale in adults. *Folia Morphol (Warsz).* 2011 Nov; 70 (4): 263–271. —
6. Cruz E.V., Quengua J.B., Gutierrez I.L., Abreu M.A., Uy H.G.: A comparative study: classical, Akinosi, and Gow-Gates techniques of mandibular nerve block. *J Philipp Dent Assoc.* 1994; 46 (1): 13–19. —
7. Goldberg S., Reader A., Drum M., Nusstein J., Beck M.: Comparison of the anesthetic efficacy of the conventional inferior alveolar, Gow-Gates, and Vazirani-Akinosi techniques. *J Endod.* 2008 Nov; 34 (11): 1306–1311. —
8. Gow-Gates G.A.: The Gow-Gates mandibular block: regional anatomy and analgesia. *Aust Endod J.* 1998. —
9. Haas D.A.: Alternative mandibular nerve block techniques: a review of the Gow-Ga-

tes and Akinosi-Vazirani closed-mouth mandibular nerve block techniques. *J Am Dent Assoc.* 2011 Sep; 142 Suppl 3: 8S–12S. — **10.** Kang S.H., Byun I.Y., Kim J.H., Park H.K., Kim M.K.: Three-dimensional anatomic analysis of mandibular foramen with mandibular anatomic landmarks for inferior alveolar nerve block anesthesia. *Oral Surg Oral Med Oral Pathol Oral Radiol.* 2013 Jun; 115 (6): e17–23.

11. Khoury J.N., Mihailidis S., Ghabriel M., Townsend G.: Applied anatomy of the pterygomandibular space: improving the success of inferior alveolar nerve blocks. *Aust Dent J.* 2011 Jun; 56 (2): 112–121. — **12.** Khoury J., Mihailidis S., Ghabriel M., Townsend G.: Anatomical relationships within the human pterygomandibular space: Relevance to local anesthesia. *Clin Anat.* 2010 Nov; 23 (8): 936–944. — **13.** Madrid C., Reynes P.: The fasciae of the pterygomandibular space. *Acta Anat (Basel).* 1989; 136 (1): 55–60. — **14.** Okamoto Y., Takasugi Y., Moriya K., Furuya H.: Inferior alveolar nerve block by injection into the pterygomandibular space anterior to the mandibular foramen: radiographic study of local anesthetic spread in the pterygomandibular space. *Anesth Prog.* 2000 Winter; 47 (4): 130–133. — **15.** Shaw M.D., Fierst P.: Clinical prosection for dental gross anatomy: a medial approach to the pterygomandibular space. *Anat Rec.* 1988 Nov; 222 (3): 305–308. — **16.** Skrzat J., Walocha J., Środek R., Nizankowska A.: An atypical position of the foramen ovale. *Folia Morphol (Warsz).* 2006 Nov; 65 (4): 396–399. — **17.** Skrzat J., Walocha J., Środek R.: An anatomical study of the pterygoalar bar and the pterygoalar foramen. *Folia Morphol (Warsz).* 2005 May; 64 (2): 92–96. — **18.** Skrzat J., Walocha J., Zawilński J.: Accessory spine of the foramen ovale. *Folia Morphol (Warsz).* 2012 Nov; 71 (4): 263–266. — **19.** Thangavelu K., Kannan R., Kumar N.S., Rethish E., Sabitha S., Sayeeganes N.: Significance of localization of mandibular foramen in an inferior alveolar nerve block. *J Nat Sci Biol Med.* 2012 Jul; 3 (2): 156–160. — **20.** Watson J.E.: The Gow-Gates mandibular block: applied anatomy and geometry. *Aust Endod J.* 1998 Apr; 24 (1): 20–23.

21. Zanette G., Manani G., Facco E., Mariuzzi M.L., Tregnaghi A., Robb N.D.: Comparison between two regional anaesthesia techniques performed by inexperienced operators: the Gow-Gates block versus the Kenneth Reed block. *SAAD Dig.* 2011 Jan; 27: 8–15.

¹ Department of Anatomy

Jagiellonian University Medical College, Kraków, Poland

² Department of Periodontology and Oral Medicine,
Institute of Dentistry

Jagiellonian University Medical College, Kraków, Poland

³ Department of Orthodontics, Institute of Dentistry
Jagiellonian University Medical College, Kraków, Poland

⁴ Department of Dental Surgery, Institute of Dentistry
Jagiellonian University Medical College, Kraków, Poland

Corresponding author:

Marcin Lipski, MD, PhD

Department of Anatomy

Jagiellonian University Medical College
ul. Kopernika 12, 31-034 Kraków, Poland

Tel./Fax: +48 12 422 95 11

E-mail: m.lipski@uj.edu.pl

