



University of
Zurich^{UZH}

Zurich Open Repository and
Archive

University of Zurich
Main Library
Strickhofstrasse 39
CH-8057 Zurich
www.zora.uzh.ch

Year: 2019

Wildlife-transmitted *Taenia* and *Versteria* cysticercosis and coenurosis in humans and other primates

Deplazes, Peter ; Eichenberger, Ramon M ; Grimm, Felix

Abstract: Wild mustelids and canids are definitive hosts of *Taenia* and *Versteria* spp. while rodents act as natural intermediate hosts. Rarely, larval stages of these parasites can cause serious zoonoses. In Europe, four cases of *Taenia martis* cysticercosis have been diagnosed in immunocompetent women, and two cases in zoo primates since 2013. In North America, a zoonotic genotype related but distinct from *Versteria mustelae* has been identified in 2014, which had caused a fatal infection in an orangutan and liver- and disseminated cysticercoses in two severely immune deficient human patients in 2018, respectively. Additionally, we could attribute a historic human case from the USA to this *Versteria* sp. by reanalysing a published nucleotide sequence. In the last decades, sporadic zoonotic infections by cysticerci of the canid tapeworm *Taenia crassiceps* have been described (4 in North America, 8 in Europe). Besides, 3 ocular cases from North America and one neural infection from Europe, all in immunocompetent patients, 6 cutaneous infections were described in severely immunocompromised European patients. Correspondingly, besides oral infections with taeniid eggs, accidental subcutaneous oncosphere establishment after egg-contamination of open wounds was suggested, especially in cases with a history of cutaneous injuries at the infection site. *Taenia multiceps* is mainly transmitted in a domestic cycle. Only five human coenurosis cases are published since 2000. In contrast, *T. serialis* coenurosis (1 human case since 2000) is primarily transmitted by wild canids. The etiological diagnosis of exotic cysticercoses is challenging. Usually, clinical material does not allow for a morphological identification, and serological tests are not available. These limitations have partly been overcome by molecular tools. Without claiming any dramatic emergence of cysticercoses and coenuroses transmitted by wild carnivores, further sporadic cases of such 'exotic' infections have to be expected.

DOI: <https://doi.org/10.1016/j.ijppaw.2019.03.013>

Posted at the Zurich Open Repository and Archive, University of Zurich

ZORA URL: <https://doi.org/10.5167/uzh-179589>

Journal Article

Published Version




The following work is licensed under a Creative Commons: Attribution-NonCommercial-NoDerivatives 4.0 International (CC BY-NC-ND 4.0) License.

Originally published at:

Deplazes, Peter; Eichenberger, Ramon M; Grimm, Felix (2019). Wildlife-transmitted *Taenia* and *Versteria* cysticercosis and coenurosis in humans and other primates. *International Journal for Parasitology*:

Parasites and Wildlife, 9:342-358.
DOI: <https://doi.org/10.1016/j.ijppaw.2019.03.013>



Wildlife-transmitted *Taenia* and *Versteria* cysticercosis and coenurosis in humans and other primates



Peter Deplazes*, Ramon M. Eichenberger, Felix Grimm

Institute of Parasitology, University of Zürich, 8057, Zürich, Switzerland

ARTICLE INFO

Keywords:

Taenia crassiceps
Taenia martis
Taenia serialis
Versteria sp.
 Mustelids
 Wild canids

ABSTRACT

Wild mustelids and canids are definitive hosts of *Taenia* and *Versteria* spp. while rodents act as natural intermediate hosts. Rarely, larval stages of these parasites can cause serious zoonoses. In Europe, four cases of *Taenia martis* cysticercosis have been diagnosed in immunocompetent women, and two cases in zoo primates since 2013. In North America, a zoonotic genotype related but distinct from *Versteria mustelae* has been identified in 2014, which had caused a fatal infection in an orangutan and liver- and disseminated cysticercoses in two severely immune deficient human patients in 2018, respectively. Additionally, we could attribute a historic human case from the USA to this *Versteria* sp. by reanalysing a published nucleotide sequence. In the last decades, sporadic zoonotic infections by cysticerci of the canid tapeworm *Taenia crassiceps* have been described (4 in North America, 8 in Europe). Besides, 3 ocular cases from North America and one neural infection from Europe, all in immunocompetent patients, 6 cutaneous infections were described in severely immunocompromised European patients. Correspondingly, besides oral infections with taeniid eggs, accidental subcutaneous oncosphere establishment after egg-contamination of open wounds was suggested, especially in cases with a history of cutaneous injuries at the infection site. *Taenia multiceps* is mainly transmitted in a domestic cycle. Only five human coenurosis cases are published since 2000. In contrast, *T. serialis* coenurosis (1 human case since 2000) is primarily transmitted by wild canids. The etiological diagnosis of exotic cysticercoses is challenging. Usually, clinical material does not allow for a morphological identification, and serological tests are not available. These limitations have partly been overcome by molecular tools. Without claiming any dramatic emergence of cysticercoses and coenuroses transmitted by wild carnivores, further sporadic cases of such 'exotic' infections have to be expected.

1. Introduction

Wildlife is confronted worldwide with expanding urban and agricultural areas and increasing human leisure activities. This development has strong effects on the biodiversity of ecosystems and poses a threat to many species. However, several carnivores and other species may take advantage of urban resources and new habitats, and they are increasing their populations. Furthermore, the stone marten (*Martes foina*) is known to be adapted to urbanised habitats for centuries (Wereszczuk et al., 2017). More recently, carnivore species thriving in anthropogenic habitats include the red fox (*Vulpes vulpes*) (Chautan et al., 2000), coyotes (*Canis latrans*, in Canadian cities) (Liccioli et al., 2015), raccoons (*Procyon lotor*, in North America and Central Europe) (Mackenstedt et al., 2015) and European badgers (*Meles meles*, in Europe) (Geiger et al., 2018). Consequently, urbanization influences the transmission of parasites with complex life cycles, which often involve

intermediate and definitive host species with very different ecologies (Liccioli et al., 2015; Lafferty, 1999). For example, a distinct increase of human alveolar echinococcosis has been observed in Central Europe, approximately ten years after the establishment of stable urban fox populations (Schweiger et al., 2007). And more recently, a clear increase of angiostrongylosis in dogs has been observed in parallel with a strong increase of the prevalence of this parasite in foxes living in the Swiss Plateau (Gillis-Germitsch and Schnyder, 2018). Furthermore, increasing recreational and sports activities of the urban population, together with their dogs, in agricultural and wildlife areas have increased the transmission risks of parasites between wild and domestic carnivores. This is supported by the observations of many veterinarians reporting increasing numbers of *Sarcoptes* infestations in dogs after *Sarcoptes mange* had become more prevalent in foxes in Eastern Switzerland (Deplazes P., unpublished). Trends in the transmission of parasites between wild and domestic carnivores have been reviewed for

* Corresponding author. Institute of Parasitology, University of Zurich, Winterthurerstr. 266a, 8057 Zurich, Switzerland.
 E-mail address: deplazesp@access.uzh.ch (P. Deplazes).

Table 1*Taenia* and *Versteria* spp. of domestic and wild carnivores with zoonotic potential. Biological characteristics (modified after Deplazes et al., 2016).

Taenia species	Distribution	Definitive host (rare hosts in parentheses)	Natural intermediate host, common name of larval stage, predilection sites, dead-end hosts
<i>Taenia crassiceps</i> (Zeder 1800)	Northern hemisphere	Fox, wolf, jackal, raccoon dog (dog, cat, wild cat, mustelids)	Rodents, (moles); <i>Cysticercus longicollis</i> ; subcutaneous tissue, body cavities. Variety of mammal dead-end hosts, 12 cases described in humans (Table 2).
<i>Taenia martis</i> (Zeder, 1803), <i>T. martis americana</i>	Northern hemisphere	Mustelids: <i>Martes</i> , <i>Mustela</i> , <i>Meles</i> , <i>Gulo</i> , <i>Lutra</i> , (fox)	Rodents (voles, murids, red squirrel) <i>cysticercus</i> ; body cavities, rarely CNS. Rarely primates as dead-end hosts, recently 4 first cases in humans.
<i>Taenia taeniaeformis</i> (Batsch 1786)	Worldwide	Cat, lynx, other felids, (mustelids, fox)	Rodents: <i>Strobilocercus fasciolaris</i> ; liver. Rarely in other hosts including a single human case.
<i>Taenia multiceps</i> (Leske, 1780)	Worldwide	Dog, red fox, wolf, (hyena, jackal, coyote)	Sheep, goat, cattle, buffalo, yak, other domestic and wild ruminants; <i>Coenurus cerebralis</i> ; CNS, connective tissue. 5 case-reports in humans in the last 25 years. Rarely in other primates.
<i>Taenia serialis</i> (Gervais, 1847)	Worldwide	Fox, wolf, hyena, coyote, jackal, (dog, cat)	Hare, rabbit, (rodents); <i>Coenurus serialis</i> ; subcutaneous and intermuscular tissue. Two case-reports in humans in the last 25 years. Several cases in primates (including abdominal infection).
'African-type' coenurosis (<i>Taenia brauni</i> , <i>Taenia glomeratus</i>)	Africa	Dog, fox, jackal, genet	Rodents (swamp rat, porcupine, gerbil), <i>Coenurus brauni</i> / <i>Coenurus glomeratus</i> ; no recent report of zoonotic infections, but few historic cases (Supplemental Table 1).
<i>Versteria mustelae</i> (Gmelin, 1790) (Syn. <i>Taenia mustelae</i>)	Northern hemisphere	Mustelids	Rodents, <i>cysticercus</i> , liver. No primate cases caused by <i>V. mustelae</i> in Europe and Asia
<i>Versteria</i> sp. ^a (<i>V. mustelae</i> zoonotic genotype)	Northern America	Mustelids: ermine, mink	Rodents (<i>cysticercus</i>), liver. 3 cases of cysticercosis in immunosuppressed human patients, one case in an orangutang (Table 3).

^a So far not fully described zoonotic genotype of *V. mustelae* or new *Versteria* species.

protozoa and tick-borne agents (Otranto et al., 2015a), as well as for helminths and arthropods (Otranto et al., 2015b).

The causative agents of human alveolar (AE) and cystic echinococcosis (CE) are *Echinococcus multilocularis* and *E. granulosus* sensu lato (s.l.), respectively (Kern et al., 2017), while *Taenia solium* is the etiological agent for cysticercosis (Flisser et al., 2011). Zoonotic transmissions of CE and *T. solium* cysticercosis mainly involve domestic animals: pigs as the intermediate hosts for *T. solium* (Flisser et al., 2011), and dogs as the definitive hosts of *E. granulosus* s.l. (Romig et al., 2017). In contrast, zoonotic transmission of AE is mainly attributed to increased contact zones of the wild definitive hosts (red foxes, coyotes and raccoon dogs) and humans (Romig et al., 2017). Carnivore transmitted taeniid infections other than echinococcosis and *T. solium* cysticercosis (Table 1) have been sporadically described in immunocompetent (*T. martis* or *T. crassiceps* cysticercosis and *T. multiceps*, *T. serialis*, *T. brauni* and *T. glomeratus* coenuroses) and typically in severely immunocompromised human patients (*T. crassiceps* and *Versteria* sp. cysticercoses) (Tables 2–4), as well as in other primates.

Primates are dead-end intermediate hosts for canid-transmitted taeniid species but seem to be susceptible to some degree to the development of metacestodes (larval stages) after accidental infection with eggs. The epidemiology of these rare zoonoses is not well understood. Their apparently low incidences in humans might be attributed to a very low infection pressure or to a relatively high resistance of humans against these parasites. For example, most cases of subcutaneous *T. crassiceps* cysticercosis as well as all cases of fatal *Versteria* sp. infections have been described in severely immunodeficient patients (Table 2). Interestingly, humans have been considered highly resistant against AE, which would explain the relatively low incidences in areas with high environmental contamination with *E. multilocularis* eggs (Gottstein et al., 2015). However, in patients with impaired immunological status due to AIDS (Sailer et al., 1997), cancer and drug-based immunosuppression (Chauchet et al., 2014), severe progression of AE may occur (Vuitton et al., 2015).

Based on a relatively high number of cases in relation to the small population sizes, non-human primates in zoos seem to be highly susceptible for metacestode infections. Therefore, these primates might be considered as sentinels for the zoonotic potential of cestode parasite species. Indeed, mesocostoides infections have been detected in dead-end hosts such as zoo primates (Hubbard et al., 1993; Tokiwa et al., 2014; Montalbano Di Filippo et al., 2018) and in humans (Fuentes et al., 2004). However, how humans and primates get infected is not

clear, and the taxonomy of *Mesocostoides* spp. from domestic and wild carnivores is under investigation (Varcasia et al., 2015a). Furthermore, *E. equinus* (G4), initially not considered to be zoonotic, was long known to be highly prevalent in horses as intermediate and in foxhounds as definitive hosts in Great Britain. In 2012, CE caused by *E. equinus* was identified in lemurs (*Varecia rubra*, *V. variegatarubra*) living in a British zoo (Boufana et al., 2012; Denk et al., 2016) and in 2018, the first human CE case caused by *E. equinus* has been discovered in Uzbekistan (Timbur et al., 2018). Other examples of *T. crassiceps*, *T. martis*, and *Versteria* sp., *T. multiceps* and *T. serialis* infections in humans and other primates will be documented in more detail in this review (Tables 2–4 and supplemental material).

Genetic analyses of specified gene sequences allow for a reliable species differentiation, even if only small amounts of parasite tissue are available. The detection of *T. martis* and *Versteria* sp. cysticercosis in humans and other primates can especially be attributed to the new molecular diagnostic strategies, and probably does not represent an emergence of these zoonoses.

Furthermore, the zoonotic potential of several other *Taenia* spp. (e.g. *T. ovis*, *T. hydatigena* or *T. taeniaeformis*) has been claimed in textbooks based on few observations. However, for *T. hydatigena*, two well documented cases of *Cysticercus tenuicollis* abdominal cysticercosis with large cysts have been described in non-human primates (Table 4). As an example, intestinal *T. taeniaeformis* infections are mostly found in felids, rarely also in red foxes (Table 1). Historically, a human intestinal infection with a *Taenia* sp. named *T. infantis* has been reported in a 5-year-old boy from Buenos Aires by Bacigalupo (1922). However, Joyeux and Baer (1929) later showed that *T. infantis* was a synonym of *T. taeniaeformis*. Furthermore, the infections of a 55 years old woman and several children from Japan were attributed to *T. taeniaeformis* (cited in Sterba and Barus, 1976). The intermediate host stage of *T. taeniaeformis*, *Strobilocercus fasciolaris*, infects a large range of rodents and rabbits (Table 1), but there is at least one well documented record of *T. taeniaeformis* metacestode infection of the liver in a 77-year-old man diagnosed at post-mortem examination in 1974 (Sterba and Barus, 1976). Interestingly, Sterba and Barus (1976) mentioned a *Strobilocercus* infection in a gibbon (*Hylobates leuciscus*). However, considering the worldwide distribution of *T. taeniaeformis*, we can conclude that this species has a neglectable zoonotic potential and should not be listed as a zoonotic agent.

Similarly, coenuroses caused by *T. multiceps*, *T. serialis*, *T. brauni*, and *T. glomeratus* have been described as serious zoonoses for decades

Table 2
Cases of *Taenia crassiceps* cysticercosis in humans.

Case no.; references	Patient, immune status and case history	Pathological findings	Etiological diagnosis: morphology and DNA analysis (PCR ^a , sequencing)
Case 1 Shea et al. (1973); Freeman et al. (1973)	17-year-old immunocompetent Canadian woman, with decreased visual acuity of her right eye since two months. Four months earlier she suffered from a severe generalized erythematous skin condition. A family dog infected most probably with <i>T. crassiceps</i> (based on proglottid morphology) lived in intimate association with the patient.	A large motile cyst with a scolex and several smaller cystic lesions were observed at the posterior pole of her right eye. With a putative diagnosis of a <i>T. crassiceps</i> cysticercosis, cysts were removed by surgical intervention.	Morphology. Based on clinical material and from the established isolate in mice, <i>T. crassiceps</i> cysticerci were identified by rostellar hook morphology and numbers as well as by the budding proliferation of the cysticerci. DNA analysis. Nd.
Case 2 Klinker et al. (1992)	33-year-old German male, AIDS patient with a <i>Pneumocystis carinii</i> pneumonia and cerebral toxoplasmosis presented a growing paravertebral haematoma. The patient reported a fall around 4 weeks before the first symptoms appeared.	Subcutaneous, paravertebral infiltrate resembling a haematoma which spread over several weeks to cover almost the entire back. A spontaneous rupture of the infiltrate released “whitish spherical masses, 2–3 mm in diameter”.	Morphology. <i>T. crassiceps</i> diagnosis was confirmed by the number of hooks and the typical budding of the cysticerci. DNA analysis. Nd.
Case 3 Chermette et al. (1995)	33-year-old Frenchman, AIDS patient (stage IV). Suffered around 2 months earlier of a haematoma of the left arm after a fall.	Subcutaneous and muscular tissues invasion of the left arm with extension to the pectoral region. A surgical intervention revealed multiple larval forms.	Morphology. Ovoid (4 mm × 2 mm), transparent vesicles of different developmental stages, some containing one scolex with 4 suckers and 2 rows of rostellar hooks, some with external buds at the opposite site of the scolex. DNA analysis. Nd.
Case 4 Chuck et al. (1997)	38-year-old USA woman, (immune status not mentioned) with blurred vision in the right eye that had persisted for 4 weeks. The patient played with a 6-month-old German shepherd shortly before the dog passed a tapeworm.	Dilated fundus examination revealed a large, elevated, clear, fluid filled subretinal mass with several oval cystic structures of varying sizes.	Morphology. One of the cysts contained a mature scolex with characteristic hooks. Budding on the distal part of the cysticerci was indicative for <i>T. crassiceps</i> . DNA analysis. Nd.
Case 5 Francois et al. (1998)	38-year-old Frenchman with severe AIDS. He denied using intravenous drugs. Two months before admission he noticed a rapid progressive swelling in the right arm and forearm. The patient was in close contact with dogs and frequently walked in the forests of Normandy and Jura.	MRI showed a mass, suggesting a soft tissue neoplasm with numerous, heterogeneous, invasive cystlike lesions. Surgery revealed lesions “containing a yellowish viscous fluid, hundreds of granules, and cysticerci like small vesicles”.	Morphology. invaginated scolex with two rows of small and large rostellar hooks, endogenous budding of the cysticerci. DNA analysis. Nd.
Case 6 Maillard et al. (1998)	34-year-old Frenchman, AIDS patient (C3) clinical disease, developed a traumatic haematoma on the left arm after a fall in the countryside. One month later, the swelling spread to the left pectoral region.	US and MRI showed a dissociation of muscular fibres. An incision on the left arm produced “a fluid that contained many transparent, spherical masses, 1–3 mm in diameter”.	Morphology. Microscopic examination revealed parasites compatible with larvae of <i>T. crassiceps</i> with single or multiple external buds at the opposite side of the scolex. DNA analysis. Nd.
Case 7 Heldwein et al. (2006)	82-year-old German woman, with a history of colon cancer with hemicolectomy and a B cell non-Hodgkin's lymphoma treated with fludarabine phosphate and cyclophosphamide two months before admission. She had also undergone radiotherapy of retrocardiac and iliac lymph nodes. Progressive pain and swelling in the left forearm and back of the left hand had started six weeks earlier after a fall on the hand with soft tissue injury.	US and MRI of the limb showed massive oedema of subcutaneous tissue and in between muscles and tendons and multiple cystic lesions were demonstrated. At fasciotomy jelly-like tissue containing multiple spherical masses with diameters of up to 2 mm, “similar to fish spawn”, was removed from the subcutis, muscles, and tendons.	Morphology. Cysticerci with an ellipsoid cystic body, a long and retractable neck, and a single scolex with four suckers and two rows of hooklets. Additionally, buds at the posterior end of the larvae were observed. DNA analysis. Nd.
Case 8 Goesseringer et al. (2011); Flammer Anikpeh et al. (2014)	47-year-old Swiss woman, severely immunodeficient (HIV-1 RNA viral load of > 4 million copies/mL). Suffered from an injury to her right wrist during her work as a zoo-employee 5 months earlier. Exposed to dogs and foxes.	Swollen and painful right forearm for 2 weeks with clinical presentation and MRI suggestive for a necrotising fasciitis. “Surgical exploration revealed small transparent cystic bodies resembling white caviar”.	Morphology. Small (4–5 mm) transparent cystic bodies with a retractable neck and a single scolex with four suckers and two rows of hooklets as well as budding were indicative for <i>T. crassiceps</i> . DNA analysis. 12S [P6]: “Sequence analysis of a fragment of the small subunit rRNA gene1 permitted species identification” (but this was not substantiated).
Case 9 Schmid et al. (2014)	57-year-old Swiss woman, immunocompetent (serological testing for HIV negative) and other immunological parameters were inconspicuous, presented with swelling and an 8-cm haematoma localized on the right temple. She had no history of a traumatic incident.	Sonography revealed a hypoechoic lesion within the temporal muscle. A small amount of whitish material was aspirated.	Morphology. Smears revealed a putative tapeworm larva and accumulation of eosinophilic granulocytes (Papanicolaou stains). DNA analysis. 12S [P6] sequence analysis tentatively identified the parasite as <i>T. crassiceps nad1</i> [P3]: Identity 421/421 bp or 100% with <i>T. crassiceps nad1</i> , (GenBank AF216699).

(continued on next page)

Table 2 (continued)

Case no.; references	Patient, immune status and case history	Pathological findings	Etiological diagnosis: morphology and DNA analysis (PCR ^a , sequencing)
Case 10 Ntoukas et al. (2013)	51-year-old immunocompetent German (Regensburg, southern Germany) woman, was hospitalized with progressive headache, nausea, vomiting and cerebellar ataxia but no further neurologic deficits. She had been living with her dog (not regularly dewormed, with free access to garden and forest) in a rural area for many years.	Craniotomy revealed subdural and intracerebellar jelly-like tumorous tissue ($\approx 30 \times 30$ mm). The tumor consisted of multiple spherical masses with diameters of 2–4 mm, which was resected.	Morphology. Gross morphology and histology revealed typical structures of cestode larvae. DNA analysis. <i>12s</i> [P5]: Identity 99% with <i>T. crassiceps</i> and <i>cox1</i> [P1]: identity 450/450 bp or 100%, with <i>T. crassiceps</i> .
Case 11 (Ronald Neafie, pers. comm.) ^b	US Patient (Oregon) without immunosuppression	Site of infection: Eye (subretinal)	No details given
Case 12 (Ronald Neafie, pers. comm.) ^b	US Patient (Maine) without immunosuppression	Site of infection: Subcutis, shoulder	No details given

^a Primer pairs [P] used are given in squared brackets and refer to Table 6.

^b Cited in Ntoukas et al. (2013).

(Supplemental Table 1). For *T. multiceps*, the parasite lifecycle is mainly maintained in a domestic cycle including dogs and farm ruminants (Abera et al., 2016). Nevertheless, wild carnivores such as foxes and wolves have been demonstrated to be responsible for the dissemination of tapeworm eggs (Varcasia et al., 2015b; Otranto et al., 2015b). In contrast, for *T. serialis*, the cycle is mainly based on wildlife with wild canids and herbivores (primarily lagomorphs) as natural hosts. In Africa, two more *Taenia* spp. of wildlife origin have been described causing coenurosis with zoonotic potential (*T. brauni* and *T. glomeratus*) (Morel, 1959), to which we refer as ‘African-type coenurosis’ in this review. However, based on their appearance, these species might be variants/strains of *T. serialis* (no molecular data is available). Over the last century, several cases of coenurosis have been described in humans and other primates. Clinically, *T. multiceps* coenurosis in humans caused severe central nervous symptoms and ended fatally in 42% of the collected case reports (Supplemental Table 1). In contrast, coenurosis by *T. serialis* and the ‘African-type’ coenuroses have a tropism to subcutaneous and muscle tissues, and the clinical outcome is favorable. Taking account of the high prevalence of these parasites globally and the low number of cases published, the zoonotic risk of coenuroses has to be considered minimal, irrespective of potential severe consequences.

In this review we focus on non-*T. solium* cysticercoses and on coenuroses that are transmitted through wild carnivores (mustelids, canids, and exceptionally felids), exemplify the habitual infection biology of involved species, refer to their zoonotic potential and discuss “state-of-the-art” diagnostic strategies. The herein reported information was retrieved from full texts by comprehensive database searches (PubMed and Google scholar). Extensive screening of reference lists for historical and missing publications was accomplished.

2. Mustelid-transmitted cysticercoses

2.1. *Taenia martis* cysticercosis

Taenia martis is a large tapeworm of around 20 cm in length that develops in the small intestine of wild carnivores, mainly Mustelidae. In North America, *T. martis americana* has been described in *Martes americanum* (Hoberg et al., 1990). In Europe, it was described in the stone marten (*Martes foina*) and in the pine marten (*M. martes*). However, other mustelids and rarely canids and felids might also act as definitive hosts (Table 1). *Taenia martis* is transmitted in a wild-animal cycle between mustelid carnivores and their prey, including rodents and other small mammals as intermediate hosts. In the intermediate hosts the larval form (cysticercus) reaches a size of 6–32 mm (more details see diagnostic section). It mainly develops in the pleural and

peritoneal cavity as a pseudo segmented larva, not surrounded by a fibrous capsule, and without asexual multiplication (Schuster and Benitz, 1992).

In Europe, *T. martis* has been observed in martens in Italy (Millan et al., 2001), Belgium (Mathy et al., 2009) Poland (Kornaś et al., 2013) and Belarus where it has also been detected in the European polecats (Shimalov, 2010). In Southwestern Germany, *T. martis* was found in 1 (0.03%) of 3573 red foxes, in 2 (2.2%) of 84 badgers (*Meles meles*) and in 17 (37%) of 47 stone martens (Loos-Frank and Zeyhle, 1982). In southwestern Yakutia (Siberia) between 1981 and 1987, *T. martis* was found in 28% of 272 and 30% of 1548 *Martes zibellina*, respectively (Sedalischev and Odnokurtsev, 2011; Odnokurtsev and Sedalischev, 2011).

Taenia martis cysticercosis in rodents seems to occur all over Europe but focally in variable prevalence. As an example in Eastern Switzerland, *T. martis* larval stages (cysticerci) were detected in 43 (10.5%) of 411 *Apodemus flavicollis*, in 100 (7.8%) of 1276 *A. sylvaticus* and in 294 (24.3%) of 1211 *Myodes* (syn. *Clethrionomys glareolus*), but not in 894 *Arvicola terrestris*, 347 *Microtus arvalis* and 250 *M. agrestis* of the same area (Schaefer, 1987). In contrast, in Western Switzerland (Geneva) *T. martis* was found in 2 of 99 *A. flavicollis*, but not in 466 *A. terrestris*, 58 *M. glareolus* and 35 *M. arvalis* (Reperant et al., 2009). Comparable low prevalence of *T. martis* were found in Berlin, Germany (1.4% of 59 *M. glareolus*, 78 *Apodemus agrarius* and 82 *A. flavicollis*) (Krücken et al., 2017), and in Western France in nutria (*Myocastor coypus*) (Umhang et al., 2013). In Germany, muskrats (*Ondatra zibethicus*) were highly infected with *T. martis* cysticerci (Loos-Frank and Zeyhle, 1981), similar to the Limburg region in the Netherlands (18.6% of 526 muskrats), but in contrast to animals from Groningen (n = 1200) with a prevalence of merely 0.7% (Borgsteede et al., 2003). From Ireland, Loxton et al. (2017) reported a prevalence of *T. martis* of 0.77% (CI: 0.16–2.24) in wood mice (*A. sylvaticus*). Reports from northern Spain document the occurrence of *T. martis* in 0.7–1.0% of 376 *M. glareolus* (Ribas et al., 2009). In Serbia 4.1% of 588 *M. glareolus* were infected with *T. martis* (Bjelić-Čabrilo et al., 2011). In Belarus, the red-backed vole, the striped field mouse and the yellow-necked mouse are hosts of this helminth (Shimalov, 2010), and recently it was documented there as a parasite of red squirrels (*Sciurus vulgaris* Linnaeus, 1758) (Shimalov, 2016).

To our knowledge, four cases of human *T. martis* cysticercosis have been reported in immunocompetent women (Table 3). Interestingly, three of these patients originated from Alsace (France) and Western Germany, while the remaining fourth case was described in northern Germany. In these cases, cysticercosis manifested itself as a solitary lesion in the brain, in the peritoneum and in two cases in the eye. Furthermore, two cases in non-human primates, one originating from

Table 3
Cases of *Taenia martis*, *Versteria* sp. (zoonotic genotype) and non-specified cysticercoses in humans.

Taeniid species, cases, citations	Patient, immune status and case history	Pathological findings	Etiological diagnosis: morphology and/or DNA analysis (PCR ^a), sequencing
<i>Taenia martis</i> Case 1, Eberwein et al. (2013)	43-year-old immunocompetent German woman (Freiburg im Breisgau), with mobile subretinal tumor with adjacent intraretinal and subhyaloid bleeding.	The removed cyst (after 8 days of albendazole/dexamethason therapy) showed the characteristic macroscopic and histologic features of a cysticercus bladder wall.	DNA Analysis. <i>cox1</i> [P1], <i>nd1</i> [P4], <i>12S</i> [P8]; all sequences showed highest identity with <i>T. martis</i> (99%–100%).
<i>T. martis</i> Case 2, Brunet et al. (2015)	44-year-old immunocompetent French woman (Alsace), with suspected meningoencephalitis.	Thick-walled parasitic cyst with dense fibrosis and intense mononuclear inflammation contained dense fluid consisting of thick bright eosinophilic ribbons of membranous tissue and calcareous corpuscles.	DNA analysis. <i>cox1</i> [P1], (396/396 bp or 100% with <i>T. martis</i> EU544557), <i>nd1</i> [P3] (488/188 bp or 100% with EU544607) and <i>12S</i> [P6] (263/265 bp or 99.2% with JX415820).
<i>T. martis</i> Case 3, Koch et al. (2016)	70-year-old immunocompetent woman from northern Germany; visual acuity of her left eye dropped significantly.	Intraocular inflammation and vitreous haemorrhage without fundus view in the affected eye. On US, a retinal detachment was disclosed and at surgery a moving larval parasite was extracted from the eye.	Morphology. Macroscopically, the 3 mm long semi-translucent parasite had the appearance of a cestode larva. Tissue sections showed a characteristic tapeworm tegument. DNA analysis. Identities for <i>cox1</i> [P1], <i>nd1</i> [P4], <i>12S</i> [P8] were 100%, 99%, and 99%, respectively with <i>T. martis</i> sequences.
<i>T. martis</i> Case 4, Rudelius et al. (2017)	36-year-old immunocompetent woman (Germany); recurring, asymptomatic ascites, which progressed slightly over a period of 8 weeks	Histopathology assessment revealed a tumor mass with central necrosis and aggregates of epithelioid cells with intermingled multinucleated giant cells of Langhans type in the periphery.	Morphology. A larva could be detected with suckers, a two-layered tegumentum and calcified corpuscles. DNA analysis. <i>12S</i> [P5]: Identity 99% with <i>T. martis</i> (ENA LT837855).
<i>Versteria</i> sp. (zoonotic genotype) Case 1, Connor et al. (1976); Olson et al. (2003)	58-year-old man from Pennsylvania (USA) with Hodgkin disease died after repeated courses of chemotherapy and radiotherapy.	Disseminated cyst like structures throughout the viscera, blood vessels, lymph nodes, and subcutaneous tissues were observed.	Morphology. Not conclusive. DNA analysis. Our recent re-evaluation of the 183-bp sequence of the 18S rRNA gene including the V2 region published by Olson et al. (2003) (GenBank AY193876), showed an identity of 95% (172/180 bp, 3 gaps) with the corresponding sequence of <i>V. mustelae</i> (GenBank AB731633), and the sequence had a 99.7% identity with the amplified sequence of the same gene of patient 2 (GenBank MK641670).
<i>Versteria</i> sp. (zoonotic genotype) Case 2, Barkati et al. (2018)	53-year-old female from rural New Brunswick (Atlantic Canada) with a 3-day history of fever, productive cough, myalgia, malaise, and anorexia. Her past medical history included an obstructive nephropathy necessitating a kidney transplant with immunosuppression with tacrolimus, mycophenolate mofetil, and prednisone.	“The patient presented with severe pulmonary and systemic symptoms”. CT revealed mixed alveolar opacities and “a large heterogeneous central hepatic lesion (19.3 × 15 × 8.7 cm) abutting the middle hepatic and left portal veins, with multiple satellite nodules”.	Morphology. Histopathology revealed cestode larvae with parts of a rostellum and 2 refractile hooklets without species diagnosis. DNA analysis. Needle biopsies of the liver and formalin-fixed paraffin-embedded liver tissue were used for DNA analyses. <i>12S</i> [P6]: Identity 98% with a sequence from a <i>Versteria</i> sp. isolate (GenBank KF303341) from a captive orangutan.
<i>Versteria</i> sp. (zoonotic genotype) Case 3, Lehman et al. (2018)	68-year-old North American woman with hypogammaglobulinemia and previously treated lymphoma presented with fever and abdominal pain.	CT revealed numerous nodules in the lung, eye, brain, and liver. An open liver biopsy revealed “numerous nodular lesions and a mass made up of multifocal coalescing cystic lesions”. Histopathology revealed 3-layered lesions a bladder wall and calcareous corpuscles in a matrix of granulomatous tissue inflammation with areas of necrosis.	Morphology. Suggestive of metacestodes DNA analysis. <i>cox1</i> [primer not specified]: Identity 98% (of 129 bp) with a sequence of <i>Versteria</i> sp. (GenBank KT223034).
<i>Taenia</i> sp. Ocular cysticercosis, Mougeot et al. (1996)	14-year-old (probably immunocompetent) man from Auvergne (Central France), was presented with acute ocular pain, haemorrhage of the conjunctiva and fever. The boy grew up in a rural environment with a pet dog and vegetable garden.	A “parasite” was observed in the internal chamber and surgically resected.	Morphology. A 6 mm long cysticercus was diagnosed by parasitologists, but the morphology did not allow species identification. DNA analysis. Nd.
<i>Taenia</i> sp. Ocular cysticercosis, Arockker-Mettinger et al. (1992)	15-year-old, Austrian, immune-competent woman presented with an iridocyclitis in the right eye. She had close contact to the young family dog.	A living parasite stage could be isolated from the anterior chamber.	Morphology. Contractable parasite stage of 2 mm length without characteristic structures such as a scolex. A putative <i>T. crassiceps</i> diagnosis was based on antibody reactions against <i>T. crassiceps</i> larval antigens in Western blots ^b DNA analysis. Nd.

Nd: Not done or no data given.

^a Primer pairs used are given in squared brackets and refer to Table 6.

^b Analysis could not consider *T. martis* and other rare cysticercoses.

Alsace, the other from a zoo in Rome (Italy), presented as abdominal *T. martis*-cysticercosis (Table 4). Finally, in a 14-year-old Frenchman and a 15-year-old Austrian woman, ocular cysticercoses caused by juvenile taeniid larvae could not be morphologically specified (Table 3). Similarly, a cysticercosis with fully developed cysticerci isolated from the

abdomen of a lemur from a zoo in the USA in 1989 was diagnosed as *Taenia* sp. cysticercosis (Table 4).

Routes of human infections can only be speculated about. Two patients were recreational gardeners and could have been exposed to marten faeces during such activities. Extensive recreational hiking in

Table 4
Taenia spp. and *Vesrteria* sp. cysticercoses and *Taenia* spp. coenuroses in non-human primates.

Taenia sp., case no., citation	Primate species, patient, origin, and case history	Pathological findings	Etiological diagnosis: morphology and DNA analysis (PCR, sequencing) ^a
<i>Taenia crassiceps</i> Case 1, Baer and Scheidegger (1946)	Hamadryas baboon (<i>Papio hamadryas</i>) “no individual data available”, lived in a group in the Zoo Basel, Switzerland, together with a couple of foxes. The animal was necropsied after a history of tetraplegia.	Necropsy. Larval stages subcutaneously and in the smooth muscles, penetrating to the retroperitoneal cavity, with parasite infiltration into the spinal cord.	Morphology. Diagnosis based on number (n = 30–35) and size (large 182–200, small 138 < 150 μm) of rostellar hooks and budding of the cysticerci. DNA analysis. Nd.
<i>T. crassiceps</i> Case 2, Dyer and Greve (1998)	Adult female black lemur (<i>Eulemur macaco macaco</i>) with a clinical history of lethargy, anorexia, and depression of a week's duration was submitted for necropsy. The animal was housed outdoors in a group.	Necropsy. Fluctuant swelling measuring 10 cm by 6 cm on the left back. A well-defined cystic structure contained hundreds of ellipsoidal to spherical cysts of 1–4 mm in diameter. Infiltration of both the peritoneal and pleural cavities by large numbers of cysticerci were found replacing approximately 90% of the left lung.	Morphology. Cysticerci with calcareous corpuscles, a scolex with a rostellum with hooks, spinous tegument, and exogenous budding. DNA analysis. Nd.
<i>T. crassiceps</i> Case 3, Young et al. (2000)	6-year-old female red ruffed lemur (<i>Varecia variegata rubra</i>) with 2 days history of lethargy and anorexia was presented with a large, fluctuant subcutaneous swelling extending from the dorsal aspect of the skull to the ventral cervical region.	Radiographs of the cervical region showed the mass containing discrete areas of mineralization. Surgical exploration “revealed a multiloculated mass with each individual cyst-like structure containing hundreds of bead-like nodules (< 1 mm)”. US image of the swelling suggested a septated subcutaneous mass. Exploratory surgery revealed an irregular fibrous cystic structure, containing numerous small transparent vesicles (ca. 3 mm in diameter) and after the peritoneal cavity was opened more vesicles were extirpated.	Morphology. A wet-prep of the nodules revealed cestode larvae. Histopathology. A single mass was described as granulomatous cellulitis with intralesional larval cestodes. DNA analysis. Nd.
<i>T. crassiceps</i> Case 4, Luzón et al. (2010)	5-year-old male, ring-tailed lemur (<i>Lemur catta</i>) in the Madrid Zoo-Aquarium, Spain, presented a large swelling in its abdomen (15 cm in length × 10 cm in width × 4 cm in height) and was anesthetized for a complete medical evaluation.	US image of the swelling suggested a septated subcutaneous mass. Exploratory surgery revealed an irregular fibrous cystic structure, containing numerous small transparent vesicles (ca. 3 mm in diameter) and after the peritoneal cavity was opened more vesicles were extirpated.	Morphology. Based on the scolex and hooks and budding was observed. DNA analysis. <i>cox1</i> [P1] and <i>nd1</i> [P3]: Identities 99–100% with corresponding published <i>T. crassiceps</i> sequences.
<i>T. crassiceps</i> Case 5, Alić et al. (2017)	15-year-old female ring-tailed lemur (<i>L. catta</i>) from Sarajevo Zoo, Bosnia and Herzegovina was presented after sudden death	Necropsy. “large multicystic structure, subdivided with fibrous septa and filled with numerous translucent, oval to ellipsoid bladder-like cysts, almost completely replacing right lung lobe “.	Morphology. Cysticerci with single inverted scolex, a rostellum with two rows of hooks and exogenous buds. DNA analysis. <i>cox1</i> [P2]: Identity 880/880bp, 100% with <i>T. crassiceps</i> (GenBank AF216699, AB033411).
<i>T. crassiceps</i> Case 6, Bleyer et al. (2018)	28-year-old female, captive-born Nilgiri langur (<i>Semnopithecus johnii</i>) from a German zoo, with a right ankle joint age-related myxosarcoma developed an edematous swelling of the left thigh and also suffered from lethargy and anorexia. Animal was euthanized because of poor general condition.	Necropsy. Skeletal muscle of the left thigh had been replaced by a multilocular cystic mass containing numerous sand-grain-sized whitish structures; similar cysts were also present in the lung and the myocardium.	Morphology. Based on hook morphology. DNA analysis. <i>cox1</i> [P1]: Identities 98–100% (450 bp) with <i>T. crassiceps</i> sequences.
<i>Taenia serialis</i> Case 1, Schwartz (1927)	Gelada baboon (<i>Theropithecus gelada</i>) from the National Zoological Park at Washington, D. C. with a large subcutaneous tumor in the right thoracic region.	Necropsy. Large subcutaneous tumor (1.5 kg). The majority of the mature cysts contained several hundred scoleces.	Morphology based on larval hooks and of adult worms from experimentally infected dogs. DNA analysis. Nd.
<i>T. serialis</i> Case 2, Sandground (1937)	Juvenile (< 2 years) spotted-nose monkey (<i>Cercopithecus nictitans</i>) imported from the West African Coast to the USA as a pet animal. Slight torticollis for 3–4 weeks, soft swelling at the back of the head. Died.	Necropsy. Many discolored bodies (1–2 cm) attached to mesentery. Scalp with bone erosion and protrusion of a mass of translucent, white cysts.	Morphology. Microscopical examination corresponds to <i>Coenurus serialis</i> . DNA analysis. Nd.
<i>T. serialis</i> Case 3, Elek and Finkelstein (1939)	4-year-old gelada baboon (<i>T. gelada</i>), borne in captivity in Germany and imported to USA (zoological park). Spastic paralysis in right lower extremity before death.	Necropsy. Multiple subcutaneous nodules in upper and lower extremities (1–12 cm), and a large intra-abdominal cystic mass infiltrating underlying muscles.	Morphology. Diagnosis of cysts (no microscopic details provided). DNA analysis. Nd.
<i>T. serialis</i> Case 4, Clark (1969)	Male gelada baboon (<i>T. gelada</i>), transported between two zoological parks in the USA. Nodular enlargement on right thigh. Euthanized because surgery was not successful.	Necropsy. Subcutaneous nodular enlargement (11–25 cm) with small ulcerations.	Morphology. Diagnosis of cysts (no microscopic details provided). Infection of 2 dogs was not successful. DNA analysis. Nd.
<i>T. serialis</i> Case 5, Schneider-Crease et al. (2013)	13-year-old male, wild Ethiopian gelada baboon (<i>T. gelada</i>) from a national park. Tissue was extracted from a protuberant coenurus on the left ventral forelimb.	Small to large swellings in various parts of the animal's body.	Morphology. Not reported. DNA analysis. <i>Its2</i> [P9] and <i>12S</i> [P5]: 99% and 99% identity with <i>T. serialis</i> sequences.
<i>T. multiceps</i> (probably misdiagnosed) Leith and Satterfield (1974)	6-year-old female gelada baboon (<i>T. gelada</i>) from a zoological park in the USA. Animal, which was imported from Ethiopia with 2 years, presented multiple subcutaneous cysts.	Necropsy. Multilocular easily ruptured cystic masses in the left masseter and temporal muscle region. Further subcutaneous cysts in the scapular region extending into the abdomen.	Morphology. Size, number, and shape of hooklets provided by the author, but inconclusive according to Table 5. DNA analysis. Nd.
<i>T. brauni</i> ^b Railliet and Marullaz (1919)	Rhesus monkey (<i>Macaca mulatta</i>), kept in France but unknown origin, infected with <i>Leishmania tropica</i> , died in experiment. Monkey (<i>Cercopithecus mitis doggetti</i>), Rwanda	Necropsy. Abdominal tumor at left perineum (2.7–5 cm).	Morphology. Microscopical measurements performed. ^b DNA analysis. Nd.

(continued on next page)

Table 4 (continued)

Taenia sp., case no., citation	Primate species, patient, origin, and case history	Pathological findings	Etiological diagnosis: morphology and DNA analysis (PCR, sequencing) ^a
<i>Taenia brauni</i> Fain (1956)		Cysts in brain (parietal lobe; 2 cm), heart (apex; 1 cm), and parotid gland	Morphology. Performed but no details provided by the author. DNA analysis. Nd.
<i>Taenia sp. coenurosis</i> Lau et al. (1973)	Whitehanded gibbon (<i>Hylobates lar</i>) at zoological park in the USA. Left eye progressing gradually for 3–4 weeks. Retrobulbar mass at radiography. Euthanasia.	Cyst behind the left eyeball.	Morphology. Size and shape analysis of hooklets inconclusive. DNA analysis. Nd.
<i>Taenia martis</i> De Liberato et al. (2014)	18-year-old male ring-tailed lemur (<i>L. catta</i>), immunocompetent, lives in a zoo in Rome (Italy). Apathy, loss of appetite, abdominal distension and diarrhoea were observed 10 days before death.	Severe exudative fibrinous-purulent peritonitis with numerous adhesions between the abdominal wall and the bowel loops. After intestine removal, two free and viable, 4 cm long, whitish, leaf-like parasitic forms were pinpointed.	Morphology. Macroscopic examination of the two parasites allowed their identification as larval stages of cestodes. DNA analysis. <i>cox1</i> [P1]: Identity 98% with <i>T. martis</i> sequences.
<i>T. martis</i> Brunet et al. (2014)	3-years-old subadult mail tonkean macaque (<i>Macaca tonkeana</i>), immunocompetent, born and raised at Strasbourg University Centre of Primatology, France.	Abdominal mass (± 10 cm × 5 cm) was detected at palpation without clinical signs.	Morphology. Cysticerci and rostellar hooks were most close to the <i>T. martis</i> description. DNA analysis. <i>cox1</i> [P1]: Identity 382/383 bp or 99.7% with <i>T. martis</i> sequence (GenBank AB731758). <i>nd1</i> [P3]: Identity 438/439 or 99.8% with EU544606.
<i>Versteria sp.</i> Goldberg et al. (2014)	Juvenile (sex?) Bornean orangutan (<i>Pongo pygmaeus</i>), captive born in Colorado, USA, (no indications of immunosuppression). Loss of appetite and intermittent, moist cough; became increasingly lethargic and was found dead after 2 days.	Necropsy. Diffuse hemorrhages in the lungs, splenomegaly, a pale mottled liver, and thoracic and pericardial effusions. Histopathology of the liver revealed cystic structures containing eukaryotic parasite cells. Cause of death: “acute respiratory distress due to disseminated infection with an unknown parasite”.	Morphology. Not conclusive. DNA analysis. Deep sequencing identified a <i>Taenia</i> spp. <i>12S</i> [P7] and <i>cox1/nd1</i> [P1/P3] phylogenetic trees placed the organism within <i>Versteria</i> sp. (Cestoda: Taeniidae).
<i>Taenia hydatigena</i> Hobbs et al. (2003)	5-year-old male rhesus macaque (<i>M. mulatta</i>), born and raised in a primate colony in China and imported 15 months earlier to the Oregon National Primate Research Centre. An abdominal mass was discovered during routine physical examination.	Necropsy. A pale yellow cyst attached to the greater omentum containing 500 ml of flocculent yellow fluid.	Morphology. Rostellar hooks, the large size of the cysticercus, and its location within the peritoneal cavity were consistent with the diagnosis of a <i>Taenia hydatigena</i> cysticercosis. DNA analysis. Nd.
<i>T. hydatigena</i> Tsubota et al. (2009)	5-years-old male long-tailed macaque (<i>Macaca fascicularis</i>), born and raised in a primate research colony in China in a toxicity study in Osaka (Japan). The monkey showed no clinical signs and was sacrificed at the end of a dosing experiment.	Necropsy. A yellow cyst filled with more than 100 ml of pale yellow fluid was found in the abdominal cavity.	Morphology. A cysticercus with a well developed scolex was found in the cyst. DNA analysis. <i>nd1</i> [P3]: Identities of 96.7%–98.5% with <i>T. hydatigena</i> sequences.
<i>Taenia sp.</i> Wolff et al. (1989)	Captive-born 1-year-old male red ruffed lemur (<i>V. variegata rubra</i>) with unremarkable routine quarantine examination with radiography (zoo, USA).	Necropsy. Extrapleural calcified larval cestode in the left ventro-caudal thorax and pulmonary nodule with a cysticercus in the left dorso-caudal lung.	Morphology. Cysticercus with armed scolex; species identification not done. DNA analysis. Nd.

Nd: Not done or no data given.

^a Primer pairs used are given in squared brackets and refer to Table 6.

^b Diagnosed as *Multiceps ramosus* or *M. lemuris* by the author, which are considered to be a synonym for *T. brauni* (Loos-Frank, 2000).

the Alps was reported from another patient but without obvious contact to wild animals. All four patients could successfully be treated by surgery and anthelmintics.

Interestingly, all *T. martis*-cysticercosis patients described so far originated from Europe, and no data are available on the zoonotic potential of *T. martis americana*. Furthermore, all four human *T. martis* cases were documented in 36, 43, 44 and 70 years old women, though the number of cases is too small to speculate on a gender association. However, the host's endocrine system can have an impact on the susceptibility to cestode infections. For example, castration of male and pregnancy in female pigs significantly increased the prevalence of naturally acquired *T. solium* cysticercosis (Morales et al., 2002), female mice are more susceptible to experimental infections with *T. crassiceps* than males (Morales-Montor et al., 2002), and female rabbits are more frequently infected with *T. pisiformis* metacestodes than males (Domínguez-Roldán et al., 2018).

2.2. *Versteria mustelae* and *Versteria sp. cysticercosis*

Versteria mustelae (new genus created by Nakao et al., 2013; syn. *Taenia mustelae*) is an up to 10 cm long tapeworm of mustelids with a wide range of rodents as intermediate hosts, bearing in the liver the

rather small, ovoid, 0.4–2.0 mm large cysticerci containing many calcereous bodies (Freeman, 1956; Slais, 1973). In Europe, weasel (*Mustela* sp.), stone marten (*Martes foina*) and pine marten (*M. martes*), and in the USA American pine marten (*Martes americana*), ermine (*Mustela ermine*) and mink (*Neovison vison*) have been described as definitive hosts (Lee et al., 2016; Hoberg et al., 1990). Between 1981 and 1987, *V. mustelae* was identified in 2.9% of 272 *Martes zibellina* in Southwestern Yakutia (Siberia) (Sedalischev and Odnokurtsev, 2011).

A variety of rodents have been identified as intermediate hosts of *V. mustelae* in Europe and Asia. In eastern Switzerland, *V. mustelae* was found in very low prevalences in 0.1% of 1276 *A. sylvaticus*, in 0.1% of 1211 *M. glareolus*, in 0.3% of 347 *M. arvalis* and in 0.4% of 250 *M. agrestis*, but neither in 411 *A. flavicollis* nor in 894 *A. terrestris* (Schaerer, 1987). In Zealand (Denmark), 14 of 46 *M. glareolus* were infected with *V. mustelae* (Tenora et al., 1991), and this species was found in 9.3% of 172 *M. glareolus* trapped in rural forest habitats and in 0.4% of 231 animals from urban forests and parks but not in 41 and 129 *A. flavicollis*, respectively (Al-Sabi et al., 2015). In this study, prevalences were determined by molecular analyses with considerably higher sensitivities as compared to morphological identification. Interestingly, the authors stated that “several poorly developed cysts without specific morphology were observed”. In Sweden, *V. mustelae* was diagnosed by

PCR in 13% of 56 *A. amphibius* and in 14% of 187 *M. agrestis* from field habitats, and in 8.4% of 655 *M. glareolus*, but not in 79 *A. flavicollis* and 206 *A. sylvaticus* from forest habitats (Miller et al., 2017). In Finland *M. glareolus*, *M. rutilus*, *M. rufocanus*, *M. agrestis*, *M. oeconomus* and *A. flavicollis* have been identified as intermediate hosts of *V. mustelae* (syn. *Taenia tenuicollis*) (Tenora et al., 1983). In South-Central Finland, cysts of *V. mustelae* were detected in 9% of 34 *M. agrestis* and in 27% of 117 *C. glareolus* in the liver in a habitat with *Mustela nivalis* and *M. erminea* as main definitive hosts (Soveri et al., 2000).

In France (Jura), *V. mustelae* was more frequently observed in *M. glareolus* (24% of 349) than in *Pitymys subterraneus* (5% of 75), *M. agrestis* (9% of 47), *M. arvalis* (1% of 2520) and *Apodemus* sp. (1% of 230) (Le Pesteur et al., 1992). In Spain, *V. mustelae* was reported in *P. duodecimcostatus*, *P. lusitanicus*, *P. pyrenaicus*, *M. agrestis*, *M. arvalis*, *M. cabrae* and *M. glareolus* (Feliu et al., 1997). Ribas et al. (2009) documented the occurrence of *T. tenuicollis* (former syn. of *V. mustelae*, not to be confused with *Cysticercus tenuicollis* of *T. hydatigena*) in 6.7–12.6% of 376 *M. glareolus* caught in northern Spain.

Genetic investigations revealed that a complex of species, genotypes and genetic lineages exist within the genus *Versteria* in North America (Lee et al., 2016). The authors suggested the occurrence of a “western lineage” (present in Colorado, Oregon, and Idaho, and the Northwest Territories (NWT) of Canada) and a “northern continental lineage” (present in Wisconsin and the NWT), with sympatry in the NWT. This northern continental lineage clusters with *V. mustelae* from Eurasia (Finland and Siberia). The western lineage responsible for fatal infections of an orangutan and a human patient (Case 2, Table 2) also infects muskrats (*Ondatra zibethicus*) in Idaho, USA, and the NWT.

So far, *V. mustelae* genetically related to the European isolates, have not been found in primates, including humans all over the northern hemisphere. On the other hand, in North America, a “zoonotic” lineage named *Versteria* sp. responsible for a fatal infection of an orangutan (Table 5) and in 2018 of infections in two human patients (Table 3) seems to be genetically closely related, but distinct from *V. mustelae*. In this review we refer to this genotype as *Versteria* sp. or North American zoonotic *V. mustelae* variant as used by Goldberg et al., 2014; Lee et al., 2016. Furthermore, based on the description of a patient from Pennsylvania (USA) with Hodgkin disease and an undefined helminthic infection (Connor et al., 1976), Olson et al. (2003) published a 18S sequence (GenBank: AY193876) without significant homology to other sequences in the database at the time of publication. We reanalysed this sequence in 2019 and identified a homology of 95% with *V. mustelae* (GenBank: AB731633) of European origin. Moreover, we recently sequenced the corresponding 18S region obtained by molecular analysis of clinical material of a female patient from Atlantic Canada with a *Versteria* sp. infection (published by Barkati et al., 2018, Table 3), and detected a homology of 99.7% with the GenBank entry (AY193876) of the Pennsylvanian patient mentioned above. Therefore, we conclude that the patient originating from Pennsylvania (USA) (Connor et al., 1976) represents the first documented case of human *V. mustelae* sp. cysticercosis (patient 1, Table 3).

Interestingly, North American *V. mustelae* isolates from Minnesota (USA) and from Algonquin Park (Canada) are capable of asexual multiplication in the intermediate host (Freeman, 1956), however it is unclear whether *V. mustelae* or the zoonotic *Versteria* sp. have been investigated. This phenomenon is distinct from the budding multiplication of *T. crassiceps*, and could be responsible for the systemic and invasive infections in heavily immunocompromised human patients. However, further investigations with genetically defined isolates are needed to elucidate the fascinating biology of *Versteria* spp. Furthermore, based on the small, not fully developed *Versteria* sp. cysticerci in the liver in immunocompromised patients, this infection must be considered in the differential diagnosis of alveolar echinococcosis as proposed by Barkati et al. (2018).

3. Canid-transmitted cysticercosis and coenurosis

3.1. *Taenia crassiceps* cysticercosis

Taenia crassiceps is a relatively large but harmless tapeworm, 10–22 cm in length, inhabiting the intestines of carnivore definitive hosts, and it is widely distributed in the northern hemisphere (Table 1). In rodents, which are the natural intermediate hosts for the parasite, the larval (metacestode) form of *T. crassiceps* has a particular asexual reproduction by budding both exogenously and endogenously (Baer and Scheidegger, 1946; Freeman, 1962; Slais, 1973). Exogenous budding at the abscoplex pole can produce 1–6 daughter cysticerci, which can bud off or remain attached and form a scolex of their own. This continuous and uncontrolled proliferation leads to massive infections, most frequently involving the subcutis, and both pleural and peritoneal cavities, causing death of the intermediate host within several months, or serious pathological implications in a large variety of dead-end hosts, including humans and other primates. Sporadic cases of cysticercosis caused by *T. crassiceps* have been documented in humans (Table 2), non-human primates (Table 4), but also rarely in e.g. domestic dogs (Ballweber, 2009; Beugnet et al., 2009; Chermette et al., 1993; Hoberg et al., 1999), a cat (Wunschmann et al., 2003), red foxes (Konjević et al., 2016; Whipp et al., 2017) and a chinchilla (*Chinchilla lanigera*) (Basso et al., 2014).

Natural intestinal infections with *T. crassiceps* have been described in the northern hemisphere mainly in the red fox (*V. vulpes*), but also in several other canids. A study in New Brunswick and Nova Scotia in eastern Canada in red foxes reported prevalences of 50% for *T. crassiceps* (Smith, 1978). *T. crassiceps* was also reported from Greenland (Andreassen et al., 2017), from Svalbard island (Stien et al., 2010), and from China, with 2 of 27 red foxes, and 1 of 9 Tibetan sand foxes found infected (Li et al., 2013).

In European red foxes *T. crassiceps* is widely distributed with prevalence varying between 4.3 and 29%, and 7.6% in foxes living in the city of Zurich, Switzerland (Hofer et al., 2000). Similar prevalence ranges have been described for Germany (17.7–28.5%, Ballek et al., 1992; Loos-Frank and Zeyhle, 1982; Pfeiffer et al., 1997; Welzel et al., 1995), France (15.9–29%, Pétavy and Deblock, 1980; Pétavy et al., 1990), Spain (4.3–23%, Alvarez et al., 1995; Segovia et al., 2004), and Lithuania (26.4%, Bruzinskaite-Schmidhalter et al., 2012). In Russia, 19% of 68 hunted red foxes were infected with *T. crassiceps* in central Yakutia (Sedalischev and Odnokurtsev, 2013), and 49% of 247 red foxes and 7% of 43 corsac foxes (*V. corsac*) of Omsk Oblast (Siberia) between 2000 and 2004 (Bukova, 2006).

Taenia crassiceps was also detected in wolves in Canada, Europe and Russia (Abuladze, 1970; Craig and Craig, 2005). In Latvia 9% of 34 (Bagrađe et al., 2009), and in North-West Caucasia 2.8% of 36 wolves were infected with *T. crassiceps* (Itin et al., 2018). Freeman (1961) detected *T. crassiceps* in 1.7% of 58 Canadian wolves and in one of 6 coyote-dog hybrids, but not in 68 coyotes.

Of 17 Hungarian golden jackals (*Canis aureus* L., 1758), *T. crassiceps* has been found in 40% (Takács et al., 2014) and infections were recorded in 0.6% of 179 wolves in northern Italy (Gori et al., 2015). The raccoon dog (*Nyctereutes procyonoides*) seems to be another suitable host of *T. crassiceps*: it was identified in 6 of 72 animals from the Republic of Belarus (Subbotin, 2009), and it was found in 3.5% of 85 raccoon dogs in Lithuania (Bruzinskaite-Schmidhalter et al., 2012).

However, not only canids seem to be susceptible to *T. crassiceps* intestinal infections. Raccoons (*Procyon lotor*) were infected with *T. crassiceps* as reported from the North-Western Caucasus with a prevalence of 24% in 42 animals (Itin et al., 2018). Schuster et al. (1993) identified *T. crassiceps* tapeworms in 2 of 25 wild cats (*Felis silvestris*) and Loos-Frank and Zeyhle (1982) found infections in 6% of 47 stone martens (*Martes foina*) in Germany.

Finally, in several human patients with *T. crassiceps* cysticercosis, close contacts to domestic dogs were assumed as source of infection (cases 1, 4, 5, 8, 10; Table 2). However, the epidemiological importance of domestic carnivores is probably overestimated. Umhang et al. (2014) reported 5 of 817 (0.6%) dog faecal samples from eastern France to be positive for *T. crassiceps* eggs. Dyachenko et al. (2008) detected *T. crassiceps* eggs in 7 of 17,894 (0.04%) dog samples in Germany and other European countries, but in none of 9064 cat faeces. However, in an older study in southwest Germany intestinal infections with *T. crassiceps* were also observed in 1% of 387 stray cats supplied for rabies examination, some had been shot by private hunters and some were road kills (Loos-Frank and Zeyhle, 1982).

As intermediate hosts in northern America, the muskrat (*Ondatra zibethicus*), the common vole (*Microtus arvalis*), the eastern chipmunk (*Tamias striatus*), the deer mouse (*Peromyscus maniculatus*), the meadow vole (*Microtus pennsylvanicus*), but also the woodchuck (*Marmota monax*), and lemmings (*Dicrostonyx groenlandicus richardsonii*, *Lemmus trimucronatus trimucronatus*) were identified (Leiby and Whittaker, 1966; Albert et al., 1972). In Europe *T. crassiceps* cysticercosis seems to occur focally in variable prevalence in rodents. In Switzerland, *T. crassiceps* cysticerci were detected in 2 (0.22%) of 894 *Arvicola terrestris*, in 3 of 347 (0.86%) *Microtus arvalis*, and in 1 (0.4%) of 250 *M. agrestis*, but not in 411 *Apodemus flavicollis*, 1276 *A. sylvaticus* and 1211 *Myodes* (Syn. *Clethrionomy) glareolus* of the same area in eastern Switzerland (Schaerer, 1987). These very low prevalence of *T. crassiceps*, as well as very low prevalence of *E. multilocularis* (0.11%) in *A. terrestris*, and the absence in the other species mentioned above, were probably associated with the significantly reduced fox population during this time, which was attributed to the rabies epidemic and the corresponding control measurements. Later studies reported higher *T. crassiceps* prevalence, e.g., in 2.0% of 889 *A. terrestris*, whereas none were detected in neither 83 *M. glareolus* nor 154 *Apodemus* sp. (Stieger et al., 2002), while another study found *T. crassiceps* in 1.9% of 856 *A. terrestris* (Burlet et al., 2011) in the Zurich Area (Switzerland). In the Geneva area (Switzerland) Reperant et al. (2009) detected *T. crassiceps* cysticerci in 2.6% of 466 *A. terrestris*, in 2.9% of 35 *M. arvalis*, and in 1.0% of 99 *A. flavicollis*, but not in 58 *M. glareolus*. Interestingly, no *T. crassiceps* or *T. taeniaeformis* were identified in a study in Berlin (Germany), including 77 *A. flavicollis*, 25 *A. sylvaticus*, 72 *A. agrarius*, 56 *M. glareolus*, and 10 *Microtus* sp. (Krücken et al., 2017). Finally, in Japan *T. crassiceps* was found in three of 46 *M. montebelli* but not in 187 *Apodemus speciosus* (Ihama et al., 2000).

Interestingly, no reports on the occurrence of *T. crassiceps* were found from Scandinavia, Ireland and the UK. No *T. crassiceps* infections were detected in 197 foxes from Wales (Jones and Walters, 1992a), in 843 foxes from Southern England (Richards et al., 1995), and in 366 foxes from Northern Ireland (Ross and Fairley, 1969). Furthermore, in this paper the intestinal helminths in foxes in the UK were reviewed and *T. crassiceps* was not mentioned in several older studies. Further, no *T. crassiceps* findings are mentioned in rodent investigations in Zealand, Denmark (Al-Sabi et al., 2015; Tenora et al., 1991), in 1702 rodents investigated in Sweden (Miller et al., 2016), nor in high numbers of rodents investigated in Finland (Tenora et al., 1983; Soveri et al., 2000), and Ireland (Loxton et al., 2017).

Because of the high *T. crassiceps* prevalence in red foxes and their high population densities, the fox seems to be responsible for the perpetuation of the parasite cycle, as well as for the contamination of the environment with eggs in Central Europe. A similar situation can be observed with *E. multilocularis* (Hegglin and Deplazes, 2013). However, only a few studies have documented environmental contamination with *T. crassiceps* eggs. For example, Hauser et al. (2015) identified *T. crassiceps* eggs through DNA analyses in 5 (8.6%) of 58 fox faecal samples,

and in one (0.2%) of 402 dog samples collected during the course of one year in 14 different grassland areas in the canton of Zurich, Switzerland. Furthermore, *T. crassiceps* eggs have been identified in the washing water of one of 141 samples of food, which consisted each of around 40 heads of lettuce, as well as various vegetables and fruits (Federer et al., 2016).

A number of well documented cases of *T. crassiceps* cysticercoses have been published in humans and other primates (Tables 2 and 4). Most of the cases, which have all been published in the last 30 years, originated from Central Europe (Germany, Switzerland, and France). Most cases of humans involving subcutis and muscles have been associated with underlying immunosuppression (cases 2, 3, 5–8; Table 2), except case 9, where a subcutaneous infection was associated with a haematoma localized on the right temple in an immunocompetent Swiss patient, and case 12 where a subcutaneous infection on the shoulder of a patient from USA was documented (Table 2). In contrast, an intercerebellar (case 10) or intraocular infections (cases 1, 4, and 11; Table 2) were not associated with an impaired immune system.

Surprisingly, in all cases, the infection started uni-focally and progressed by infiltration of the surrounding tissues, especially in the non-ocular/neural cases. Due to the systemic spread of the activated oncospheres in the blood circulation after oral egg uptake we would expect simultaneous multifocal infections as described for *T. solium* (especially in severely immunocompromised patients) and for *T. serialis*, where in some cases multiple lesions were observed in individuals without any indication of immuno-suppression. Interestingly, among the 7 cases of subcutaneous *T. crassiceps* cysticercosis (Table 2), 5 had a history of precedent injuries associated with the later development of cysticercosis. In cases 2, 3, 6, 7 a haematoma after a fall was reported at the site of subsequent cysticercosis development. In case 8, the patient remembered, that 5 months before the swelling on the same arm started, an injury to her right wrist occurred during her work as a zoo-employee.

Generally, humans acquire taeniid infection by oral ingestion of infective eggs. The most probable route of transmission after contact with taeniid eggs in the contaminated environment is the hand-to-mouth route. Hypothetically, transmission has also been linked to water or food-borne sources (vegetables/fruit/berries), but any source attribution is uncertain (Alvarez-Rojas et al., 2018). Taeniid eggs can be dispersed from carnivore faeces with water or by adhering to objects (e.g. shoes and tyres). For example *E. multilocularis* eggs have been found on the hair coat of foxes (Nagy et al., 2011), suggesting a variety of potential infection routes to humans.

There is experimental evidence that taeniid eggs can hatch and develop further without the gastric passage. In sheep it was demonstrated that intra-tracheal *E. granulosus* egg inoculation was followed by cystic echinococcosis development in the lungs (Thompson, 1995). Furthermore, embryophore-free (based on sodium hypochlorite treatment) but not enzymatically activated *E. multilocularis* oncospheres caused local alveolar echinococcosis after subcutaneous injection in a mouse model designed for the documentation of egg viability (Federer et al., 2015). The same method using 1000 *T. crassiceps* eggs resulted in subcutaneous cysticercosis (confirmed by PCR/sequencing as described in Trachsel et al., 2007) in 2 of 3 inoculated BALB/c mice (Joekel D. and Deplazes P., unpublished data). Therefore, taeniid eggs accidentally contaminating cutaneous injuries might locally hatch and further develop to larval stages. A human case of subcutaneous alveolar echinococcosis (Tschudi and Ammann, 1988) associated with a cutaneous injury, and a subcutaneous cystic echinococcosis in the popliteal fossa at the site of a previous wasp sting (Battany et al., 2010), have been documented.

3.2. Coenuroses

3.2.1. Introduction

Coenurosis results from infection with metacestodes of *Taenia multiceps*, *T. serialis*, *T. brauni* and *T. glomeratus*. Canids and rarely other carnivores are the definitive hosts harbouring adult tapeworms in the intestine (Table 1). Tapeworms mature within 15–42 days, with 3–4 proglottids shed daily containing more than 35,000 eggs per proglottid (Willis and Herbert, 1984). For *T. multiceps* it was shown that most eggs are released already from the proglottis in the intestine of the final host (Herbert et al., 1984; Scala and Varcasia, 2006). Each of the described tapeworm species usually infects a specific range of intermediate hosts (Table 1). After spreading of the oncosphere through the blood system, a vesicle-shaped cyst develops as coenurus, containing a few to several hundred protoscolices (Lescano and Zunt, 2013; Willis and Herbert, 1984).

Classically, only *T. multiceps* was considered to cause CNS, spinal cord, and eye infections, while *T. serialis*, *T. brauni* and *T. glomeratus* distribute to soft tissue/subcutaneous connective tissue, the musculoskeletal system, and visceral organs (Lescano and Zunt, 2013). However, a morphologically similar and genetically identical strain (based on mitochondrial genes) of *T. multiceps* (referred to as *T. gaigeri* or *T. multiceps gaigeri* in goats and *T. skrjabini* in sheep) was shown to cause non-cerebral coenurosis in goats and to a lesser extent in sheep (Christodouloupoulos et al., 2013; Schuster et al., 2010; Verster, 1969). However, for none of these strains the zoonotic potential has been documented.

Humans may be infected as dead-end hosts, with the cystic larvae usually developing in the CNS, eye, or subcutaneous or intramuscular tissues. Between 1994 and 2018, 7 cases of coenurosis in humans have been described, mainly in individuals with close contact to canids (Supplemental Table 1). Human coenurosis is much less common than cystic echinococcosis, though both causing agents have the same definitive hosts. Cases have been reported predominantly from African countries, and only a few cases have been documented in South- and North America and Europe. Patients with coenurosis usually have a space-occupying lesion caused by a single cyst of 2–6 cm in diameter. However, cysts up to 10 cm in diameter have been reported.

3.2.2. *Taenia multiceps* coenurosis

Taenia multiceps (formerly *Multiceps multiceps*) is a large tapeworm with variable size between 20 and 120 cm. *Taenia multiceps* coenurosis (sometimes called gid, staggers, or sturdy) has been documented in scattered foci all over the world, with the exception of Australia and New Zealand (Scala and Varcasia, 2006). In North America, however, the last case of *T. multiceps* gid has been reported in the thirties and the disease is considered absent, despite one supposed human case in 1982 (Becklund, 1970; Ing et al., 1998; Schellhas and Norris, 1985).

The parasite life cycle is predominantly maintained by domestic and stray dogs, when they have access to residuals from improper discarded slaughtered meat, or roaming of stray dogs around small ruminant farms and early access to animals that died in the field (Abera et al., 2016; Vasileiou et al., 2015). Global transport of domestic dogs (travel and trading) represents yet another risk for the dissemination of taeniid eggs. Correspondingly, in Switzerland where only rare and sporadic cases are noticed, an outbreak of coenurosis in a dairy sheep flock has been reported, with approx. 10% of 140 sheep presenting clinical signs. The source of infection was a single livestock guardian dog imported from Italy (Schweizer et al., 2006).

The importance of wild carnivores for the distribution of taeniid eggs is valid where wild canids (e.g. wolves and foxes) have access to animals that have died in the field infected with *T. multiceps*. The role of

wild carnivores was neglected as it was assumed that they have no access to sheep brains protected by the thick skull. However, firstly, the presence of cysts is associated with thinner skull bones, thus allowing access, even for foxes (Scala and Varcasia, 2006). Secondly, infection trials have demonstrated that foxes can develop gravid proglottis and infective eggs (Varcasia et al., 2015b). Correspondingly, in various regions where *T. multiceps* coenurosis is endemic in sheep, tapeworms have been reported from fox species, with 1–28.2% positive results from necropsied foxes in Russia (summarised in Varcasia et al., 2015b), 0–5% in Germany (Ballek et al., 1992; Loos-Frank and Zeyhle, 1982; Welzel et al., 1995), 2% in Peru (Moro et al., 1998), 3.8% in Jordan (El-Shehaby et al., 1999), 4.8–8.2% in Iran (Dalimi et al., 2006; Nabavi et al., 2014), and 6% in Tibetan sand foxes in China (Li et al., 2013). An extensive survey on fox hounds and foxes in Wales revealed 0.46%–1.7% dogs infected with *T. multiceps* but none of the foxes (Jones and Walters, 1992a, 1992b). However, the foxes had other *Taenia* species, including *T. serialis* which is responsible for coenurosis in lagomorphs in the UK (see below). In addition, earlier publications demonstrate the presence of *T. multiceps* in foxes in Bulgaria, Czech Republic, Italy, Poland and Switzerland (summarised in Loos-Frank and Zeyhle, 1982).

The wolf is a known definitive host for *T. multiceps* and *T. serialis* (Craig and Craig, 2005; Otranto et al., 2015b). Data are available for European grey wolf populations with prevalences of 0.5% in Croatia (Hermosilla et al., 2017), 3.9% in Serbia (Cirovic et al., 2015a), 0–9% in Italy (Gori et al., 2015; Guberti et al., 1993; Paoletti et al., 2017), 27% in Estonia (Moks et al., 2006), 28–29.8% in Spain (Segovia et al., 2001, 2003), and up to 47.1% in Latvia (Bagrade et al., 2009). Nabavi et al. (2014) found 1 of 4 wolves from Iran positive for *T. multiceps*. Interestingly, golden jackals (*C. aureus*) from Italy as well as from the western part of Iran were negative for *T. multiceps* and *T. serialis* (Dalimi et al., 2006; Nabavi et al., 2014; Paoletti et al., 2017). In Serbia, however, *T. multiceps* was found in 1.6% of golden jackals, another wild carnivore of eastern Europe, the Middle East and Asia (Cirovic et al., 2015b). These tapeworm species were absent in 80 brown bears in a *T. multiceps*/*T. serialis* endemic region in central Italy (Paoletti et al., 2017). Henke et al. (2002) described *T. multiceps* in coyotes in Texas but this report needs to be considered with care as it could be a morphological miss-diagnosis of *T. serialis*, and generally *T. multiceps* is assumed to be absent in North America.

Metacestode infections (coenurosis) have also been reported from dead-end hosts (including dogs, horses, humans and other primates). *Taenia multiceps* coenurosis in humans and other primates represents a serious clinical condition. Supplemental Table 1 summarizes 45 cases of human *T. multiceps*-coenurosis, which were from Africa (n = 21), Europe (n = 17), Asia (n = 2), South America (n = 1), USA (n = 3) and the Middle East (Israel; n = 1). Where specified, the age of the patients was between 1 and 55 years (median: 33; SD: 17.0), showing that all age groups are potentially affected. Similar to infections in ruminants, the predominant infected tissue was the brain (n = 35/44), followed by intra-/periocular infections (n = 8/44) and rarely infections in the spinal cord (n = 1/44). Correspondingly, the infection was often fatal (42%) or ended with the loss of vision after eye removal (15%). Symptoms like partial paresis or paraplegia remained (12%), and only one third of the patients recovered partially or completely after surgery. However, in spite of the severity of the outcome of an infection in humans, coenurosis represents a rather minor risk for public health, given the relatively high infection pressure demonstrated by the wide occurrence and high prevalence of *T. multiceps* in canids but only 5 published cases in the past 25 years. Furthermore, there are no indications of immunodeficiency in these cases. Similarly, *T. multiceps* is rarely reported in other primates.

3.2.3. *Taenia serialis* coenurosis

The adult *T. serialis* tapeworm has a size of 20–72 cm and is morphologically very similar to *T. multiceps* but can be differentiated by hook number, size, and shape (Table 5). The life cycle of *T. serialis* includes canids as final hosts and hares and rabbits (rarely rodents) as intermediate host (Table 1), with *Coenurus serialis* in subcutaneous and muscle tissues, and occasionally in abdominal cavities (Pfaffenberger and Valencia, 1988; Verster, 1969). *Taenia serialis* is prevalent in North America, Europe and Africa. However, there are also recent reports of *T. serialis* in rabbits from Iran and China (Moshiri et al., 2018; Zhang et al., 2018). Furthermore, PCR confirmed *T. serialis* eggs in the faeces from 2 out of 1425 dogs from rural Australia (Jenkins et al., 2014). Hence, it is not surprising that this parasite has been occasionally found in Australian ring-tailed possums (*Pseudocheirus peregrinus*) and in kangaroos (*Macropus fuliginosus*) (Dunsmore and Howkins, 1968; Hough, 2000).

In contrast to *T. multiceps* with a predominantly domestic life cycle, wildlife plays a more prominent role in *T. serialis*. Surveys in the USA showed high prevalence throughout the nation, e.g. 12% (429 dogs) in Arizona and New Mexico and overall 3–29% in definitive hosts (Ing et al., 1998). With regard to intermediate hosts, 46% of 35 black-tailed jack rabbits (*Lepus californicus*) and 19% of a local rodent population were infected with *T. serialis* (Pfaffenberger and Valencia, 1988; Schantz et al., 1977). Henke et al. (2002) reported on *T. multiceps* in coyotes (*C. latrans*) from Texas but a misdiagnosis with *T. serialis* is probable in the absence of molecular species confirmation. Correspondingly, a recent study from Edmonton (Canada) found *T. serialis* in 13% out of 23 urban coyote carcasses (Luong et al., 2018). Interestingly, *T. serialis* was also found in arctic foxes (*Vulpes lagopus*) from north-east Greenland, demonstrating the widespread occurrence of this parasite in wild carnivores and the importance of a wildlife-cycle (Andreassen et al., 2017). In Europe, *T. serialis* occurs in regions where lagomorphs are present. In the UK, 0.3–0.6% of hunting dogs and 0.5% of 197 foxes from the same region have been found positive for *T. serialis*, respectively (Jones and Walters, 1992a, 1992b). Interestingly, *T. multiceps* was absent in the same fox population, despite being in a sheep raising region with observed cases of coenurosis. In Northern Ireland, up to 4% of the local fox population was infected with *T. serialis* (Ross and Fairley, 1969). On the European mainland, this cestode is rarely reported in foxes. Correspondingly, by examining large numbers of foxes from Germany, 0.15–2.3% of foxes were positive (Loos-Frank and Zeyhle, 1982; Pfeiffer et al., 1997; Welzel et al., 1995). In wolves, however, reported infection rates were 2.1% of 47 and 8% of 50 wolves in Spain (Segovia et al., 2001, 2003), 5.9% of 68 wolves in Portugal (Guerra et al., 2013), and 1% of 102 wolves in Serbia (Cirovic et al., 2015a). Hence, wolf migration might be a risk for the dissemination of *T. serialis* from the southern and eastern parts of Europe to new areas. In this sense, *T. serialis* was found in 1.1% of 447 golden jackals from Serbia, a species migrating into Central Europe (Cirovic et al., 2015b). A survey in Germany could not find adult *T. serialis* in 84 badgers, 47 stone marten, and 387 cats (Loos-Frank and Zeyhle, 1982).

Rare cases of coenurosis in cats caused by *T. serialis*, but not by *T. multiceps* have been reported (Hayes and Creighton, 1978; Huss et al., 1994; Orioles et al., 2014; Slocombe et al., 1989; Smith et al., 1988). Correspondingly, *T. serialis*-coenurosis represents a zoonosis with 11 case reports found in literature (Supplemental Table 1). The predominant location of the coenuri was subcutaneously or intramuscularly on the trunk of the patient. While cerebral infections due to *T. serialis* have been reported in sheep (and cats), there are no such reported cases in humans. The lesions were presented as palpable swellings, which were usually painless. Where indicated, all patients recovered after surgical removal of the lesion.

Several cases of *T. serialis* coenurosis in non-human primates have been reported, in contrast to *T. multiceps* with only one described case with uncertain diagnosis (Table 4). Unlike in humans, cerebral, intra-abdominal, intramuscular and subcutaneous infections have been

observed. Interestingly, in a study between 1971 and 1972 in an Ethiopian national park, metacestodes of *T. serialis* have been identified morphologically in large visible subcutaneous swellings in 9.2% of 92 gelada baboons. In a follow-up study (1974–1975) observing the same animals, 10.6% were infected (Dunbar, 1980). Forty years later (2011), 4.8% of 291 other gelada baboons living in the same park had visible swellings, and in some of them, *T. serialis* was molecularly confirmed (Schneider-Crease et al., 2013). Unlike in other intermediate hosts, these visible asymmetric masses can grow very large in baboons (> 16 × 20 cm) and may show ulcerations, disturbing the animals obtrusively (Schneider-Crease et al., 2013; Schwartz, 1927). Potentially, these large lesions can develop over long time periods because of a long life span and a low predation rate of the infected animals. In fact, only 0.9% of juvenile baboons presented visible swellings, as compared to 9.9% of adults (Schneider-Crease et al., 2013). In spite of an endemic infection of primates, there were no human case-reports from Ethiopia, relativizing the zoonotic risk of *T. serialis*. Noteworthy, in contrast to e.g. *T. crassiceps* cysticercosis with single subcutaneous locations, many cases of *T. serialis*-coenurosis show multiple lesions, indicating a peroral infection and systemic parasite dissemination.

3.2.4. ‘African-type’ coenuroses

Reported cases of soft-tissue coenuroses in Africa are considered to be caused by *T. brauni* and *T. glomeratus* (syn. *T. glomerata*). *Taenia brauni* is a tropical tapeworm of Eastern and Northern Africa, Rwanda and the Democratic Republic of Congo, with a wild animal life cycle, including dog, fox, jackal and genet as definitive hosts and rodents such as the swamp rat, porcupine and gerbil as intermediate hosts (Collomb et al., 2007; Fain, 1956; Vanderick et al., 1964). Coenuri in the brain only have been reported from rats (*Rattus r. rattus*) and non-human primates (Fain, 1956). *Taenia glomeratus*, which can be distinguished from *T. serialis* by careful morphological examination (Clapham, 1940a, 1940b), has only been reported from Nigeria and the Democratic Republic of Congo (Morel, 1959; Turner and Leiper, 1919).

In humans, 27 cases of *T. brauni* and one case of *T. glomeratus* have been reported from Rwanda, Uganda, Nigeria, and Congo, based on morphological identification and geographical association (Supplemental Table 1). There is only one report in a non-human primate (*Cercopithecus mitis doggetti*) from Rwanda with cysts in the brain, heart and parotid gland (Fain, 1956).

Overall, only limited information is available on these cestode species and any recent data is missing. It has to be considered that these species may be strains of *T. serialis*, based on the shared host range, tissue tropism, and clinical signs (Loos-Frank, 2000; Morel, 1959). However, there is no genetic data on *T. brauni* and *T. glomeratus*, and only a small number of published sequences for *T. multiceps* and *T. serialis*, which impair epidemiological studies (Collomb et al., 2007).

4. Diagnosis of cysticercosis and coenurosis

The tumor-like pathology of metacestode development in primates as dead-end hosts represents a challenge for the etiological diagnosis, which is mainly achieved only after necropsy, surgery or invasive diagnostic interventions. Serological tests have not been developed or validated with the exception of *T. solium* cysticercosis. The morphological characteristics of metacestodes, especially size and form of the scolex hooks, allowed highly probable diagnoses on species level (Verster, 1969; Slais, 1973; Loos-Frank, 2000). However, incomplete or damaged larval stages without or with only a few scolex hooks might be present in clinical diagnostic material. Furthermore, their development in dead-end hosts might be atypical and lead to altered morphological characteristics. For example, Bamrungphol et al. (1972) described a juvenile strobilate tapeworm found in the spinal cord of a young man from Thailand, who had suffered from paraplegia for several months. The recovered worm (76 mm long with 300 segments) had a scolex with four muscular suckers and a rostellum with few remaining,

Table 5
Taenia and *Versteria* spp. of domestic and wild carnivores with zoonotic potential. Morphological characteristics (modified after Loos-Frank, 2000).

Species	Larval type and name	Size	Asexual replication	Number of scoleces	Number of hooks	Length of large hooks (µm)
<i>T. crassiceps</i>	Cysticercus (<i>Cysticercus longicollis</i>)	2–8 mm	Yes	One	30–34	178–195
<i>T. martis</i>	Cysticercus	6–32 mm	No	One	28–30	183–218
<i>T. taeniaeformis</i>	Strobilocercus (<i>Strobilocercus fasciolaris</i>)	up to several cm	No	One	24–52	300–530
<i>T. multiceps</i>	Coenurus (<i>Coenurus cerebralis</i>)	up to several cm	No	Many	24–32	157–177
<i>T. serialis</i>	Coenurus (<i>Coenurus serialis</i>)	12–34 mm	No	Many	28–34	145–170
<i>T. brauni</i>	Coenurus (<i>Coenurus brauni</i>)	> 1 cm ^a	No	Many	22–30	85–160
<i>T. glomeratus</i> ^b	Coenurus (<i>Coenurus glomeratus</i>)	5.5–27.2 mm (up to 121 mm)	No	Many	18–34	90–110 ^b
<i>Versteria</i> (<i>Syn. Taenia</i>) <i>mustelae</i>	Cysticercus	0.4–2 mm	Yes ^c	One	30–74	14–38

^a Cysts from an ape in various parts of the body (Fain, 1956).

^b According to Turner and Leiper (1919); Clapham (1940a).

^c Observed with genetically not characterized North American isolates (Freeman, 1956).

morphologically highly variable hooks. The authors concluded that “the immature state of the worm and the loss of many of the hooks from the scolex make its specific identification impossible”. However, they suggested that this strobilate form of a tapeworm found in extra-intestinal tissue likely belongs to the family Taeniidae.

Among the parasites discussed, three different metacestodes types exist, cysticercus, strobilocercus and coenurus (Table 5). These stages consist of a fluid-filled bladder of various sizes and forms, with a single (in the case of cysticerci or strobilocerci) or multiple (in the case of coenurus) invaginated scolex or scoleces. At the anterior end, scoleces carry a rostellum, a retractable muscular organ, that is equipped with four suckers and each a row of characteristic large and somewhat smaller hooks. *Taenia crassiceps* cysticerci are able to multiply locally and to produce daughter cysticerci by an exo- or endogenous budding process (see chapter 3.1). Cysticerci are whitish, translucent, oval bladders of 0.4 to more than 30 mm in diameter, depending on the species. At one pole, a clearly visible, white, non-translucent knob-like structure is present: the invaginated scolex. Daughter cysts usually develop at the opposite pole. More challenging is the morphological diagnosis of *Versteria* sp. cysticercosis, as this currently not well described species proliferates in the liver without many precise morphological characteristics (see chapter 2.2) and so far only 3 cases have been identified in humans based on molecular analyses (Table 3). The strobilocercus of *T. taeniaeformis* lives encapsulated in spherical cysts in the liver of its intermediate host. Isolated strobilocerci appear to be segmented and resemble adult tapeworms. However, the body has an unsegmented, flattened tube-like form, may reach several centimeters in length and carries a single scolex (Table 5). Coenuri are translucent, fluid-filled sacks of up to several centimeters in size that contain many scoleces or even clusters of scoleces (Verster, 1969; Loos-Frank, 2000; Deplazes et al., 2016).

Characteristic structures that allow a tentative morphological identification include calcareous corpuscles, microtriches and scolex hooks. In HE stained histological sections, calcareous corpuscles appear as small (5–15 µm) oval structures of a whorled appearance in the parenchyma of cestodes. The corpuscles are diagnostic for cestodes and are especially prominent in larval stages. They contain calcium carbonate whose role is not understood. The bladder wall may be smooth or have a warty appearance. Microvilli-like structures (microtriches) are present on the outer surface of the larval stages (Orihel and Ash, 1995). As shown for *T. solium*, they appear early in the development from the oncosphere to the cysticercus (Fig. 1) (Chile et al., 2016).

For a morphological species identification, number, form and size of the scolex hooks are important. However, reported size ranges of hooks are quite broad and do not allow for a definite species identification (Table 5). Moreover, many measurements refer to hooks of adults and some differences between adult and larval hooks and differences between the development in natural and in accidental and dead-end hosts may exist.

Today, identification of larval cestodes in clinical material is mainly based on the analyses of the nucleotide sequences of the mitochondrial 12S rRNA, ND1 (NADH dehydrogenase 1), and COI (cytochrome c oxidase subunit 1) genes or the nuclear ITS2 (ribosomal internal transcribed spacer 2) sequence (Bowles et al., 1992; Bowles and McManus, 1993; von Nickisch-Roseneck et al., 1999; Trachsel et al., 2007) (Table 6). The same technique and in particular COI sequences have been broadly used for phylogenetic analyses (Sharma et al., 2016). Comparison of sequence data to published sequences in databases allow for a most reliable identification of cestodes, even if only small amounts of larval material is available, and this approach should be accepted as gold standard. However, sequence data especially of *T. brauni* and *T. glomeratus* are completely lacking, hindering the molecular identification in these cases. Therefore, efforts to produce and provide such data preferably based on morphologically characterized specimens should be intensified.

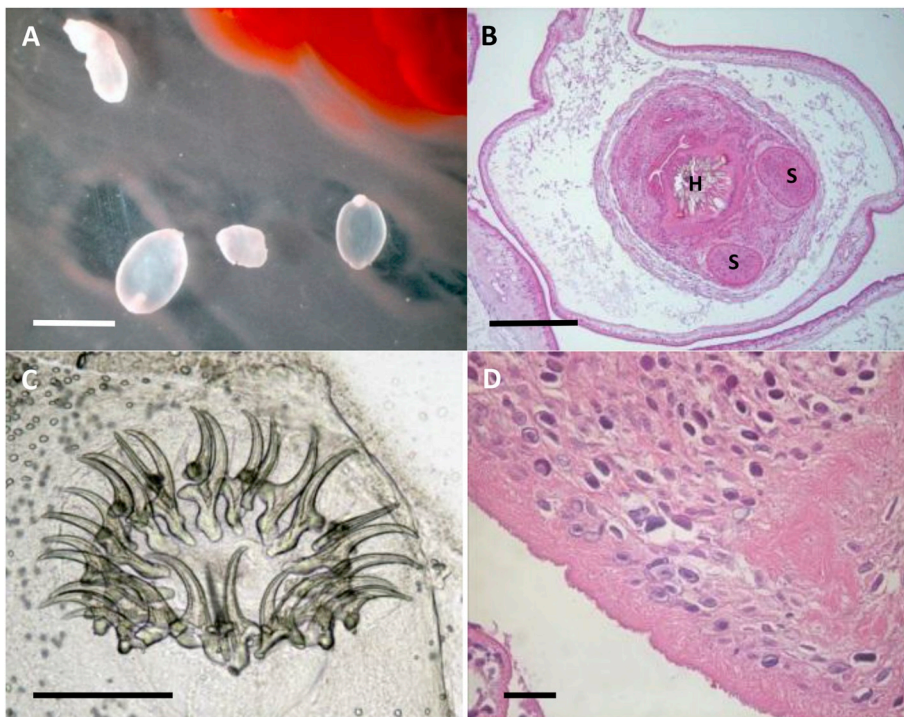


Fig. 1. *Taenia crassiceps* metacystodes (case 8, Table 2). **A.** Cysticerci isolated at surgery (wet preparation, scale bar 5 mm). **B.** HE stained section of an invaginated scolex with suckers (S) and hooks (H) (scale bar 500 µm). **C.** Large and small hooks, calcareous corpuscles (wet preparation, scale bar 200 µm). **D.** Calcareous corpuscles in the parenchyma and microvilli like structures (microtriches) on the outer surface of a metacystode wall (HE stain, scale bar 20 µm).

Table 6
Genetic targets for the PCR-based identification of cestode parasites.

Symbol (bold) and aliases	Primer designations	Primer sequence (5'-3') and approximate amplicon size	Reference and primer code [in squared brackets] as referred to in Tables 2–5
Target gene: Mitochondrial cytochrome c oxidase subunit 1			
mt-CO1	JB3	5'-TTT TTT GGG CAT CCT GAG GTT TAT-3'	Bowles et al. (1992). [P1]
<i>cox1</i> , COX1, COI	JB4.5	5'-TAA AGA AAG AAC ATA ATG AAA ATG-3' 529 bp	
	F/COI	5'-TTG AAT TTG CCA CGT TTG AAT GC-3'	Nakao et al. (2000). [P2]
	R/COI	5'-GAA CCT AAC GAC ATA ACA TAA TGA-3' 880 bp	
Target gene: Mitochondrial NADH:ubiquinone oxidoreductase core subunit 1			
mt-ND1	JB11	5'-AGA TTC GTA AGG GGC CTA ATA-3'	Bowles and McManus (1993). [P3]
<i>nd1</i> , ND1, NAD1	JB12	5'-ACC ACT AAC TAA TTC ACT TTC-3' 529 bp	
	NAD1-FF	5'-ATT GKG TTA TTT CAG AGT TTT TCT GAT TTA-3'	Eberwein et al. (2013). [P4]
	NAD1-RR	5'-CTC MCC ATA ATC AAA TGG ACT ACG-3' 394 bp	
Target gene: Mitochondrial 12S rRNA			
mt-RNR1	60.for	5'-TTA AGA TAT ATG TGG TAC AGG ATT AGA TAC	von Nickisch-Roseneck et al. (1999). [P5]
<i>12S</i>	375.rev	CC-3' 5'-AAC CGA GGG TGA CGG GCG GTG TGT ACC-3' 357 bp	
	Cest3	5'-YGA YTC TTT TTA GGG GAA GGT GTG-3'	Trachsel et al. (2007). [P6]
	Cest5	5'-GCG GTG TGT ACM TGA GCT AAA C-3' 267 bp	
	CES12SF	5'-AGG GGA TAG GAC ACA GTG CCA GC-3'	Goldberg et al. (2014). [P7]
	CES12SR	5'-CGG TGT GTA CMT GAG YTA AAC-3' 480 bp	
	12S Taenia FF	5'-CAC AGT GCC AGC ATC YGC GGT-3'	Eberwein et al. (2013). [P8]
	12S Taenia RR	5'-GAG GGT GAC GGG CGG TGT GTA C-3' 426 bp	
Target gene: Ribosomal Internal Transcribed Spacer			
ITS2 <i>its2</i>	NC-2	5'-TTA GTT TCT TTT CCT CCG CT-3'	Gasser and Chilton (1995). [P9]
	NC-6	5'-ATC GAC ATC TTG AAC GCA CAT TGC-3' 600-700 bp	

Acknowledgments

The authors thank Teivi Laurimae and Alexander Mathis for their critical revision of the manuscript, Cristian Alvarez-Rojas for sequence analysis of a clinical sample (Institute of Parasitology, University of Zürich, Switzerland) and Bruno Gottstein (Institute of Parasitology,

University of Bern, Switzerland) for supplying DNA of a clinical case.

Appendix A. Supplementary data

Supplementary data to this article can be found online at <https://doi.org/10.1016/j.ijppaw.2019.03.013>.

References

- Abera, S., Wubit, T., Nejash, A., 2016. Cerebral coenurosis in small ruminants: a review. *J. Anim. Sci. Adv.* 6, 1595–1608.
- Abuladze, K.I., 1970. Taeniata of animals and man and diseases caused by them. In: In: Skrjabin, K.I. (Ed.), *Essentials of Cestodology*, vol. IV. Israel Program for Scientific Translations, Jerusalem, pp. 62–67.
- Al-Sabi, M.N.S., Jensen, P.M., Christensen, M.U., Kapel, C.M.O., 2015. Morphological and molecular analyses of larval taeniid species in small mammals from contrasting habitats in Denmark. *J. Helminthol.* 89, 112–117.
- Albert, T.F., Schueler, R.L., Panuska, J.A., Ingling, A.L., 1972. Tapeworm larvae (*Taenia crassiceps*) in woodchucks. *J. Am. Vet. Med. Assoc.* 161, 648–651.
- Alič, A., Hodžić, A., Škapur, V., Alić, S., Prašović, S., Duscher, G.G., 2017. Fatal pulmonary cysticercosis caused by *Cysticercus longicollis* in a captive ring-tailed lemur (*Lemur catta*). *Vet. Parasitol.* 241, 1–4.
- Alvarez, M.F., Iglesias, R., Garcia, J., Paniagua, E., Sanmartin, M.L., 1995. Intestinal helminths of the red fox (*Vulpes vulpes* L.) in Galicia (Northwest Spain). *Wiad. Parazytol.* 41, 429–442.
- Alvarez-Rojas, C.A., Mathis, A., Deplazes, P., 2018. Assessing the contamination of food and the environment with *Taenia* and *Echinococcus* eggs and their zoonotic transmission. *Curr. Clin. Micro. Rpt.* 5, 154–163.
- Andreassen, P.N.S., Schmidt, N.M., Kapel, C.M.O., Christensen, M.U., Sittler, B., Gilg, O., Enemark, H.L., Al-Sabi, M.N.S., 2017. Gastrointestinal parasites of two populations of Arctic foxes (*Vulpes lagopus*) from north-east Greenland. *Polar Res.* 36, 13.
- Arocker-Mettinger, E., Huber-Spitzy, V., Auer, H., Grabner, G., Stur, M., 1992. *Taenia crassiceps* in the anterior chamber of the human eye. A case report. *Klin. Monatsbl. Augenheilkd.* 201, 34–37.
- Bacigalupo, J., 1922. Sobre una nueva especie de *Taenia*, *Taenia infantis*. *Semana Med* 26, 726.
- Baer, G.J., Scheidegger, S., 1946. Un cas interessant de tetraplegie d'origine parasitaire. *Schweiz. Z. Path. Bakt.* 9, 61–66.
- Bagrađe, G., Kirjusina, M., Vismans, K., Ozolins, J., 2009. Helminth parasites of the wolf *Canis lupus* from Latvia. *J. Helminthol.* 83, 63–68.
- Ballek, D., Takla, M., Ising-Volmer, S., Stoye, M., 1992. The helminth fauna of red foxes (*Vulpes vulpes* Linnaeus 1758) in north Hesse and east Westphalia 1. *Cestodes. Dtsch. Tierarztl. Wochenschr.* 99, 362–365.
- Ballweber, L.R., 2009. *Taenia crassiceps* subcutaneous cysticercosis in an adult dog. *Vet. Rec.* 165, 693–694.
- Bamrunghphol, V., Little, M.D., Virayavejakul, A., Sujtanonm, M., Chaiyaporn, V., 1972. Juvenile strobilate tapeworm from the human spinal cord. Report of a case. *Am. J. Trop. Med. Hyg.* 21, 435–439.
- Barkati, S., Gottstein, B., Müller, N., Sheitoyan-Pesant, C., Metrakos, P., Chen, T., Garceau, R., Libman, M.D., Ndao, M., Yansouni, C.P., 2018. First human case of metacestode infection caused by *Versteria* sp. in a kidney transplant recipient. *Clin. Infect. Dis.* 68, 680–683.
- Basso, W., Rütten, M., Deplazes, P., Grimm, F., 2014. Generalized *Taenia crassiceps* cysticercosis in a chinchilla (*Chinchilla lanigera*). *Vet. Parasitol.* 199, 116–120.
- Battyany, I., Andrea, L., Nagy, K.K., 2010. Subcutaneous hydatid cyst in the popliteal fossa at the site of a previous wasp sting. *Diagn. Interv. Radiol.* 17, 163–165.
- Becklund, W.W., 1970. Current knowledge of the gid bladder worm, *Coenurus cerebralis* (= *Taenia multiceps*), in North American domestic sheep, *Ovis aries*. *Proc. Helm. Soc. Wash.* 37, 200–203.
- Beugnet, F., Delpon, B., Gevrey, J., Souchere, T., 2009. Note à propos d'un cas de cysticercose sous-cultanée chez un chien. *Rev. Med. Vet-Toulouse* 147, 227–232.
- Bjelić-Čabrilo, O., Kostić, D., Popović, E., Lujic, J., 2011. Helminth fauna of the bank vole *Myodes glareolus* (rodentia, arvicolineae) on the territory of fruska gora mountain (Serbia)-a potential source of zoonoses. *Bulg. J. Agric. Sci.* 17, 829–836.
- Bleyer, M., Risch, T., Roos, C., Kaup, F.J., Mätz-Rensing, K., 2018. *Taenia crassiceps* cysticercosis in a nilgiri langur (*Semnopithecus johnii*). *J. Zoo Wildl. Med.* 49, 501–504.
- Borgsteede, F.H., Tibben, J.H., van der Giessen, J.W., 2003. The musk rat (*Ondatra zibethicus*) as intermediate host of cestodes in The Netherlands. *Vet. Parasitol.* 117, 29–36.
- Boufana, B., Stidworthy, M.F., Bell, S., Chantrey, J., Masters, N., Unwin, S., Wood, R., Lawrence, R.P., Potter, A., McGarry, J., Redrobe, S., Killick, R., Foster, A.P., Mitchell, S., Greenwood, A.G., Sako, Y., Nakao, M., Ito, A., Wyatt, K., Lord, B., Craig, P.S., 2012. *Echinococcus* and *Taenia* spp. from captive mammals in the United Kingdom. *Vet. Parasitol.* 190, 95–103.
- Bowles, J., McManus, D.P., 1993. NADH dehydrogenase 1 gene sequences compared for species and strains of the genus *Echinococcus*. *Int. J. Parasitol.* 23, 969–972.
- Bowles, J., Blair, D., McManus, D.P., 1992. Genetic variants within the genus *Echinococcus* identified by mitochondrial DNA sequencing. *Mol. Biochem. Parasitol.* 54, 165–174.
- Brunet, P., Pesson, B., Chermette, R., Regnard, P., Grimm, F., Deplazes, P., Ferreira, X., Sabou, M., Pfaff, A.W., Abou-Bacar, A., Candolfi, E., 2014. First case of peritoneal cysticercosis in a non-human primate host (*Macaca tonkeana*) due to *Taenia martis*. *Parasites Vectors* 7, 422.
- Brunet, J., Benoît, A., Kremer, S., Dalvit, C., Lefebvre, N., Hansmann, Y., Chenard, M.P., Mathieu, B., Grimm, F., Deplazes, P., Pfaff, A.W., Abou-Bacar, A., Marescaux, C., Candolfi, E., 2015. First case of human cerebral *Taenia martis* cysticercosis. *J. Clin. Microbiol.* 53, 2756–2759.
- Bruzinskaite-Schmidhalter, R., Sarkunas, M., Malakauskas, A., Mathis, A., Torgerson, P.R., Deplazes, P., 2012. Helminths of red foxes (*Vulpes vulpes*) and raccoon dogs (*Nyctereutes procyonoides*) in Lithuania. *Parasitology* 139, 120–127.
- Bukova, A.M., 2006. Cestodes of wild carnivorous animals in the Omsk region. *Scientific Bulletin Omskiy nauchnyy vestnik* 7, 163–165.
- Burlet, P., Deplazes, P., Hegglin, D., 2011. Age, season and spatio-temporal factors affecting the prevalence of *Echinococcus multilocularis* and *Taenia taeniaeformis* in *Arvicola terrestris*. *Parasites Vectors* 4, 1–9.
- Chauchet, A., Grenouillet, F., Knapp, J., Richou, C., Delabrousse, E., Dentan, C., Millon, L., Di Martino, V., Contreras, R., Deconinck, E., Blagosklonov, O., Vuitton, D.A., Bresson-Hadni, S., Franc Echino Network, 2014. Increased incidence and characteristics of alveolar echinococcosis in patients with immunosuppression-associated conditions. *Clin. Infect. Dis.* 59, 1095–1104.
- Chautan, M., Pontier, D., Artois, M., 2000. Role of rabies in recent demographic changes in Red Fox (*Vulpes vulpes*) populations in Europe. *Mammalia* 64, 391–410.
- Chermette, R., Bussières, J., Mialot, M., Raynal, P.C., 1993. Subcutaneous *Taenia crassiceps* cysticercosis in a dog. *J. Am. Vet. Med. Assoc.* 203, 263–265.
- Chermette, R., Bussières, J., Marionneau, J., Boyer, E., Roubin, C., Prophette, B., Maillard, H., Fabiani, B., 1995. Invasive cysticercosis due to *Taenia crassiceps* in an AIDS patient. *Bull. Acad. Natl. Med.* 179, 777–780.
- Chile, N., Clark, T., Arana, Y., Ortega, Y.R., Palma, S., Mejia, A., Angulo, N., Kosek, J.C., Kosek, M., Gomez-Puerta, L.A., Garcia, H.H., Gavidia, C.M., Gilman, R.H., Verastegui, M., Cysticercosis Working Group in Peru, 2016. In vitro study of *Taenia solium* postoncospherical form. *PLoS Neglected Trop. Dis.* 10, e0004396.
- Christodouloupoulos, G., Kassab, A., Theodoropoulos, G., 2013. Occurrence of non-cerebral coenurosis in sheep. *J. Helminthol.* 87, 125–127.
- Chuck, R.S., Olk, R.J., Weil, G.J., Akduman, L., Benenson, I.L., Smith, M.E., Kaplan, H.J., 1997. Surgical removal of a subretinal proliferating cysticercus of *Taeniaformis crassiceps*. *Arch. Ophthalmol.* 115, 562–563.
- Cirovic, D., Pavlovic, I., Penezic, A., 2015a. Intestinal helminth parasites of the grey wolf (*Canis lupus* L.) in Serbia. *Acta Vet. Hung.* 63, 189–198.
- Cirovic, D., Pavlovic, I., Penezic, A., Kulisic, Z., Selakovic, S., 2015b. Levels of infection of intestinal helminth species in the golden jackal *Canis aureus* from Serbia. *J. Helminthol.* 89, 28–33.
- Clapham, P.A., 1940a. Studies on coenurus glomeratus. *J. Helminthol.* 18, 45–52.
- Clapham, P.A., 1940b. Further studies on coenurus glomeratus. *J. Helminthol.* 18, 95–102.
- Clark, J.D., 1969. Coenurosis in a gelada baboon (*Theropithecus gelada*). *J. Am. Vet. Med. Assoc.* 155, 1258–1263.
- Collomb, J., Machouart, M., Biava, M.F., Brizion, M., Montagne, K., Plenat, F., Fortier, B., 2007. Contribution of NADH dehydrogenase subunit I and cytochrome C oxidase subunit I sequences toward identifying a case of human coenurosis in France. *J. Parasitol.* 93, 934–937.
- Connor, D.H., Sparks, A.K., Strano, A.J., Neafie, R.C., Juvelier, B., 1976. Disseminated parasitosis in an immunosuppressed patient: possibly a mutated sparganum. *Arch. Pathol. Lab Med.* 100, 65–68.
- Craig, H.L., Craig, P.S., 2005. Helminth parasites of wolves (*Canis lupus*): a species list and an analysis of published prevalence studies in Nearctic and Palaearctic populations. *J. Helminthol.* 79, 95–103.
- Dalimi, A., Sattari, A., Motamedi, G., 2006. A study on intestinal helminths of dogs, foxes and jackals in the western part of Iran. *Vet. Parasitol.* 142, 129–133.
- De Liberato, C., Berrilli, F., Meoli, R., Friedrich, K.G., Di Cerbo, P., Cocumelli, C., Eleni, C., 2014. Fatal infection with *Taenia martis* metacestodes in a ring-tailed lemur (*Lemur catta*) living in an Italian zoological garden. *Parasitol. Int.* 63, 695–697.
- Denk, D., Boufana, B., Masters, N.J., Stidworthy, M.F., 2016. Fatal echinococcosis in three lemurs in the United Kingdom-A case series. *Vet. Parasitol.* 218, 10–14.
- Deplazes, P., Eckert, J., Mathis, A., von Samson-Himmelstjerna, G., Zahner, H., 2016. *Parasitology in Veterinary Medicine*. Wageningen Academic Publishers, Wageningen, The Netherlands.
- Dominguez-Roldan, R., Pérez-Martínez, M., Rosetti, M.F., Arias-Hernández, D., Bernal-Fernández, G., Flores-Pérez, F.I., Hallal-Calleros, C., 2018. High frequency of *Taenia pisiformis* metacestodes and high sex-associated susceptibility to cysticercosis in naturally infected wild rabbits. *Parasitol. Res.* 117, 2201–2206.
- Dunbar, R.I.M., 1980. Demographic and life history variables of a population of gelada baboons (*Theropithecus gelada*). *J. Anim. Ecol.* 49, 485–506.
- Dunsmore, J.D., Howkins, A.B., 1968. *Coenurus serialis* in a grey kangaroo. *Aust. Vet. J.* 30, 465.
- Dyachenko, V., Pantchev, N., Gawłowska, S., Vrhovec, M.G., Bauer, C., 2008. *Echinococcus multilocularis* infections in domestic dogs and cats from Germany and other European countries. *Vet. Parasitol.* 157, 244–253.
- Dyer, N.W., Greve, J.H., 1998. Severe *Cysticercus longicollis* cysticercosis in a black lemur (*Eulemur macaco macaco*). *J. Vet. Diagn. Investig.* 10, 362–364.
- Eberwein, P., Haeupler, A., Kuepper, F., Wagner, D., Kern, W.V., Muntau, B., Racz, P., Agostini, H., Poppert, S., 2013. Human infection with marten tapeworm. *Emerg. Infect. Dis.* 19, 1152–1154.
- El-Shehaby, F.S., Abdel-Hafez, S.K., Kamhawi, S.A., 1999. Prevalence of intestinal helminths of dogs and foxes from Jordan. *Parasitol. Res.* 85, 928–934.
- Elek, S.R., Finkelstein, L.E., 1939. *Multiceps serialis* infestation in a baboon. Report of a case exhibiting connective tissue cystic masses. *Zoologica* 24, 323–328.
- Fain, A., 1956. Coenurus of *Taenia brauni* Setti parasitic in man and animals from the Belgian Congo and Ruanda-Urundi. *Nature* 178, 1353.
- Federer, K., Armua-Fernandez, M.T., Hoby, S., Wenker, C., Deplazes, P., 2015. In vivo viability of *Echinococcus multilocularis* eggs in a rodent model after different thermo-treatments. *Exp. Parasitol.* 154, 14–19.
- Federer, K., Armua-Fernandez, M.T., Gori, F., Hoby, S., Wenker, C., Deplazes, P., 2016. Detection of taeniid (*Taenia* spp., *Echinococcus* spp.) eggs contaminating vegetables and fruits sold in European markets and the risk for metacestode infections in captive primates. *Int. J. Parasitol. Parasites Wildl.* 5, 249–253.
- Feliu, C., Renaud, F., Catzeffis, F., Hugot, J.-P., Durand, P., Morand, S., 1997. A comparative analysis of parasite species richness of Iberian rodents. *Parasitology* 115, 453–466.
- Flammer Anikpeh, Y., Grimm, F., Lindenblatt, N., Zinkernagel, A., 2014. It isn't always

- caivari. *BMJ Case Rep.*
- Flisser, A., Craig, P.S., Ito, A., 2011. Cysticercosis and taeniosis: *Taenia solium*, *Taenia saginata* and *Taenia asiatica*. In: Palmer, S.R., Soulsby, L., Torgerson, P.R., Brown, D.W.G. (Eds.), *Oxford Textbook of Zoonoses Biology, Clinical Practice, and Public Health Control*. Oxford University Press, pp. 625–649.
- Francois, A., Favennec, L., Cambon-Michot, C., Gueit, I., Biga, N., Tron, F., Brasseur, P., Hemet, J., 1998. *Taenia crassiceps* invasive cysticercosis: a new human pathogen in acquired immunodeficiency syndrome? *Am. J. Surg. Pathol.* 22, 488–492.
- Freeman, R.S., 1956. Life history studies on *Taenia mustelae* Gmelin, 1790, and the taxonomy of certain taenioid cestodes from mustelidae. *Can. J. Zool.* 34, 219–242.
- Freeman, R.S., 1961. Cestodes of wolves, coyotes and coyote-dog hybrids in Ontario. *Can. J. Zool.* 39, 527–532.
- Freeman, R.S., 1962. Studies on the biology of *Taenia crassiceps* (Zeder, 1800) Rudolphi, 1810 (Cestoda). *Can. J. Zool.* 40, 969–990.
- Freeman, R.S., Fallis, A.M., Shea, M., Maberley, A.L., Walters, J., 1973. Intraocular *Taenia crassiceps* (Cestoda). II. The parasite. *Am. J. Trop. Med. Hyg.* 22, 493–495.
- Fuentes, M.V., Sáez, S., Trellis, M., Galán-Puchades, M.T., Esteban, J.G., 2004. The helminth community of the wood mouse, *Apodemus sylvaticus*, in the Sierra Espuña, Murcia, Spain. *J. Helminthol.* 78, 219–223.
- Gasser, R.B., Chilton, N.B., 1995. Characterisation of taeniid cestode species by PCR-RFLP of ITS2 ribosomal DNA. *Acta Trop.* 59, 31–40.
- Geiger, M., Taucher, A.T., Gloor, G., Hegglin, D., Bontadina, B., 2018. In the footsteps of city foxes: evidence for a rise of urban badger populations in Switzerland. *Hystrix* it. *J. Mammal.* 29, 236–238.
- Gillis-Germitsch, N., Schnyder, M., 2018. The spread of *Angiostrongylus vasorum* in the Swiss fox population in the last 30 years. In: *Proceedings of the 6th European Dirofilaria and Angiostrongylus Days*, Belgrade, Serbia.
- Goessinger, N., Lindenblatt, N., Mihic-Probst, D., Grimm, F., Giovanoli, P., 2011. *Taenia crassiceps* upper limb fasciitis in a patient with untreated AIDS and chronic hepatitis C infection - the role of surgical debridement. *J. Plast. Reconstr. Aesthet. Surg.* 64, 174–176.
- Goldberg, T.L., Gendron-Fitzpatrick, A., Deering, K.M., Wallace, R.S., Clyde, V.L., Lauck, M., 2014. Fatal metacestode infection in Bornean orangutan caused by unknown *Versteria* species. *Emerg. Infect. Dis.* 20, 109–113.
- Gori, F., Armua-Fernandez, M.T., Milanese, P., Serafini, M., Magi, M., Deplazes, P., Macchioni, F., 2015. The occurrence of taeniids of wolves in Liguria (northern Italy). *Int. J. Parasitol. Parasites Wildl.* 4, 252–255.
- Gottstein, B., Stojkovic, M., Vuitton, D.A., Millon, L., Marcinkute, A., Deplazes, P., 2015. Threat of alveolar echinococcosis to public health—a challenge for Europe. *Trends Parasitol.* 31, 407–412.
- Guberti, V., Stancampiano, L., Francisci, F., 1993. Intestinal helminth parasite community in wolves (*Canis lupus*) in Italy. *Parassitologia* 35, 59–65.
- Guerra, D., Armua-Fernandez, M.T., Silva, M., Bravo, I., Santos, N., Deplazes, P., Carvalho, L.M., 2013. Taeniid species of the Iberian wolf (*Canis lupus signatus*) in Portugal with special focus on *Echinococcus* spp. *Int. J. Parasitol. Parasites Wildl.* 2, 50–53.
- Hauser, M., Basso, W., Deplazes, P., 2015. Dog and fox faecal contamination of farmland. *Schweiz. Arch. Tierheilkd.* 157, 449–455.
- Hayes, M.A., Creighton, S.R., 1978. A coenurus in the brain of a cat. *Can. Vet. J.* 19, 341–343.
- Hegglin, D., Deplazes, P., 2013. Control of *Echinococcus multilocularis*: strategies, feasibility and cost-benefit analyses. *Int. J. Parasitol.* 43, 327–337.
- Heldwein, K., Biedermann, H.G., Hamperl, W.D., Bretzel, G., Loscher, T., Laregina, D., Frosch, M., Buttner, D.W., Tappe, D., 2006. Subcutaneous *Taenia crassiceps* infection in a patient with non-Hodgkin's lymphoma. *Am. J. Trop. Med. Hyg.* 75, 108–111.
- Henke, S., Pence, D.B., Bryant, F.C., 2002. Effect of short-term coyote removal on populations of coyote helminths. *J. Wildl. Dis.* 38, 54–67.
- Herbert, I.V., Edwards, G.T., Willis, J.M., 1984. Some host factors which influence the epidemiology of *Taenia multiceps* infections in sheep. *Ann. Trop. Med. Parasitol.* 78, 243–248.
- Hermosilla, C., Kleinertz, S., Silva, L.M., Hirtzmann, J., Huber, D., Kusak, J., Taubert, A., 2017. Protozoan and helminth parasite fauna of free-living Croatian wild wolves (*Canis lupus*) analyzed by scat collection. *Vet. Parasitol.* 233, 14–19.
- Hobbs, T.R., Colgin, L.M.A., Maginnis, G.M., Lewis, A.D., 2003. Abdominal cysticercosis in a rhesus macaque (*Macaca mulata*). *Comp. Med.* 53, 545–547.
- Hoberg, E.P., Ebinger, W., Render, J.A., 1999. Fatal cysticercosis by *Taenia crassiceps* (Cyclophyllidae: Taeniidae) in a presumed immunocompromised canine host. *J. Parasitol.* 85, 1174–1178.
- Hofer, S., Gloor, S., Müller, U., Mathis, A., Hegglin, D., Deplazes, P., 2000. High prevalence of *Echinococcus multilocularis* in urban red foxes (*Vulpes vulpes*) and voles (*Arvicola terrestris*) in the city of Zurich, Switzerland. *Parasitology* 120, 135–142.
- Hough, I., 2000. Subcutaneous larval *Taenia serialis* in a ring-tailed possum (*Pseudocheirus peregrinus*). *Aust. Vet. J.* 78, 468–468.
- Hubbard, G.B., Gardiner, C.H., Bellini, S., Ehler, W.J., Conn, D.B., King, M.M., 1993. Mesocestoides infection in captive olive baboons (*Papio cynocephalus anubis*). *Lab. Anim. Sci.* 43, 625–627.
- Huss, B.T., Miller, M.A., Corwin, R.M., Hoberg, E.P., O'Brien, D.P., 1994. Fatal cerebral coenurosis in a cat. *J. Am. Vet. Med. Assoc.* 205, 69–71.
- Ihama, Y., Sato, H., Makino, Y., Kamiya, H., 2000. Two *Taenia* species found in Japan, with new distribution record of *Taenia polyacantha* Leuckart, 1856 (Cestoda: Taeniidae). *Parasitol. Int.* 48, 303–306.
- Ing, M.B., Schantz, P.M., Turner, J.A., 1998. Human coenurosis in North America: case reports and review. *Clin. Infect. Dis.* 27, 519–523.
- Itin, G.S., Kravchenko, V.M., Shantiz, A.Y., 2018. Characteristics of helminth infections of american mink (*Mustela vison*), raccoon (*Procyon lotor*) and wolf (*Canis lupus*) on the territory of the North-Western Caucasus. *Sci. J. KubSAU.* 136.
- Jenkins, D.J., Lievaart, J.J., Boufana, B., Lett, W.S., Bradshaw, H., Armua-Fernandez, M.T., 2014. *Echinococcus granulosus* and other intestinal helminths: current status of prevalence and management in rural dogs of eastern Australia. *Aust. Vet. J.* 92, 292–298.
- Jones, A., Walters, T.M., 1992a. A survey of taeniid cestodes in farm dogs in mid-Wales. *Ann. Trop. Med. Parasitol.* 86, 137–142.
- Jones, A., Walters, T.M., 1992b. The cestodes of foxhounds and foxes in Powys, mid-Wales. *Ann. Trop. Med. Parasitol.* 86, 143–150.
- Joyeux, C., Baer, J.G., 1929. Les cestodes rares de l'homme. *Bull. Soc. Path. Exot.* 22, 114–136.
- Kern, P., Menezes da Silva, A., Akhan, O., Müllhaupt, B., Vizcaychipi, K.A., Budke, C., Vuitton, D.A., 2017. The *Echinococcoses*: diagnosis, clinical management and Burden of disease. *Adv. Parasitol.* 96, 259–369.
- Klinker, H., Tintelnot, K., Joeres, R., Müller, J., Gross, U., Schmidt-Rotte, H., Landwehr, P., Richter, E., 1992. *Taenia crassiceps* infection in AIDS. *Dtsch. Med. Wochenschr.* 117, 133–138.
- Koch, T., Schoen, C., Muntau, B., Addo, M., Ostertag, H., Wiechens, B., Tappe, D., 2016. Molecular diagnosis of human *Taenia martis* eye infection. *Am. J. Trop. Med. Hyg.* 94, 1055–1057.
- Konjević, D., Živičnjak, T., Kurilj, A.G., Sindičić, M., Martinković, F., Jan, D.S., 2016. When things go wrong: cysticercus longicollis in an adult wild red fox (*Vulpes vulpes*). *Parasitol. Res.* 115, 1345–1348.
- Kornaš, S., Wierzbowska, I.A., Górski, P., Okarma, H., 2013. Occurrence of internal parasites in stone martens (*Martes foina*) from Cracow and suburbs. *Ann. Parasitol.* 59, 203–205.
- Krücken, J., Blümke, J., Maaz, D., Demeler, J., Ramünke, S., Antolová, D., Schaper, R., von Samson-Himmelstjerna, G., 2017. Small rodents as paratenic or intermediate hosts of carnivore parasites in Berlin, Germany. *PLoS One* 12, e0172829.
- Lafferty, K.D., 1999. The evolution of trophic transmission. *Parasitol. Today* 15, 111–115.
- Lau, D.T., Casey, W.J., Jones, M.D., 1973. Coenurosis in a whitehanded gibbon. *J. Am. Vet. Med. Assoc.* 163, 633–635.
- Le Pesteur, M.H., Girardoux, P., Delattre, P., Damange, J.P., Quéré, J.P., 1992. Spatiotemporal distribution of four species of cestodes in a landscape of mid-altitude mountains (Jura, France). *Ann. Parasitol. Hum. Comp.* 67, 155–160.
- Lee, L.M., Wallace, R.S., Clyde, V.L., Gendron-Fitzpatrick, A., Sibley, S.D., Stuchin, M., Lauck, M., O'Connor, D.H., Nakao, M., Lavikainen, A., Hoberg, E.P., Goldberg, T.L., 2016. Definitive hosts of *Versteria* tapeworms (Cestoda: Taeniidae) causing fatal infection in North America. *Emerg. Infect. Dis.* 22, 707–710.
- Lehman, B.D.O., Leal, S., Procop, G.W., O'Connell, E.M., Nash, T., Jones, S., Braunthal, S., Cruise, M., Mukhopadhyay, S., Banzon, J., 2018. Disseminated metacestode infection due to an unknown *Versteria* species. In: *Proceedings of the IDWeek 2018*, Washington, USA.
- Leiby, P.D., Whittaker, F.H., 1966. Occurrence of *Taenia crassiceps* in the conterminous United States. *J. Parasitol.* 52, 786.
- Leith, J.D., Satterfield, W.C., 1974. Coenurus cysts of *Taenia multiceps* in a baboon, *Theropithecus gelada*. *J. Zoo Anim. Med.* 5, 32–34.
- Lescano, A.G., Zunt, J., 2013. Other cestodes: sparganosis, coenurosis and *Taenia crassiceps* cysticercosis. *Handb. Clin. Neurol.* 114, 335–345.
- Li, W., Guo, Z., Duo, H., Fu, Y., Peng, M., Shen, X., Tsukada, H., Irie, T., Nasu, T., Horii, Y., Nonaka, N., 2013. Survey on helminths in the small intestine of wild foxes in Qinghai, China. *J. Vet. Med. Sci.* 75, 1329–1333.
- Liccioli, S., Bialowas, C., Ruckstuhl, K.E., Massolo, A., 2015. Feeding ecology informs parasite epidemiology: prey selection modulates encounter rate with *Echinococcus multilocularis* in urban coyotes. *PLoS One* 10, e0212646.
- Loos-Frank, B., 2000. An up-date of Verster's (1969) Taxonomic revision of the genus *Taenia* Linnaeus' (Cestoda) in table format. *Styct. Parasitol.* 45, 155–183.
- Loos-Frank, B., Zeyhle, E., 1982. The intestinal helminths of the red fox and some other carnivores in southwest Germany. *Z. Parasitenkd.* 67, 99–113.
- Loos-Frank, B., Zeyhle, E., 1981. Zur Parasitierung von 3603 Rotfüchsen in Württemberg. *Z. Jagdwiss* 27, 258–266.
- Loxton, K.C., Lawton, C., Stafford, P., Holland, C.V., 2017. Parasite dynamics in an invaded ecosystem: helminth communities of native wood mice are impacted by the invasive bank vole. *Parasitology* 144, 1476–1489.
- Luong, L.T., Chambers, J.L., Moizis, A., Stock, T.M., St Clair, C.C., 2018. Helminth parasites and zoonotic risk associated with urban coyotes (*Canis latrans*) in Alberta, Canada. *J. Helminthol.* 1–5.
- Luzón, M., de la Fuente-Lopez, C., Martinez-Navado, E., Fernandez-Moran, J., Ponce-Gordo, F., 2010. *Taenia crassiceps* cysticercosis in a ring-tailed lemur (*Lemur catta*). *J. Zoo Wildl. Med.* 41, 327–330.
- Mackenstedt, U., Jenkins, D., Romig, T., 2015. The role of wildlife in the transmission of parasitic zoonoses in peri-urban and urban areas. *Int. J. Parasitol. Parasites Wildl.* 4, 71–79.
- Maillard, H., Marionneau, J., Prophette, B., Boyer, E., Celerier, P., 1998. *Taenia crassiceps* cysticercosis and AIDS. *AIDS* 20, 1551–1552.
- Mathy, A., Hanosset, R., Adant, S., Losson, B., 2009. The carriage of larval *Echinococcus multilocularis* and other cestodes by the muskrat (*Ondatra zibethicus*) along the Ourthe River and its tributaries (Belgium). *J. Wildl. Dis.* 45, 279–287.
- Millan, J., Real, C.E., Ferroglio, E., 2001. Helminth parasites in stone martens (*Martes foina*) from Italy. *Z. Jagdwiss.* 47, 229–231.
- Miller, A.L., Olsson, G.E., Walburg, M.R., Sollenberg, S., Skarin, M., Ley, C., Wahlström, H., Höglund, J., 2016. First identification of *Echinococcus multilocularis* in rodent intermediate hosts in Sweden. *Int. J. Parasitol. Parasites Wildl.* 5, 56–63.
- Miller, A.L., Olsson, G.E., Sollenberg, S., Walburg, M.R., Skarin, M., Höglund, J., 2017. Transmission ecology of taeniid larval cestodes in rodents in Sweden, a low endemic area for *Echinococcus multilocularis*. *Parasitology* 144, 1041–1051.
- Moks, E., Jogisalu, I., Saarma, U., Talvik, H., Jarvis, T., Valdmann, H., 2006.

- Helminthologic survey of the wolf (*Canis lupus*) in Estonia, with an emphasis on *Echinococcus granulosus*. J. Wildl. Dis. 42, 359–365.
- Montalbano Di Filippo, M., Meoli, R., Cavallero, S., Eleni, C., De Liberato, C., Berrilli, F., 2018. Molecular identification of Mesocestoides sp. metacestodes in a captive gold-handled tamarin (*Saguinus midas*). Infect. Genet. Evol. 65, 399–405.
- Morales, J., Velasco, T., Tovar, V., Frago, G., Fleury, A., Beltrán, C., Villalobos, N., Aluja, A., Rodarte, L.F., Sciutto, E., Larralde, C., 2002. Castration and pregnancy of rural pigs significantly increase the prevalence of naturally acquired *Taenia solium* cysticercosis. Vet. Parasitol. 108, 41–48.
- Morales-Montor, J., Baig, S., Hallal-Calleros, C., Damian, R.T., 2002. *Taenia crassiceps*: androgen reconstitution of the host leads to protection during cysticercosis. Exp. Parasitol. 100, 209–216.
- Morel, P., 1959. Les helminthes des animaux domestiques de l'Afrique occidentale. Rev. Elev. Med. Vet. Pay. 12, 153–174.
- Moro, P.L., Ballarta, J., Gilman, R.H., Leguia, G., Rojas, M., Montes, G., 1998. Intestinal parasites of the grey fox (*Pseudalopex culpaeus*) in the central Peruvian Andes. J. Helminthol. 72, 87–89.
- Moshiri, A., Shamsian, S., Berenji, F., Jadidoleslami, A., Moghadda, E., 2018. Coenurus serialis in northeastern Iran: a probable danger to human. Int. J. Infect. 5, e13218.
- Mougeot, G., Cambon, M., Dimeglio, V., Menerath, J.M., 1996. Intraocular cestode larva in a 14-year-old boy in Auvergne. Presse Med. 25, 1168.
- Nabavi, R., Manouchehri Naeini, K., Zebardast, N., Hashemi, H., 2014. Epidemiological study of gastrointestinal helminths of canids in chaharmahal and bakhtiari province of Iran. Iran. J. Parasitol. 9, 276–281.
- Nagy, A., Ziadinov, I., Schweiger, A., Schnyder, M., Deplazes, P., 2011. Hair coat contamination with zoonotic helminth eggs of farm and pet dogs and foxes. Berl. Münchener Tierärztliche Wochenschr. 124, 503–511.
- Nakao, M., Sako, Y., Yokoyama, N., Fukunaga, M., Ito, A., 2000. Mitochondrial genetic code in cestodes. Mol. Biochem. Parasitol. 111, 415–424.
- Nakao, M., Lavikainen, A., Iwaki, T., Haukisalml, V., Konyayev, S., Oku, Y., 2013. Molecular phylogeny of the genus *Taenia* (Cestoda: Taeniidae): proposals for the resurrection of *Hydatigera* Lamarck, 1816 and the creation of a new genus *Versteria*. Int. J. Parasitol. 43, 427–437.
- Ntoukas, V., Tappe, D., Pfütze, D., Simon, M., Holzmann, T., 2013. Cerebellar cysticercosis caused by larval *Taenia crassiceps* tapeworm in immunocompetent woman, Germany. Emerg. Infect. Dis. 19, 2008–2011.
- Odnokurtsev, V.A., Sedalischev, V.T., 2011. Helminthes fauna of sable (*Martes zibellina* Linnaeus, 1758) in Yakutia. Tomsk State Univ. J. Biol. 2, 22–34.
- Olson, P.D., Yoder, K., Fajardo, L.-G.L.F., Marty, A.M., van de Pas, S., Olivier, C., Relman, D.A., 2003. Lethal invasive cestodiasis in immunosuppressed patients. J. Infect. Dis. 187, 1962–1966.
- Orihel, T.C., Ash, L.R., 1995. Parasites in Human Tissues. ASCP Press, Chicago.
- Orioles, M., Beltran, E., Stewart, J., Boufana, B., Holloway, A., 2014. Cerebral coenurosis in a cat. Vet. Rec. Case Rep. 2, e000124.
- Otranto, D., Cantacessi, C., Pfeffer, M., Dantas-Torres, F., Brianti, E., Deplazes, P., Genchi, C., Guberti, V., Capelli, G., 2015a. The role of wild canids and felids in spreading parasites to dogs and cats in Europe. Part I: Protozoa and tick-borne agents. Vet. Parasitol. 213, 12–23.
- Otranto, D., Cantacessi, C., Dantas-Torres, F., Brianti, E., Pfeffer, M., Genchi, C., Guberti, V., Capelli, G., Deplazes, P., 2015b. The role of wild canids and felids in spreading parasites to dogs and cats in Europe. Part II: helminths and arthropods. Vet. Parasitol. 213, 24–37.
- Paoletti, B., Iorio, R., Traversa, D., Di Francesco, C.E., Gentile, L., Angelucci, S., Amicucci, C., Bartolini, R., Marangi, M., Di Cesare, A., 2017. Helminth infections in faecal samples of Apennine wolf (*Canis lupus italicus*) and Marsican brown bear (*Ursus arctos marsicanus*) in two protected national parks of central Italy. Ann. Parasitol. 63, 205–212.
- Pétavy, A.F., Deblock, S., 1980. Helminths of the common fox (*Vulpes vulpes* L.) from the massif central (France). Ann. Parasitol. Hum. Comp. 55, 379–391.
- Pétavy, A.F., Deblock, S., Prost, C., 1990. Epidemiology of alveolar echinococcosis in France. 1. Intestinal helminths in the red fox (*Vulpes vulpes* L.) from Haute-Savoie. Ann. Parasitol. Hum. Comp. 65, 22–27.
- Pfaffenberger, G.S., Valencia, V.B., 1988. Helminths of sympatric black-tailed jack rabbits (*Lepus californicus*) and desert cottontails (*Sylvilagus audubonii*) from the high plains of eastern New Mexico. J. Wildl. Dis. 24, 375–377.
- Pfeiffer, F., Kuschfeldt, S., Stoye, M., 1997. Helminth fauna of the red fox (*Vulpes vulpes* LINNE 1758) in south Sachsen-Anhalt -1: Cestodes. Dtsch. Tierärztl. Wochenschr. 104, 445–448.
- Railliet, A., Marullaz, M., 1919. Sur un Cénure nouveau du Bonnet chinois (*Macacus sinicus*). B. Soc. Pathol. Exot. 12, 223–228.
- Reperant, L.A., Hegglin, D., Tanner, I., Fischer, C., Deplazes, P., 2009. Rodents as shared indicators for zoonotic parasites of carnivores in urban environments. Parasitology 136, 329–337.
- Ribas, A., Torre, I., Feliu, C., Arrizabalaga, A., Casanova, J.C., 2009. Helminth communities of the bank vole *Myodes glareolus* in two populations: Montseny natural park (NE Spain) and Pi Natural reserve (French Pyrenees). Rev. Ibero-Latinoam. Parasitol. Int. 1, 73–89.
- Richards, D.T., Harris, S., Lewis, J.W., 1995. Epidemiological studies on intestinal helminth parasites of rural and urban red foxes (*Vulpes vulpes*) in the United Kingdom. Vet. Parasitol. 59, 39–51.
- Romig, T., Deplazes, P., Jenkins, D., Giraudoux, P., Massolo, A., Craig, P.S., Wassermann, M., Takahashi, K., De La Rue, M., 2017. Ecology and life cycle patterns of *Echinococcus* species. Adv. Parasitol. 95, 213–314.
- Ross, J.G., Fairley, J.S., 1969. Studies of disease in the red fox (*Vulpes vulpes*) in northern Ireland. J. Zool. 157, 375–381.
- Rudelius, M., Brehm, K., Poelcher, M., Spinner, C., Rosenwald, A., da Costa, C.P., 2017. First case of human peritoneal cysticercosis mimicking peritoneal carcinosis: necessity of laparoscopy and histologic assessment for the correct diagnosis. JMM Case Rep. 4, e005097.
- Sailer, M., Soelder, B., Allerberger, F., Zaknun, D., Feichtinger, H., Gottstein, B., 1997. Alveolar echinococcosis of the liver in a six-year-old girl with acquired immunodeficiency syndrome. J. Pediatr. 130, 320–323.
- Sandground, J.H., 1937. On a coenurus from the brain of a monkey. J. Parasitol. 23, 482–490.
- Scala, A., Varcasia, A., 2006. Updates on morphobiology, epidemiology and molecular characterization of coenurosis in sheep. Parasitologia 48, 61–63.
- Schaerer, O., 1987. Die Metacestoden der Kleinsäuger (Insectivora und Rodentia) und ihre Wirtsarten, Verbreitung und Häufigkeit im Kanton Thurgau (Schweiz). Dissertation. University of Zurich, Zurich, Switzerland.
- Schantz, P.M., Alstine, C.V., Blacksheep, A., Sinclair, S., 1977. Prevalence of *Echinococcus granulosus* and other cestodes in dogs on the Navajo reservation in Arizona and New Mexico. Am. J. Vet. Res. 38, 669–670.
- Schellhas, K.P., Norris, G.A., 1985. Disseminated human subarachnoid coenurosis: computed tomographic appearance. Am. J. Neuroradiol. 6, 638–640.
- Schmid, S., Grimm, F., Huber, M., Beck, B., Custer, P., Bode, B., 2014. *Taenia crassiceps* infection - an unusual presentation of a tapeworm diagnosed by FNA cytology and PCR. Cytopathology 25, 340–341.
- Schneider-Crease, I.A., Snyder-Mackler, N., Jarvey, J.C., Bergman, T.J., 2013. Molecular identification of *Taenia serialis* coenurosis in a wild Ethiopian gelada (*Theropithecus gelada*). Vet. Parasitol. 198, 240–243.
- Schuster, R., Benitz, R., 1992. On the development of *Taenia martis* (Zeder, 1803) in the intermediate host. Helminthologia 29, 13–18.
- Schuster, R., Heidecke, D., Schierhorn, K., 1993. Contribution to the parasite fauna of local hosts. On the endoparasitic fauna of *Felis silvestris*. Appl. Parasitol. 34, 113–120.
- Schuster, R.K., Sivakumar, S., Wieckowsky, T., 2010. Non-cerebral coenurosis in goats. Parasitol. Res. 107, 721–726.
- Schwartz, B., 1927. A subcutaneous tumor in a primate caused by tapeworm larvae experimentally reared to maturity in dogs. J. Agric. Res. 35, 471–480.
- Schweiger, A., Ammann, R.W., Candinas, D., Clavien, P.A., Eckert, J., Gottstein, B., Halkic, N., Muellhaupt, B., Prinz, B.M., Reichen, J., Tarr, P.E., Torgerson, P.R., Deplazes, P., 2007. Human alveolar echinococcosis after fox population increase, Switzerland. Emerg. Infect. Dis. 13, 878–882.
- Schweizer, G., Grunenfelder, F., Sydlar, T., Rademacher, N., Braun, U., Deplazes, P., 2006. Imported coenurosis in sheep. Schweiz. Arch. Tierheilkd. 148, 490–499.
- Sedalischev, V.T., Odnokurtsev, V.A., 2011. Ecology of sable (*Martes zibellina* L., 1758) of southwestern Yakutia. Vestnik okhotovedeniya 8.
- Sedalischev, V.T., Odnokurtsev, V.A., 2013. On Ecology of Red Fox (*Vulpes vulpes* L. 1758) in Yakutia, vol. 3 Izvestia of Samara Scientific Center of the Russian Academy of Sciences.
- Segovia, J.M., Torres, J., Miquel, J., Llana, L., Feliu, C., 2001. Helminths in the wolf, *Canis lupus*, from north-western Spain. J. Helminthol. 75, 183–192.
- Segovia, J.M., Guerrero, R., Torres, J., Miquel, J., Feliu, C., 2003. Ecological analyses of the intestinal helminth communities of the wolf, *Canis lupus*, in Spain. Folia Parasitol. 50, 231–236.
- Segovia, J.M., Torres, J., Miquel, J., 2004. Helminth parasites of the red fox (*Vulpes vulpes* L., 1758) in the Iberian Peninsula: an ecological study. Acta Parasitol. 49, 67–79.
- Sharma, S., Lyngdoh, D., Roy, B., Tandon, V., 2016. Molecular phylogeny of Cyclophyllidae (Cestoda: Eucestoda): an in-silico analysis based on mtCOI gene. Parasitol. Res. 115, 3329–3335.
- Shea, M., Maberley, A.L., Walters, J., Freeman, R.S., Fallis, A.M., 1973. Intraocular *Taenia crassiceps* (Cestoda). Trans. Am. Acad. Ophthalmol. Otolaryngol. 77, 778–783.
- Shimalov, V.V., 2010. *Taenia martis* (Cestoda, Taeniidae) from vertebrates in the Republic of Belarus. Parasitologiya 44, 435–440.
- Shimalov, V.V., 2016. New data about the helminth fauna of the red squirrel (*Sciurus vulgaris* Linnaeus, 1758) in Belorussian Polesie. J. Parasit. Dis. 40, 1620–1621.
- Slais, J., 1973. Functional morphology of cestode larvae. Adv. Parasitol. 11, 395–480.
- Slocome, R.F., Arundel, J.H., Labuc, R., Doyle, M.K., 1989. Cerebral coenurosis in a domestic cat. Aust. Vet. J. 66, 92–93.
- Smith, H.J., 1978. Parasites of red foxes in new Brunswick and Nova Scotia. J. Wildl. Dis. 14, 366–370.
- Smith, M.C., Bailey, C.S., Baker, N., Kock, N., 1988. Cerebral coenurosis in a cat. J. Am. Vet. Med. Assoc. 192, 82–84.
- Soveri, T., Henttonen, H., Rudbäck, E., Schildt, R., Tanskanen, R., Husu-Kallio, J., Haukisalml, V., Sukura, A., Laakkonen, J., 2000. Disease patterns in field and bank vole populations during a cyclical decline in central Finland. Comp. Immunol. Microbiol. Infect. Dis. 23, 73–89.
- Sterba, J., Barus, V., 1976. First record of *Strobilocercus fasciolaris* (Taeniidae-larvae) in man. Folia Parasitol. 23, 221–226.
- Stieger, C., Hegglin, D., Schwarzenbach, G., Mathis, A., Deplazes, P., 2002. Spatial and temporal aspects of urban transmission of *Echinococcus multilocularis*. Parasitology 124, 631–640.
- Stien, A., Voutilainen, L., Haukisalml, V., Fuglei, E., Mørk, T., Yoccoz, N.G., Ims, R.A., Henttonen, H., 2010. Intestinal parasites of the Arctic fox in relation to the abundance and distribution of intermediate hosts. Parasitol. 137, 149–157.
- Subbotin, A.M., 2009. Analysis of helminthocenosis structure in raccoon dog (*Nyctereutes procyonoides*) in the Republic of Belarus. Sci. Bull. V.S.U. 1.
- Takács, A., Szabó, L., Juhász, L., Takács, A.A., Lanszki, J., Takács, P.T., Heltai, M., 2014. Data on the parasitological status of golden jackal (*Canis aureus* L., 1758) in Hungary. Acta Vet. Hung. 62, 33–41.
- Tenora, F., Henttonen, H., Haukisalml, V., 1983. On helminths of rodents in Finland. Ann. Zool. Fenn. 20, 37–45.
- Tenora, F., Andreassen, J., Hindsbo, O., Lodal, J., 1991. Helminths of small rodents in

- Denmark. *Helminthologia* 28, 151–154.
- Thompson, R.C.A., 1995. Biology and systematics of *Echinococcus multilocularis*. In: Thompson, R.C.A., Lymbery, A.J. (Eds.), *Echinococcus and Hydatid Disease*. CAB International, pp. 1–50.
- Timbur, M., Suvonkulov, U., Zafar, S., Olesya, A., Kim, H.-J., Yong, T., Lee, G.-J., Park, G.-M., Shin, M.-H., Yu, H.S., 2018. Genotypic and phylogenetic characteristics of *Echinococcus granulosus* sensu lato in Uzbekistan. In: Proceedings of the 14th International Congress of Parasitology, Daegu, Korea.
- Tokiwa, T., Taira, K., Yamazaki, M., Kashimura, A., Une, Y., 2014. The first report of peritoneal tetrahyridiosis in squirrel monkey (*Saimiri sciureus*). *Parasitol. Int.* 63, 705–707.
- Trachsel, D., Deplazes, P., Mathis, A., 2007. Identification of taeniid eggs in the faeces from carnivores based on multiplex PCR using targets in mitochondrial DNA. *Parasitology* 134, 911–920.
- Tschudi, K., Ammann, R., 1988. Recurrent chest wall abscess. Result of a probable percutaneous infection with *Echinococcus multilocularis* following a dormouse bite. *Schweiz. Med. Wschr.* 118, 1011–1015.
- Tsubota, K., Nakatsuji, S., Matsumoto, M., Fujihira, S., Yoshizawa, K., Okazaki, Y., Murakami, Y., Anagawa, A., Oku, Y., Oishi, Y., 2009. Abdominal cysticercosis in a cynomolgus monkey. *Vet. Parasitol.* 161, 339–341.
- Turner, M., Leiper, R.T., 1919. On the occurrence of *Coenurus glomeratus* in man in West Africa. *Trans. Roy. Soc. Trop. Med. Hyg.* 13, 23–24.
- Umhang, G., Richomme, C., Boucher, J.M., Guedon, G., Boué, F., 2013. Nutrias and muskrats as bioindicators for the presence of *Echinococcus multilocularis* in new endemic areas. *Vet. Parasitol.* 197, 283–287.
- Umhang, G., Comte, S., Raton, V., Hormaz, V., Boucher, J.M., Favier, S., Combes, B., Boué, F., 2014. *Echinococcus multilocularis* infections in dogs from urban and peri-urban areas in France. *Parasitol. Res.* 113, 2219–2222.
- Vanderick, F., Fain, A., Langi, S., Vanbalen, H., 1964. 2 new cases of human coenurosis caused by *Taenia brauni* in Rwanda, with orbital localization of the *Coenurus*. *Ann. Soc. Belges. Med. Trop. Parasitol. Mycol.* 44, 1077–1079.
- Varcasia, A., Sanna, D., Casu, M., Lahmar, S., Dessì, G., Pipia, A.P., Tamponi, C., Gaglio, G., Hrčková, G., Otranto, D., Scala, A., 2015a. Species delimitation based on mtDNA genes suggests the occurrence of new species of *Mesocestoides* in the Mediterranean region. *Parasites Vectors* 11, 619.
- Varcasia, A., Tamponi, C., Tosciri, G., Pipia, A.P., Dore, F., Schuster, R.K., Kandil, O.M., Manunta, M.L., Scala, A., 2015b. Is the red fox (*Vulpes vulpes*) a competent definitive host for *Taenia multiceps*? *Parasites Vectors* 8, 491.
- Vasileiou, N.G., Fthenakis, G.C., Papadopoulos, E., 2015. Dissemination of parasites by animal movements in small ruminant farms. *Vet. Parasitol.* 213, 56–60.
- Verster, A., 1969. A taxonomic revision of the genus *Taenia* Linnaeus, 1758 s.str. *Onderstepoort J. Vet. Res.* 36, 3–58.
- von Nickisch-Rosenegk, M., Lucius, R., Loos-Frank, B., 1999. Contributions to the phylogeny of the Cyclophyllidea (Cestoda) inferred from mitochondrial 12S rDNA. *J. Mol. Evol.* 48, 586–596.
- Vuitton, L., Bresson-Hadni, S., Millon, L., 2015. Clinical epidemiology of human AE in Europe. *Vet. Parasitol.* 213, 110–120.
- Welzel, A., Steinbach, G., von Keyserlingk, M., Stoye, M., 1995. Zur Helminthenfauna des Rotfuchses (*Vulpes vulpes* L.) in Südniedersachsen. *Z. Jagdwiss.* 41, 100–109.
- Wereszczuk, A., Leblois, R., Zalewski, A., 2017. Genetic diversity and structure related to expansion history and habitat isolation: stone marten populating rural-urban habitats. *BMC Ecol.* 17, 46.
- Whipp, C.J., Daoust, P.Y., Conboy, G., Gelens, H., 2017. Abdominal cysticercosis in a red fox (*Vulpes vulpes*). *J. Wildl. Dis.* 53, 197–199.
- Willis, J.M., Herbert, I.V., 1984. Some factors affecting the eggs of *Taenia multiceps*: their transmission onto pasture and their viability. *Ann. Trop. Med. Parasitol.* 78, 236–242.
- Wolff, M., Bush, M., Montali, R., Gardiner, C.H., 1989. Cysticercus pneumonitis and pleuritis in a red-ruffed lemur. *J. Zoo Wildl. Med.* 20, 383–385.
- Wunschmann, A., Garlie, V., Averbek, G., Kurtz, H., Hoberg, E.P., 2003. Cerebral cysticercosis by *Taenia crassiceps* in a domestic cat. *J. Vet. Diagn. Investig.* 15, 484–488.
- Young, L.A., Morris, P.J., Keener, L., Gardiner, C.H., Stalis, I.H., Bicknese, E., Sutherland-Smith, M., Janssen, D.L., 2000. Subcutaneous *Taenia crassiceps* cysticercosis in a red ruffed lemur (*Varecia variegata rubra*). In: Proceedings of the AAZV and IAAAM Joint Conference, New Orleans, USA, pp. 251–252.
- Zhang, X.Y., Jian, Y.N., Ma, L.Q., Li, X.P., Karanis, P., 2018. A case of coenurosis in wild rabbit (*Lepus sinensis*) caused by *Taenia serialis* metacestode in Qinghai plateau Aarea, China. *Kor. J. Parasitol.* 56, 195–198.