

Kent Academic Repository

Full text document (pdf)

Citation for published version

Erdelyi, Ralph-Alexandru and Duma, Virgil-Florin and Dobre, George and Bradu, Adrian and Podoleanu, Adrian G.H. and Kovaiinová, Jana (2019) Investigations of dental cavities: between x-ray radiography and OCT. In: Proceedings Volume 11385, Optics and Measurement International Conference 2019; 1138504 (2019). . p. 19.

DOI

<https://doi.org/10.1117/12.2542904>

Link to record in KAR

<https://kar.kent.ac.uk/79482/>

Document Version

Author's Accepted Manuscript

Copyright & reuse

Content in the Kent Academic Repository is made available for research purposes. Unless otherwise stated all content is protected by copyright and in the absence of an open licence (eg Creative Commons), permissions for further reuse of content should be sought from the publisher, author or other copyright holder.

Versions of research

The version in the Kent Academic Repository may differ from the final published version.

Users are advised to check <http://kar.kent.ac.uk> for the status of the paper. **Users should always cite the published version of record.**

Enquiries

For any further enquiries regarding the licence status of this document, please contact:

researchsupport@kent.ac.uk

If you believe this document infringes copyright then please contact the KAR admin team with the take-down information provided at <http://kar.kent.ac.uk/contact.html>

Investigations of dental cavities: between X-ray radiography and OCT

Ralph-Alexandru Erdelyi^{a,b 1}, Virgil-Florin Duma^{a,b 2},
George Dobre^c, Adrian Bradu^c, Adrian Gh. Podoleanu^c

^a3OM Optomechatronics Group, Aurel Vlaicu University of Arad, 77 Revolutiei Ave.,
Arad 310130, Romania

^bDoctoral School, Polytechnic University of Timisoara, 1 Mihai Viteazu Ave.,
Timisoara 300222, Romania

^cApplied Optics Group, School of Physical Sciences, University of Kent, Canterbury, CT2 7NH,
United Kingdom

ABSTRACT

Nowadays in dentistry a correct diagnosis is given only after a clinical and radiological evaluation. Radiographs are also required for treatment assessments. The aim of this study is to present results obtained on evaluating dental cavities in a dental clinic in Western Romania, using both X-ray radiography and Optical Coherence Tomography (OCT). The most common methods for daily-basis clinical imaging are utilized, i.e. panoramic radiography and three-dimensional (3D) cone beam computed tomography (CBCT). Advantages of OCT as an imaging method in dentistry are discussed: it avoids exposing the patient to X-ray radiation, and image resolution of OCT is superior. This led us to test this technique for dental assessments and see how it can work in conjunction with radiography. The study also provides upsides and downsides of both medical imaging techniques. Panoramic radiographs and 3D CBCT to several extracted teeth are performed. Dedicated toolbars from Romexis software (Planmeca, Helsinki, Finland) are analyzed with regard to their capability to make precise measurements. Processing of images are made to obtain a high-quality; measurements are done and data are collected. The same teeth are scanned with an in-house developed SS-OCT system. Images from both investigations are presented, and clinical conclusions are drawn. For dental issues (i.e., cavities) that appear on the surface of the teeth, OCT proves to be more suitable than radiographs; it is also more accurate and radiation-free.

Keywords: dental cavities, dental radiography, optical coherence tomography (OCT), optical measurements, image characterization, resolution, X-ray radiography, dental imaging, Cone Beam Computed Tomography (CBCT).

1 INTRODUCTION

Dentistry evolved fast in the last decades because the technology is increasingly involved in diagnosis and treatment [1-3]. There are several types of medical imaging techniques used for diagnosis: X-ray radiography, some laser-based methods for the detection of cavities, as well as dynamical techniques like Optical Coherence Tomography (OCT) [4-7].

The most common methods for daily-basis clinical imaging in dental medicine are intraoral radiographs, panoramic radiography, and three-dimensional (3D) Cone Beam Computed Tomography (CBCT). One of their drawbacks is that patients have issues with being exposed to X-ray radiation. In this respect, the radiation dose must be properly calculated for every method [8], therefore X-ray units are improved to be able to reduce the radiation dose [9]. Because nowadays every X-ray unit is digital (consisting of X-ray unit, sensors, and PC equipped with dedicated software), users can enhance, process, and analyze in-depth obtained images. Accurate high-quality images with high resolution, good contrast, and no artefacts are mandatory in order to correctly diagnose the patient or to assess the performed treatment.

OCT is a relatively new medical imaging technique which can be used not only to diagnose dental issues, but also to assess the treatment [10]. Even if OCT is not yet a common imaging method in dentistry [7], one of its advantages is that it avoids

¹ Email: ralph.erdelyi93@gmail.com;

² Email: duma.virgil@osamember.org; phone: +40-751-511451; sites: <http://3om-group-optomechatronics.ro/>;
<https://www.researchgate.net/lab/3OM-Optomechatronics-Group-Virgil-Florin-Duma>

exposing the patient to X-ray radiation: as OCT is based on IR radiation, it is entirely non-invasive. Image resolution in OCT is also superior, which led us to test this technique and compare it with (common) radiographs. The drawback of OCT is its penetration depth, which is inversely proportional to the density of the material being investigated. Even though, images obtained with OCT can reveal dental issues in earlier stages than radiographs because of the resolution difference between these two techniques [11].

Measurement tools provided by dedicated software are important because the Medical Doctor (MD) can assess by using them, with high accuracy, issues such as cavities, secondary cavities, length of the root canal, or periodontitis. Without these measurement tools, the images obtained with any medical imaging techniques are utilized only to detect the issue, but not to assess it. In consequence, it is not enough to see a cavity on an image obtained with an OCT technique. The image must be furthermore processed and analyzed to provide to exact information [12,13].

For this study several extracted teeth were gathered from *Dental Experts*, a dental clinic from Timisoara. The radiological investigations with additional measurement were also performed there. The OCT investigations and measurements were realized in the *Laboratory of Optomechatronic and Biomedical Photonics* of the 'Aurel Vlaicu' University of Arad. The ethical protocols at the *Dental Experts* Clinic have been observed for all procedures. The images obtained with both techniques alongside the detailed information about each problem spotted on every image analyzed are presented in this paper. In addition, the measurement protocol utilized is also presented.

2 MATERIALS AND METHODS

2.1 Radiography

All radiographs have been performed in the *Dental Experts* Clinic in Western Romania, using two radiological units: Planmeca ProMax 3D Plus (Planmeca, Helsinki, Finland), for panoramic radiographs and 3D CBCT, Gendex Oralix (Danaher Corporation, Washington DC, United States) for intraoral radiographs [14] – Fig. 1. The maximum resolution achieved with both X-ray units has been 75 μm , after the optimizations carried out as described in detail in [11]. For panoramic radiographs, the exposure time has been 15 s and for 3D CBCT only 5 s, with the remark that intraoral radiographs require an exposure time between 0.5 and 1 s for a high-quality image. The protocol for getting such high-quality radiographs is also optimized in order to respect the *As Low As Reasonably Achievable* (ALARA) protocol [9], in order to minimize the exposure to radiations of patients.




Figure 1. (a) Photo with teeth positioned in the X-ray unit Planmeca ProMax 3D Plus (Planmeca, Helsinki, Finland), ready for exposure. (b) Photo with teeth positioned in the X-ray unit Gendex Oralix (Danaher Corporation, Washington DC, USA), ready for exposure.

With regard to such X-rays imaging investigations, one must highlight that there are differences in details that can be observed in any kind of radiography, even if the utilized techniques have the same resolution. For example, a small cavity cannot be discovered exactly on a panoramic radiography, but an intraoral radiography delivers more detailed information about the cavity, because the focus is on that part of the mouth where the tooth with that specific issue is located [15].

Each X-ray unit is equipped with additional computers and machines in order to provide a final high-quality image. Planmeca X-ray unit is integrated in a system with two computers, all linked in a private network, one for image reconstruction and the other one for image processing. To accomplish these tasks, the computers should be equipped with performant components; their minimum system requirements are presented in Tab. 1.

Table 1. Minimum system requirements for Planmeca ProMax 3D Plus.

Component	Image Reconstruction PC	Image Processing PC
CPU	Intel Core i5 (6 th generation)	Intel Core i7 (6 th generation)
RAM	16GB	16GB
System type	x64	x64
Memory	1 SSD (anyone) + 1 HDD (anyone)	1SSD (min. 256 GB) + 2 HDD (1TB RAID1 mirroring)
GPU	Dedicated GPU with minimum 2GB RAM	Dedicated GPU with minimum 2GB RAM
Network	LAN	2 LAN
Monitor	No monitor	

For intraoral radiographs there are two possibilities nowadays when it comes to sensors: digital detectors and photostimulable phosphor plates (PSP) – Fig. 2. Digital detectors provide the image directly on the computer monitor in the moment when the exposure is realized, while PSPs require a machine that converts the energy stored on these films into a digital radiography. Digital detectors are based on charge coupled devices (CCD) and complementary-metal-oxide semiconductors (CMOS), where the radiation is stored in form of electric charge at the level of every pixel of the digital detector and furthermore amplified and converted into digital. Amplification and conversion are taking place on the way from the detector towards the monitor/software used to visualize the radiography. In the case of CCD and CMOS (in contrast to PSPs) the amplification and conversion is done individually by every pixel.

There are advantages and disadvantages in using both types of technology for intraoral radiographs, as listed in Tab. 2.




Figure 2. PSP used in this study. (a) is the front view of a PSP inside the cover, while (b) is the back of the cover.

2.2 OCT

An in-house developed Swept Source (SS) (SS)-OCT, Master-Slave (MS) enhanced [16] has been utilized in this study. The OCT system is centered at a wavelength of 1310 nm and uses a fixed 2D dual axis galvanometer scanner for the lateral scanning of the sample [17]. A detailed description of the system has been made in [18].

Table 2. Advantages and disadvantages of using digital detectors and radiographic films.

Digital detectors		PSP	
Advantage	Disadvantage	Advantage	Disadvantage
Time saving	Easily decalibrated	No calibration	Time consuming
Better resolution than radiographic films	Thicker than radiographic films - discomfort	Easy to handle	More devices required
	Damage predisposition	Easy to protect from physical damage (scars)	
	Hard to cover without altering their properties		

2.3 Procedure

This study is based on the idea of measuring dental cavities with another medical imaging technique than radiography and then to compare the results. Also, the workflow for measuring these dental issues is furthermore described and several conclusions are highlighted.

Firstly, extracted teeth are analyzed with the X-ray technique, because radiology equipment has been located in the same place from where the teeth are gathered for this study, i.e. the dental clinic.

After the teeth were extracted, they were cleaned and prepared for investigations. All types of radiographs were realized with all the equipment available in the clinic: intraoral radiographs, panoramic radiography, and 3D CBCT.

The software utilized in this study is Romexis Viewer (Planmeca, Helsinki, Finland), which have a measurement toolbar that allows for the exact measuring of dental issues, even for images imported from other sources. After the image is provided by the X-ray unit or imported from another sources, a calibration step is mandatory. This implies a correlation between the number of pixels and the surface (mm) and it is done by drawing a straight line on the image and by simply measuring it with a ruler. In Fig. 3 an example of such a calibration process is shown.

After the calibration step, the user can measure any dental problem spotted on the radiography. In our case, we are looking for small dental cavities. The measurement toolbar consists of calibration, as well as angle and/or length measurements. With additional toolbars for drawing and image enhancement, the software provides the resources needed to correctly assess a radiograph.

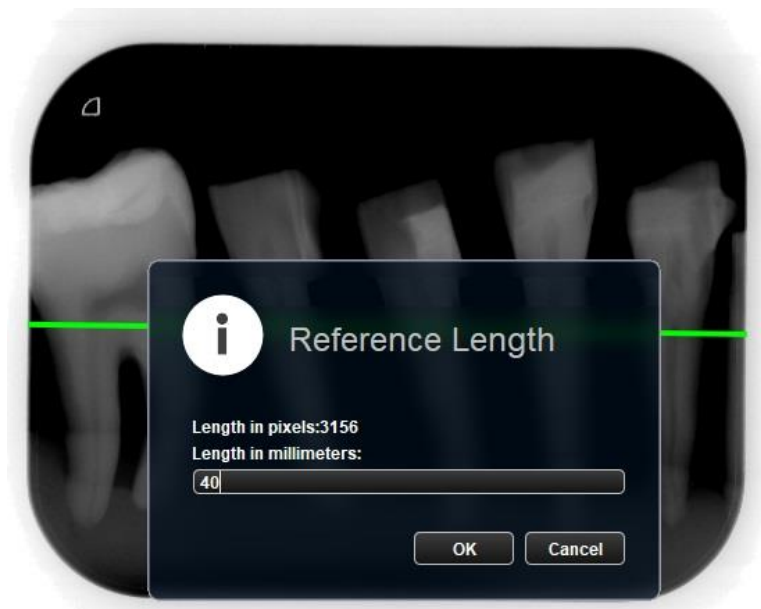


Figure 3. Calibration step in Romexis Viewer (Planmeca, Helsinki, Finland).

Even if this Romexis software is a trustworthy tool for accomplishing a correct assessment of a radiograph, limitations exist because of the radiography resolution. Thus, the software cannot measure something that cannot be observed on radiographs. Because of the superior resolution provided by the OCT system, we scanned the same extracted teeth and then the images obtained were imported into the Romexis software and further on assessed using all the available measurement tools (Fig. 4).

OCT images were processed with an open source image processing software, ImageJ (Wayne Rasband, NIH/LOCI, University of Wisconsin). The 500 OCT B-scans have been rendered into a 3D image/volumetric reconstruction. An example of such a reconstruction is shown in Fig. 4(d). Figure 5 shows the area investigated from an extracted tooth utilized in the study.

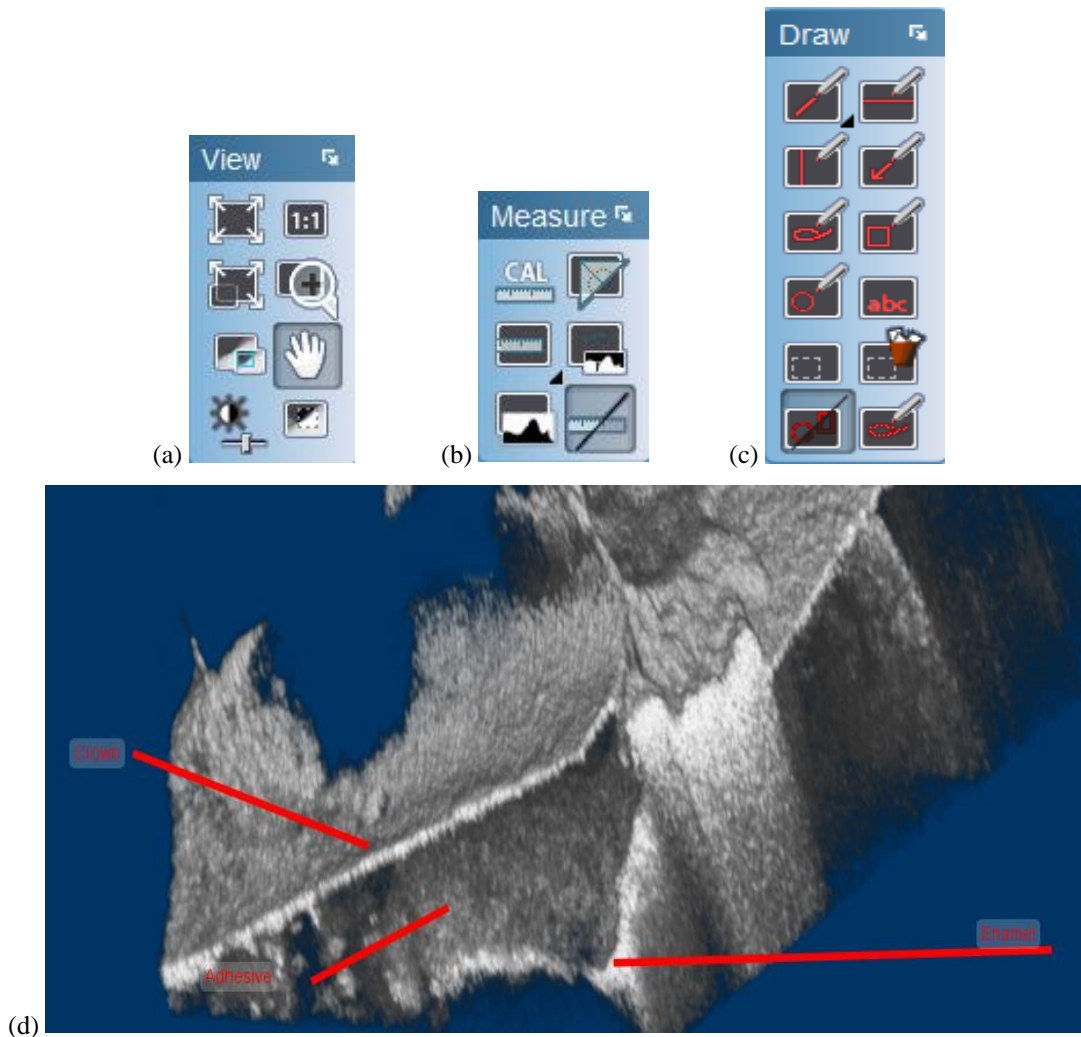


Figure 4. Romexis toolbars: (a) View toolbar; (b) Measuring toolbar; (c) Draw toolbar; (d) OCT volumetric reconstruction with annotations.



Figure 5. Image with a section from a tooth used in the study.

3 RESULTS

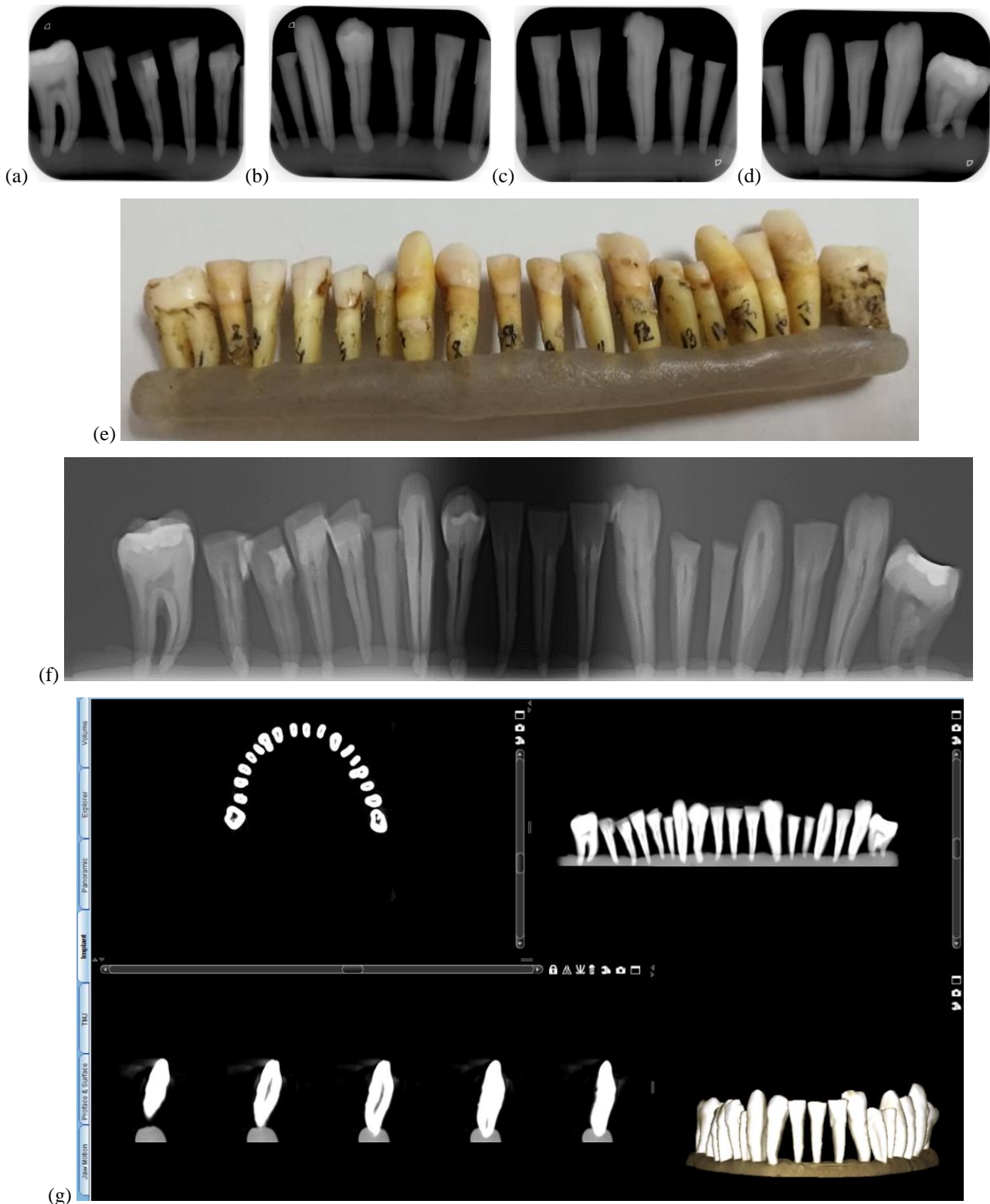


Figure 6. Pictures from (a) to (d) are intraoral radiographs of extracted teeth from picture (e). (f) is the panoramic radiography and (g) is the 3D CBCT of the same extracted teeth.

The first step of this study has been to obtain all possible radiographs with the available equipment in the dental clinic and to analyze them in order to detect dental issues that cannot be visible with the naked eye. Several small cavities were spotted on the intraoral radiographs, which proved to be the best radiological technique for imaging such dental issues in early stages. Furthermore, the teeth with medical problems were marked and then the areas of interest from every tooth were analyzed with the SS-OCT system. The extracted teeth have been kept at the same position during all exposures. They have been numbered, in order to be able to compare the images and data gathered from radiographs and OCT investigations, as it can be observed in Fig. 6(e).

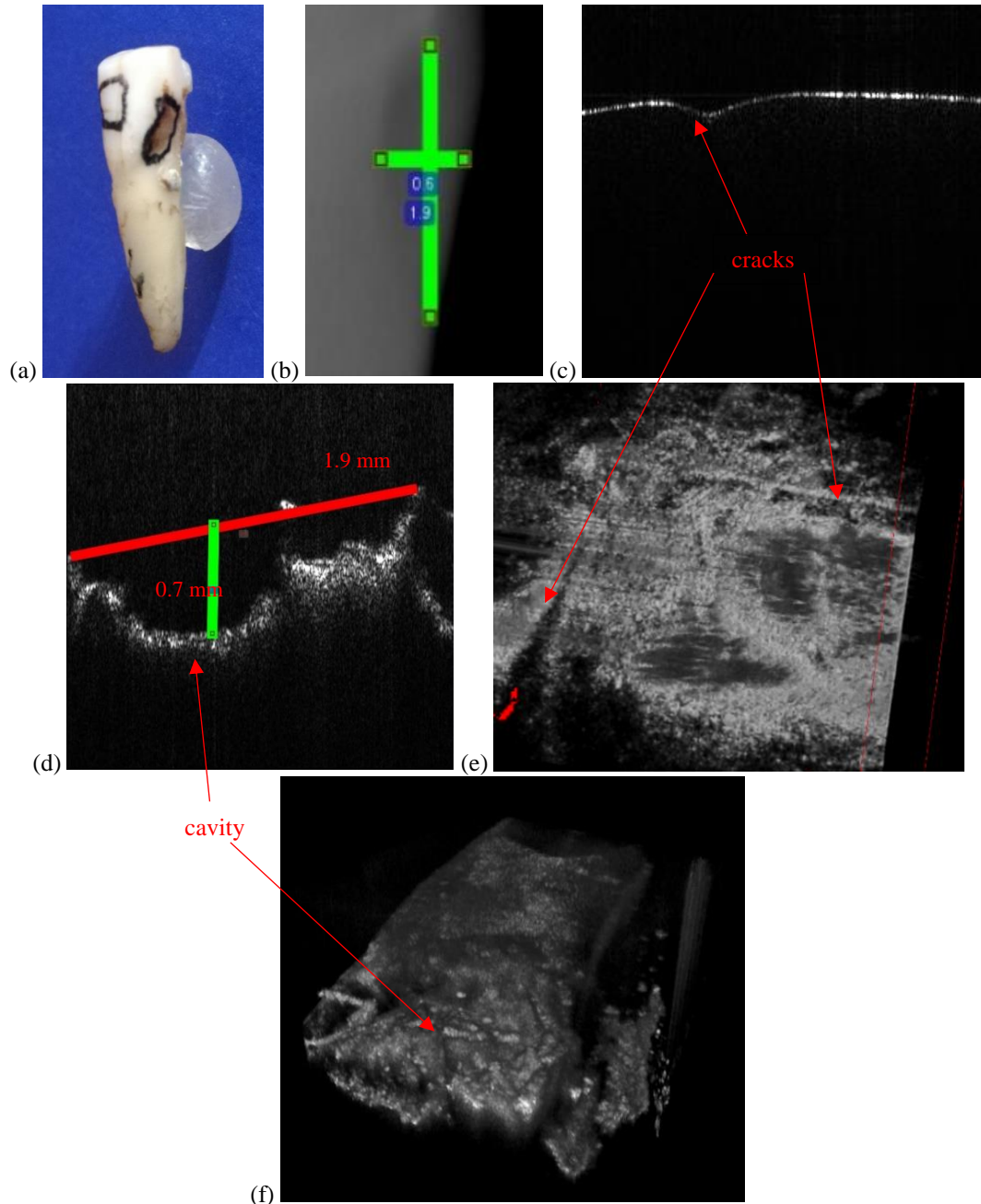


Figure 7. (a) Tooth number 4, marked for OCT investigations; (b) a section from the intraoral radiography with a focus on the measured cavity; (c), (d) OCT images where small cracks can be visible on the surface of the tooth number 4; (e), (f) OCT volumetric reconstructions of the cavity present in this tooth.

As our aim has been to spot and measure on OCT images clear margins of the cavities and to discover new cavities that cannot be observed on radiographs, in Figs. 7 to 11 several OCT images are presented and compared with processed radiographs. Measurements have been performed using each technique.

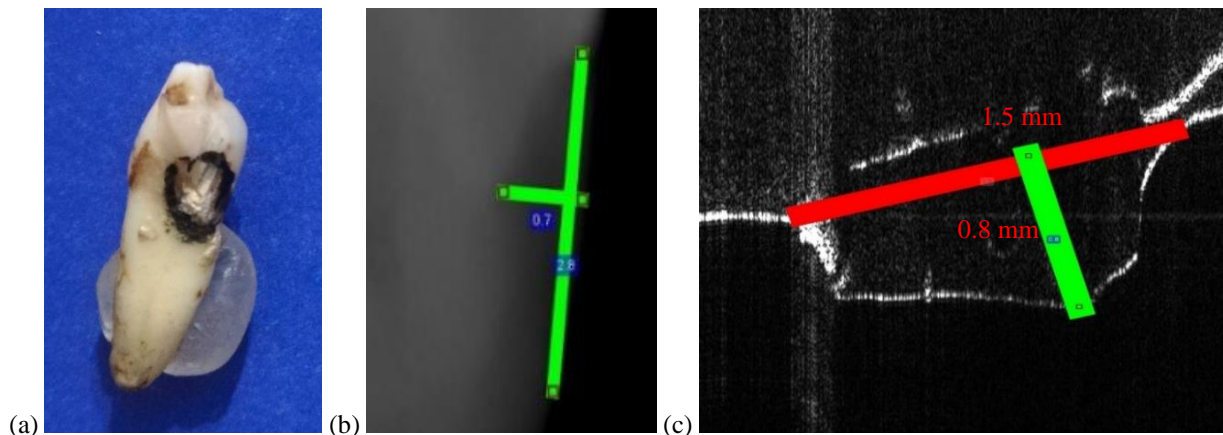


Figure 8. (a) Tooth number 5, marked for OCT investigations; (b) a section from the intraoral radiography with a focus on the measured cavity; (c) a section from an OCT image where the measurements of the cavity were done.





Figure 9. (a) Tooth number 8, marked for OCT investigations; (b) a section from the intraoral radiography with a focus on the measured cavity; (c) a section from an OCT image where the measurements of the cavity were done.






Figure 10. (a) Tooth number 11, marked for OCT investigations; (b) a section from the intraoral radiograph, with a focus on the measured cavity; (c), (d) XY and XZ sections from an OCT image where the measurements of the cavity were done; (e) volumetric reconstruction after OCT investigation where two cavities are marked; the first one is a cavity in the early stages and the second one is the cavity from (c) and (d).

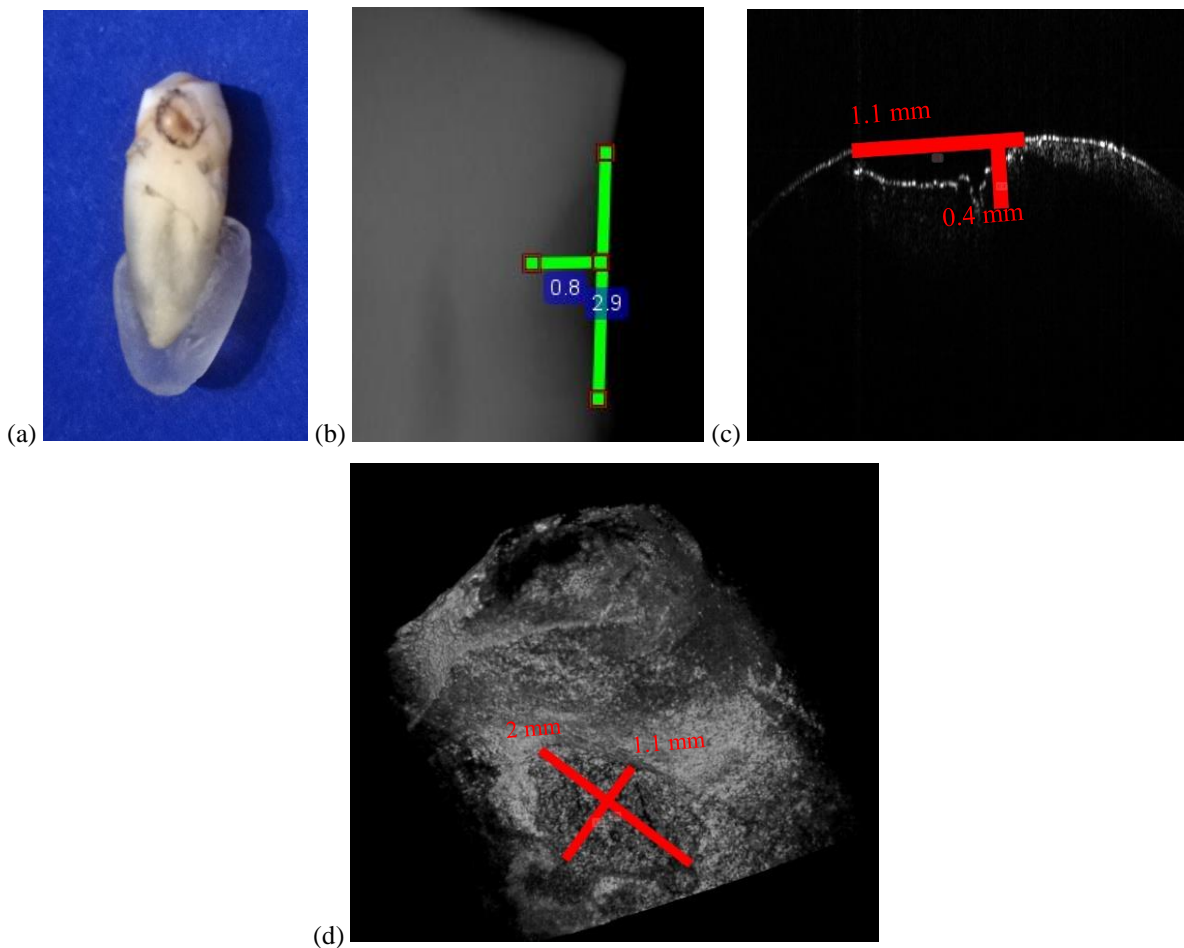


Figure 11. (a) tooth number 13, marked for OCT investigations; (b) a section from the intraoral radiograph with a focus on the measured cavity; (c), (d) XY and XZ sections from an OCT image where the measurements of the cavity were done. (d) is a volumetric reconstruction after OCT investigation, where 2 cavities are marked: one is a cavity in the early stages and the other one is the cavity from the previous views.

4 CONCLUSIONS

After all the images have been analyzed using both medical imaging techniques, several conclusions have been drawn. For a correct assessment of small dental cavities, 3D CBCT and panoramic radiographs are not necessary. Intraoral radiography is the best option to choose for detection of such dental issues when all radiological techniques are available. Even so, as seen from this study, in some cases intraoral radiographs can lead to wrong measurements (Figs. 8, 10, and 11).

The drawback of intraoral radiographs is that they are 2D images and thus they lack volumetric information. In contrast, OCT provides both 2D and 3D images and the measurements are more accurate than in the case of radiographs. Also, the resolution is superior for OCT in comparison with radiographs, i.e. a common 4 to 10 μm axial resolution for OCT and only 150 μm for radiographs (that can be improved up to 75 μm [9]). Another aspect that should be emphasized is that OCT is a radiation-free imaging technique, which is beneficial for patients.

In addition, some of the OCT images reveal early stages of caries that are not visible on radiographs. After analyzing the images and the results of measurements, OCT proves to be more suitable for detecting small caries than radiographs. A comparison of the measurements performed is shown in Tab. 3.

Table 3. Comparison between the dimensions of the cavities obtained with OCT and with radiography.

Tooth number	Radiography measurements [mm]	OCT measurements [mm]	Validation and comments
4	1.9 x 0.6	1.9 x 0.7	Similar values of measurements
5	2.8 x 0.7	1.5 x 0.8	Wrong measurement for the length of the cavity on radiography. OCT results validated with physical measurements
8	0.2	0.19 x 0.04	Cavity barely visible on the radiograph. Precise measurements using OCT
11	0.9 x 0.6	1.2 x 1.2	Cavity barely visible on the radiograph. Wrong measurement for the length of the cavity on the radiograph. Precise measurements on OCT
13	2.9 x 0.8	2 x 0.4	Cavity barely visible on the radiograph. Wrong measurement for the length of the cavity on the radiograph. Precise measurements using OCT

ACKNOWLEDGEMENTS

This work was funded by the European Union through the European Regional Development Fund under the Competitiveness Operational Program (BioCell-NanoART = Novel Bio-inspired Cellular Nano-architectures, POC-A1-A1.1.4-E nr. 30/2016), as well by the Romanian National Authority for Scientific Research, CNDI-UEFISCDI project PN-III-P2-2.1-PTE-2016-181 (<http://3om-group-optomechatronics.ro/>). The support of the Polytechnic University of Timisoara, through its Doctoral School Program, for the participation at the Conference, is also acknowledged.

REFERENCES

- [1] Jung, R. E., Schneider, D., Ganeles, J., Wismeijer, D., Zwahlen, M., Hammerle, C. H., Tahmeseb, A., "Computer Technology Applications in Surgical Implant Dentistry: A Systematic Review," *The International J. of Oral & Maxillofacial Implants*, 24, 92-109 (2009).
- [2] Lin, L., Fang, Y., Liao, Y., Chen, G., Gao, C., Zhu, O., "3D Printing and Digital Processing Techniques in Dentistry: A Review of Literature", *Advanced Engineering Materials* 21(6) (2019).

- [3] Javaid, M., Haleem, A., Kumar, L., "Current status and applications of 3D scanning in dentistry", *Clinical Epidemiology and Global Health* 7(2), 228-233 (2019).
- [4] Huang, D., Swanson, E. A., Lin, C. P., Schuman, J. S., Stinson, W. G., Chang, W., Hee, M. R., Flotte, T., Gregory, K., Puliafito, C. A. and Fujimoto, J. G., "Optical coherence tomography," *Science* 254(5035), 1178-1181 (1991).
- [5] Drexler, W., Liu, M., Kumar, A., Kamali, T., Unterhuber, A., and Leitgeb, R. A., "Optical coherence tomography today: speed, contrast, and multimodality," *J. Biomed. Opt.* 19, 071412 (2014).
- [6] Hsieh, Y.-S., Ho, Y.-C., Lee, S.-Y., Chuang, C.-C., Tsai, J., Lin, K.-F., and Sun, C.-W., "Dental Optical Coherence Tomography," *Sensors* 13, 8928-8949 (2013).
- [7] Canjau, S., Todea, C., Negrutiu, M. L., Sinescu, C., Topala, F. I., Marcauteanu, C., Manescu, A., Duma, V.-F., Bradu, A., Podoleanu, A., "Optical Coherence Tomography for Non-Invasive ex vivo Investigations in Dental Medicine - a Joint Group Experience (Review)," *Modern Technologies in Medicine* 7(1), 97-115 (2015).
- [8] Poppe, B., Looe, H. K., Pfaffenberger, A., Chofo, N., Eenboom, F., Sering, M., Rühmann, A., Poplawski, A., Willborn, K., "Dose-area product measurements in panoramic dental radiology," *Radiation Protection Dosimetry* 123(1), 131-134 (2007).
- [9] Erdelyi, R. A., Duma, V.-F., "Optimization of radiation doses and patients' risk in dental radiography", *AIP Proceedings* 2071, 040013 (2019).
- [10] Alshahni, R. Z., Shimada, Y., Zhou, Y., Yoshiyama, M., Sadr, A., Sumi Y., and Tagami, J., "Cavity adaptation of composite restorations prepared at crown and root: Optical assessment using SS-OCT," *Dental Materials Journal*, (2019).
- [11] Otis, L., Everett, M. J., Sathyam, U.S., Colston Jr., B. W., "Optical Coherence Tomography: A New Imaging: Technology for Dentistry," *The Journal of the American Dental Association* 131(4), 511-514 (2000).
- [12] Ko, A. C.-T., Choo-Smith, L.-P., Hewko, M. D., Leonardi, L., Sowa, M. G., Dong, C. C. C. S., Williams, P., Cleghorn, B., "Ex vivo detection and characterization of early dental caries by optical coherence tomography and Raman spectroscopy," *J. of Biomedical Optics* 10(3), 031118 (2005).
- [13] Amaechi, B. T., Higham, S. M., Podoleanu, A. G., Rogers, J. A., Jackson, D. A., "Use of optical coherence tomography for assessment of dental caries: quantitative procedure," *Journal of Oral Rehabilitation* 28(12), 1092-1093 (2001).
- [14] Imaging Manual, "en 3D s/Classic with ProTouch", 21.05.2019, <https://materialbank.planmeca.com/> (20.09.2019).
- [15] Versteeg, C. H., Sanderink, G. C. H., van der Stelt, P. F., "Efficacy of digital intra-oral radiography in clinical dentistry," *Journal of Dentistry* 25(3-4), 215-224 (1997).
- [16] Podoleanu, A., Bradu, A., Master-slave interferometry for parallel spectral domain interferometry sensing and versatile 3D optical coherence tomography, *Opt Express* 21, 19324-19338 (2013).
- [17] Duma, V.-F., "Laser scanners with oscillatory elements: Design and optimization of 1D and 2D scanning functions," *Applied Mathematical Modelling* 67(3), 456-476 (2019).
- [18] Duma, V.-F., Dobre, G., Demian, D., Cernat, R., Sinescu, C., Topala, F. I., Negrutiu, M. L., Hutiu, Gh., Bradu, A., and Podoleanu, A. Gh., "Handheld scanning probes for optical coherence tomography," *Romanian Reports in Physics* 67(4), 1346-1358 (2015).