



## Results of ulnar shortening osteotomy in patients with ulnar wrist pain. A retrospective study

JONAS DECLERQ, WIM VANHOVE, SZABOLCS BENIS, NADINE HOLLEVOET

*From the Ghent University Hospital, Department of Orthopaedic Surgery and Traumatology*

The aim of the study was to find out if ulnar shortening is effective to treat ulnar wrist pain and which factors influence outcome. Thirty-seven patients were evaluated with a mean follow-up of 4.5 years. Thirty patients (81%) would undergo the same operation again although 21 (57%) had residual ulnar wrist pain. Mean disabilities of arm, shoulder and hand (DASH) score was 22 and mean patient rated wrist evaluation score (PRWE) was 33. DASH and PRWE scores were better in smokers, in patients operated on the non-dominant side and when follow-up was longer. PRWE score was worse in posttraumatic cases. Age, gender and type of osteotomy did not influence outcome. Three patients (8%) needed an additional operation for nonunion and in 17 (46%) plate and screws had to be removed. It can be concluded that ulnar shortening can be proposed to treat ulnocarpal wrist pain, but complete pain relief cannot be guaranteed and additional surgery may be required.

**Keywords :** ulnar shortening osteotomy ; ulnar wrist pain ; ulnocarpal impaction

### INTRODUCTION

Ulnar-sided wrist pain has been compared with low back pain because the exact etiology may be difficult to determine and results of surgical treatment can be unpredictable. Several causes of ulnar wrist pain have been reported, including

ulnocarpal impaction, triangular fibrocartilagenous complex (TFCC) lesions, tendonitis of the extensor or flexor carpi ulnaris and other posttraumatic, inflammatory or degenerative lesions of joints on the medial side of the wrist (24,25).

It has been shown that high loads cross the ulnocarpal joint in wrists with a positive ulnar variance and these may induce ulnocarpal impaction with degenerative changes and ulnar wrist pain (22,24). An ulna plus can be idiopathic or secondary to a radius fracture (3), Essex-Lopresti injury (16) or premature growth arrest of the distal radius (10). Ulnocarpal impaction has also been reported in wrists with a neutral or negative ulnar variance (28). Dynamic wrist X-rays with loading can reveal this condition. Symptoms of ulnocarpal impaction include ulnar-sided wrist pain, weakness, occasionally swelling and loss of wrist

- 
- Jonas Declerq, medical student,
  - Wim Vanhove, M.D., Orthopaedic Surgeon
  - Szabolcs Benis, M.D., Orthopaedic Surgeon
  - Nadine Hollevoet, MD, Ph.D., Orthopaedic Surgeon, Associate Professor  
*Ghent University Hospital, Department of Orthopaedic Surgery and Traumatology*
- Correspondence : Nadine Hollevoet, Ghent University Hospital, Department of Orthopaedic Surgery and Traumatology, Corneel Heymanslaan 10, B-9000 Gent, Belgium. Tel 09 332 5521,  
E-mail: Nadine.hollevoet@ugent.be  
© 2019, Acta Orthopædica Belgica.
- 

*No benefits or funds were received in support of this study.  
The authors report no conflict of interests.*

motion and forearm rotation (25). Initially, non-operative treatment measures should be taken such as immobilization, nonsteroidal anti-inflammatory drugs, activity modification and corticosteroid injections (24,25). If these fail, surgery can be considered. The aim is to achieve pain relief by mechanical decompression in the ulnocarpal joint by decreasing ulnar variance (21,24,25). One of the operative treatment options is ulnar shortening osteotomy which can be done in the diaphyseal or distal part of the ulna. The osteotomy can be oblique, transverse or performed with a step-cut (3,24). Other surgical techniques are the wafer procedure or the cartilage-retaining wafer resection (4,25). The orientation of the sigmoid notch may influence the type of surgical treatment. In wrists with a proximally orientated sigmoid notch, ulnar shortening may not be indicated (9).

Most frequently ulnar shortening is performed to treat ulnocarpal impaction, but it may also be indicated in patients with early posttraumatic arthritis of the distal radioulnar joint (26) or instability of the distal ulna (2).

The purpose of the retrospective study was to find out if diaphyseal ulnar shortening osteotomy was effective to treat ulnar wrist pain. We also looked for complications and for factors that may influence outcome such as age, gender, hand dominance, smoking, type of osteotomy, length of follow-up and whether or not a trauma was involved.

## MATERIALS AND METHODS

The electronic medical files were searched for patients operated on for ulnar wrist pain with ulnar shortening between 2006 and 2014. Only patients with closed epiphyseal plates were included. Forty-six patients were identified and asked by telephone if they were willing to participate in the study. Eight patients could not be contacted and one declined. Thirty-seven patients were included in the study. Twenty-five were available for clinical evaluation and interview. Twelve were interviewed by telephone.

The study has been approved by the medical ethics committee of the Ghent University and all patients gave written consent. The search in the

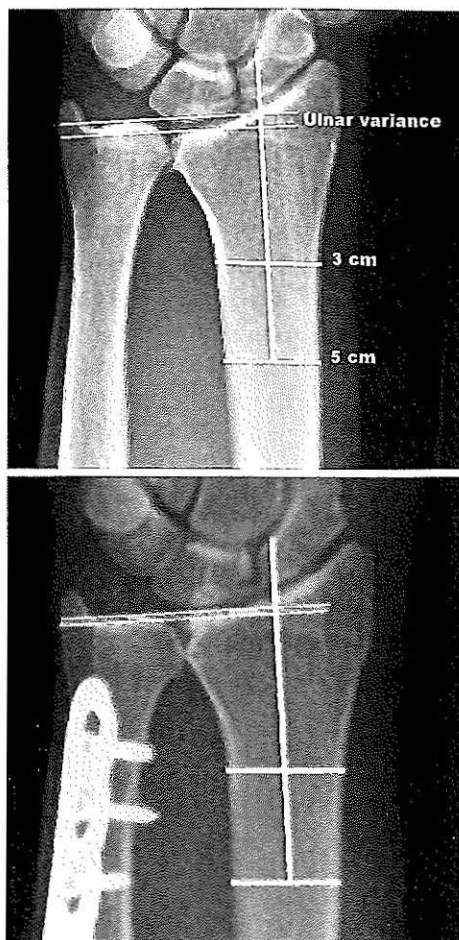
electronic files, interview, clinical examination and radiological measurements were performed by the first author, who was not involved in the treatment.

The electronic patient files were searched for information about gender, age, operated side, hand dominance and preoperative grip strength. It was also noted if ulnar wrist pain was caused by a trauma and if patients had been treated previously with arthroscopic surgery. Information about complications and reoperations following ulnar shortening was retrieved from the patient files and during the interview. It was also noted if instability of the distal radio-ulnar joint was reported in the patient files and if this had been solved by ulnar shortening.

Two standardized outcome questionnaires were used during the interview: the disabilities of the arm, shoulder and hand (DASH) questionnaire (20) and the patient-rated wrist/hand evaluation-Dutch language version (PRWE) (19). Patients were asked to answer with "yes" or "no" if they had any of the following complaints at the time of the assessment: ulnar sided wrist pain, clicking, weakness, stiffness and swelling (6) and if they were smokers. Patients had to record their pain intensity before surgery and during the interview on a Visual Analogue Scale (VAS). The VAS score ranges between 0 and 10. A score of 0 meant patients had no pain at all and a score of 10 intolerable pain. Patients were also asked if they would undergo the same operation again.

Clinical assessment included measuring range of motion of both wrists with a goniometer (flexion, extension, pronation, supination, radial and ulnar deviation) and determining grip strength. Grip strength was measured twice on both sides with a Jamar dynamometer and the highest value was used. Results were presented as a percentage of the contralateral wrist.

The X-ray images were evaluated with the picture archiving and communication system (PACS, GE Healthcare, Chicago, United States). It was determined how much the ulna was shortened by measuring pre- and postoperative ulnar variance on standard wrist radiographs with the method of perpendiculars. The distance between two parallel lines perpendicular to the central axis of the radius



*Figure 1.* — Determination of ulnar variance on pre- and postoperative anteroposterior wrist radiographs in a patient with ulnocarpal impaction syndrome.

was measured, one line passed through the distal articular surface of the ulna and the other through the medial articular surface of the radius (Fig. 1) (30). Pre- and postoperative standard wrist X-rays were available in 21 patient files. In 16 patients preoperative and in nine postoperative standard anteroposterior radiographs of the wrist were not available.

In patients with idiopathic ulnocarpal impaction or premature growth arrest of the distal radius, the aim was to shorten the ulna with 2 to 3 mm. In wrists with ulnocarpal impaction caused by posttraumatic radial shortening, the goal was to achieve the same ulnar variance as the contralateral wrist. A low contact dynamic compression plate was used in 30 patients, a metacarpal plate in five and an ulnar

shortening plate in two (Synthes GmbH, Zuchwil, Switzerland). In 28 cases a transverse and in 9 an oblique osteotomy was performed in the diaphyseal area. In one patient an additional dorsal arthrotomy of the distal radioulnar joint was performed to remove a proximal osteophyte at the sigmoid notch (Fig.1). Two staff surgeons (WV, NH) performed the operations. Postoperatively the wrist was immobilized for 4 weeks in a forearm cast. After removal of the cast, a removable forearm splint was worn intermittently until the osteotomy had healed or the patient was pain free.

Statistical analysis was performed with the SPSS, version 22 (IBM SPSS, Armonk, NY, USA). Data were analyzed for normality with the Shapiro-Wilk test. Differences between pre- and postoperative VAS and grip strength were determined with the Wilcoxon test. Differences in DASH and PRWE between smokers and nonsmokers, whether or not a trauma was involved, non-dominant or dominant side, horizontal or oblique osteotomy and gender were tested with the Mann-Whitney U test. Simple linear regression analysis was performed to investigate the influence of the following factors on DASH and PRWE scores: smoking, trauma, hand dominance, type of osteotomy (horizontal or oblique), age, gender, time to follow-up and preoperative VAS score. With the information of the simple linear regression analysis and the Mann-Whitney U tests, following factors were selected to make a multiple linear regression model: smoking, hand dominance and follow-up. A P-value lower than 0.05 was considered to be statistically significant.

## RESULTS

Twenty-four women and 13 men were included in the study. Patients were reviewed with a mean follow up of 54 months (range: 7-99). Mean age at the time of surgery was 39 years (range: 15-69). The dominant hand was involved in 19 cases (51%). In 36 patients ulnar wrist pain was diagnosed as ulnocarpal impaction associated with an ulna plus. In one patient with a negative ulnar variance, ulnar shortening was performed to treat degenerative changes of the distal radioulnar joint (Fig. 2). In

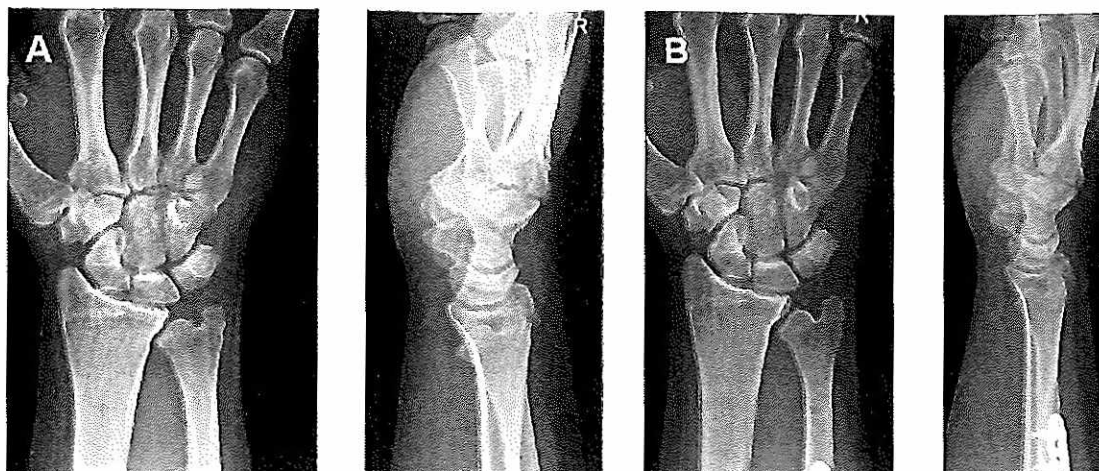


Figure 2. — A 40-year-old man underwent ulnar shortening osteotomy for ulnar wrist pain associated with degenerative changes of the distal radioulnar joint. A : preoperative wrist X-rays and B : X-rays 2 years postoperatively.

Table I. — Number of patients replying yes when asked if they experienced complaints

Complaints	N
Ulnar-sided wrist pain	21 (57%)
Weakness	16 (43%)
Clicking	11 (30%)
Stiffness	11 (30%)
Swelling	7 (19%)

18 patients ulnar wrist pain started after a trauma (14 had a fracture of the distal radius or ulna and 4 a sprain). In 3 patients with a history of trauma, premature closure of the epiphyseal plates of the distal radius had caused ulnocarpal impaction. Idiopathic ulnocarpal impaction was found in 19 patients. Six had been treated previously with an arthroscopic TFCC debridement in other centres.

Following ulnar shortening, plates and screws were removed in 17 patients (46%) and reoperation for non-union was performed in three (8%). In two patients instability of the distal ulna was reported. Ulnar shortening could not restore stability in those 2 patients. Another procedure to stabilize the distal ulna was performed in one patient by reconstructing the dorsal radioulnar ligament with a tendon graft.

Mean DASH score in the present study was 22 (range : 0-75) and mean PRWE score 33 (range : 0-90). Patients most frequently said yes to the question : Do you have persistent ulnar-sided wrist pain? (Table I). Fifteen patients were smokers (41%). Preoperatively mean VAS was 7.1 (range : 1.7-10) and postoperatively 2.6 (range : 0-7.8). The difference was statistically significant ( $P < 0.001$ ).

Table II. — Mean range of wrist motion and grip strength measured at the time of follow-up of in 25 patients

	Operated limb (SD)	Healthy limb (SD)	% of healthy limb
Flexion (°)	56 (24)	67 (11)	84
Extension (°)	48 (17)	64 (9)	75
Radial inclination (°)	27 (9)	30 (7)	90
Ulnar inclination (°)	36 (14)	46 (9)	78
Pronation (°)	71 (27)	84 (19)	85
Supination (°)	77 (30)	90 (15)	86
Grip strength (kg)	26 (17)	31 (14)	84

Table III. — Mean values of DASH and PRWE scores according to gender, smoking, trauma, hand dominance and type of osteotomy.

	Mean DASH	P	Mean PRWE	P
Men/women	16/25	0.24	34/38	0.24
Smokers/nonsmokers	13/19	0.03	28/42	0.01
Trauma/without trauma	27/17	0.9	44/23	0.01
Dominant/nondominant	29/14	0.1	41/25	0.14
Osteotomy oblique /horizontal	18/23	0.74	30/34	0.66

Table IV. — Results of linear regression analysis for the DASH score.

Variables	Simple linear regression			Multiple linear regression		
	Regression coefficient	Unadjusted significance	95% CI	Regression coefficient	Adjusted significance	95% CI
Smoking	-14.77	0.04	[-28.70;-0.85]	-15.91	0.01	[-28.09;-3.73]
Hand dominance	15.37	0.03	[1.80;28.94]	15.28	0.01	[3.32;27.24]
Follow-up	-2.79	0.04	[-5.49;-0.09]	-2.80	0.02	[-5.15;-0.44]
Age	0.03	0.14	[-0.01;0.72]			
Trauma	11.22	0.114	[-2.82;25.26]			
Preoperative VAS	0.21	0.20	[-0.12;0.54]			
gender	-8.58	0.25	[-23.54;6.37]			
Osteotomy type	-5.27	0.53	[-22.13;11.59]			

Table V. — Results of linear regression analysis for the PRWE score.

Variables	Simple linear regression			Multiple linear regression		
	Regression coefficient	Unadjusted significance	95% CI	Regression coefficient	Adjusted significance	95% CI
Smoking	-23.13	0.01	[-41.27;-5.00]	-24.60	0.004	[-40.60;-8.59]
Hand dominance	15.85	0.09	[-2.82;34.52]	15.73	0.05	[0.01;31.46]
Follow-up	-4.13	0.02	[-7.70;-0.57]	-4.21	0.009	[-7.31;-1.11]
Age	0.03	0.37	[-0.03;0.08]			
Trauma	21.20	0.02	[3.17;39.24]			
Preoperative VAS	0.16	0.46	[-0.28;0.61]			
gender	-14.11	0.16	[-33.88;5.67]			
Osteotomy type	-4.30	0.70	[-26.90;18.31]			

Thirty patients (81%) would undergo the same operation again. Seven patients would not: one had previously undergone a radial head resection and ulnar shortening could not restore normal ulnar variance, in 2 patients pain had increased postoperatively, one patient had associated problems of cubital tunnel syndrome, one had mental problems and in one it took 9 months before the osteotomy had healed. In another patient a second operation was required for non-union and a third to remove the plate. During plate removal it was not possible to remove a locking screw with the screw driver and the plate was pulled out together

with the screw. During this maneuver the ulna fractured longitudinally through the screw holes. The fracture healed uneventfully with plaster cast immobilization.

Results of measurements of range of motion of the wrists at follow-up are presented in Table II. Mean grip strength of the operated limb measured preoperatively 18 kg (range : 0-42 kg) and postoperatively 26 kg (range : 2-60 kg). The difference was statistically significant ( $P=0.002$ ).

Preoperatively mean ulnar variance measured 3 mm (range : -2, 9) and postoperatively 1mm (range : -4, 7). Mean shortening was 2 mm (range : 1, 4).

Mean differences in DASH and PRWE scores between men and women, smokers and nonsmokers, whether or not a trauma was involved, between surgery on the dominant or non-dominant side and whether an oblique or horizontal osteotomy was used, are presented in Table III. Mean DASH and PRWE scores were significantly better in smokers. PRWE score was worse in patients with a history of wrist trauma. Results of linear and multiple regression analyses for the DASH and PRWE scores are presented in Tables IV and V. Outcomes were significantly better in smokers, when the dominant side was operated on and when the follow-up was longer. The adjusted determination coefficient  $R^2$  was 0.31 for the DASH and 0.33 for the PRWE score.

The patient who was operated on for degeneration of the distal radioulnar joint had a preoperative ulnar variance of -2 mm. His VAS score improved from 9 to 2, postoperatively the DASH score was 18 and the PRWE score 26. His pre- and postoperative X-rays are shown in Figure 2.

## DISCUSSION

In the present study, 81% of patients would undergo the same operation again. This is similar to the findings of Stockton et al. with 84% satisfied patients in a systematic review (27). Reasons why patients would not undergo the operation again in the present study were wrong indication (Essex Loprosti injury), mental problems, complications (delayed union, problems during hardware removal) and persistent pain. Not all ulnar wrist pain can be diagnosed as ulnocarpal impaction and solved by ulnar shortening, even in the presence of a positive ulnar variance.

In the present study, mean grip strength improved significantly compared to preoperative values. Nevertheless, 46% of patients said yes when they were asked if they experienced weakness. In the study of Cherchel et al. 39% of patients complained of weakness (6).

In our study the mean postoperative VAS score of 2.6 had significantly improved when compared with reported preoperative values. Mean postoperative VAS score was 4 in the study of Vandenberghe et

al. (31) and 3 in the study of Fulton et al. (12). In the present study, a high number of patients (57%) still felt ulnar wrist pain at the time of follow-up. Ashan et al. reported persistent wrist pain in only 2 out of 30 patients (7%) (1). In the study of Cherchel et al. 22% reported postoperative pain (6).

Mean DASH score of 22 in the present study was similar to other studies. Vandenberghe et al. reported a mean DASH score of 26 (31) and Fulton et al. a mean score of 37 (12). A better mean score of 12 was reported by Ahsan et al. (1). In the present study mean PRWE score was 33, which is similar to the mean PRWE score of 40 reported by Rajgopal et al. (23).

We found that length of follow-up influenced DASH and PRWE scores. Reasons why results may be better with a longer follow-up is that patients may have adapted their activities or that it may take long time to recover from an ulnar shortening. Several studies with long term follow-up reported good DASH scores. In the study of Fufa et al. with a mean follow-up of 10 years, 88% of patients were either satisfied or very satisfied and 91% would have the same procedure again. Average pain rating was 2 out of 10 at final follow-up and mean DASH score was 11 (range, 0-39) (11). A mean DASH of 9 was reported by Tatabe et al. in a study with a mean follow-up of 11 years (29). High satisfaction was reported by Cherchel et al. with a mean follow-up of six years; 94% would undergo the same operation again and mean DASH was 18 (6).

In contrast to other studies we found better DASH and PRWE scores in smokers. Rajgopal et al. had significantly poorer mean PRWE scores in smokers (23) than in nonsmokers (28,23). Fulton et al. reported higher mean VAS (4 versus 2) and DASH scores (51 versus 30) in smokers (12). Moermans et al. did not find a difference in DASH score between smokers and non-smokers (21). It is not clear why results were better in smokers in the present study. Smoking may increase the risk of nonunion but may not affect DASH and PRWE scores in relatively young and active patients after healing of the osteotomy.

We had a nonunion rate of 8%. In many studies there were no nonunions (5-8,14,15,18,29). Gaspar et al. reported a nonunion rate of 6% (4 out of 72) with a higher risk of nonunion in smokers (13).

Rajgopal et al. had 8% nonunions (6 out of 53) (23). Vandenberghe et al. had 12% nonunions (3 out of 25) (12%) (31) and Fulton et al. reported 18% nonunions (5 out of 28) (12).

Plate irritation following ulnar shortening osteotomy is common. In the present study, plates were removed in 46% of patients. Plate removal was reported in 13% of cases (4 out of 30 patients) by Ahsan et al. (1), in 18% by Gaspar et al. (13), in 20% by Vandenberghe et al. (31), in 30% by Fufa et al. (10 out of 33) (11), in 39% by Fulton et al. (11 out of 28 patients) (12), in 45% in by Rajgopal et al. (23), in 55 % by Iwasaki et al. (29 out of 53 wrists) (14), in 67% (12 out of 18 patients) by Cherchel's et al. (6) and in 95% (69 out of 73) by Tatebe et al. (29).

In the present study, fracture of the ulna during plate removal occurred in one patient. Rajgopal et al. reported refracture in 4 out of 34 patients in whom hardware had been removed. Two needed additional surgery and four could be treated in a cast (23).

An alternative for ulnar shortening osteotomy is the open or arthroscopic wafer procedure (24,27). Vandenberghe et al. compared the results of ulnar shortening osteotomy with the arthroscopic wafer procedure. No differences in outcome were found, but the advantage of the wafer procedure was that nonunion or plate removal were not required (31). Available evidence showed that arthroscopic and open wafer procedure may be viable alternatives to the more popular ulnar shortening, but clinical superiority is yet to be established (27).

It has been suggested that ulnar shortening may have a stabilizing effect on the distal radio-ulnar joint (2), but this was not the case in two patients in our series. Persistent instability of the distal ulna may be a reason for dissatisfaction or a high DASH score. Patients may also be dissatisfied with ulnar shortening if there are concurrent problems such as carpal instability (17). Patients with workers' compensation had significantly poorer PRWE scores (23), worse clinical scores (14) and significant higher DASH scores (60 versus 26) (11).

The present study has several limitations. It was retrospective and preoperative DASH, PRWE scores and range of motion were not available. Preoperative VAS was asked at the time of follow-

up which may not be totally accurate. Different causes of ulnar wrist pain were included (idiopathic and posttraumatic). One patient with a negative ulnar variance was also included in the study. Other parameters that may influence outcome of ulnar shortening such as workers' compensation, mental problems or joint hyperlaxity were not studied.

Twenty percent of patients were lost to follow-up in the present study. However, this is a lower percentage than in other studies with 21% to 61% of cases lost to follow-up (1,6,11,12,21,23).

It can be concluded that ulnar shortening osteotomy can be performed to treat ulnar wrist pain caused by ulnocarpal impaction. It may also be used in patients with moderate osteoarthritis of the distal radioulnar joint, however, more investigation are required before any conclusion can be made for this indication. Ulnar shortening cannot resolve pain in all patients and a high percentage will need an additional operation to remove the hardware.

## REFERENCES

1. Ahsan Z S, Song Y, Yao J. Outcomes of ulnar shortening osteotomy fixed with a dynamic compression system. *J Hand Surg.* 2013 ; 38-A : 1520-1523.
2. Arimitsu S, Moritomo H, Kitamura T. et al. The stabilizing effect of the distal interosseous membrane on the distal radioulnar joint in an ulnar shortening procedure : a biomechanical study. *J Bone Joint Surg.* 2011 ; 93-A : 2022-2030.
3. Barbaric K, Rujevcan G, Labas M. et al. Ulnar Shortening Osteotomy After Distal Radius Fracture Malunion : Review of Literature. *Open Orthop.* 2015 ; 9 : 98-106.
4. Barry J A, Macksoud W S. Cartilage-retaining wafer resection osteotomy of the distal ulna. *Clin Orthop Relat Res.* 2008 ; 466 : 396-401.
5. Chen N C, Wolfe S W. Ulna shortening osteotomy using a compression device. *J Hand Surg.* 2003 ; 28-A : 88-93.
6. Cherchel A, Vandendungen S, Moermans J P. et al. Ulna-shortening osteotomy : subjective appreciation and long-term functional outcome. *Acta Orthop Belg* 2012 ; 78 : 317-322.
7. Chun S, Palmer A K. The ulnar impaction syndrome : follow-up of ulnar shortening osteotomy. *J Hand Surg.* 1993 ; 18-A : 46-53.
8. Clark S M, Geissler W B. Results of ulnar shortening osteotomy with a new plate compression system. *Hand (NY).* 2012 ; 7 : 281-285.
9. De Smet L, Fabry G. Orientation of the sigmoid notch of the distal radius : determination of different types of the

- distal radioulnar joint. *Acta Orthop Belg.* 1993 ; 59 : 269-272.
10. De Smet L, Claessens A, Fabry G. Gymnast wrist. *Acta Orthop Belg.* 1993 ; 59 : 377-380.
  11. Fufa D T, Carlson M G, Calfee R P. *et al.* Mid-term results following ulna shortening osteotomy. *HSS J.* 2014 ; 10 : 13-17.
  12. Fulton C, Grewal R, Faber K J. *et al.* Outcome analysis of ulnar shortening osteotomy for ulnar impaction syndrome. *Can J Plast Surg.* 2012 ; 20 : e1-5.
  13. Gaspar MP, Kane PM, Zohn RC. *et al.* Variables prognostic for delayed union and nonunion following ulnar shortening fixed with a dedicated osteotomy plate. *J Hand Surg.* 2016 ; 41-A : 237-243.
  14. Iwasaki N, Ishikawa J, Kato H. *et al.* Factors affecting results of ulnar shortening for ulnar impaction syndrome. *Clin Orthop Relat Res.* 2007 ; 465 : 215-219.
  15. Iwatsuki K, Tatebe M, Yamamoto M. *et al.* Ulnar impaction syndrome : incidence of lunotriquetral ligament degeneration and outcome of ulnar-shortening osteotomy. *J Hand Surg.* 2014 ; 39-A : 1108-1113.
  16. Jungbluth P, Frangen TM, Arens S, Muhr, Kälicke T. The undiagnosed Essex-Lopresti injury. *J Bone Joint Surg.* 2006 ; 88-B : 1629-1633.
  17. Loh Y C, Van Den Abbeele K, Stanley J K. *et al.* The results of ulnar shortening for ulnar impaction syndrome. *J Hand Surg.* 1999 ; 24-B : 316-320.
  18. Luria S, Lauder A J, Trumble T E. Comparison of ulnar-shortening osteotomy with a new Trimed dynamic compression system versus the Synthes dynamic compression system : clinical study. *J Hand Surg.* 2008 ; 33-A : 1493-1497.
  19. MacDermid JC. Development of a scale for patient rating of wrist pain and disability. *J Hand Ther.* 1996 ; 9 : 178-183.
  20. MacDermid JC, Turgeon T, Richards RS, Beadle M, Roth JH. Patient rating of wrist pain and disability : a reliable and valid measurement tool. *J Orthop Trauma.* 1998 ; 12 : 577-586.
  21. Moermans A, Degreef I, De Smet L. Ulnar shortening osteotomy for ulnar ideopathic impaction syndrome. *Scand J Plast Reconstr Surg Hand Surg.* 2007 ; 41 : 310-314.
  22. Palmer A K, Werner F W. Biomechanics of the distal radioulnar joint. *Clin Orthop Relat Res.* 1984 ; 187 : 26-35.
  23. Rajgopal R, Roth J, King G, Faber K, Grewal R. Outcomes and complications of ulnar shortening osteotomy : an institutional review. *Hand.* 2015 ; 10 : 535-540.
  24. Sachar K. Ulnar-sided wrist pain : evaluation and treatment of triangular fibrocartilage complex tears, ulnocarpal impaction syndrome, and lunotriquetral ligament tears. *J Hand Surg.* 2012 ; 37-A : 1489-1500.
  25. Sammer D M, Rizzo M. Ulnar impaction. *Hand Clin.* 2010 ; 26 : 549-557.
  26. Scheker LR, Severo A. Ulnar shortening for the treatment of early-posttraumatic osteoarthritis at the distal radioulnar joint. *J Hand Surg.* 2001 ; 26-B : 41-44.
  27. Stockton DJ, Pellentier ME, Pike JM. Operative treatment of ulnar impaction syndrome : a systematic review. *J Hand Surg.* 2015 ; 40-E : 470-476.
  28. Tatebe M, Nakamura R, Horii E. *et al.* Results of ulnar shortening osteotomy for ulnocarpal impaction syndrome in wrists with neutral or negative ulnar variance. *J Hand Surg.* 2005 ; 30-B : 129-32.
  29. Tatebe M, Shinohara T, Okui N. *et al.* Clinical, radiographic, and arthroscopic outcomes after ulnar shortening osteotomy : a long-term follow-up study. *J Hand Surg.* 2012 ; 37-A : 2468-2474.
  30. Thuysbaert G, Ringburg A, Petronilia S. *et al.* Measurement of ulnar variance and radial inclination on X-rays of healed distal radius fractures. With the axis of the distal radius or ulna? *Acta Orthop Belg.* 2015 ; 81 : 308-314.
  31. Vandenberghe L, Degreef I, Didden K. *et al.* Ulnar shortening of arthroscopic wafer resection for ulnar impaction syndrome. *Acta Orthop Belg.* 2012 ; 78 : 323-326.