



# THE CENTRAL AFRICAN JOURNAL OF MEDICINE

Vol. 58, Nos. 5/6

CONTENTS

May/August 2012

## ORIGINAL ARTICLES

Mortality within 24 hours of admission to the Paediatric Unit, Harare Central Hospital, Zimbabwe...

HA Mujuru, RA Kambarami.....17

Investigation of the effect of Stalanev (Stavudine, Lamivudine and Nevirapine) treatment on plasma lactate levels in adults attending Beatrice Road and Wilkins Infectious Diseases Hospital Opportunistic Infections Clinics in Harare, Zimbabwe.....

G Malunga, WB Mujaji, C Musarurwa, T Nyamayaro.....22

## CASE REPORT

~~Rhabdomyosarcoma~~ Rhabdomyosarcoma of the orbit in a four months old infant in Zimbabwe: A case report.....

Chitsike I, Masanganise R, Sibanda C, Kuona.....26

## NOTES AND NEWS

Instructions to Authors.....

*Central African Journal of Medicine*.....29

# Rhabdomyosarcoma of the orbit in a four months old infant in Zimbabwe: A case report

\*I CHITSIKE, \*\*R MASANGANISE, \*\*\*D SIBANDA, \*P KUONA

## Abstract

Infants younger than one year of age with Rhabdomyosarcoma appear to have worse prognosis compared to older children due partly to high rates of local failure. We report a 4 months old infant with orbital rhabdomyosarcoma with poor outcome. Reluctance to use aggressive local control measures and suboptimal chemotherapy dosing are significant contributory factors. Call is made for need for more studies to determine appropriate local therapy in infants with rhabdomyosarcoma.

*Cent Afr J Med 2012;58(1/4) 26-29*

## Introduction

Rhabdomyosarcoma is known to be the commonest primary paediatric orbital malignancy seen in the developed countries to date. It is widely accepted that the tumour arises independently of the muscles and probably develops from undifferentiated mesenchymal cells in the orbit, conjunctiva, eyelid or anterior uveal tract. Rhabdomyosarcoma (RMS) has an incidence of about 5% among orbital biopsies of children and adolescents, the orbit being the primary site of origin in 10% of cases and the average age of onset being 5 to 7 years of age. The tumour is more aggressive and carries a poorer prognosis in infancy. Clinically 80 to 100% of patients present with proptosis, 80% with globe displacement, 30 to 50% with blepharoptosis, 60% with conjunctival and eyelid swelling, 25% with palpable mass, while 10% present with pain. Histologically there are three types: the embryonal cell type being the commonest and has a good prognosis (94% 5-year survival rate), the alveolar cell type is the second in frequency but has a poorer prognosis (74% 5-year survival rate) and the botryoid cell type that rarely occurs in the orbit.<sup>1,3</sup>

## Case Report

A 4 months old baby girl presented to Sekuru Kaguvi Hospital Eye Unit with a history of swelling of the right eye dating from 2 months of age. The mother initially noticed redness of the eye followed by swelling and

protrusion of the globe. She was seen by the ophthalmologist who noted that the right eye had axial proptosis measuring 34mm (using a transparent ruler). The proptosis was slightly deviated medially. It was non-reducible. There was conjunctival injection and chemosis. There was exposure keratopathy with a melted cornea inferiorly and a descematocele superiorly. Anterior segment structures were not visible. The eyelids were normal but there was widening of palpebral fissure height. An orbital mass was palpable infero-temporally. The mass was soft, non-tender, non-pulsatile and without bruits on auscultation. The left eye was otherwise normal. There was no parotid or sub-mental lymphadenopathy. A working diagnosis of a right retinoblastoma with extra orbital extensions was suggested. The differential list included rhabdomyosarcoma, lymphoma, and neuroblastoma. The patient was then referred to the paediatric oncology unit for further management.

On general examination in the paediatric oncology unit the marked proptosis of the right eye was noted as shown in figure 1. The growth of the infant was within normal range with a weight of 5.6kg (10-50<sup>th</sup> centile), length 62cm (50<sup>th</sup> centile) and head circumference 41.5cm (50-90<sup>th</sup> centile). Examination of the rest of the systems revealed an opisthotonic baby with right upper facial nerve palsy, generalized hypertonia and increased reflexes. The abdomen was distended with a 4cm hepatomegaly. The remainder of the physical examination was unremarkable. There was no

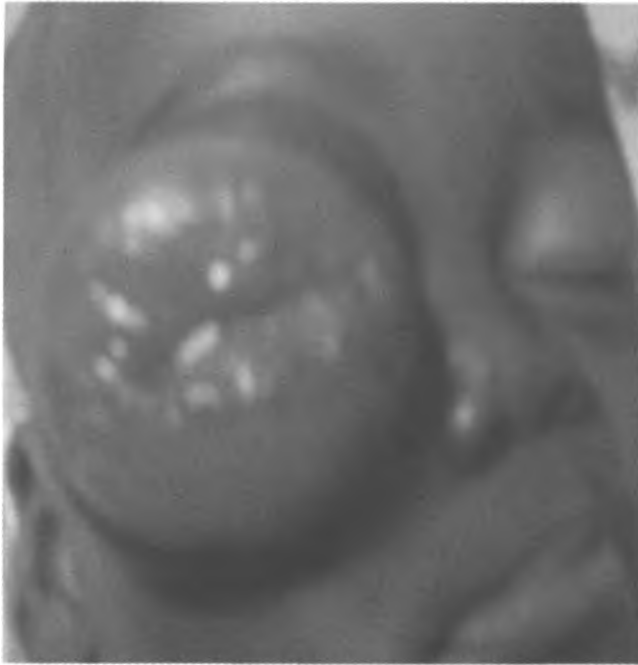## Correspondence to:

Dr Inam Chitsike,  
Department of Paediatrics and Child Health  
University of Zimbabwe, College of Health Sciences  
P O Box A178, Avondale, Harare, Zimbabwe

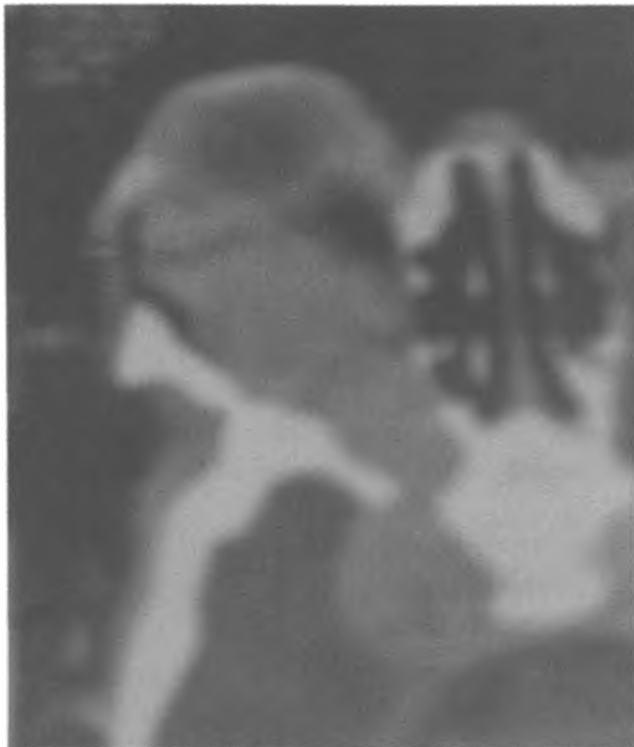
\* Department of Paediatrics and Child Health  
University of Zimbabwe, College of Health Sciences  
P O Box A178, Avondale, Harare, Zimbabwe  
\*\*Department of Ophthalmology  
University of Zimbabwe, College of Health Sciences  
P O Box A178, Avondale, Harare, Zimbabwe  
\*\*\*Sekuru Kaguvi Eye Unit, Parirenyatwa Hospital  
P O Box CY198, Causeway  
Harare, Zimbabwe

evidence of distant metastatic disease. Laboratory investigations showed normal full blood count and biochemical values.

*Figure I: Picture showing marked proptosis of the right eye.*



*Figure II: CT scan right orbit and brain.*



A CT scan of the brain revealed the following findings:  
“Large right lobulated intra orbital retro-bulbar mass

extending into the middle cranial fossa that was hyperdense and enhanced following contrast infusion. The mass incorporated the optic nerve, right side of optic chiasm and right cavernous sinus. There was no associated bony erosion or thickening”. The differentials suggested by the radiologist included optic nerve glioma and lymphoma.

The lesion was biopsied for histology and initially reported as: “Sections show conjunctiva with an underlying lesion comprised of small cells with scanty cytoplasm and hyperchromatic nuclei. The appearances are consistent with Embryonal Rhabdomyosarcoma” it was suggested that immunohistochemistry would be helpful. Part of the biopsied tissue was sent to St Jude Children's Research Hospital for immunohistochemistry that is not locally available. Immunohistochemistry confirmed rhabdoid tumour although it was not possible to decide whether the tumour originated in the middle cranial fossa and brain with extension into the orbit or vice versa, hence the suggestion of a possible atypical teratoid-rhabdoid tumour. However, both tumours are identical except for their sites of origin.

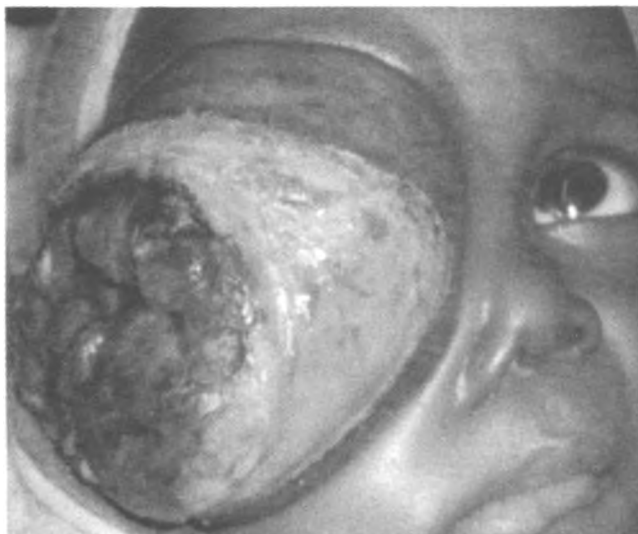### **Treatment**

The main stay of treatment in this patient was chemotherapy. The patient received vincristine, dactinomycin and ifosfamide the dosages calculated by weight and body surface area depending on the chemotherapeutic agent. The patient was given 50% of the prescribed chemotherapy doses at the initial phase as recommended for that age.<sup>4,5</sup> Radiotherapy was not used in this patient because of her age and location of tumour. Surgical intervention was not employed in our case because of intracranial involvement that carried a very poor surgical outcome and as recommended in other studies.<sup>6,7</sup>

### **Follow up**

The patient responded well to 2 cycles of chemotherapy given at 3 weeks interval. The swelling began to subside initially but by the third cycle the size of the tumour was increasing with evidence of local disease progression but with no distant metastasis on clinical examination. At that stage a decision not to proceed with chemotherapy but offer palliative care was made.

Figure III: Picture showing local progression of disease six weeks after commencing chemotherapy.



## Discussion

Published literature show that the incidence of rhabdomyosarcoma (RMS) is higher during the first year of life.<sup>8,9</sup> Our patient was four months old when the diagnosis was made and could be the youngest case with this disease to be reported in Zimbabwe. This young age of presentation is uncommon for Zimbabwe although from the literature it appears young age of presentation is not unusual.<sup>10,12</sup> In a series of 33 South African children with RMS, Schyff and colleague reported the youngest age to be 7 days old.<sup>13</sup>

In Zimbabwe a total of 102 children under the age of 15 years with RMS were registered with the Zimbabwe National Cancer Registry between 2000 and 2009. The male to female ratio was 1.7:1. A total of 48 were not classified. Of those classified, embryonal rhabdo was the commonest classification with 38 cases, followed by alveolar 14 cases and pleomorphic only 2 cases.<sup>14</sup>

Known prognostic factors associated with unfavourable outcome include young age at onset, alveolar / undifferentiated tumour and advanced group and stage of tumour on assessment. Joshi and colleagues confirmed that age at presentation was an independent prognostic factor after adjusting for important prognostic factors. They also showed that patients less than one year of age at diagnosis were associated with worse outcome.<sup>15</sup>

However, this finding has not been supported by other researchers who in a study of 78 patients younger than one year, did not find age to be an important prognostic determinant of outcome in rhabdomyosarcoma.<sup>10</sup>

### **Histopathology.**

The histopathology in our case was embryonal rhabdomyosarcoma. This is in line with the findings in the Zimbabwe National Cancer Register where embryonic RMS was the commonest histological type

reported.<sup>14</sup> This finding is similar to that by the Children's Oncology Group where embryonal rhabdomyosarcoma was the commonest histological type ( 57%) in their group of children less than one year age.<sup>5</sup> Other studies however have shown different results. Ragab et al reported significantly higher proportions of undifferentiated sarcoma and botryoid pathology.<sup>10</sup> Salloum et al found higher frequency of alveolar and poorly differentiated histologic subtypes in infants aged under one year.<sup>11</sup>

### **Treatment received and outcome**

The treatment of RMS in infants is a challenge. A lot depends on patient age, accurate patient evaluation, stage and severity of disease. Our patient was four months old, with RMS involving the orbit with intracranial extensions and no clinically significant lymphadenopathy. Local disease control in terms of surgical excision was not undertaken because of the likelihood of poor surgical outcome and as advocated by Heyn et al.<sup>16</sup> Radiotherapy was not given in our patient because of the patient's age and extent of intracranial involvement.<sup>17</sup> Our patient received multiple-agent therapy but the choice of drugs was severely compromised by drug availability.

In addition to that our patient received 50% of chemotherapy dose recommended for older children. This is in line with recommendations from the IRS protocol which was amended so that infants would receive only 50% of recommended dose for older children in order to mitigate the toxic effects of chemotherapeutic agents on infants.<sup>3</sup> This low dosage, probably suboptimal treatment could also have contributed to poor outcome in our patient.

Researchers from the Children's Oncology Group have concluded that reluctance to use aggressive local control measures because of concerns regarding morbidity in infants may lead to high failure rate.<sup>16</sup> There are now calls to review the management of these patients in order to improve the outcome in infants.<sup>5</sup> Findings from Puri *et al* suggest that appropriate radiotherapy in very young children can be administered to achieve reasonable local control.<sup>17</sup> However, for resource challenged countries the problems of drug availability outweigh the dilemmas of choosing the most appropriate treatment protocol, as is the case locally.

## Conclusion

In conclusion, we report a case of RMS in a 4 months old, youngest reported case in Zimbabwe who presented with aggressive disease and failed on treatment. Our patient had some poor prognostic factors that could explain the poor outcome, the young age at presentation, inadequate treatment for local control such as surgery and radiotherapy and probably suboptimal chemotherapy dosing. It is essential that studies are carried out to determine appropriate local

therapy particularly use of radiotherapy in infants and pharmacokinetic studies for optimum chemotherapy dosing.

### Acknowledgement

The authors would like to thank Dr Ibrahim Qaddoumi, Department of Oncology and Director Telemedicine Programme International Outreach Program for facilitating the review of the histology and also his comments on the manuscript. We also thank Dr Jesse Jenkins the pathologist for review of histology.

### References

1. Shields JA, Shields CL. Orbital rhabdomyosarcoma: review for the ophthalmologist. *Surv Ophthalmol* 2003;48:39-57.
2. Company F, Pedram M, Rezaei N. Clinical characteristics and prognosis of childhood rhabdomyosarcoma in 60 patients treated at a single institute. *Acta Med Iran* 2011;49(4): 219-24.
3. Raney RB, Walterhouse DO, Meza JL, Andrassy RJ, Breneman JC, Crist WM, Maurer HM, Meyer WH, Parham DM, Anderson JR. Results of the Intergroup Rhabdomyosarcoma Study Group D9602 protocol, using vincristine and dactinomycin with or without cyclophosphamide and radiation therapy, for newly diagnosed patients with low-risk embryonal rhabdomyosarcoma: a report from the Soft Tissue Sarcoma Committee of the Children's Oncology Group. *J Clin Oncol* 2011;29:1312-8.
4. Ferrari A, Casanova M. Current chemotherapeutic strategies for rhabdomyosarcoma. *Expert Rev Anticancer Ther* 2005;5:283-94.
5. Malempati S, David A, Rodeberg MD, Sarah S Donaldson MD, Elizabeth R. Lyden MS *et al.* Rhabdomyosarcoma in infants younger than 1 year. *Cancer* 2011;117:3493-3501.
6. Wharam M, Beltangady M, Hays D, *et al.* Localized orbital rhabdomyosarcoma. An interim report of the Intergroup Rhabdomyosarcoma Study Committee. *Ophthalmology* 1987;94(3):251-4.
7. Oberlin O, Rey A, Anderson J, *et al.* Treatment of orbital rhabdomyosarcoma: survival and late effects of treatment--results of an international workshop. *J Clin Oncol* 2001;19(1):197-204.
8. Gurney JG, Severson RK, Davis S, Robison LL. Incidence of cancer in children in the United States. *Cancer* 1995;75:2186-95.
9. Kaatsch P, Haaf G, Michaelis J. Childhood malignancies in Germany: methods and results of a nationwide registry. *Eur J Cancer* 1995;31A:9939.
10. Ragab AH, Heyn R, Tefft M, Hays DM, Newton WA, Beltangady M. Infants younger than 1 year of age with rhabdomyosarcoma. *Cancer* 1986;58:2606-10.
11. Salloum E, Flamant F, Rey A, Caillaud JM, Friedman S, Valteau D, *et al.* Rhabdomyosarcoma in infants under one year of age: experience of the Institut Gustave-Roussy. *Med Pediatr Oncol* 1989;17(5):424-8.
12. Brown BJ, Oluwasola OA. Childhood rhabdomyosarcoma in Ibadan, Nigeria: 1984-2003. *Ann Trop Paediatr* 2006;26(4):349-55.
13. Schyff AV, Stefan, CD. Clinical characteristics and outcome of rhabdomyosarcoma in South African children. *Afr J Haematol Oncol* 2010;1:40-7.
14. Zimbabwe National Cancer Registry 2000 to 2009.
15. Joshi D, Anderson JR, Paidas C, Breneman J, Parham DM, Crist W. Age is an independent prognostic factor in rhabdomyosarcoma: a report from the soft tissue sarcoma committee of the children's oncology group. *Pediatr Blood Cancer* 2004;42:64-73.
16. Heyn R, Ragab A, Raney RB, *et al.* Late effects of therapy in orbital rhabdomyosarcoma in children: a report from the Intergroup Rhabdomyosarcoma Study. *Cancer* 1986;57(9): 1738-43.
17. Puri DR, Wexler LH, Meyers PA, La Quaglia MP, Healey JH, Wolden SL. The challenging role of radiation therapy for very young children with rhabdomyosarcoma. *Int J Radiat Oncol Biol Phys* 2006;65:1177-84.



This work is licensed under a  
Creative Commons  
Attribution – NonCommercial - NoDerivs 3.0 License.

To view a copy of the license please see:  
<http://creativecommons.org/licenses/by-nc-nd/3.0/>

This is a download from the BLDS Digital Library on OpenDocs  
<http://opendocs.ids.ac.uk/opendocs/>