



# The CENTRAL AFRICAN JOURNAL OF MEDICINE

Dr. DAVID LIVINGSTONE

Vol. 3. No. 11.

NOVEMBER, 1957.

## C O N T E N T S

### ORIGINAL ARTICLES

Subdural Haematoma in Infancy	<i>L. F. Levy, T. I. Hoen and I. S. Cooper</i> . . . . .	435
Brucella Pylonephritis	<i>R. M. Honey, M. Gelfand and N. H. Myers</i> . . . . .	465
Medical Education	<i>A. Bourne</i> . . . . .	469

### EDITORIALS

Disease in the European and African Child	473
Golden Jubilee of Royal Society of Tropical Medicine	475
A Dental Contribution	475
Surgeons of Mashonaland	477
The Borradaile Trust . . . . .	478
The Mentally Handicapped Child . . . . .	480
"84" Baines . . . . .	481
Correspondence . . . . .	481
In Rhodesia Then . . . . .	482
Book Review . . . . .	483
The Journal Library . . . . .	483
Medical Council . . . . .	484

## Chronic *Brucella* Pyelonephritis with Calcification

SHORT REVIEW OF THE LITERATURE  
AND REPORT OF A CASE

BY

R. M. HONEY, F.R.C.S. (Ed.)

Consulting Urologist, General Hospital, Salisbury;

M. GELFAND, O.B.E., M.D., F.R.C.P.

Consulting Physician, General Hospital, Salisbury;

AND

N. H. MYERS, B.A., M.B., CH.B.

Pathologist, Salisbury.

The localisation of brucellosis in the urinary tract is an infrequently reported condition. The paucity of recorded cases may be due to the rarity of the condition or to the fact that the profession as a whole is not sufficiently aware of the possibility of urinary tract involvement in brucellosis. Having recently investigated a patient who is suffering from pyelonephritis and cystitis occurring as a complication of brucellosis, we were prompted to publish his case record with the aim of calling the attention of the profession to the various aspects of this disease and emphasising its localisation in the genito-urinary system.

### HISTORICAL DATA

In 1887 David Bruce was the first to demonstrate that the *Micrococcus melitensis* was the causative organism of Malta fever. He showed that no less than 50 per cent. of the goats on the island were infected and that the disease was transmitted through their milk. He also recovered the organism from the spleen of persons dying of the disease.

In 1897 Bang—a Danish veterinary surgeon—first isolated the *Brucella abortus* and demonstrated its causative role in contagious abortion in cattle. In 1917 Alice Evans demonstrated the similarity between the cultural, morphological and serological characteristics of *Brucella abortus* and *Micrococcus melitensis*, and grouped them under the generic term *Brucella*. The disease caused by these organisms became known as brucellosis or undulant fever.

In 1921 Bevan, working in S. Rhodesia, was the first to show that the organism causing contagious abortion in cattle was infectious to man, and he and Orpen demonstrated a case from whom *Brucella abortus* was cultured from an infected joint.

In 1924 Keefer reported the first human infection with *Brucella abortus* in the United States.

Many observers have pointed out the difficulty of diagnosis in this disease and how it mimics other diseases affecting many organs, such as the heart, bones and joints, as well as the genital and urinary systems. Relatively few reports of urinary involvement by brucellosis appear in the literature, although brucella orchitis, epididymitis and prostatitis have been described somewhat more frequently.

In 1929 Simpson and Frazier reported three cases of seminal vesiculitis, prostatitis, epididymitis and orchitis occurring in 63 cases of undulant fever. In the same year Wainwright held that 20 per cent. of patients with melitensis type and 4 per cent. of those with abortus type developed orchitis.

In 1937 Boyd reported a case of a man who had suffered a chronic febrile illness for eighteen years, during which time several agglutination and other laboratory tests for brucellosis had been negative. He was known to have prostatitis, and after 18 years of ill health *Br. abortus* was eventually cultured from his prostatic secretion. It was eventually also cultured from the gall bladder and stools.

Clark (1939) stressed that brucellosis was frequently encountered in the south and southwest of the United States and that it affected the urinary tract more often than was suspected. He reported two cases of brucella prostatitis, but did not say on which laboratory tests he based his diagnosis. He claimed complete cure of the urinary complications by using the appropriate treatment for undulant fever, but gave no details of the treatment used. The main interest of this paper lies in its references to previous publications.

In 1938 Buckley reported a case of orchitis as a complication of brucellosis, the agglutination titre being 1:7280.

Reports of cases of pyelonephritis associated with brucellosis are rare. Strong and Musgrave in 1900 reported an autopsy on a patient dying of Malta fever, in which the kidneys showed haemorrhages.

In 1911 Casaneuve reported a case of Malta fever in which renal complications expressed in attacks of haematuria were present. In the same year Cantaloupe and Thibault also reported haematuria accompanying the disease. In 1934 Sharp pointed out that renal damage occurs and that brucellosis with renal insufficiency had been

known to cause death. Shuller in 1937 mentioned pain in the region of the kidneys and bladder and pus in the urine. Hardy said that cases with initial symptoms of cystitis and pyelonephritis thought to be tuberculous had been diagnosed as undulant fever through isolation of the organism from the urine and positive agglutination tests.

In 1950 Greene and Albers and again in 1952 Greene, Weed and Albers described two cases of chronic pyelonephritis due to *Brucella*. The first patient had been suffering from known brucellosis for four years prior to the onset of urinary symptoms of increased frequency of urination and suprapubic distress. The urine examination disclosed gross pyuria, and culture on the usual media was sterile. A plain roentgenogram of the urinary tract disclosed fine calcific shadows scattered throughout the renal parenchyma. Cystoscopy showed diffuse sub-acute cystitis and pyelograms revealed dilatation and clubbing of the calyces, with scarring and narrowing of some of the infundibula to the calyces. The agglutination of the serum for brucella occurred in a dilution of 1 in 200. On blood culture micrococci were cultured. *Brucella melitensis* was cultured from the urine and recovered from the spleen of a guinea pig two months after injection.

The second patient was a butcher who ten years prior to the onset of urinary symptoms had experienced an attack of brucellosis. When examined he had been suffering from attacks of urinary frequency, dysuria and haematuria for two years. Urinary examination revealed gross pyuria. The results of routine culture of the urine and culture for *M. tuberculosis* were negative. Culture on hormone blood agar plates under 10 per cent.  $\text{CO}_2$  tension incubated at  $37^\circ\text{C}$ . grew *Br. suis*. The agglutination reaction for brucella was positive in a dilution of 1/1,000.

On roentgenography extensive areas of calcification were noted in each kidney, and cystoscopy revealed a bladder capacity of 100 c.c. and scattered areas of acute inflammation. On pyelography the calyces and pelves were not distorted.

In a valuable paper in 1955, Abernethy, Price and Spink gave details of a further case of brucellar pyelonephritis which closely simulated tuberculosis. Their patient was a 46-year-old man who had suffered from urinary frequency, dysuria and haematuria for four months, and who had recently suffered from renal colic and had passed a stone. Gross pyuria was discovered. Cystoscopic examination revealed severe diffuse

granular cystitis. X-ray films of the abdomen showed an enlarged left kidney with multiple calcification in its upper portion. Prograde pyelogram showed no dye excretion from the left and moderate hydronephrosis on the right. *Br. suis*. was isolated from culture of the urine. Agglutination tests for *Brucella* were negative, which was shown to be due to the presence of blocking *Brucella* antibodies.

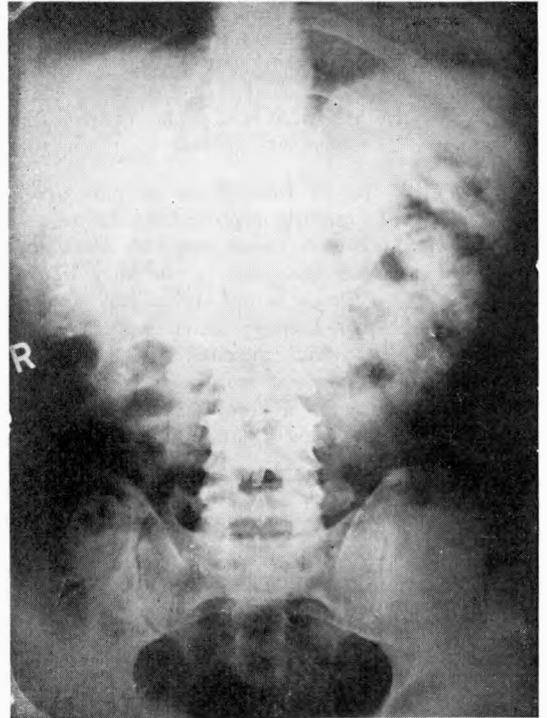


Fig. 1—Notice the widespread but patchy and rather faint calcified foci in both renal areas.

This report is of considerable value on account of the detailed histological description of the left kidney, which was removed surgically on the diagnosis of renal tuberculosis a week before the urine culture became positive for *Br. suis*. The microscopical examination of the kidney showed the close similarity between the lesions caused by *Br. suis*. and those of tuberculosis.

#### REPORT OF A CASE

The orthopaedic aspect of this case was reported previously by Trevor Jones (1955).

E.J., aged 50, is a Rhodesian European male who is employed in the civil service. In 1947 he developed a fever and a rash. The illness was diagnosed as "tick fever." The acute illness lasted three weeks. During the next six months he had a slight afternoon pyrexia and experienced pains in the joints of his

hands and feet. In February, 1948, while on holiday in Denmark, he sought medical advice about the pains in his knees and shoulders. He was referred to the Copenhagen Institute, where blood examination revealed a high agglutination titre to *Br. abortus*. No special therapy was advised, as it was considered that no specific remedy was known for brucellosis, which in any event was considered as a self-limiting disease. After six weeks he recovered and remained well until October, 1948, when he returned to Rhodesia. He then suffered pain in his left hip and right knee. Blood examination carried out in Salisbury gave a positive titre of 1:640 to *Br. abortus*, but blood culture was negative. The affected hip was swollen and tender and movements were markedly limited and painful. No bony abnormality was revealed on X-ray. He was put to bed with weight extension to the left leg, was treated with polyvalent militensis vaccine and with Bayer 205. After two months the movements of the hip had returned to normal. A plaster spica was applied for six weeks, followed by a weight-bearing caliper for six months.

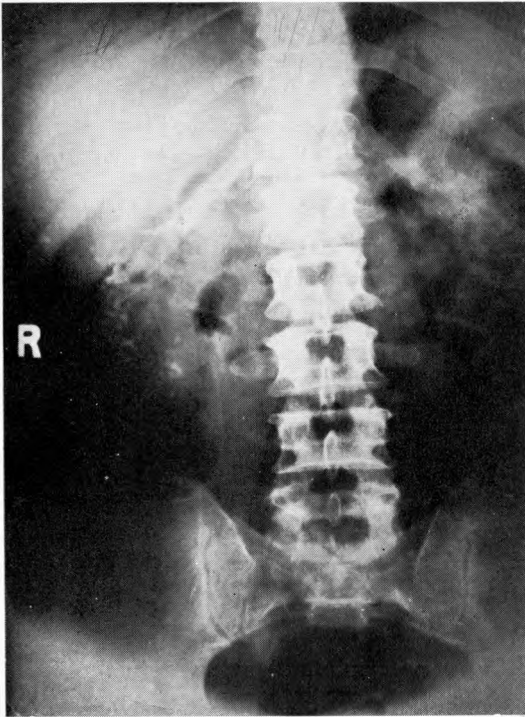


Fig. 2—Poor concentration of dye on intravenous pyelography.

He remained well until October, 1949, when he suddenly developed pain in the right hip. After a short course of chloromycetin, thick pus was aspirated from the right hip joint, from which *Br. abortus* was grown. Following this, in succession he developed an arthritis of the right ankle and abscess over the dorsum of the left foot and one over the lower end of his sternum. During this period he received terramycin and chloromycetin in large doses over a two-week period. He was then prescribed a polyvalent brucella

vaccine. During 1950 the acute phase again subsided. Movement of the hips was only slightly limited, and ankle movements full and painless.

In 1953 he suddenly developed an acute pain across the front of his chest, which proved to be a coronary thrombosis. Typical cardiographic changes were demonstrated. At this time also it was discovered that he had hypertension.

In 1954 he began to experience a stinging sensation at the end of micturition, and noticed that he was passing urine more frequently than usual by day and rising occasionally at night. In December, 1955, he passed bloody urine for two days, the bleeding being most marked towards the end of micturition.

In 1956 the pain on micturition was worse and he was experiencing marked increased frequency—by day and night. He was rising as often as eight times at night. He again noticed blood in his urine, which lasted for two days.

At no time did the patient complain of backache and, apart from the early acute phase in 1947 and a slight evening temperature in 1949, he has been afebrile throughout his illness.

On examination he was a small-built, well-proportioned man of fairly healthy complexion. The range of movement of all joints was full. There was a chronic abscess over the lower sternum. On the right leg above the lateral malleolus were three thin adherent scars, one of which had been draining pus off and on for three years. Just above these was a large diffuse reddened fluctuant area, which was only very slightly tender. Sixty ml. thick pus was aspirated, which on culture gave a growth of *Br. abortus*.

The blood pressure was 210:120. The heart was moderately enlarged, the enlargement being mainly left ventricular in type. The heart sounds were normal and the cardiograph showed deep and widened Q2 and Q3 with inversion of T2, T3, Tv5 and TAVF. The retinal vessels were unaffected and the discs normal. The liver and spleen were not palpable.

Neither kidney was palpable. Both testes and epididymi were normal. The prostate was normal, and vesicles were not palpable.

The urine contained a large number of pus cells, but no growth was obtained on any media.

An X-ray of the abdomen revealed diffuse patchy rather faint calcification throughout both kidney areas (Fig. 1). The concentration of dye on intravenous pyelography was poor and did not demonstrate the calyceal systems (Fig. 2). Blood calcium 10.4 mg. per cent. Serum phosphate 2.6 mg. per cent. Blood urea 47.5 mg. per cent. Urea clearance test 40.9 per cent. normal. Urine concentration test yielded a maximum specific gravity of 1009. The Addis count in a 12-hour concentrated specimen yielded a urine volume of 510 ml. leucocytes 101, 388,000 RBC, 6,528,000, epith. cells 62,500, hyaline casts 6,100.

On cystoscopic examination under pentothal anaesthesia the bladder capacity was found to be 160 ml. The bladder walls were acutely congested, with several superficial ulcers measuring about 1 to 1½ cm. diameter, to the surface of which flakes of purulent material adhered. Appearances were similar on the vault and on the base. Both ureteric orifices were normal in situation and appearance, except that the mucosa surrounding each was oedematous.

Catheters passed up each ureter with ease.

Retrograde pyelograms (Fig. 3) show pictures typical of chronic ulcerative pyelonephritis with distortion of the calyceal outlines by ulceration in some places and cicatricial contraction in others. The calcium deposits are numerous and situated round all the calyces.

#### COMMENT

This case demonstrates well numerous features of this disease. The bone and joint involvement is well shown, as well as the persistent abscesses in soft tissues. The hypertension can be attributed to the severe pyelonephritis, presumably caused by *Br. abortus*, and the coronary disease in turn being associated with the hypertension.

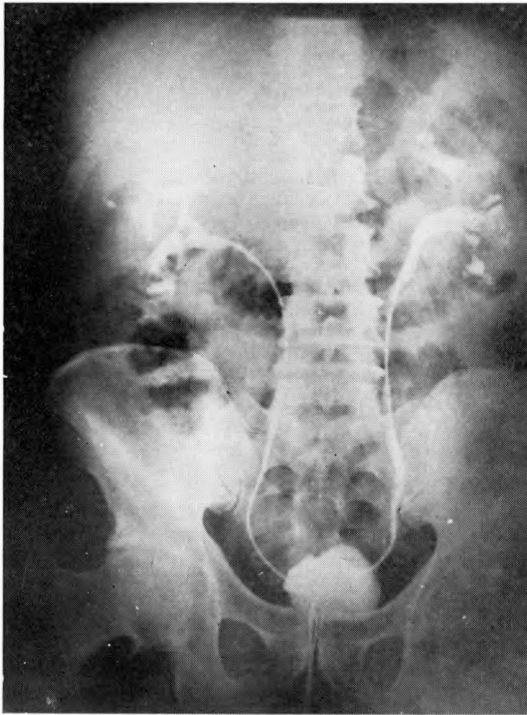


Fig. 3—Retrograde pyelogram showing distortion of the calyceal outlines by cicatricial contraction. The calcium deposits are numerous.

The urological features are very similar to those in the cases reported by Green and Albers, which showed a similar late involvement some years after a known acute febrile onset, with renal calcification and cystitis with decreased capacity.

The calcification is extensive and splashed over all areas of the kidney. It is somewhat different to that seen in tuberculosis, which usually involves and outlines definite groups of calyces, except when an entire kidney becomes quiescent and calcified. It also differs from nephrocal-

cinosis associated with hypercalcaemia, in which the calcium deposits are usually limited to the pyramids.

Apart from the difference in calcium deposition and the history of brucellosis, there is a great similarity between the ulcerative pyelonephritis seen in this case and that met with in tuberculosis.

In spite of the persistent draining sinus over the sternum and a constant abscess on the right leg from which pus may be aspirated every few weeks, a gross pyuria and obvious renal damage, he remains afebrile, feels well, has a good appetite, is well nourished and has lost little time off his work.

We should like to stress that in all cases of cystitis and pyelonephritis which do not respond to ordinary therapy, and in which the urine is sterile on culture on the usual media, brucellosis should be suspected.

#### SUMMARY

A case of brucellosis of nine years' standing, with marked pyelonephritis and cystitis, is reported.

The close similarity between renal brucellosis and clinical renal tuberculosis is demonstrated.

The literature is reviewed.

#### REFERENCES

- ABERNETHY, PRICE & SPINK (1955). *J. Amer. med. Assoc.*, 159, 1534.
- BEVAN, L. E. W. (1930). *Trans. Roy. Soc. trop. Med.*, 24, 93.
- BOYD, M. L. (1938). *J. Urol.*, 39, 717.
- BRUCE, SIR DAVID (1889). *Brit. med. J.*, 1, 1101 (quoted Clark, 1939).
- BUCKLEY, T. I. (1938). *Calif. & West. Med. J.*, 48, 175.
- CANTALOUPE & THIBAUD (1911). Quoted from Boyd, M. L. (1938), *J. Urol.*, 39, 717.
- CASENEUVE (1911). Quoted from Boyd, M. L. (1938), *J. Urol.*, 39, 717.
- CLARK, A. L. (1939). *J. Urol.*, 42, 249.
- EVANS, ALICE (1918). *J. infect. Dis.*, 22, 580 (quoted Clark, 1939).
- GREENE, L. F. & ALBERS, D. D. (1950). *Proc. Mayo Clinic*, 25, 638.
- GREENE, L. F., WEED, L. A. & ALBERS, D. D. (1952). *J. Urol.*, 67, 765.
- KEEFER (1924). *Med. Bull. Johns Hopkins Hospital* (quoted from Boyd, M. L. (1938), *J. Urol.*, 39, 717).
- SIMPSON, W. M. & FRAZIER (1929). *J. Amer. med. Assoc.*, 93, 1958.
- SHARP (1934).
- SHULLER (1937). *J. Okla. med. Assoc.*, 30, 50 (quoted Clark, 1939).
- STRONG, R. P. & MUSGRAVE, W. E. (1900). *Philad. med. J.*, 6, 996 (quoted Clark, 1939).
- TREVOR JONES, R. (1955). *C. Afr. J. Med.*, 1, 16.



This work is licensed under a  
Creative Commons  
Attribution – NonCommercial - NoDerivs 3.0 License.

To view a copy of the license please see:  
<http://creativecommons.org/licenses/by-nc-nd/3.0/>

This is a download from the BLDS Digital Library on OpenDocs  
<http://opendocs.ids.ac.uk/opendocs/>