



The CENTRAL AFRICAN JOURNAL OF MEDICINE

Dr. DAVID LIVINGSTONE

Vol. 4, No. 12.

C O N T E N T S

DECEMBER, 1958.

ORIGINAL ARTICLES

| | | |
|---|---|-----|
| Acute Neonatal Intestinal Obstruction | Charles Marks - - - - - | 509 |
| Angiography | J. M. Allcock - - - - - | 516 |
| Bilateral Congenital Absence of Radius | J. G. Borok - - - - - | 524 |
| Typhoid with Meningitis | M. A. Kibel and E. McNair | 526 |
| Clinical Endocrinology (Part II) | W. P. V. Jackson and R. Hoffenburg - - - - - | 529 |
| An Orthopaedic Bed | J. R. Little - - - - - | 533 |
| Cortisone in Dermatology | W. P. Elford - - - - - | 536 |
| Neurological Biographies: (2) James Collier | Macdonald Critchley - - - | 539 |
| The Writing of Medical Papers | C. Wilcocks - - - - - | 545 |

EDITORIALS

| | |
|--|-----|
| Fifth Year of <i>Central African Journal of Medicine</i> | 551 |
| Solitary Pulmonary Hypertension | 551 |
| Involuntary Laughter | 552 |

| | | | |
|-------------------------------|-----|------------------------------------|-----|
| Prevention of Rheumatic Fever | 552 | Native Liquors in S. Rhodesia | 558 |
| Drug Treatment of Disease | 553 | In Rhodesia Then | 560 |
| Lewellin Hospital, Kitwe | 553 | Book Reviews | 561 |
| The Redcliffe Hospital | 556 | Latest Pharmaceutical Preparations | 562 |

The Central African Journal of Medicine

Volume 4

DECEMBER, 1958

No. 12

Acute Neonatal Intestinal Obstruction*

BY

CHARLES MARKS, M.B., CH.B. (Cape Town),
M.R.C.P. (Edin.), F.R.C.S.
Surgeon, Salisbury.

The newborn infant ejected from his comfortable isothermic habitat into a hostile world has many physiological adjustments to make in the first four weeks of life. If, as a result of intestinal obstruction, the newborn infant persistently vomits, fails to pass meconium stools and develops abdominal distension, then it is mortally ill. Three factors will militate against a successful surgical outcome in these infants.

(1) **PREMATURITY.**—The premature infant not only responds badly to surgical handling, but is, as frequently, badly handled. Such babies do not tolerate rough or excessive surgical trauma, whilst the immature kidney is readily overloaded with fluid, resulting in excessive accumulation of extracellular fluid and oedema. Thus if parenteral fluids need to be administered it is wise to restrict this to 30 c.c./pound per day and to give it in the form of 5 per cent. dextrose in water. Administration of oxygen in high concentration in these infants is dangerous, for the association of prematurity, excessive oxygen administration and retrolental fibroplasia is well known.

(2) **INADEQUATE SUPPORTIVE MEASURES.**—Evaluation of the neonatal surgical patient is fraught with difficulty. He cannot relate his symptoms, he may be on the verge of shock without obvious sign, he may be prostrate with infection and evince no fever, and it is easy to overlook the infant's limited physiological reserve. To illustrate: a 7lb. infant has a total blood volume of 300 c.c. An operative loss of

only 30 c.c. of blood thus comprises 10 per cent. of his total blood volume. Whilst the oxygen consumption of an adult is 4 c.c. per kg. per metre of body surface, that of a newborn is 10 c.c. per kg. per metre. Thus it is important to prevent sudden and often fatal postoperative respiratory crises, to maintain a clear airway by pharyngeal and laryngeal aspirations and to decompress any abdominal distension that may impede diaphragmatic excursions.

Fluid and Electrolyte Therapy.—Seventy per cent. of the infant's total body weight is comprised of water and 50 per cent. of its total body weight is contained in its intracellular fluid, the extracellular fluid accounting for the remaining 20 per cent. Of this latter amount, 15 per cent. is contained in the interstitial tissues and 5 per cent. in the blood plasma.

| | | | |
|--------------|--------------------|---------------------|--------|
| 5% | 15% | 50% | 30% |
| Blood Plasma | Interstitial Fluid | Intracellular Fluid | Solids |

GENERAL RULES FOR THERAPY

Total Daily Requirements

The premature infant: 30 c.c. per pound weight. The newborn infant: 45 c.c. per pound weight. Severely dehydrated: 90 c.c. per pound weight.

Parenteral Saline Requirements

(a) 10 c.c. per pound per day for babies and children weighing less than 50 lb.

(b) 5 c.c. per pound per day for children over 50 lb., as the fluid and electrolyte requirements in older children contract down to adult levels with advancing age.

Blood Transfusions

In infancy, blood may be given either by the slow drip method or by the rapid technique.

(a) Slow intravenous drip: 30 c.c. per pound body weight is calculated so as to be administered over several hours.

* Address delivered before the Mashonaland Association of Surgeons on the 19th February, 1958.

Distribution of Electrolytes

Extracellular

| CATIONS | | ANIONS | |
|------------------------------|----------------------------|--|-----------|
| Sodium (Na ⁺) | 142 Milliequivalents/litre | Bicarbonate (HCO ₃ ⁻) | 28 Meq/l |
| Potassium (K ⁺) | 5 Meq/l | Chlorides (Cl ⁻) | 103 Meq/l |
| Calcium (Ca ⁺) | 5 Meq/l | Phosphates (PO ₄ ⁻) | 1 Meq/l |
| Magnesium (Mg ⁺) | 3 Meq/l | Sulphates (SO ₄ ⁻) | 1 Meq/l |
| | | Proteins | 16 Meq/l |
| | | Acids | 6 Meq/l |
| | 155 Meq/l | | 155 Meq/l |

Intracellular

| CATIONS | | ANIONS | |
|------------------------------|-----------|---|-----------|
| Sodium (Na ⁺) | 10 Meq/l | Bicarbonate (HCO ₃ ⁻) | 10 Meq/l |
| Potassium (K ⁺) | 140 Meq/l | Acid Phosphate (HPO ₄ ⁻) | 100 Meq/l |
| Magnesium (Mg ⁺) | 45 Meq/l | Sulphates (SO ₄ ⁻) | 20 Meq/l |
| | | Proteins | 65 Meq/l |
| | 195 Meq/l | | 195 Meq/l |

(b) Rapid technique. Blood is forced by syringe through a small peripheral vein, e.g., scalp. Not more than 10 c.c. should be administered at a time.

Effects of Rapid Fluid and Electrolyte Loss

The rapid loss of gastrointestinal fluids results in varying degrees of acidosis and alkalosis, depending on whether acid or base is predominantly lost. Quantitative assessment of this metabolic disturbance is made by estimation of serum chloride and the carbon dioxide combining power, appropriate electrolytic corrections then being made.

Thus: 4.2 c.c. of 1/6 molar ammonium chloride will lower the carbon dioxide combining power by 1 Meq per litre, and counter alkalosis. 4.2 c.c. of 1/6 molar sodium lactate will raise the carbon dioxide combining power by 1 Meq per litre, and counter acidosis.

(3) DELAYS AND ERRORS IN DIAGNOSIS.—The best preventive against delay and diagnostic errors lies, I believe, in invoking a mental discipline to consider the possible causes and special features of the individual causes of obstruction of the alimentary tract in the newborn and to apply it in the pre-operative and operative phases so as to provide the infant with prompt and efficient management.

(A) INTRINSIC OBSTRUCTIONS

(I) *Atresia or Stenosis*

Generally speaking, atresia will present clinically within the first 24 hours of life, whilst in

stenosis, depending on the degree, symptoms may progress slowly over several weeks. It is as well to remind ourselves that prior to the fifth week of intrauterine life the bowel has a well-defined lumen. Epithelial proliferation then converts this hollow tube into a solid rod. Cellular resorption and recanalisation of the lumen normally occurs by the twelfth week of foetal life, but should recanalisation be incomplete at any site, stenosis ensues; whilst should complete failure of recanalisation occur at this same site, then atresia results.

Two forms of atresia may occur:

- (a) An internal diaphragm within the bowel lumen causes intestinal obstruction.
- (b) The bowel, at the site of atresia, ends as a grossly distended blind sac. The dilated proximal segment may be detached from the distal diminutive segment of bowel or may be connected to it by a fibrous cord.

Atresia usually occurs at points of embryological significance, e.g., at the junction of the upper and middle thirds of the oesophagus; at the mid-duodenum which is the site of junction of fore and mid-guts; that section of the transverse colon which represents the junction of mid and hind-guts or at the site where hind-gut and proctodaeum normally fuse in cases of imperforate anus. At these sites vital vascular anastomoses may fail to become established, and this may occur as an expression of genetic aberration or may represent mechanical varia-

tions between the foetus and its surroundings or it may represent toxic influences such as rubella or vitamin deficiencies in the mother.

Common Sites of Intrinsic Obstruction

(a) *Oesophageal Atresia*.—This most commonly takes the form of a blind proximal pouch and a separate distal segment which has a fistulous connection with the lower trachea. Difficulty in feeding with choking attacks and bouts of cyanosis associated with the production of large quantities of oral mucus and saliva should suggest the diagnosis in the early hours of life. The introduction of an oesophageal catheter will confirm the presence of a block, whilst that of a little lipiodol and radiography will demonstrate the blind proximal pouch ending at the level of the first dorsal interspace. The presence of gas in the stomach associated with oesophageal atresia is indicative of the presence of a tracheo-oesophageal fistula. However, if the abdominal distension is excessive the possibility of a concomitant duodenal or ileal atresia should be considered. Surgical repair should be performed at the earliest possible moment before an aspiration bronchopneumonia vitiates hopes of success. A fourth interspace transpleural thoracotomy on the right side permits ready mobilisation of the distal segment and closure of the fistula. The proximal pouch may then be mobilised and a two layer oesophago-oesophagostomy carried out.

(b) *Congenital Hypertrophic Pyloric Stenosis*.—This disorder, with an incidence of one per 250 live births, is the commonest condition requiring surgical attention in the first weeks of life. Though classically described as presenting during the third week of life, I have seen it at two days of age at the one extreme and at twelve weeks of age at the other. I have seen it, not infrequently, in females, whilst its occurrence in second, third and even fourth-born has been observed. The presence of acholic vomiting, constipation, failure to gain weight and a palpable pyloric tumour is a strong indication for early surgical relief.

(c) *Duodenal Atresia*.—All duodenal obstructions presenting in the early days of life are due to either atresia or stenosis. The extrinsic obstructions due to annular pancreas or anomalous intestinal rotations do not usually present for several weeks or months. Vomiting occurs shortly after feeding, this being a characteristic of all high small intestinal obstructions. The vomitus may or may not contain bile, depending on the location of the obstruction in relation to the sphincter of Oddi. Duodenal atresia is

a rare congenital abnormality, having an incidence of one per 9,000 births. Case reports suggest an even distribution between males and females, but frequent note has been made of its association with mongolism. Though it has been reported in Negroes, I am not aware of its occurrence in African infants.

Clinically upper abdominal distension develops rapidly after the first 24 hours of life, and straight X-ray of the abdomen confirms the distension of stomach and duodenum up to the point of obstruction. If air is seen in the distal

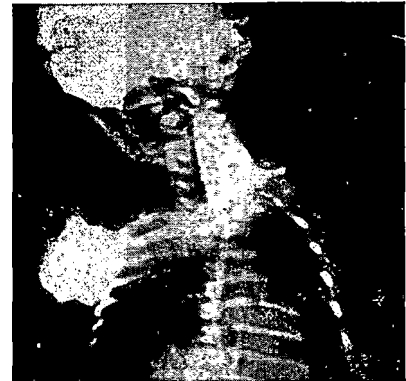

Fig. 1—Oesophageal atresia with proximal blind pouch outlined by radio-opaque fluoroscopy.

bowel, then stenosis is a preferable diagnosis than atresia. The installation of a little oral lipiodol is occasionally helpful in identifying the site of obstruction. Clinical icterus is occasionally present due to incomplete obstruction in the region of the ampulla of Vater. In some 40 per cent. of cases there are associated congenital abnormalities, some incompatible with life, whilst others, e.g., oesophageal atresia, imperforate anus, biliary atresia or congenital heart disease, posing additional problems in management.

Operative relief is necessary at the earliest possible moment, and at laparotomy a decision must be made whether to perform a gastro-jejunostomy, a duodeno-jejunostomy or a duodeno-duodenostomy. There is little doubt that a duodeno-jejunostomy is the procedure of choice, whilst evidence that a gastro-jejunostomy is, from the long-term point of view, undesirable may be inferred from this recent case that I had contact with. At birth, 22 years ago, this man had undergone laparotomy at Great Ormond Street Children's Hospital and a gastro-jejunostomy performed for duodenal atresia.

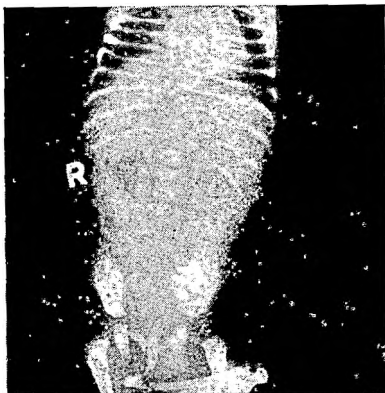


Fig. 2—Straight X-ray of abdomen confirming the presence of congenital hypertrophic pyloric stenosis.

Eighteen years later bouts of vomiting and gastric invalidism led to a laparotomy at Groote Schuur Hospital, Cape Town, and a diaphragmatic duodenal obstruction resected. Subsequent bouts of haematemesis led to a partial gastrectomy a year ago, and at operation the area short-circuited by the original gastro-jejunostomy was found to be a large, dilated, ulcerated, stagnant pouch.

(d) *Enteric Atresia*.—Atresia of the small intestine from the duodeno-jejunal to the ileo-caecal junctions has an incidence of one per 4,000 births. Multiple areas of atresia are not uncommon, hence it is imperative to carry out a thorough operative examination of the whole length of the small intestine before choosing a definitive site for an entero-anastomosis.

Farber's Test.—Normally meconium contains mucus, bile, lanugo hairs and swallowed epithelium squames. In a case of neonatal intestinal obstruction a smear of intestinal meconium should be stained with Sterling's gentian violet for one minute and then decolourised with acid alcohol before putting it under the microscope. If examination fails to disclose stained epithelial cells, then atresia may be presumed.

The presence of vomiting, generalised abdominal distension and paucity of meconium should lead to early diagnosis, and straight X-ray of the abdomen, with the infant in varying positions, will demonstrate distended loops of bowel, whilst the associated presence of pneumoperitoneum will be evidence that intestinal perforation, proximal to the obstruction, has already occurred. The absence of intraperitoneal calcific speckling also serves to aid exclusion of meconium ileus.

At laparotomy the greatest technical difficulty imposed at the anastomosis is that set by the disparity in diameter between the dilated proximal segment and the small calibre lumen of the distal bowel. The latter may be distended with air or saline through a hypodermic syringe and needle, a two-layer anastomosis then being possible either by an end to side or side to side technique, using "oooo" silk for the sero-muscular layer and "oooo" chromic catgut for the mucosa. A small catheter within the opened lumen of the distal segment facilitates the anastomotic manoeuvres.

(e) *Colonic Atresia*.—This is a rare form of intestinal atresia comprising less than 10 per cent. of all intestinal atresias. In reported series 23 per cent. of all cases of colonic atresia had suffered a patch of gangrene or perforation proximal to the obstruction. To date there are only 11 successful cases having been operated on within 72 hours of birth. An immediate colostomy is necessary, and two to three months later intestinal continuity may be established, either by direct anastomosis or by a Miculicz type of exteriorisation procedure.

Thus to generalise in cases of intestinal atresia, the principles of operative therapy are:

- (1) Laparotomy and assessment of the pathology.
- (2) Decompression of the proximal bowel.
- (3) Resection of the atonic dilated proximal bowel.
- (4) Restoration of bowel continuity.

(f) *Imperforate Anus*.—During the first six weeks of foetal life the primitive cloaca drains the intestinal tract and the urogenital sinus. A

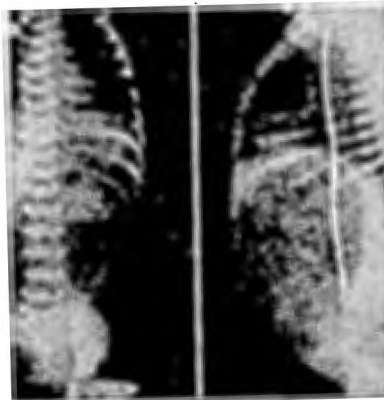

Fig. 3—Duodenal atresia demonstrated by antero-posterior and lateral radiographic views of the infant's abdomen.

urorectal septum then develops longitudinally to separate the ventral bladder and dorsal rectum. Also at this time, in the female, the Mullerian ducts differentiate into uterus and vagina. It is thus simple to envisage how rectovesical and, in the female, recto-vaginal fistulae may complicate maldevelopment in this region. Non-perforation of the anal membrane with failure in downgrowth of the rectal pouch results in an imperforate anus, and in 40 per cent. of these cases there will be associated fistulae to bladder, urethra or perineum in the male and to the vagina in the female.

With an incidence of one per 4,000 live births, anomalies of the anorectal region may present in four ways:

- (1) Anal stenosis. There is normal ano-urinary development except for the presence of narrowing of the anal canal.
- (2) Anorectal atresia. There is a normal anal orifice and a normal rectum to 3-6 cm. above the external sphincter, but at this point there is lack of continuity of the two segments.
- (3) Anal membrane. Here the anal membrane covers the external orifice, having failed to undergo spontaneous perforation.
- (4) Imperforate anus. This is the commonest form of abnormality, the rectum ending as a blind intestinal pouch at a variable distance from the anal dimple. As the external sphincter develops independently of the bowel descent, from local mesodermal elements, it is always normally formed and normally placed.

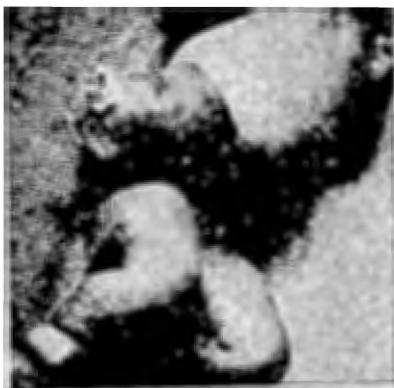

Fig. 4—A six-hour infant with exomphalos, subsequently successfully repaired.

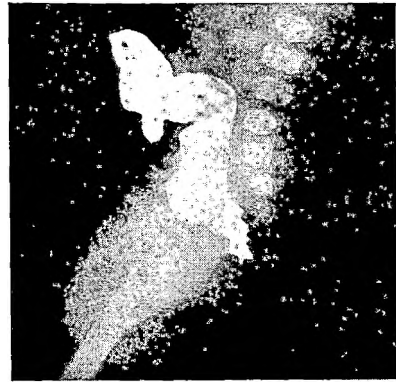


Fig. 5—Barium study of infant with imperforate anus and ectopic perineal fistula.

Diagnosis of imperforate anus and its concomitant abnormalities is readily made by inspection of the perineum, whilst the presence of specks of meconium in the urine attests to the presence of a recto-urinary fistula.

After birth it takes 12 to 24 hours for gas to reach the rectum, and it is then possible to utilise the well-known radiological manoeuvre of Wangenstein and Rice and X-ray the infant in the inverted posture with a radio-opaque coin strapped to the site of the anal plate. The gas contrast will indicate the exact distance between the blind rectal pouch and the anal plate. If this distance does not exceed 2 cm., then it is usually possible to perform a perineal repair without having recourse to a colostomy, any fistulae to adjacent viscera being dealt with through this approach. If the gap is greater than 2 cm. a decision must be made whether to perform a preliminary colostomy or not. I believe that a colostomy is generally unnecessary unless the child is premature or has other congenital abnormalities rating a higher priority. If the infant's condition is good and he weighs over 7 lb., then an immediate abdomino-perineal "pull-through" type of repair is recommended.

(II) *Meconium Ileus*

Meconium ileus presents a picture of acute intestinal obstruction in the newborn. Vomiting is associated with rapidly developing abdominal distension, which may be well marked at birth. Upon palpation of the infant's abdomen, firm to hard abdominal masses may be felt. The obstruction is, of course, due to mechanical blockage of the intestine by dark, viscid, putty-like meconium. This abnormal meconium is the result of pancreatic insufficiency due to

fibrocystic disease of the pancreas. This is only one component of deranged endocrine secretion, which also involves the lung, liver, sweat glands and salivary glands, and has received the generic appellation by Farber of mucoviscidosis. Pulmonary involvement and a tendency to heat prostration from excessive loss of sweat electrolytes are potent causes of death. Meconium ileus accounts for 10 per cent. of the presenting features of this syndrome and a family history of fibrocystic disease of the pancreas or mucoviscidosis is invariably present.

Straight X-ray of the abdomen reveals dilated loops of bowel, and of diagnostic significance in this condition is the variation in the size of the loops as well as the presence of gas bubbles within the meconium masses contained within the dilated bowel. The presence on X-ray of a granular calcium-flecked pattern is evidence of meconium peritonitis.

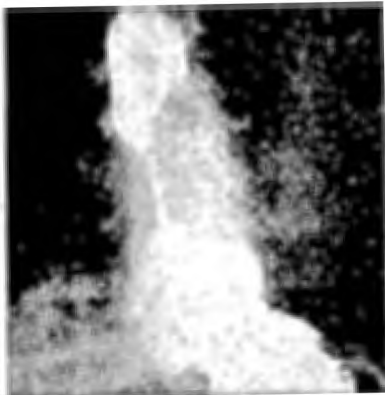

Fig. 6—Barium meal in infant with congenital diaphragmatic hernia with short stenosed oesophagus.

Treatment.—A combination of surgical relief of obstruction, maintenance of nutrition and control of pulmonary infection offers the best chance of success. Mild cases of meconium ileus may on occasion respond to a conservative regime of 3 per cent. hydrogen peroxide enemas, gastric lavage and the feeding of pancreatic enzymes, but usually laparotomy is required. Although the performance of an enterotomy, lavage of meconium with 3 per cent. hydrogen peroxide and instillation of pancreatic enzymes via an enterostomy tube has been recommended, the operation of choice is a Miculicz type resection of the distended meconium-filled ileum and construction of a double-barrelled ileostomy which is brought out through a separate incision. This procedure permits proximal decompression

and distal wash-outs with pancreatic enzymes. Any bowel involved in a concomitant volvulus is also similarly resected. Intestinal continuity may be restored three to four weeks later. Postoperatively a high calorie diet (200 cal./kg.) low in fat and liberal in carbohydrate and protein is administered, whilst administration of antibiotics will serve to control pulmonary infection. A high intake of sodium chloride, especially in hot weather, is necessary, and pancreatic enzymes in the form of Viokase powder, half teaspoonful per meal, may be required.

(III) *Hirschsprung's Disease*

In this disease there is a congenital absence of intramural ganglion cells and a dysplasia of the autonomic nerve bundles in a segment of terminal colon. Lack of co-ordinated peristalsis in this segment leads to obstruction with secondary dilatation of the bowel proximal to this segment. Though over 90 per cent. of cases have symptoms dating from birth, only 20 per cent. of cases present with acute intestinal obstruction in the neonatal period. Differentiation from other forms of obstruction may be difficult, and though megacolon be considered it is dangerous and unwise to carry out a barium enema at this age, as perforation of the distended colon is a real danger. A biopsy of a small piece of rectal mucosa can be readily carried out and will demonstrate the absence of intramural ganglia and the presence of abnormal nerve trunks in Hirschsprung's disease.

Early colostomy should be performed in these cases just proximal to the aganglionic area, and when the infant attains 30 lb. in weight, rectosigmoidectomy with excision of the colostomy and restitution of bowel continuity by the "pull-through" technique may be carried out.

(B) EXTRINSIC OBSTRUCTION

(1) *Annular Pancreas.*—This uncommon condition is due to encirclement of the second part of the duodenum by a napkin-like ring of pancreatic tissue, derived from a persistence of the ventral embryological anlage of the pancreas. It may produce acute or chronic duodenal obstruction and may present in the early weeks of life or any time up to old age. Occasionally icterus due to obstruction of the common bile duct may also be present. Relief is best provided by duodeno-jejunostomy or gastro-enterostomy, for it is unwise to divide the pancreatic ring, not only because of its difficulty, but because of the risk of pancreatitis or pancreatic fistula.

(2) *Malrotation of the Intestine.*—Understanding of the pathology of this group of congenital disorders is based on a thorough comprehension of the normal embryological events occurring during the sixth to twelfth weeks of intra-uterine life.

From the sixth to the tenth weeks of foetal life the alimentary tube grows more rapidly than the coelomic cavity, so that a portion of the mid-gut is accommodated in the umbilical cord as a physiological hernia. Failure in reduction during the tenth to twelfth weeks results in the infant being born with an exomphalos. Normally spontaneous withdrawal of the mid-gut into the enlarged coelomic cavity occurs at about the tenth week of life. The reduction of this duodeno-colic segment of bowel, pivoted on the superior mesenteric artery, is the key to the understanding of this phenomenon. The pre-axial portion comprising the duodenum, jejunum and proximal ileum rotates through 180° in an anti-clockwise direction and is withdrawn behind the artery. The postaxial portion, i.e., terminal ileum, caecum and ascending colon and transverse colon, is withdrawn into the left side of the peritoneal cavity and gradually migrates, in an anti-clockwise fashion, to the right hypochondrium and then descends to its normal situation, where it becomes fixed by peritoneal attachment to the posterior peritoneum.

If the caecum fails to rotate fully, its migration may become arrested and it comes to lie just distal to the stomach, and peritoneal bands from the caecum sweep across to the right flank and obstruct the second part of the duodenum.

If, together with this caecal malrotation, there is also failure in posterior fixation of the small intestinal mesentery, then the scene is set for volvulus neonatorum. Torsion of the intestine about its unfixed mesentery occurs as one or two twists in the clockwise direction. Clinical suspicion of these conditions may be confirmed by barium enema, as it demonstrates the abnormal situation of caecum and colon.

At operation, relief of the volvulus must be followed by relief of the associated duodenal obstruction by division of the caecal band and transferring the caecum well over to the left hypochondrium.

(3) The persistence of mesogastric bands and internal herniae are merely further expressions of peritoneal maldevelopment, whilst volvulus round a persistent vitello-intestinal duct or intussusception usually occurs later than the arbitrary neonatal period.

Incarceration or strangulation of inguinal, femoral or umbilical herniae are unusual in the neonate, but not so uncommon is the occurrence of diaphragmatic hernia. Gastric or colonic obstruction associated with cardio-respiratory distress should suggest the possibility of an incarcerated diaphragmatic hernia and barium study implemented.

In conclusion, may I state that I have sought to tell you nothing that you did not already know, but if this address has brought into sharper focus some details associated with the management of neonatal intestinal obstruction, then my labour to-night shall not have been in vain.



This work is licensed under a
Creative Commons
Attribution – NonCommercial - NoDerivs 3.0 License.

To view a copy of the license please see:
<http://creativecommons.org/licenses/by-nc-nd/3.0/>

This is a download from the BLDS Digital Library on OpenDocs
<http://opendocs.ids.ac.uk/opendocs/>