

The Central African Journal of Medicine



Editor:

MICHAEL GELFAND, C.B.E., M.D., F.R.C.P.

Assistant Editor:

JOSEPH RITCHKEN, M.D.

Volume Eighteen
JANUARY - DECEMBER
1972

Experiences with Lymphangiography in Rhodesia

by

J. A. GORDON, F.R.C.S. (Edin.)

Senior Surgeon

&

R. I. DENT, F.R.C.S.

*Senior Surgical Registrar
Harare Central Hospital*

Lymphangiography has proved to be an extremely useful radiological investigation both experimentally and in current clinical use, and has been so used in many countries for the last 40 years. It has become, however, a routine investigation only during the last 20 years. The procedure was extensively used by Kinmonth at St. Thomas's Hospital and by White at the Westminster Hospital.

The third circulation of the body had been relatively neglected, principally because the vessels are tiny and extremely hard to find, making lymphangiography a tedious procedure. The results, however, are rewarding both to the research worker and to the clinician. The use of various aniline dyes to first outline the vessels made their cannulation possible. Following this, the refinement of poppy seed oils with iodine facilitated the radiographic delineation of lymphatic vessels and nodes. Today such radio opaque dyes as ultra-fluid lipiodol are routinely used.

Lymphangiography has really only been attempted in Rhodesia since 1967, but our experience is rapidly growing. For a great many years improvised types of apparatus were used in an attempt to cannulate the vessels. With the introduction of lymphangiographic sets this is no longer necessary and the use of the proper tools makes lymphangiography an easier, but still time-consuming procedure.

INDICATIONS FOR LYMPHANGIOGRAPHY

(1) *Malignant Disease:*

- (a) Regional lymph node studies have been widely used in the investigation of the spread of such peripheral tumours as malignant melanoma, epitheliomata and leiomyosarcoma.
- (b) The investigation of the lymphomata, particularly the extent of involvement of such clinically inaccessible nodes as those in the retroperitoneal chain.
- (c) In operative surgery, to confirm the complete removal of a chain of lymphatic nodes.

(2) With venography, to investigate the various forms of chronic oedema of the lower limbs.

(3) To assist with the diagnosis of an abdominal mass.

(4) Lymphangiography has also a number of uses in clinical research.

LOCAL EXPERIENCE IN THE USE OF LYMPHANGIOGRAPHY

The greatest use of lymphangiography in our practice has been in the investigation and treatment of malignant melanoma. It has also been used locally to investigate lymphadenopathy associated with carcinoma of the cervix, to stage and assess prognosis and success of therapy in Hodgkin's Disease and other lymphomata, and to delineate the abdominal nodes in seminoma of the testis.

In malignant melanoma, lymphangiography was at first employed to outline the inguinal and iliac lymph nodes in patients with malignant melanoma of the foot. This was carried out to demonstrate whether the inguinal and iliac glands were involved by the tumour, and when the patient was submitted to a block dissection of involved nodes draining the leg, an X-ray film taken before closure of the wound confirmed the completeness of this dissection.

Subsequently this form of lymphangiography has developed to include experimental studies. Five cases of malignant melanoma have so far been treated with an intra-lymphatic injection of vaccinia virus followed by a lymphangiogram through the same needle in an effort to fill metastatic melanotic nodes with virus. The aim is to assess whether the vaccinia virus has the same effect on the nodes as on the dermal metastasis described by research workers in Britain and South Africa (Hunter-Craig 1970 and Hunt 1970).

The technique has similarly been applied in epitheliomata and other malignant tumours of the limbs in which the lymphatic system might be involved by metastasis.

In lymphomata and Hodgkin's Disease, lymphangiography has a definite place in determining the involvement of a chain of nodes. Use has been made of lymphangiography in Hodgkin's Disease where the nodes of the cervical chain have been the presenting feature and the diagnosis confirmed histologically. Before radiotherapy to the neck was instituted a lymphangiogram was done via the lower limb to show the lymphatic chain below the diaphragm, thus aiding the radiotherapist in deciding the type and extent of his treatment.

Lymphangiography was employed in the case of a young male who had his right testicle removed for a seminoma of the testis, to exclude secondary spread as a cause of epigastric pain of which the patient complained. No actual mass of nodes could be felt and, as the testis had been removed, the lymphatic chain along the spermatic vessels had been obliterated. However, a lymphangiogram through a lymphatic on the dorsum of the foot filled the para-aortic chain well above the coeliac axis showing that there was no lymph node involvement of the vessels at the level of the renal artery and vein, and therefore the patient was not subjected to any radiation in the epigastrium.

The most disappointing investigations so far have been in lymph-oedema. This is often a lymph-oedema praecox, but the average patient presents with an enormous limb with very thickened dermis, and the isolation of the lymphatics has proved to be well nigh impossible. A great deal of success has been had with this type of investigation in Uganda and Nigeria, but we cannot claim many successes to date.

Experimentally lymphangiography has been carried out by one of us (J.G.) at the Westminster Hospital in London, on rabbits. Lymphangiography was carried out to delineate the lymphatic channels in the rabbit's leg and then to give intra-lymphatic dosages of V.X.2 tumour to the rabbit and assess the involvement of the rabbit's lymphatic nodes and lungs. Palmer and Cook at Makarere (1962) produced the first film of the lymphaticovenous shunt which partially explains the gross oedema of the legs in patients with Kaposi's sarcoma. At Harare Hospital the major experimental work carried out by ourselves on the direct intra-lymphatic injection of vaccinia virus has already been mentioned.

COMPLICATIONS

To date we have encountered very few complications. In the main these have been slow healing of the wound following lymphangiogram. Complications are said to be pain during the injection, extravasation because of too rapid injection, fever, delayed healing of the wound and local infection, discolouration of the skin, hypersensitivity reaction, tumour spread, pulmonary embolisation (Love and Kim, 1967). It must be admitted that a great deal of patience is required to carry out the procedure, particularly when the operator is not experienced, and secondly that the vessel is liable to rupture with too rapid injection. Perhaps we have not yet done enough lymphangiograms, but we have not come across many com-

plications — local sepsis at the injection site being the most common.

DISCUSSION

Lymphangiography is a clinical tool and is undoubtedly of great value. We would disagree with Love and Kim when they state that it is more useful as a diagnostic tool in lymph-oedema and lymphoma than in metastatic disease. The greatest application at Harare Hospital has so far been in metastatic disease, in its assessment and in ensuring adequate clearance during operation. We would go as far as saying that if any node clearance is to be carried out a preoperative lymphangiogram with an "on-table" X-ray to ensure clearance is mandatory. To date we have not been able to embark on endolymphatic therapy other than in the experimental form with vaccinia virus, but it would appear from the work of Kinmoth and Edwards (1969) that radioactive endolymphatic therapy plays an extremely important part in the treatment of such diseases as malignant melanoma.

A great deal of experience is required in recognising the signs of involvement of a lymph node and it has been our practice to compare lymphangiograms with a known normal lymphangiogram to gain experience. Once the pattern of metastatic disease is recognised small deposits 3-5 mm. in size may be detected, although these deposits are large compared with those found on microscopy. Therefore, having demonstrated a suspicious node on lymphangiography, the surgeon is recommended to clear at least one group of nodes above the level of the involvement.

The use of lymphangiography in delineating and guiding therapy in lymphomata and Hodgkin's Disease appears to be generally accepted a very sound method. Should a patient present with one clinically apparent set of nodes, lymphangiography may be employed to show that nodes elsewhere in the body are not involved, thereby influencing the decision of the radiotherapist or enabling him to plan his therapy more accurately. The same may be said of surgeons, for if an unexpected metastasis may be demonstrated in a clinically inaccessible part of the body this might influence him in his decision to perform radical surgery.

Experimentally, lymphangiography is a powerful tool in the hands of the research worker. The technique as applied to rabbits and other animals enables the research worker to delineate his lymphatic chain and to inject viruses into the lymphatic glands. It also aids in delineating tumours such as Kaposi's sarcoma.

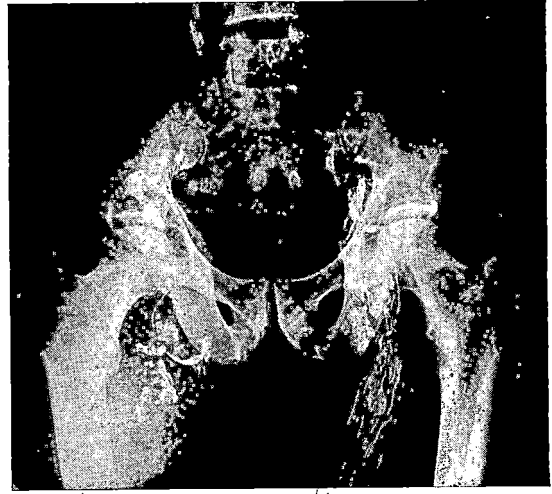


Fig. 1—A male of 45 years with a history of a black lump in his right groin. Three years prior to this he had his right little toe removed for "a black lump". On examination—a very fit male with an inguinal mass the size of a rugby ball. The skin over it was shining and at the apex black pigment was obvious. The right little toe had been amputated but there was a black melanotic recurrence at the site of the amputation. The lymphangiogram shows the gross involvement of inguinal and iliac glands but a relatively normal para-aortic chain. Left side shows a normal lymphatic system.

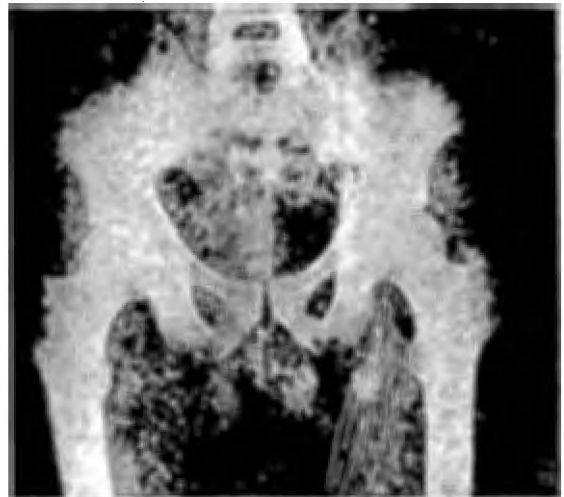

Fig. 2—Lymphangiogram showing enlarged involved inguinal and iliac lymph nodes in a case with malignant melanoma of the left foot.

SUMMARY

Lymphangiography has only recently been employed in Rhodesia but has been found to be of great use in the assessment, the planning of treatment and the assessment of ultimate clearance of lymph nodes in malignant disease. It is also useful in planning radiotherapy. Experimentally it is a very useful tool to research workers particularly in cancer and as a mode of treatment it may offer great hope to patients when various forms of endo-lymphatic therapy have been better investigated and evolved.

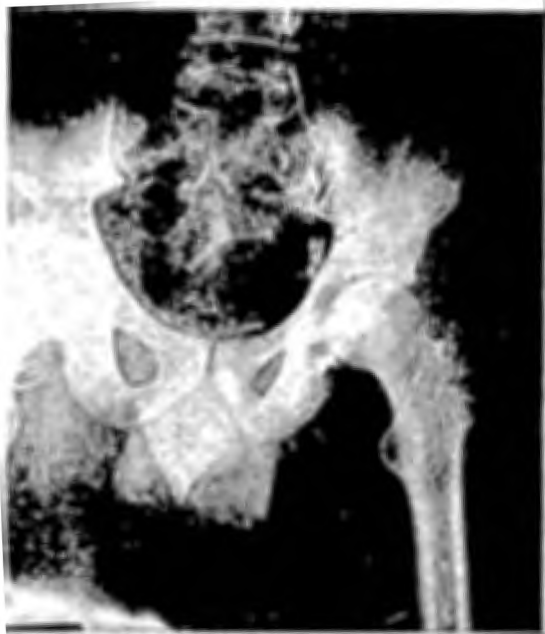

Fig. 3—An on table film of the case in Fig 2 showing incomplete removal of the lymphatic chain necessitating further clearance before completing the operative procedure. Failure to take this film would have resulted in involved nodes being overlooked.

REFERENCES

- HUNTER-CRAIG, I., NEWTON, K. A., WESTBURY, G. & LACEY, B. W. (1970). *Brit. Med. J.*, **2**, 512.
LOVE, L. & KIM SI EON. (1967). *Med. Clin. N. Amer.*, **51**, 227.
PALMER, P. (1962). *Acta. Un. Int. Cancer.*, **18**, 116.

Acknowledgments

To the Secretary for Health for permission to publish this paper. To Mrs. N. Mahomed for typing the paper.



This work is licensed under a
Creative Commons
Attribution – NonCommercial - NoDerivs 3.0 License.

To view a copy of the license please see:
<http://creativecommons.org/licenses/by-nc-nd/3.0/>

This is a download from the BLDS Digital Library on OpenDocs
<http://opendocs.ids.ac.uk/opendocs/>