

World Journal of *Clinical Cases*

World J Clin Cases 2019 November 26; 7(22): 3683-3914



Contents

Semimonthly Volume 7 Number 22 November 26, 2019

REVIEW

- 3683 Colorectal cancer: The epigenetic role of microbiome
Sabit H, Cevik E, Tombuloglu H

ORIGINAL ARTICLE**Case Control Study**

- 3698 Human podocyte injury in the early course of hypertensive renal injury
Sun D, Wang JJ, Wang W, Wang J, Wang LN, Yao L, Sun YH, Li ZL

Retrospective Cohort Study

- 3711 Relationship between acute hypercarbia and hyperkalaemia during surgery
Weinberg L, Russell A, Mackley L, Dunnachie C, Meyerov J, Tan C, Li M, Hu R, Karalapillai D

Retrospective Study

- 3718 Surgical treatment of patients with severe non-flail chest rib fractures
Zhang JP, Sun L, Li WQ, Wang YY, Li XZ, Liu Y

- 3728 Super-selective arterial embolization in the control of acute lower gastrointestinal hemorrhage
Lv LS, Gu JT

- 3734 End-stage liver disease score and future liver remnant volume predict post-hepatectomy liver failure in hepatocellular carcinoma
Kong FH, Miao XY, Zou H, Xiong L, Wen Y, Chen B, Liu X, Zhou JJ

Observational Study

- 3742 Treatment of hemorrhoids: A survey of surgical practice in Australia and New Zealand
Fowler GE, Siddiqui J, Zahid A, Young CJ

- 3751 Relationship between homocysteine level and prognosis of elderly patients with acute ischemic stroke treated by thrombolysis with recombinant tissue plasminogen activator
Li J, Zhou F, Wu FX

CASE REPORT

- 3757 Cystic fibrosis transmembrane conductance regulator functional evaluations in a G542X+/- IVS8Tn:T7/9 patient with acute recurrent pancreatitis
Caldrer S, Bergamini G, Sandri A, Vercellone S, Rodella L, Cerofolini A, Tomba F, Catalano F, Frulloni L, Buffelli M, Tridello G, de Jonge H, Assael BM, Sorio C, Melotti P

- 3765** Ulcerated intussuscepted jejunal lipoma-uncommon cause of obscure gastrointestinal bleeding: A case report
Cuciureanu T, Huiban L, Chiriac S, Singeap AM, Danciu M, Mihai F, Stanciu C, Trifan A, Vlad N
- 3772** Ultrasonographic evaluation of the effect of extracorporeal shock wave therapy on calcific tendinopathy of the rectus femoris tendon: A case report
Lee CH, Oh MK, Yoo JI
- 3778** Contrast-enhanced computed tomography findings of a huge perianal epidermoid cyst: A case report
Sun PM, Yang HM, Zhao Y, Yang JW, Yan HF, Liu JX, Sun HW, Cui Y
- 3784** Iatrogenic crystalline lens injury during intravitreal injection of triamcinolone acetonide: A report of two cases
Su J, Zheng LJ, Liu XQ
- 3792** Sagliker syndrome: A case report of a rare manifestation of uncontrolled secondary hyperparathyroidism in chronic renal failure
Yu Y, Zhu CF, Fu X, Xu H
- 3800** Pre-eclampsia with new-onset systemic lupus erythematosus during pregnancy: A case report
Huang PZ, Du PY, Han C, Xia J, Wang C, Li J, Xue FX
- 3807** Unilateral congenital scrotal agenesis with ipsilateral cryptorchidism: A case report
Fang Y, Lin J, Wang WW, Qiu J, Xie Y, Sang LP, Mo JC, Luo JH, Wei JH
- 3812** Metastatic infection caused by hypervirulent *Klebsiella pneumonia* and co-infection with *Cryptococcus meningitis*: A case report
Shi YF, Wang YK, Wang YH, Liu H, Shi XH, Li XJ, Wu BQ
- 3821** Allergic fungal rhinosinusitis accompanied by allergic bronchopulmonary aspergillosis: A case report and literature review
Cheng KJ, Zhou ML, Liu YC, Zhou SH
- 3832** Invasive aspergillosis presenting as hilar masses with stenosis of bronchus: A case report
Su SS, Zhou Y, Xu HY, Zhou LP, Chen CS, Li YP
- 3838** Retropharyngeal abscess presenting as acute airway obstruction in a 66-year-old woman: A case report
Lin J, Wu XM, Feng JX, Chen MF
- 3844** Thoracoscopic segmentectomy assisted by three-dimensional computed tomography bronchography and angiography for lung cancer in a patient living with situs inversus totalis: A case report
Wu YJ, Bao Y, Wang YL
- 3851** Single-lung transplantation for pulmonary alveolar microlithiasis: A case report
Ren XY, Fang XM, Chen JY, Ding H, Wang Y, Lu Q, Ming JL, Zhou LJ, Chen HW

- 3859** Respiratory failure and macrophage activation syndrome as an onset of systemic lupus erythematosus: A case report
Sun J, Wang JW, Wang R, Zhang H, Sun J
- 3866** Diagnosis of gastric duplication cyst by positron emission tomography/computed tomography: A case report
Hu YB, Gui HW
- 3872** Peritoneal cancer after bilateral mastectomy, hysterectomy, and bilateral salpingo-oophorectomy with a poor prognosis: A case report and review of the literature
Ma YN, Bu HL, Jin CJ, Wang X, Zhang YZ, Zhang H
- 3881** Apatinib for treatment of a pseudomyxoma peritonei patient after surgical treatment and hyperthermic intraperitoneal chemotherapy: A case report
Huang R, Shi XL, Wang YF, Yang F, Wang TT, Peng CX
- 3887** Novel frameshift mutation causes early termination of the thyroxine-binding globulin protein and complete thyroxine-binding globulin deficiency in a Chinese family: A case report
Dang PP, Xiao WW, Shan ZY, Xi Y, Wang RR, Yu XH, Teng WP, Teng XC
- 3895** Diffuse large B-cell lymphoma arising from follicular lymphoma with warthin's tumor of the parotid gland - immunophenotypic and genetic features: A case report
Wang CS, Chu X, Yang D, Ren L, Meng NL, Lv XX, Yun T, Cao YS
- 3904** Exogenous endophthalmitis caused by *Enterococcus casseliflavus*: A case report
Bao QD, Liu TX, Xie M, Tian X

LETTER TO THE EDITOR

- 3912** Microbial transglutaminase should be considered as an environmental inducer of celiac disease
Lerner A, Matthias T

ABOUT COVER

Editorial Board Member of *World Journal of Clinical Cases*, Ridvan Hamid Alimehmeti, MD, PhD, Associate Professor, Lecturer, Surgeon, Department of Neuroscience, University of Medicine, Tirana 1000, Albania

AIMS AND SCOPE

The primary aim of *World Journal of Clinical Cases (WJCC, World J Clin Cases)* is to provide scholars and readers from various fields of clinical medicine with a platform to publish high-quality clinical research articles and communicate their research findings online.

WJCC mainly publishes articles reporting research results and findings obtained in the field of clinical medicine and covering a wide range of topics, including case control studies, retrospective cohort studies, retrospective studies, clinical trials studies, observational studies, prospective studies, randomized controlled trials, randomized clinical trials, systematic reviews, meta-analysis, and case reports.

INDEXING/ABSTRACTING

The *WJCC* is now indexed in PubMed, PubMed Central, Science Citation Index Expanded (also known as SciSearch®), and Journal Citation Reports/Science Edition. The 2019 Edition of Journal Citation Reports cites the 2018 impact factor for *WJCC* as 1.153 (5-year impact factor: N/A), ranking *WJCC* as 99 among 160 journals in Medicine, General and Internal (quartile in category Q3).

RESPONSIBLE EDITORS FOR THIS ISSUE

Responsible Electronic Editor: *Ji-Hong Liu*
 Proofing Production Department Director: *Yun-Xiaojuan Wu*

NAME OF JOURNAL <i>World Journal of Clinical Cases</i>
ISSN ISSN 2307-8960 (online)
LAUNCH DATE April 16, 2013
FREQUENCY Semimonthly
EDITORS-IN-CHIEF Dennis A Bloomfield, Bao-Gan Peng, Sandro Vento
EDITORIAL BOARD MEMBERS https://www.wjnet.com/2307-8960/editorialboard.htm
EDITORIAL OFFICE Jin-Lei Wang, Director
PUBLICATION DATE November 26, 2019

COPYRIGHT © 2019 Baishideng Publishing Group Inc
INSTRUCTIONS TO AUTHORS https://www.wjnet.com/bpg/gerinfo/204
GUIDELINES FOR ETHICS DOCUMENTS https://www.wjnet.com/bpg/GerInfo/287
GUIDELINES FOR NON-NATIVE SPEAKERS OF ENGLISH https://www.wjnet.com/bpg/gerinfo/240
PUBLICATION MISCONDUCT https://www.wjnet.com/bpg/gerinfo/208
ARTICLE PROCESSING CHARGE https://www.wjnet.com/bpg/gerinfo/242
STEPS FOR SUBMITTING MANUSCRIPTS https://www.wjnet.com/bpg/GerInfo/239
ONLINE SUBMISSION https://www.f6publishing.com

Cystic fibrosis transmembrane conductance regulator functional evaluations in a G542X+/- IVS8Tn:T7/9 patient with acute recurrent pancreatitis

Sara Caldrer, Gabriella Bergamini, Angela Sandri, Silvia Vercellone, Luca Rodella, Angelo Cerofolini, Francesco Tomba, Filippo Catalano, Luca Frulloni, Mario Buffelli, Gloria Tridello, Hugo de Jonge, Baroukh Maurice Assael, Claudio Sorio, Paola Melotti

ORCID number: Sara Caldrer (0000-0002-2379-1082); Gabriella Bergamini (0000-0002-3426-9935); Angela Sandri (0000-0002-5107-0960); Silvia Vercellone (0000-0002-5671-733X); Luca Rodella (0000-0002-2355-8272); Angelo Cerofolini (0000-0003-3488-5081); Francesco Tomba (0000-0001-7399-2723); Filippo Catalano (0000-0003-3896-9733); Luca Frulloni (0000-0001-7417-2655); Mario Buffelli (0000-0002-3709-013X); Gloria Tridello (0000-0001-7963-0977); Hugo De Jonge (0000-0001-7596-7433); Baroukh Maurice Assael (0000-0002-2758-7062); Claudio Sorio (0000-0003-2739-4014); Paola Melotti (0000-0002-5276-1595).

Author contributions: Caldrer S, Bergamini G, Sandri A and Vercellone S performed the experiments; Rodella L, Cerofolini A, Tomba F, Catalano F and Frulloni L analyzed the data; Tridello G performed the statistical analysis; de Jonge H supervised the study and acted as consultant for organoids; Assael BM contributed to the design of the work and to the manuscript's drafting, critically discussing the data; Melotti P collected the patient's data and coordinated the study; Caldrer S performed the organoids experiments and drafted the manuscript; Sorio C participated in the data analysis and manuscript preparation; All

Sara Caldrer, Gabriella Bergamini, Angela Sandri, Silvia Vercellone, Claudio Sorio, Department of Medicine, General Pathology Division, Cystic Fibrosis Translational Research Laboratory "D. Lissandrini", University of Verona, Verona 37134, Italy

Gabriella Bergamini, Angela Sandri, Gloria Tridello, Baroukh Maurice Assael, Paola Melotti, Cystic Fibrosis Center, Azienda Ospedaliera Universitaria Integrata Verona, Verona 37126, Italy

Luca Rodella, Angelo Cerofolini, Francesco Tomba, Filippo Catalano, Endoscopic Surgery Unit, Azienda Ospedaliera Universitaria Integrata Verona, Verona 37126, Italy

Luca Frulloni, Department of Medicine, Pancreas Center, University of Verona, Verona 37134, Italy

Mario Buffelli, Department of Neurosciences, Biomedicine and Movement Sciences, Physiology Section University, Verona 37126, Italy

Hugo de Jonge, Gastroenterology and Hepatology, Erasmus University Medical Center, Rotterdam 3015, Netherlands

Corresponding author: Paola Melotti, MD, PhD, Chief Doctor, Medical Director, Cystic Fibrosis Center, Azienda Ospedaliera Universitaria Integrata Verona, Verona 37126, Italy.

paola.melotti@aovr.veneto.it

Telephone: +39-45-8123741

Fax: +39-45-8122042

Abstract

BACKGROUND

Acute recurrent pancreatitis (ARP) is characterized by episodes of acute pancreatitis in an otherwise normal gland. When no cause of ARP is identifiable, the diagnosis of "idiopathic" ARP is given. Mutations in the cystic fibrosis transmembrane conductance regulator (*CFTR*) gene increase the risk of ARP by 3- to 4-times compared to the general population, while cystic fibrosis (CF) patients present with a 40- to 80-times higher risk of developing pancreatitis.

CASE SUMMARY

In non-classical CF or *CFTR*-related disorders, *CFTR* functional tests can help to

the authors approved the manuscript.

Supported by Italian CF Research Foundation with the contributions of Delegazione FFC di Palermo e di Vittoria Ragusa Catania 2, No. FFC grants No. 4/2013; Delegazione FFC di Treviso Montebelluna La Bottega delle Donne, No. 3/2014; Delegazione FFC di Belluno, No. 7/2016; Delegazione FFC di Taranto Massafra, Cosenza sud, della Valpolicella, Guadagnin SRL, No. 6/2018; Delegazione FFC di Tradate Gallarate, No. 13/2018; and CFFT-USA and Lega Italiana Fibrosi Cistica-Associazione Veneta ONLUS.

Informed consent statement:

Consent was obtained from relatives of the patient for publication of this report and any accompanying images. In addition, written informed consent was obtained from the volunteers (used as controls) as approved by the local Ethical Committee of Comitato Etico per la Sperimentazione Clinica delle Province di Verona e Rovigo (Project Nos. 305CESC, 1606, and 06-Clinica delle EVOC).

Conflict-of-interest statement: The authors declare that they have no conflicts of interest.

Data sharing statement: The datasets used and/or analyzed during the current study are available from the Corresponding Author on reasonable request.

CARE Checklist (2016) statement: The authors have read the CARE Checklist (2016), and the manuscript was prepared and revised according to the CARE Checklist (2016).

Open-Access: This article is an open-access article which was selected by an in-house editor and fully peer-reviewed by external reviewers. It is distributed in accordance with the Creative Commons Attribution Non Commercial (CC BY-NC 4.0) license, which permits others to distribute, remix, adapt, build upon this work non-commercially, and license their derivative works on different terms, provided the original work is properly cited and the use is non-commercial. See: <http://creativecommons.org/licenses/by-nc/4.0/>

Manuscript source: Unsolicited manuscript

Received: May 18, 2019

Peer-review started: May 23, 2019

First decision: August 1, 2019

ensure a proper diagnosis. We applied an individualized combination of standardized and new CFTR functional bioassays for a patient referred to the Verona CF Center for evaluation after several episodes of acute pancreatitis. The *CFTR* genotype was G542X+/- with IVS8Tn:T7/9 polymorphism. The sweat (Cl⁻) values were borderline. Intestinal current measurements were performed according to the European Cystic Fibrosis Society Standardized Operating Procedure. Recent nasal surgery for deviated septum did not allow for nasal potential difference measurements. Lung function and sputum cultures were normal; azoospermia was excluded. Pancreas divisum was excluded by imaging but hypoplasia of the left hepatic lobe was detected. Innovative tests applied in this case include sweat rate measurement by image analysis, CFTR function in monocytes evaluated using a membrane potential-sensitive fluorescent probe, and the intestinal organoids forskolin-induced swelling assay.

CONCLUSION

Combination of innovative CFTR functional assays might support a controversial diagnosis when CFTR-related disorders and/or non-classical CF are suspected.

Key words: Recurrent acute pancreatitis; Cystic fibrosis; Cystic fibrosis transmembrane conductance regulator function; Intestinal current; Organoids; Sweat test; Controversial diagnosis; Case report

©The Author(s) 2019. Published by Baishideng Publishing Group Inc. All rights reserved.

Core tip: When the diagnosis of "idiopathic" recurrent acute pancreatitis is given, non-classical cystic fibrosis or disorders related to mutations in the cystic fibrosis transmembrane conductance regulator (*CFTR*) gene are sometimes suspected when the phenotype is consistent with cystic fibrosis. Combination of innovative CFTR functional assays might support a controversial diagnosis, contributing to better definitions of these clinical entities.

Citation: Caldrer S, Bergamini G, Sandri A, Vercellone S, Rodella L, Cerofolini A, Tomba F, Catalano F, Frulloni L, Buffelli M, Tridello G, de Jonge H, Assael BM, Sorio C, Melotti P. Cystic fibrosis transmembrane conductance regulator functional evaluations in a G542X+/- IVS8Tn:T7/9 patient with acute recurrent pancreatitis. *World J Clin Cases* 2019; 7(22): 3757-3764

URL: <https://www.wjgnet.com/2307-8960/full/v7/i22/3757.htm>

DOI: <https://dx.doi.org/10.12998/wjcc.v7.i22.3757>

INTRODUCTION

Cystic fibrosis (CF) is the most common lethal genetic disease in Caucasians, affecting around 1 in 3000 live births. Its underlying etiology is disease-causing genetic mutations occurring on both alleles of the cystic fibrosis transmembrane conductance regulator (*CFTR*) gene^[1]. Within the spectrum of disorders associated with *CFTR* dysfunction is recurrent-acute (ARP) and chronic pancreatitis that can harbor *CFTR* mutations within classic CF or *CFTR*-related pancreatitis^[2].

ARP and chronic pancreatitis due to *CFTR* dysfunction can be indistinguishable from idiopathic (I) ARP in its initial clinical presentation^[3].

The most recent consensus statement from the United States Cystic Fibrosis Foundation^[4] provides for a diagnosis of CF to be made in individuals who present with a characteristic clinical phenotype or a history of CF in a sibling, in the presence of an abnormal sweat chloride value ≥ 60 mmol/L and/or two CF-causing mutations. Identification of *CFTR* mutations on both alleles is not sufficient to establish the diagnosis of CF especially when one or both are not designated disease-causing mutations^[5]. While the management of pancreatitis associated with CF or *CFTR* mutations *per se* is currently not different from that of other forms of pancreatitis, the main concerns in these patients are a progression from pancreatic sufficiency to pancreatic insufficiency and increased risk of developing CF disease and/or disease in other CF-affected organs (e.g., bronchiectasis)^[2,6], as such these patients should be referred to specialized gastroenterologists or centers with expertise in CF for proper

Revised: September 16, 2019**Accepted:** October 15, 2019**Article in press:** October 15, 2019**Published online:** November 26, 2019**P-Reviewer:** Reddy DN**S-Editor:** Wang JL**L-Editor:** A**E-Editor:** Liu JH

management.

A careful evaluation of CFTR function is therefore important for proper management of these patients. Herein, we describe a patient who was evaluated by different assays targeting different tissues/cell types known to express CFTR, some of which are standardized for clinical application, such as the intestinal current measurement (ICM)^[7] and nasal potential difference (NPD) measurement^[8], or are considered as emerging approaches. The latter include the primary forskolin-induced swelling (FIS) assay on intestinal organoids^[9], assessment of CFTR function in leukocytes^[10], as well as the beta-adrenergic/cholinergic imaged sweat test^[11].

CFTR functional assays

Intestinal current measurement: For the case described herein, ion transport was studied by ICM in rectal biopsies according to the ICM European CF Society Standard Operating Procedure. The transepithelial short-circuit current (Isc) across the tissue was registered in recirculating Ussing chambers, as described previously^[7]. Briefly, superficial rectal biopsies were taken by forceps, mounted in Ussing chambers, and incubated with buffer solution at 37 °C. Basal potential difference, Isc, and transepithelial resistance were determined. The Isc, as a direct measure for the net movement of ions across the epithelium, was recorded for 60-75 min after adding amiloride, indomethacin, carbachol, 3-isobutyl-1-methylxanthine (IBMX), and forskolin, 4,4-diisothiocyanostilbene-2,2-disulfonic acid, and histamine to the mucosal and/or serosal side (referred to here as M and S, respectively). Responses to these compounds were detected and analyzed using PowerLab software version 7, and the outcome was calculated using the cumulative Isc response to carbachol, forskolin/IBMX and histamine^[7].

Crypt isolation and organoids culture from human biopsies: Human intestinal biopsies were washed with cold complete chelation solution and incubated with 10 mmol/L EDTA for 30-60 min at 4 °C. Supernatant was harvested and EDTA was washed away. Crypts were isolated by centrifugation and embedded in Matrigel (growth factor reduced, phenol-free; BD Biosciences, Franklin Lakes, NJ, United States) and seeded (50-200 crypts per 50 µL Matrigel per well) in 24-well plates. The Matrigel was polymerized for 10 min at 37 °C and immersed in complete culture medium supplemented with 1% penicillin/streptomycin, 10 mmol/L HEPES, Glutamax, N2, B27 (all from Invitrogen, Carlsbad, CA, United States), 1 µM N-acetylcysteine (Sigma-Aldrich, St Louis, MO, United States) and growth factors of 50 ng/mL mEGF, 50% Wnt3a conditioned medium and 10% Noggin conditioned medium, 20% Rspo1 conditioned medium, 10 µmol/L nicotinamide (Sigma), 10 nmol/L gastrin (Sigma), 500 nmol/L A83-01 (Tocris Bioscience, Bristol, United Kingdom) and 10 µmol/L SB202190 (Sigma). The medium was refreshed every 2-3 d and organoids were passaged at about 1:5 ratio every 7-10 d. For the FIS assay, a standard culture medium was used, composed of Advanced DMEM-F12 (Invitrogen), 1% GlutaMAX-1 (Invitrogen), 1% HEPES (Invitrogen), 1% penicillin/streptomycin (Lonza, Basel, Switzerland) and 1% Primocin (Invitrogen).

Quantification of FIS: The procedure used was adapted slightly from the method described by Dekkers *et al.*^[9]. Human organoids at the second split were seeded on a µ-Slide 8 well chamber (80826; Ibidi, Martinsried, Germany) in 5 µL of 50% Matrigel containing about 20 organoids in 200 µL culture medium. Two days after the seeding, the organoids were incubated for 30 min with 100 µL standard culture medium containing 3 µmol/L Calcein-green (Invitrogen), and stimulated with forskolin (5 µM) for direct analysis by confocal live cell microscopy (TCS-SP5 inverted microscope; Leica, Wetzlar, Germany). For CFTR inhibition, organoids were pre-incubated (60 min) with 50 µmol/L CFTR-inh172 (Sigma). The organoid volume (xyz plane) increase, relative to $t = 0$ of forskolin treatment, was normalized to baseline (= 100%) and quantified using IMMARIS 7.2.1 software (Bitplane, Zurich, Switzerland). Occasionally, cell debris and unviable structures were manually excluded from the imaging analysis by use of defined settings.

Cell membrane depolarization assay: The potential-sensitive probe bis-(1,3-diethylthio)barbituric acid trimethine oxonol (DiSBAC2(3); Life Technologies, Carlsbad, CA, United States) was used to monitor the CFTR-dependent membrane potential (V_m) changes in monocytes as previously described^[10]. The ΔF_t curves, computed as the difference between mean ΔF_t (stimulus) and mean ΔF_t (vehicle) in the last 5 min of recording, was termed "CF index" and was positive in healthy subjects and negative in CF patients, with intermediate values in healthy carriers^[10].

Bubble sweat test (BST) protocol: For the drug delivery and imaging of M- and CFTR-dependent secretion (C)-sweating, injection area on the subject's right forearm

was chosen immediately before the test. An oil reservoir was placed and fixed on the arm, and the circular area (of the reservoir) was marked with three black dots of equal distance along the circumference. The measurement procedure for M- and C-sweat is described in the Supplementary Material.

In the measurement of sweat secretion for both phases, pictures were taken manually using ImageJ software. Starting from the image taken at the end of the M-phase, sweat bubbles were numbered progressively according to the following criteria^[11]: (1) Bubbles must have clear and round outlines; (2) Their volumes must increase during the measurement period; and (3) The location of a C-sweat bubble must correspond to an M-sweat bubble.

Mapped glands were then superimposed on the image obtained at the end of the C-phase. Both images were saved as JPEG format and analyzed by ImageJ software that allows measurement of the diameter of each bubble and automatically calculates the volume. The average sweat rates of M- and C-sweating were finally determined by calculating the sweat volume secreted per unit of time.

CASE PRESENTATION

Chief complaints

A 44-year old male patient heterozygous for the nonsense *CFTR* mutation G542X was referred to our Center for evaluation. Denaturing Gradient Gel Electrophoresis and Reverse Dot Blot (kit INNOLiPA *CFTR* Deletions +6) were performed without detection of any other mutation (detection rate 98%). The status of the other family members was referred “healthy” by the patient except her sister with *CFTR* genotype G542X+/- who had recurrent bronchitis, normal sweat test and NPD, not available for all the tests performed for his brother.

History of present illness

The patient had experienced several episodes of acute pancreatitis since the age of 26 years.

History of past illness

The patient reported having been a smoker for 20 years (15 cigarettes per day), until 2010. During the years of smoking, he had occasional bronchitis (< 1 episode per year), sometimes requiring oral antibiotic treatment. He also declared occasional alcohol intake on the weekends, before 2000 (Table 1). His sister had recurrent bronchitis that disappeared after stopping smoking; she was a carrier of the G542X *CFTR* mutation.

Physical examination

Physical examination revealed positive Ewing’s sign but other examinations produced negative findings, in particular for thoracic auscultation and abdominal palpation. There was no digital clubbing. Lung function was normal.

Laboratory testing

Sweat chloride values, obtained by the Gibson and Cooke method^[12], were 41-45 mEq/L. Sputum cultures were negative for *Haemophilus parainfluenzae*. Congenital bilateral absence of the vas deferens, which is the CF phenotype associated with the mildest impairment of *CFTR* function, was excluded based on absence of azoospermia^[5]. Recent nasal surgery for deviation of the nasal septum and its complications of scars in both nostrils precluded the performance of NPD measurements or of nasal brushing. Occasionally (from 2000 to 2014 once or twice/year, first episode in 2000), high serum levels of amylase and lipase were detected.

Imaging examination

X-ray examination showed modest hypertrophy of the inferior turbinates. Thoracic computed tomography scan showed evidence of colecystectomy and hypoplastic left hepatic lobe.

Genetic examination

Genetic testing for mutations associated with pancreatitis in *SPINK1* and *PRSS1* genes provided negative results. Sequencing of entire coding regions of both genes was performed with diagnostic efficiency about 80%.

Table 1 Medical history of the patient

Year	Clinical condition
1999	Pancreatitis
Before 2000	Heartburn and gastric reflux; occasional alcohol intake on the weekends
1991-2010	Smoker (15 cigarettes per day)
2006	Sinusitis (1 episode)
2007-2014	Bronchitis once a year

FINAL DIAGNOSIS

CFTR-related pancreatitis.

TREATMENT

ICMs were performed on four rectal biopsies, following the European Cystic Fibrosis Society ICM SOP (http://qa.ecfs.eu/ecfs_dnwg), and showed tracings consistent with a non-CF pattern (Figure 1). In this case, the cumulative Isc value of carbachol + forskolin/IBMX + histamine, proposed by Derichs *et al*^[7] as a diagnostic parameter, was 87.4 $\mu\text{A}/\text{cm}^2$, with a cut-off of 34 $\mu\text{A}/\text{cm}^2$ between non-CF and CF with pancreatic sufficiency (*i.e.*, being inconsistent with the diagnosis of CF).

In order to cross-validate alternative assays using alternative primary cell samples, we tested CFTR function in monocytes. The CFTR agonists used in testing were 500 $\mu\text{mol}/\text{L}$ 8-Br-cAMP (B5386; Sigma), 10 $\mu\text{mol}/\text{L}$ forskolin and 100 $\mu\text{mol}/\text{L}$ IBMX (I7018; Sigma), added 5 min after the start of recording. We had previously defined the CF index (CFI) according to the outcome of this assay and showed positive values in non-CF subjects, in contrast to negative values in CF patients^[10]. In that study, CFTR activation was found in the ARP patient, a healthy carrier, and in a non-CF donor but not in the CF patient used as reference. In cases of ARP, the positive CFI (+44) indicates a response to CFTR stimulation within the positive range, as obtained in healthy carriers and non-CF donors (Figure 2A).

We also developed intestinal organoids from the same biopsies utilized for ICM and performed the FIS assay, as described by Dekkers *et al*^[9] (Figure 2B). Organoids obtained from our ARP patient carrying the G542X \pm mutation, a healthy donor, and a CF patient (F508del \pm), were stimulated with 5 μM forskolin and analyzed by confocal live cell microscopy. The organoids' volume (xyz plane) was increased relative to $t = 0$ of forskolin treatment and was normalized to the baseline (= 100%); volume changes were evaluated for 90 min and quantified automatically (by the Bitplane microscopy image analysis software). The normalized volume increase was 117.44 ± 5.7 (mean \pm SE), which is consistent with a non-CF phenotype. Moreover, before stimulation, the ARP organoids showed a spherical appearance similar to non-CF organoids, suggesting the presence of functional CFTR.

We finally tested the patient's CFTR function *in vivo* by measuring individual sweat gland cells through computation of the ratio between CFTR-dependent (C-sweat, evoked by a beta-adrenergic cocktail) and CFTR-independent (M-sweat, stimulated by methacholine) sweat secretion rates from multiple individual sweat glands. We obtained average ratios showing an approximately linear readout of CFTR function, as previously described^[11,13]. The mean ratio was 0.20 in the non-CF samples and 0.10 in the healthy carrier samples but 0.00 in the CF patient, as seen in all the CF patients tested at our Center. These collective results obtained on the same day were consistent with values previously obtained at our site^[13]. For our G542X \pm patient with ARP, the C/M ratio value was 0.10, overlapping our historical results of healthy carriers.

OUTCOME AND FOLLOW-UP

This patient was recommended to attend regularly the follow-up scheduled by the gastroenterologist and once-twice/year the Cystic Fibrosis Center in order to be monitored for possible new clinical signs, in particular those related to CFTR dysfunction.

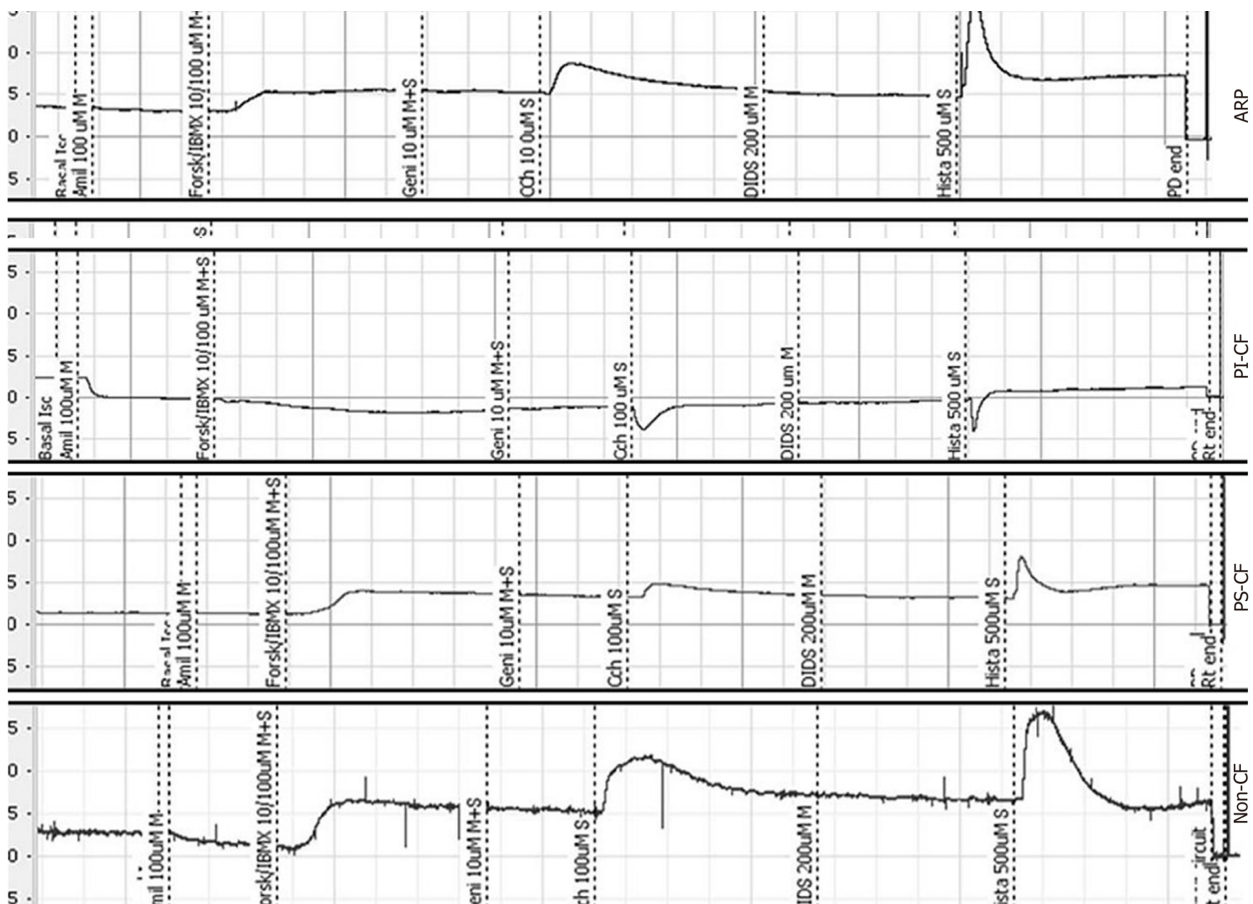


Figure 1 Results of standardized cystic fibrosis transmembrane conductance regulator functional test. Intestinal current measurement tracings from the controversial clinical case (presented herein), cystic fibrosis (CF) patients with pancreatic insufficiency-CF or pancreatic sufficiency-CF and control (non-CF donor). As shown in the top panel, there were positive tissue responses to forsk/IBMX: Forskolin/3-isobutyl-1-methylxanthine, Carbachol and Histamine clearly visible in acute recurrent pancreatitis and not consistent with CF diagnosis. ARP: Acute recurrent pancreatitis; CF: Cystic fibrosis; PI-CF: Pancreatic insufficiency-cystic fibrosis; PS-CF: Pancreatic sufficiency-cystic fibrosis.

DISCUSSION

This case report describes, for the first time, the combination of standardized assays with new, relatively simple and robust CFTR functional assays applied to several tissue types expressing CFTR; the results suggest how the combination of innovative techniques may support diagnosis at an individual level. ICM and/or NPD are suggested according to the algorithm already published^[5]. Therefore a diagnostic algorithm for similar cases, in our opinion, should include ICM and (when possible) generation of intestinal organoids in order to obtain samples for supporting/confirming diagnosis and (possibly) perform therotyping. The importance of testing different tissue types lies on the tissue specificity of exon skipping, furthermore, by testing only airway tissue, we could miss to identify CFTR related pancreatitis caused by CFTR mutations selectively affecting bicarbonate transport^[14]. In fact NPD test is unable to detect such selective bicarbonate impairment while ICM and 2D organoids are methods suitable for testing both anions transport. If standardized CFTR function test are inconclusive or not possible, as NPD and sweat chloride results in this patient, the other functional tests described can be proposed to confirm/exclude CFTR related pancreatitis. Recent data from the literature^[11,13,15] suggest that BST can be more sensitive than sweat chloride measurements for monitoring CFTR improvement during CFTR targeted therapies, making this assay particularly suitable to this aim. Exclusion of CF and CRD is very important when other causes of pancreatitis are suspected (*i.e.*, drug, gallstones, or sphincter of Oddi dysfunction), which may result in therapeutic approaches with limited/no effects (*i.e.*, drug withdrawal, cholecystectomy, or endoscopic sphincterotomy respectively) in patients with recurrent pancreatitis.

For the case presented herein, the results of a number of different tests, standardized as well as experimental, excluded the diagnosis of CF. All the recently developed assays described in this study-involving the intestinal organoids,

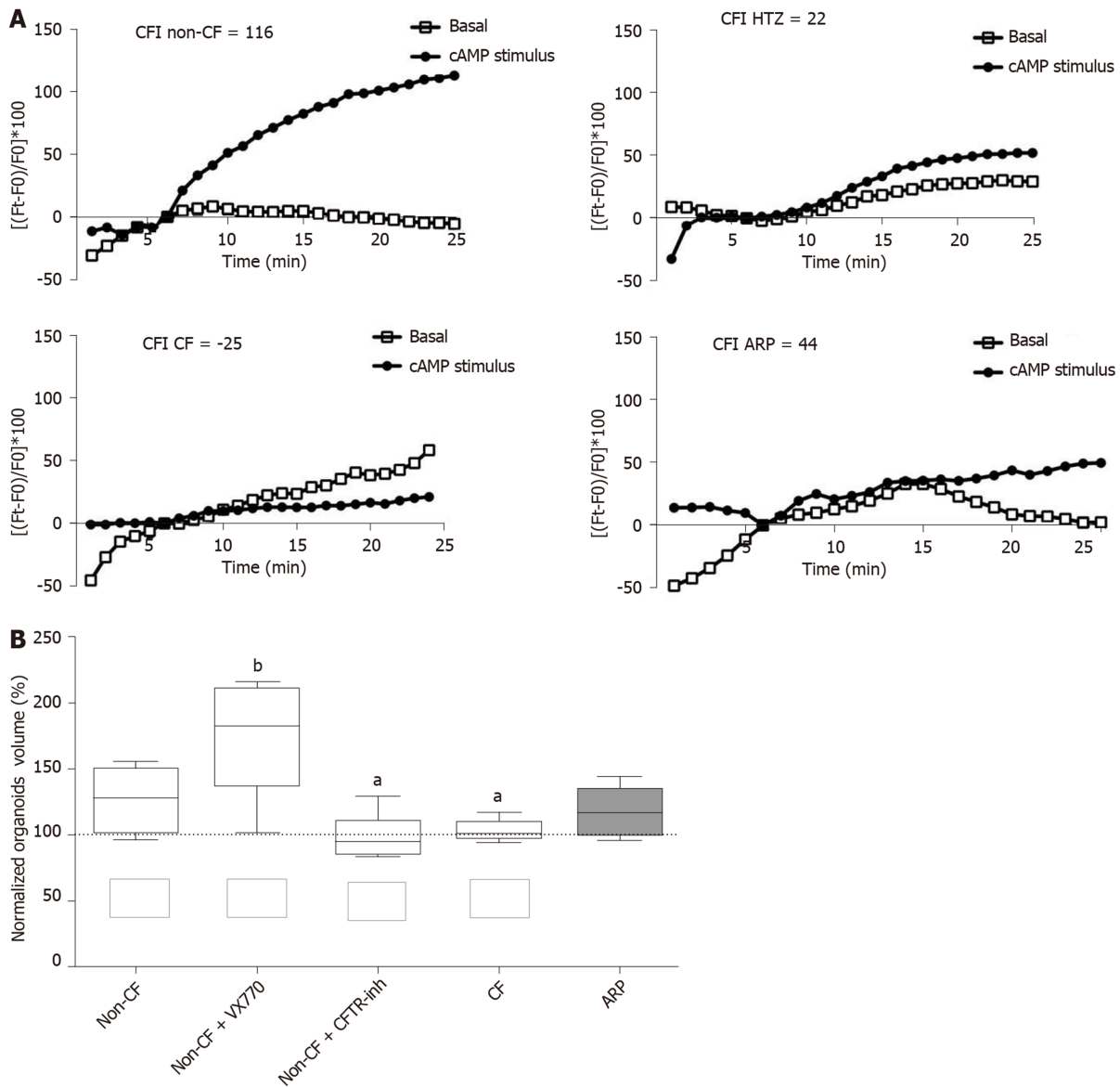


Figure 2 Results of cystic fibrosis transmembrane conductance regulator functional assays. A: Membrane depolarization by single cell fluorescence analysis performed in monocytes with (black trace) and without (white trace) stimulus added at 5 min. The cystic fibrosis (CF) index was calculated as reported^[10]; B: Normalized volume increase of individual organoids obtained during Forskolin-induced swelling assay. Organoids were obtained from the acute recurrent pancreatitis patient carrying the mutation G542+/-, a non-CF subject with or without pre-incubation with cystic fibrosis transmembrane conductance regulator-inh72 and with stimulation with the potentiator VX770, and a CF patient. Box and whisker plots (10th-90th percentiles) correspond to the normalized volume increase with respect to the baseline for each subject; the midline in boxes indicates median. Symbols indicate significant differences (one way-ANOVA; ^a $P < 0.05$; ^b $P < 0.02$) identified by Dunn's method to compare all groups vs the non-CF control. CFTR: Cystic fibrosis transmembrane conductance regulator; CF: Cystic fibrosis; CFI: Cystic fibrosis index; FIS: Forskolin-induced swelling.

leukocytes, and individual sweat glands-provided results consistent with those of ICM which, according to the currently suggested diagnostic algorithm, was considered the only standardized CFTR functional test available for this patient^[5,16]. Contraindications for NPD measurements are not rare when non-classical CF and CRD are suspected^[5,16].

In our opinion, the outcomes of some of these approaches should be further evaluated in a larger number of subjects in order to collect reference values. This might help for an individualized diagnostic approach considering sensibility, specificity, costs, and feasibility. When used alone or in combination, selected on the basis of specialized centres availability and patient's conditions, these tests might be valuable not only for diagnostic applications but also for therotyping approaches^[17,18].

ACKNOWLEDGEMENTS

This case report was presented at the following conferences: 39th ECFS Conference (8-

11 June 2016 in Basel, Switzerland; as “Supporting Diagnosis With a Combination of Standardized And New CFTR Functional Tests”) and at the 13th ECFS Basic Science Conference 2016 (30 March-02 April 2016 in Pisa, Italy; as “Combining Standardized and New CFTR Functional Tests for Improving Diagnosis”).

REFERENCES

- 1 **Maitra A**, Kumar V, Kumar V, Abbas A, Fausto N. Diseases of infancy and childhood. Robbins and cotran pathologic basis of disease. Kumar V, Abbas A, Fausto N. Philadelphia: Elsevier Saunders 2005; 469-508
- 2 **Ooi CY**, Dorfman R, Cipolli M, Gonska T, Castellani C, Keenan K, Freedman SD, Zielenski J, Berthiaume Y, Corey M, Schibli S, Tullis E, Durie PR. Type of CFTR mutation determines risk of pancreatitis in patients with cystic fibrosis. *Gastroenterology* 2011; **140**: 153-161 [PMID: 20923678 DOI: 10.1053/j.gastro.2010.09.046]
- 3 **Testoni PA**. Acute recurrent pancreatitis: Etiopathogenesis, diagnosis and treatment. *World J Gastroenterol* 2014; **20**: 16891-16901 [PMID: 25493002 DOI: 10.3748/wjg.v20.i45.16891]
- 4 **Farrell PM**, White TB, Ren CL, Hempstead SE, Accurso F, Derichs N, Howenstine M, McColley SA, Rock M, Rosenfeld M, Sermet-Gaudelus I, Southern KW, Marshall BC, Sosnay PR. Diagnosis of Cystic Fibrosis: Consensus Guidelines from the Cystic Fibrosis Foundation. *J Pediatr* 2017; **181S**: S4-S15.e1 [PMID: 28129811 DOI: 10.1016/j.jpeds.2016.09.064]
- 5 **Bombieri C**, Claustres M, De Boeck K, Derichs N, Dodge J, Girodon E, Sermet I, Schwarz M, Tzetzis M, Wilschanski M, Bareil C, Bilton D, Castellani C, Cuppens H, Cutting GR, Drevinek P, Farrell P, Elborn JS, Jarvi K, Kerem B, Kerem E, Knowles M, Macek M, Munck A, Radojkovic D, Seia M, Sheppard DN, Southern KW, Stuhmann M, Tullis E, Zielenski J, Pignatti PF, Ferec C. Recommendations for the classification of diseases as CFTR-related disorders. *J Cyst Fibros* 2011; **10** Suppl 2: S86-102 [PMID: 21658649 DOI: 10.1016/S1569-1993(11)60014-3]
- 6 **Gilljam M**, Ellis L, Corey M, Zielenski J, Durie P, Tullis DE. Clinical manifestations of cystic fibrosis among patients with diagnosis in adulthood. *Chest* 2004; **126**: 1215-1224 [PMID: 15486385 DOI: 10.1378/chest.126.4.1215]
- 7 **Derichs N**, Sanz J, Von Kanel T, Stolpe C, Zapf A, Tümmler B, Gallati S, Ballmann M. Intestinal current measurement for diagnostic classification of patients with questionable cystic fibrosis: validation and reference data. *Thorax* 2010; **65**: 594-599 [PMID: 20627915 DOI: 10.1136/thx.2009.125088]
- 8 **Naehrlich L**, Ballmann M, Davies J, Derichs N, Gonska T, Hjelte L, van Konigsbruggen-Rietschel S, Leal T, Melotti P, Middleton P, Tümmler B, Vermeulen F, Wilschanski M; ECFS Diagnostic Network Working Group. Nasal potential difference measurements in diagnosis of cystic fibrosis: an international survey. *J Cyst Fibros* 2014; **13**: 24-28 [PMID: 24022019 DOI: 10.1016/j.jcf.2013.08.006]
- 9 **Dekkers JF**, Wiegerinck CL, de Jonge HR, Bronsveld I, Janssens HM, de Winter-de Groot KM, Brandsma AM, de Jong NW, Bijvelde MJ, Scholte BJ, Nieuwenhuis EE, van den Brink S, Clevers H, van der Ent CK, Middendorp S, Beekman JM. A functional CFTR assay using primary cystic fibrosis intestinal organoids. *Nat Med* 2013; **19**: 939-945 [PMID: 23727931 DOI: 10.1038/nm.3201]
- 10 **Sorio C**, Buffelli M, Angiari C, Ettore M, Johansson J, Vezzalini M, Viviani L, Ricciardi M, Verzè G, Assael BM, Melotti P. Defective CFTR expression and function are detectable in blood monocytes: development of a new blood test for cystic fibrosis. *PLoS One* 2011; **6**: e22212 [PMID: 21811577 DOI: 10.1371/journal.pone.0022212]
- 11 **Wine JJ**, Char JE, Chen J, Cho HJ, Dunn C, Frisbee E, Joo NS, Milla C, Modlin SE, Park IH, Thomas EA, Tran KV, Verma R, Wolfe MH. In vivo readout of CFTR function: ratiometric measurement of CFTR-dependent secretion by individual, identifiable human sweat glands. *PLoS One* 2013; **8**: e77114 [PMID: 24204751 DOI: 10.1371/journal.pone.0077114]
- 12 **GIBSON LE**, COOKE RE. A test for concentration of electrolytes in sweat in cystic fibrosis of the pancreas utilizing pilocarpine by iontophoresis. *Pediatrics* 1959; **23**: 545-549 [PMID: 13633369]
- 13 **Bergamini G**, Tridello G, Calcaterra E, Ceri S, Tagliasacchi M, Bianchi F, Monti F, Masciadri A, Laudanna E, Peserico D, Sorio E, Esposito V, Leal T, Assael BM, Sorio C, Melotti P. Ratiometric sweat secretion optical test in cystic fibrosis, carriers and healthy subjects. *J Cyst Fibros* 2018; **17**: 186-189 [PMID: 29292091 DOI: 10.1016/j.jcf.2017.12.003]
- 14 **LaRusch J**, Jung J, General IJ, Lewis MD, Park HW, Brand RE, Gelrud A, Anderson MA, Banks PA, Conwell D, Lawrence C, Romagnuolo J, Baillie J, Alkaade S, Cote G, Gardner TB, Amann ST, Slivka A, Sandhu B, Aloe A, Kienholz ML, Yadav D, Barmada MM, Bahar I, Lee MG, Whitcomb DC; North American Pancreatitis Study Group. Mechanisms of CFTR functional variants that impair regulated bicarbonate permeation and increase risk for pancreatitis but not for cystic fibrosis. *PLoS Genet* 2014; **10**: e1004376 [PMID: 25033378 DOI: 10.1371/journal.pgen.1004376]
- 15 **Salinas DB**, Peng YH, Horwich B, Wee CP, Frisbee E, Maarek JM. Image-based β -adrenergic sweat rate assay captures minimal cystic fibrosis transmembrane conductance regulator function. *Pediatr Res* 2019 [PMID: 31344706 DOI: 10.1038/s41390-019-0503-8]
- 16 **De Boeck K**, Wilschanski M, Castellani C, Taylor C, Cuppens H, Dodge J, Sinaasappel M; Diagnostic Working Group. Cystic fibrosis: terminology and diagnostic algorithms. *Thorax* 2006; **61**: 627-635 [PMID: 16384879 DOI: 10.1136/thx.2005.043539]
- 17 **Beekman JM**, Sermet-Gaudelus I, de Boeck K, Gonska T, Derichs N, Mall MA, Mehta A, Martin U, Drumm M, Amaral MD. CFTR functional measurements in human models for diagnosis, prognosis and personalized therapy: Report on the pre-conference meeting to the 11th ECFS Basic Science Conference, Malta, 26-29 March 2014. *J Cyst Fibros* 2014; **13**: 363-372 [PMID: 24882694 DOI: 10.1016/j.jcf.2014.05.007]
- 18 **Char JE**, Wolfe MH, Cho HJ, Park IH, Jeong JH, Frisbee E, Dunn C, Davies Z, Milla C, Moss RB, Thomas EA, Wine JJ. A little CFTR goes a long way: CFTR-dependent sweat secretion from G551D and R117H-5T cystic fibrosis subjects taking ivacaftor. *PLoS One* 2014; **9**: e88564 [PMID: 24520399 DOI: 10.1371/journal.pone.0088564]



Published By Baishideng Publishing Group Inc
7041 Koll Center Parkway, Suite 160, Pleasanton, CA 94566, USA
Telephone: +1-925-2238242
E-mail: bpgoffice@wjgnet.com
Help Desk: <https://www.f6publishing.com/helpdesk>
<https://www.wjgnet.com>

