

Images in Infectious Diseases in Obstetrics and Gynecology

Section Editor: David E. Soper, M.D.

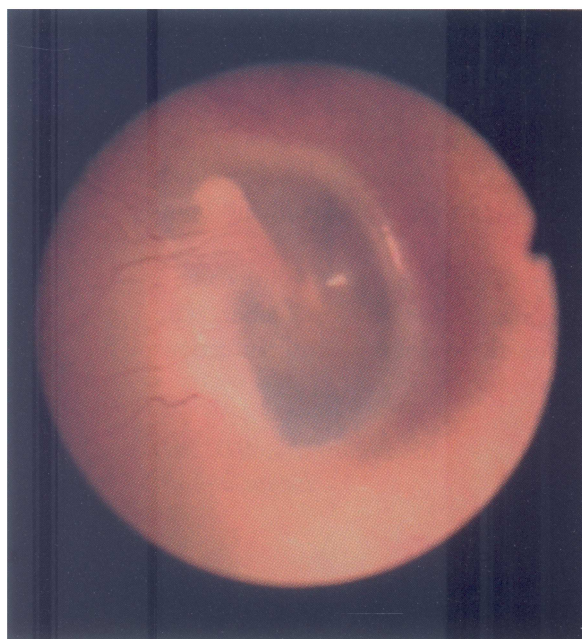
Upper Respiratory Infections—Otitis Media

Thomas B. Warren, Deborah P. Warren, and
David E. Soper

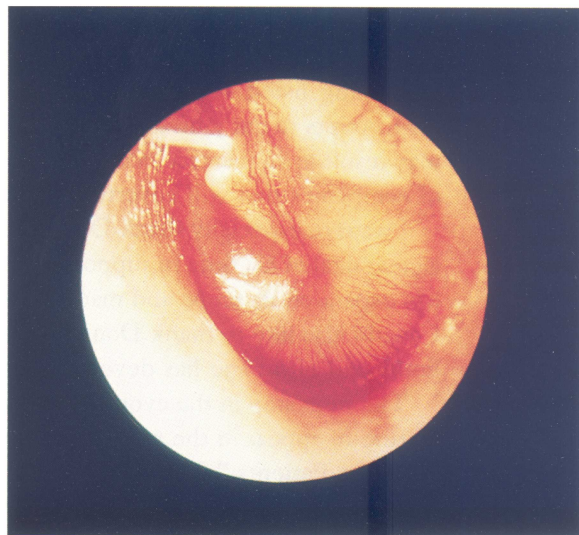
*Departments of Otolaryngology and Obstetrics and
Gynecology, Medical University of South Carolina,
Charleston, SC*

Nose, throat, upper respiratory conditions are leading causes of morbidity in women of all age groups. The normal tympanic membrane (A) is a pale, gray, ovoid semitransparent membrane situated obliquely at the end of the bony external auditory canal. In early otitis media, the membrane is retracted and pink with dilatation of the manubrial and circumferential vessels. Later, as the disease progresses, the membrane bulges, becoming fiery red in color (B) and may eventually perforate. In serous

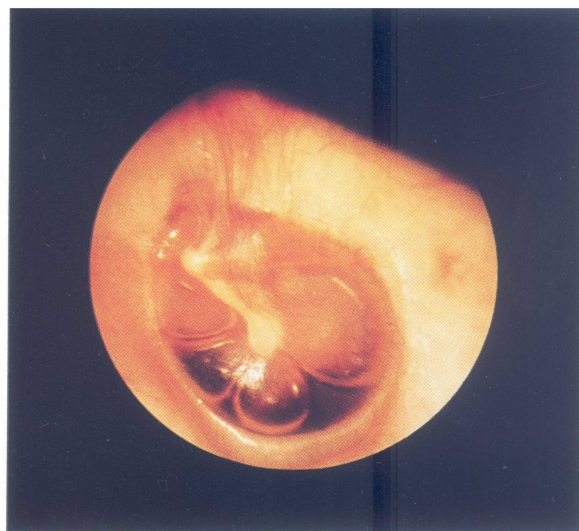
otitis media (C), pneumatic otoscopy reveals that the tympanic membrane is retracted and shows decreased mobility. Bubbles in the effusion occasionally may be seen. © 1998 Wiley-Liss, Inc.



A



B



C

Images in Infectious Diseases in Obstetrics and Gynecology presents clinically important visual images that a practitioner in women's health might encounter. If you have a high-quality color or black-and-white photograph or slide representing such an image that you would like considered for publication, send it with a descriptive legend to David E. Soper, MD, Department of Obstetrics and Gynecology, Rush-Presbyterian-St. Luke's Medical Center, 1653 West Congress Parkway, Chicago, IL 60612-3833.

Images is made possible through an educational grant from 3M Pharmaceuticals.



Hindawi

Submit your manuscripts at
<http://www.hindawi.com>

