

# Anatomy of the Squirrel Wrist: Bones, Ligaments, and Muscles

Richard W. Thorington, Jr.\* and Karolyn Darrow

*Department of Vertebrate Zoology, Smithsonian Institution, Washington, D.C.*

**ABSTRACT** Anatomical differences among squirrels are usually most evident in the comparison of flying squirrels and nongliding squirrels. This is true of wrist anatomy, probably reflecting the specializations of flying squirrels for the extension of the wing tip and control of it during gliding. In the proximal row of carpals of most squirrels, the pisiform articulates only with the triquetrum, but in flying squirrels there is also a prominent articulation between the pisiform and the scapholunate, providing a more stable base for the styloform cartilage, which supports the wing tip. In the proximal wrist joint, between these carpals and the radius and ulna, differences in curvature of articular surfaces and in the location of ligaments also correlate with differences in degree and kind of movement occurring at this joint, principally reflecting the

extreme dorsal flexion and radial deviation of the wrist in flying squirrels when gliding. The distal wrist joint, between the proximal and distal rows of carpals, also shows most variation among flying squirrels, principally in the articulations of the centrale with the other carpal bones, probably causing the distal row of carpal bones to function more like a single unit in some animals. There is little variation in wrist musculature, suggesting only minor evolutionary modification since the tribal radiation of squirrels, probably in the early Oligocene. Variation in the carpal bones, particularly the articulation of the pisiform with the triquetrum and the scapholunate, suggests a different suprageneric grouping of flying squirrels than previously proposed by McKenna (1962) and Mein (1970). *J. Morphol.* 246:85–102, 2000. †Published 2000 Wiley-Liss, Inc.

In this article, we present a study of wrist and hand anatomy, as a continuation of our survey of the forelimb musculature of squirrels (Thorington et al., 1997). Squirrels use their hands in diverse ways as they run, leap, climb, forage, feed, etc. Although all squirrels are extremely versatile, usage differs among them. For example, ground squirrels use their hands extensively in digging (“scratch-digging” in the terminology of Hildebrand, 1985); tree squirrels use them more extensively in climbing (Cartmill, 1974; Thorington and Thorington, 1989); and flying squirrels use them to extend the wing tip while gliding (Thorington et al., 1998). As in our previous studies, we examined the anatomy of the wrists and hands of squirrels to determine if there were differences that correlate with use or phylogeny.

Squirrels, mammals of the order Rodentia, occur indigenously on all continents except Australia and Antarctica. There are approximately 50 genera and 273 species recognized in the family Sciuridae (Hoffmann et al., 1993). We recognize two subfamilies, the Pteromyinae or flying squirrels, and the Sciurinae, including the ground squirrels and tree squirrels placed in seven tribes, as listed with included genera in the Appendix. The tribe Sciurini includes the common tree squirrels of the Americas, Europe, and northern Asia. There are two tribes of ground squirrels. The Marmotini includes chipmunks, marmots, prairie dogs, and the common ground squirrels of North America and Eurasia. The Xerini in-

cludes the African ground squirrels and one species from Southwest Asia. Two other tribes of squirrels are also found in Africa: the Protoxerini, including the African giant squirrels and sun squirrels, and the Funambulini, which includes a variety of tree squirrels, bush squirrels, striped squirrels, and the African pygmy squirrel. This tribe conventionally combines these African squirrels with the Indian striped squirrels, but see Thorington et al. (1997) for a different opinion. In southern Asia, there are two other tribes of squirrels, the Ratufini, including the giant tree squirrels of India and southeast Asia, and the Callosciurini, including all the smaller tree, ground, and pygmy squirrels of southeast Asia. The phylogenetic relationships of the subfamilies and tribes of squirrels are not well understood. Morphology and paleontology have not yet provided unambiguous evidence, probably because the divergence of these groups occurred early in the history of the Sciuridae (Black, 1963).

Thinking that the carpal bones might prove sensitive to differences in function and phylogeny, we focused particular attention on the articulations and ligaments of these bones. Finding major differences among flying squirrels, we examined as many genera of these as possible, while only sampling the

\*Correspondence to: R.W. Thorington, Jr., NHB 390, MRC 108, Smithsonian Institution, Washington D. C. 20560-0108.  
E-mail: Thorington.Richard@NMNH.SI.EDU

genera of other tribes of squirrels. The wrist morphology of flying squirrels has been reported previously (Gupta, 1966; Johnson-Murray, 1977; Thorington, 1984; Thorington et al., 1998) but this broadens the study to 14 of the 15 recognized genera in this subfamily (Hoffmann et al., 1993; Thorington et al., 1996). These genera were divided into five groups on the basis of their dental morphology by McKenna (1962). Mein (1970) recommended a revision of this classification, dividing the flying squirrels into three suprageneric groups, based on other dental characters. Carpal morphology provides a different perspective and an independent evaluation of these two classifications.

Previous studies of squirrel anatomy (Hoffmann and Weyenbergh, 1870; Parsons, 1894; Alezais, 1900; Peterka, 1936; Brizzee, 1941; Bryant, 1945) included data on musculature and osteology of the hands of 11 genera and 23 species, but the detail provided is extremely variable and the ligaments are not described. We report on 62 species belonging to 38 genera.

Description of the hand anatomy of other rodents is similarly sparse and variable (Parsons, 1894, 1896; Howell, 1926; Hill, 1937; Rinker, 1954; Stein, 1986), but provides interesting comparisons with squirrel anatomy.

## MATERIALS AND METHODS

Specimens examined are listed in the Appendix. We studied the skeletal material by carefully separating the individual bones and examining their articular surfaces under light and scanning electron microscopes. Descriptions are based on visual examination, direct comparisons of bones, and visual estimates of angles. We studied articulated wrists using X-rays of museum skins and of fresh and alcohol-preserved cadavers. We dissected the muscles and ligaments of alcohol-preserved specimens. For studying the superficial muscles and cartilage of the palm, we found it useful to cut the skin at the metacarpal-phalangeal joints and peel it back toward the wrist instead of skinning from proximal to distal.

We did not systematically study the innervations of the muscles. They are of little use in establishing muscle homologies in mammalian hands, which are better challenged or affirmed by embryological studies. Most of the intrinsic muscles of the hand are innervated by branches of the ulnar nerve. In squirrels, the median nerve is expected to innervate only the minute abductor pollicis brevis muscle and the radial two lumbricale muscles, and their homologies are not in doubt. Our homology assessments are based on origins, insertions, and topographic considerations, as described.

Several of the carpal bones have more than one name in mammalian anatomy. We provide the following synonyms for the names we use: scapholu-

nate (= scaphoid + lunate, navicular + lunate); triquetrum (= triangular, cuneiform); greater multangular (= trapezium); lesser multangular (= trapezoid); capitate (= magnum); hamate (= unciform); and falciform (= prepollex). The ligaments are named for the connections they make, with the more proximal bone named first. These ligaments may be homologous with ligaments of the same names in other mammals, but there seems to be no way to test such presumed homologies.

## RESULTS

### Bones

The wrist joint is comprised of the distal ends of the radius and ulna, which articulate with three proximal carpal bones, scapholunate, triquetrum, and pisiform, forming the proximal carpal joint. These three carpal bones articulate distally with five other carpals, forming the mid-carpal joint (Fig. 1). The distal row includes the greater multangular, lesser multangular, capitate, and hamate; the centrale lies between the proximal and distal rows. The four distal carpal bones articulate with five metacarpals to form the carpo-metacarpal joints. On the palmar surface, the scapholunate also articulates with the falciform bone.

**Radio-ulnar joint.** The distal ends of the radius and ulna are connected by ligaments and, in some taxa, by a diarthrosis. A small diarthrosis is occasionally present in *Sciurus*. It is larger in the African giant squirrel (*Protoxerus*), the Chinese rock squirrel (*Sciurotamias*), and the Holarctic ground squirrels (*Spermophilus*), formed by a convex articular surface on the ulna and a concave articular surface on the radius. Interosseus ligaments only are found in the Asian giant tree squirrels (*Ratufa*). In flying squirrels, there is a prominent syndesmosis, appearing to allow little or no movement between the two bones.

**Proximal carpal joint.** This joint is formed of the radius articulating with the scapholunate and the ulna articulating with the triquetrum and pisiform. The articular surface of the radius is elliptical in outline and concave in both the vertical (dorso-ventral) and transverse (radio-ulnar) axes. It is least concave in the transverse axis in the African ground squirrels (*Xerus*). The scapholunate articulation with the radius is correspondingly convex in both axes. The most distinctive taxa are the flying squirrels, in which the curvature in the transverse axis is much greater than in other squirrels. Differences in detail exist among the tree squirrels. The outline of the joint is elliptical in *Protoxerus* and *Ratufa*, but the elliptical outline is distinctly notched at the dorso-radial corner of the scapholunate in the Holarctic tree squirrels (*Sciurus* and *Tamiasciurus*) by the attachment of the dorsal ligamentous sheet.

The ulna articulates with a cup or groove formed by the triquetrum dorsally and the pisiform ven-

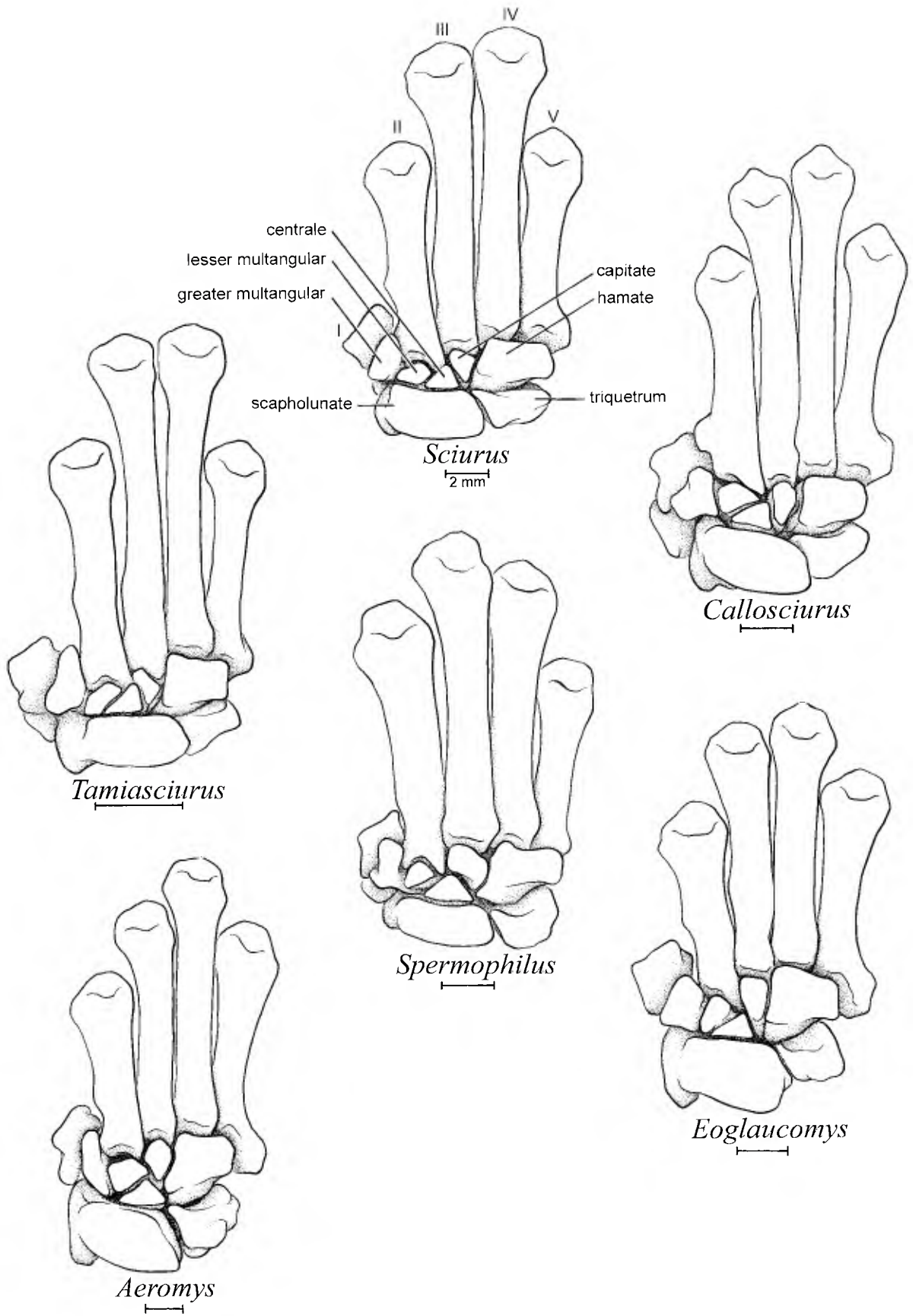


Fig. 1. Dorsal views of carpal and metacarpal bones of three tree squirrels, *Sciurus*, *Tamiasciurus*, and *Callosciurus*, one ground squirrel, *Spermophilus*, and two flying squirrels, *Aeromys* and *Eoglaucomys*. Note the relative lengths of metacarpals III and IV, and of II and V; the presence or absence of a centrale-metacarpal II articulation; and the presence or absence of a capitata-scapulunate articulation.

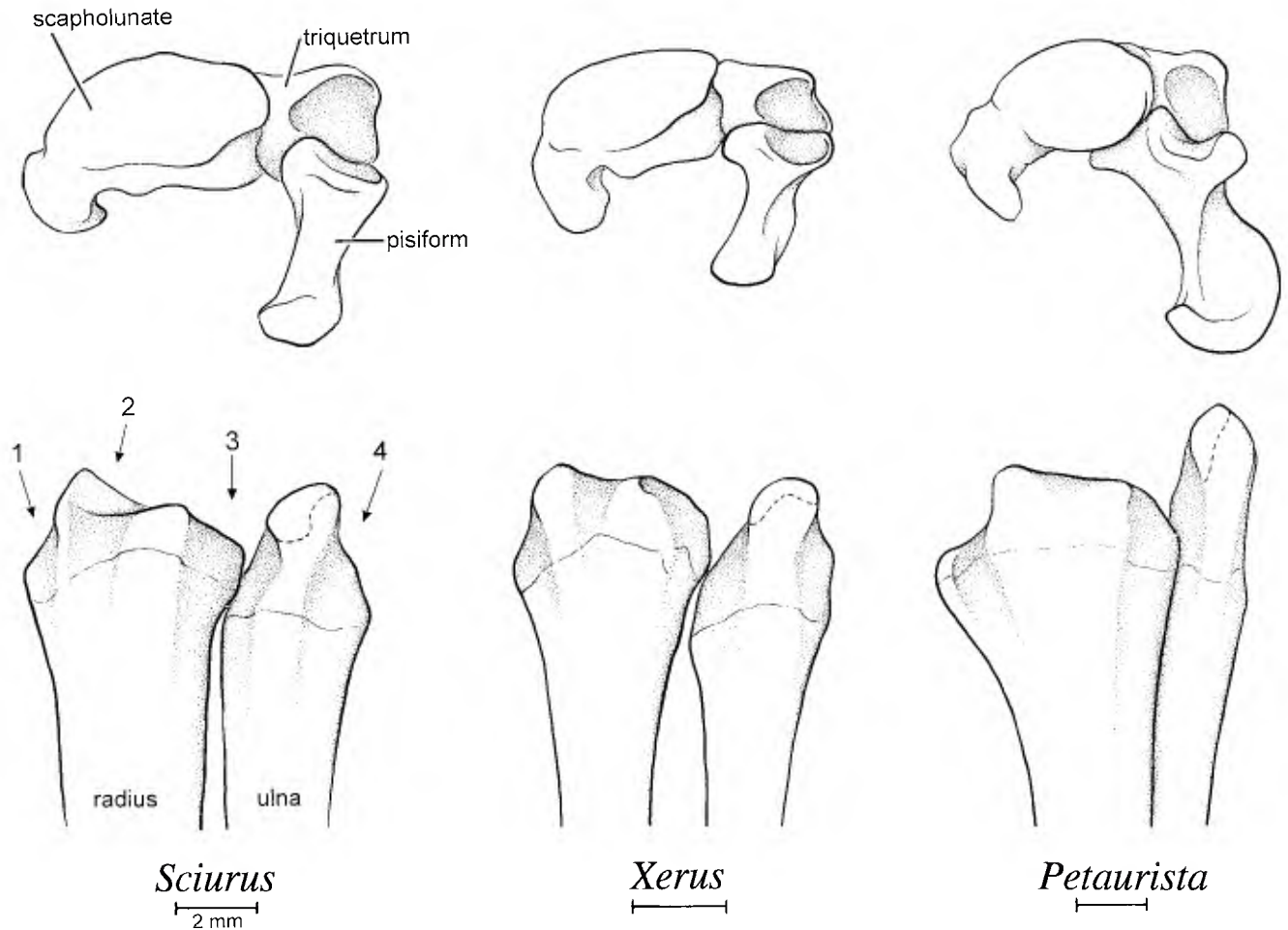


Fig. 2. Comparison of the proximal wrist joints of tree, ground, and flying squirrels. Above: proximal view of scapholunate, pisiform, and triquetrum. Note articulation of pisiform with scapholunate in *Petaurista*, typical of all flying squirrels. The groove on the ventral surface of scapholunate transmits the tendon of *M. flexor carpi radialis*. Below: dorsal views of distal ends of radius and ulna. Numbered arrows point to the dorsal compartments, which transmit tendons of the extensor musculature. Articular surface on tip of ulna indicated by dashed line.

trally. In flying squirrels, the styloid process of the ulna is long relative to the styloid process of the radius, and its articular surface is spherical and is directed radially. In most tree squirrels (*Sciurus*, *Tamiasciurus*, and *Protoxerus*), the convex ulnar articular surface is columnar in shape. In *Ratufa*, it is flatter and more discoid. In the ground squirrels (*Xerus* and *Spermophilus*), the articular surface is spherical. In the tree and ground squirrels this articular surface is directed mostly distally, in contrast with the radial orientation in flying squirrels.

In most squirrels the pisiform articulates only with the triquetrum and ulna. In all flying squirrels, the pisiform also articulates at its proximal end with the scapholunate. There is a radial thumb-like process that articulates with the scapholunate, a middle process that articulates with the triquetrum, and an ulnar process that forms part of the cup for the ulna (Fig. 2). There is a spur on the radial process that fits between the ventral surfaces of the

scapholunate and triquetrum in *Petaurista*, *Aeretes*, *Trogopterus*, *Belomys*, *Pteromyscus*, and a very small spur in *Pteromys*, *Aeromys*, and *Eupetaurus* (Table 1, Fig. 3). In other flying squirrels, *Glaucomys*, *Eoglaucomys*, *Hylopetes*, *Petinomys*, *Iomys*, and *Petaurillus*, this spur is absent. The articulation of the pisiform with the scapholunate is circular in three genera, but the concave articular facet on the scapholunate is more elongate, forming a distinct groove, in others. The body of the pisiform is twisted in most genera of flying squirrels so that the long axis at the palmar end is at 45–90° to the axis of the dorsal end. In four genera of Asian flying squirrels, *Hylopetes*, *Petinomys*, *Petaurillus*, and *Iomys*, the body of the pisiform is not twisted (Fig. 3).

In tree and ground squirrels, the pisiform-triquetrum articulation is a simple rectangular facet, immediately adjacent to the ulnar articulation. In flying squirrels it is a more complex facet, extending ventrally between the palmar process of

TABLE 1. Variations in carpal anatomy of flying squirrels

	Pisiform spur <sup>1</sup>	Pisiform twisted <sup>2</sup>	Pisi. flange for triq. <sup>3</sup>	MCarpII-centrale <sup>4</sup>	Carpal articulations <sup>5</sup>				
					Scaph.-capitate	Cent.-hamate	LessMult-scaph.	Triq. facet on scaph.	Pisi.facet on scaph.
<i>Glaucomys</i>	No	Yes	Absent	Present	Present	Absent	Present	Short	Circular
<i>Eoglaucmys</i>	No	Yes	Absent	Present	Present	Present	Absent	Short	Circular
<i>Hylopetes</i>	No	No	Present	Absent <sup>6</sup>	Absent	Present	Present	Variable	Groove
<i>Petinomys</i>	No	No	Present	Absent <sup>7</sup>	Absent <sup>7</sup>	Present <sup>7</sup>	Absent <sup>7</sup>	Short	Groove
<i>Petaurillus</i>	No	No	Present	Present	Absent	Present	Present	Short	Groove
<i>Iomys</i>	No	No	Present	Present	Absent	Present	Present	Short	Groove
<i>Pteromys</i>	Small	Yes	Absent	Present	Present	Absent	Absent	Short	Circular
<i>Eupetaurus</i>	Small	Yes	Absent	Present	Absent	Present	Present	Long	Circular
<i>Petaurista</i>	Yes	Yes	Absent	Absent	Absent	Present	Absent	Long	Circular
<i>Aeretes</i>	Yes	Yes	Absent	Present	Absent	Present	Absent	Long	Groove
<i>Aeromys</i>	Yes	Yes	Absent	Absent	Absent	Present	Absent	Short	Groove
<i>Trogopterus</i>	Yes	Yes	Absent	Present	Absent	Present	Absent	Long	Groove
<i>Belomys</i>	Yes	Yes	Absent	Present	Absent	Present	Present	Long	Groove
<i>Pteromyscus</i>	Yes	Yes	Absent	Absent	Absent	Present	Present	Long	Groove

<sup>1</sup>Pisiform spur: Presence of a dorsal process that articulates with Triquetrum.

<sup>2</sup>Pisiform twisted: The body of the Pisiform is twisted.

<sup>3</sup>Pisi. flange for triq.: Enlarged surface for Pisiform-Triquetrum articulation.

<sup>4</sup>MCarpII-centrale: Articulation between Metacarpal II and Centrale.

<sup>5</sup>Carpal articulations: Scapholunate-Capitate; Centrale-Hamate; Lesser Multangular-Scapholunate; Triquetrum facet on Scapholunate; Pisiform facet on Scapholunate.

<sup>6</sup>Present in *H. nigripes* and *H. spodiceus*.

<sup>7</sup>Except in *P. hageni*.

the triquetrum and a groove on the distal side of the pisiform bone. We have seen this distinctive process-in-groove articulation only in flying squirrels, not in other sciurids.

The scapholunate-triquetrum articulation is usually a broad elliptical facet, slightly concave on the scapholunate and convex on the triquetrum. The orientation of this articulation differs among squirrels. It is almost perpendicular to the radial-ulnar axis of the scapholunate in some squirrels (e.g., the North American ground squirrel, *Spermophilus lateralis*) and almost parallel to the axis in others (e.g., the Asian tree squirrel, *Callosciurus prevostii*).

**Scapholunate-falciform joint.** Ventral to the proximal row lies an additional element, the falciform bone. The radial end of the falciform articulates with the radio-ventral surface of the scapholunate and forms part of the flexor retinaculum of the wrist in most squirrels. Superficial fibers of the transverse carpal ligament connect it to the palmar end of the pisiform bone and the hypothenar cartilage. In flying squirrels, the falciform is free of the transverse carpal ligament and is connected to the styloform cartilage by a distinct ligament.

**Mid-carpal joint.** The mid-carpal joint usually consists of articulations between the scapholunate and all five more distal carpal bones and between the triquetrum and hamate (Fig. 4). However, articulations between the lesser multangular and scapholunate are absent in approximately half the flying squirrels, and synovial articulations between the capitate and scapholunate are absent in most flying squirrels (Table 1). In these cases, the position of the centrale prevents the contact, by its articulation with the hamate

or with the greater multangular. In the African giant squirrel (*Protoxerus*), the Asian giant tree squirrels (*Ratufa*), and the flying squirrels *Glaucomys*, *Hylopetes*, *Petaurillus*, and *Belomys*, the centrale articulates with the greater multangular without completely occluding the scapholunate-lesser multangular contact. There is a distinct facet for the articulation of the centrale and triquetrum in *Protoxerus* and the Asian long-nosed squirrel (*Rhinosciurus*) not seen in other genera.

The mid-carpal joint is complex. In *Sciurus* and most other tree squirrels, there is a linear array of indistinct facets, triangular to rectangular in shape, on the distal surface of the scapholunate for the articulation of the greater multangular, lesser multangular, centrale, and capitate bones. A ventral convexity on the proximal surface of the centrale fits in a concave pit on the distal surface of the scapholunate. As noted above, in some squirrels enlargement of the centrale reduces the extent of articulation between the scapholunate and the capitate, or between the scapholunate and the lesser multangular. The scapholunate-capitate articulation may be replaced by two articulations in series, scapholunate-centrale, and centrale-capitate. On the ulnar side of the scapholunate, a palmar "hamate process" articulates with the capitate and hamate. Commonly, the distal surface of the triquetrum is convex on the ulnar side and concave on the radial side. The combined scapholunate-triquetrum articulation with the hamate is more spherical in the African giant squirrel (*Protoxerus*) and the Chinese rock squirrel (*Sciurotamias*) than it is in *Sciurus*, *Tamiasciurus*, and others, forming more of a ball-and-socket joint in

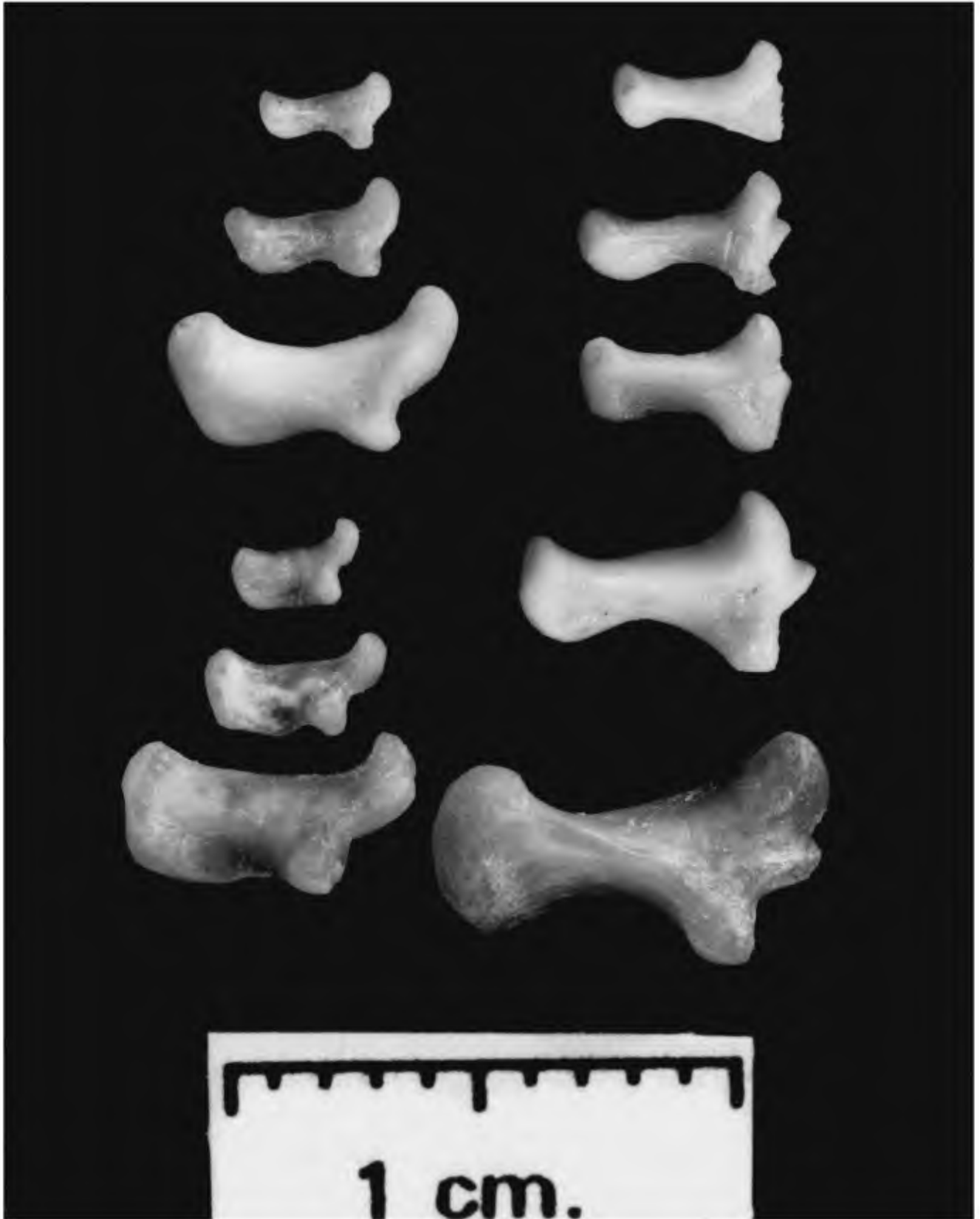


Fig. 3. Proximal views of right pisiform bones of flying squirrels, palmar end left, dorsal end right. Left column, top to bottom: *Glaucomys volans*, *Glaucomys sabrinus*, *Eoglaucomys fimbriatus*, *Hylopetes platyurus*, *H. alboniger*, *H. nigripes*. Right column, top to bottom: *Pteromys volans*, *Belomys pearsoni*, *Pteromyscus pulverulentus*, *Trogopterus xanthipes*, *Petaurista philippensis*. Note the absence of the spur in species in the left column, and the absence of twisting in *Hylopetes*.

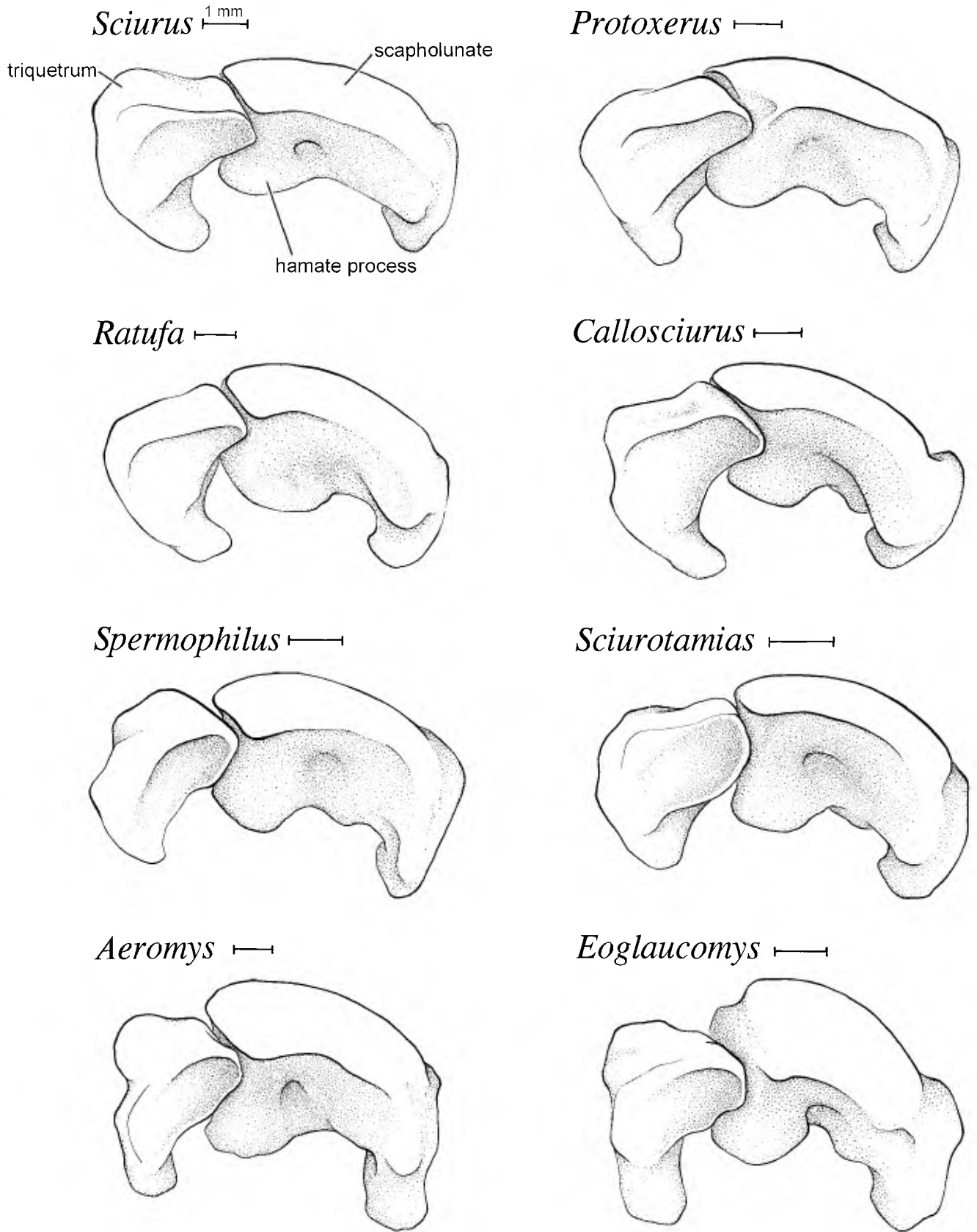


Fig. 4. Distal view of proximal surface of the mid-carpal joint. Hamate articulates with triquetrum and hamate process. Centrale and other distal carpals articulate with scapholunate.

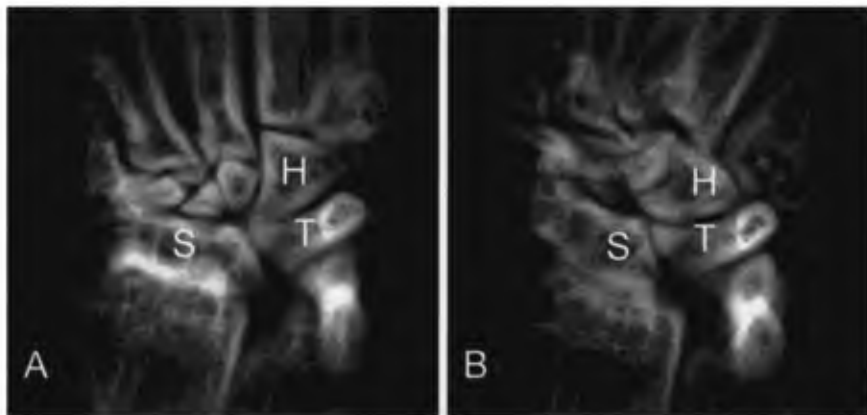


Fig. 5. X-ray images of wrist of *Sciurus carolinensis*, showing extent of radial (A) and ulnar (B) deviation permitted.

these species. In flying squirrels the articular surface of the hamate extends further dorsally than in other squirrels.

The amount of mobility at the mid-carpal joint is difficult to judge from observation of living animals and even from examination of X-rays. In Figure 5, the wrist of *Sciurus* is shown in extreme radial deviation (A) and extreme ulnar deviation (B). It appears that there are equal amounts of movement in the proximal and mid-carpal joints—the scapholunate moves on the radius as much as the hamate moves relative to the triquetrum, and it seems that the hamate and capitate move as a unit relatively independent of the more radial carpal bones. The relative movements of scapholunate and triquetrum can also be seen in the X-rays—in Figure 5A the triquetrum protrudes into the mid-carpal joint. In *Protoxerus* and *Rhinosciurus*, it is probable that the centrale and triquetrum occlude in this position, and that the occurrence of a distinct facet indicates that further radial deviation is prevented by this articulation. Although the centrale and triquetrum appear to make contact in other squirrels, there is not a distinct facet, and radial deviation is probably limited by ligaments.

**Carpo-metacarpal joints.** The distal joints between the carpals and the metacarpals exhibit little variation among squirrels. The greater multangular articulates with metacarpals I and II. The lesser multangular articulates with metacarpal II. The capitate articulates with metacarpals II and III. The hamate articulates radially with the proximal side of metacarpal III, and distally with metacarpals IV and V. In squirrels with very narrow hands, such as the tree squirrels *Sciurus* and *Tamiasciurus*, and the flying squirrels, the disto-radial corner of the hamate is square, and metacarpal III articulates strictly with the radial side of the hamate. In other squirrels with broader hands, particularly ground squirrels, the disto-radial corner of the hamate is truncated by a broader articulation with metacarpal III (which articulates with the truncated surface as well as with the radial side of the bone). Metacarpal II extends proximally between the lesser multangu-

lar and capitate to articulate with the centrale in most squirrels. This articulation with the centrale is absent in some Asian tree squirrels (notably in *Callosciurus*) and some flying squirrels (Table 1). The scapholunate articulates with the first metacarpal only in flying squirrels.

### Ligaments

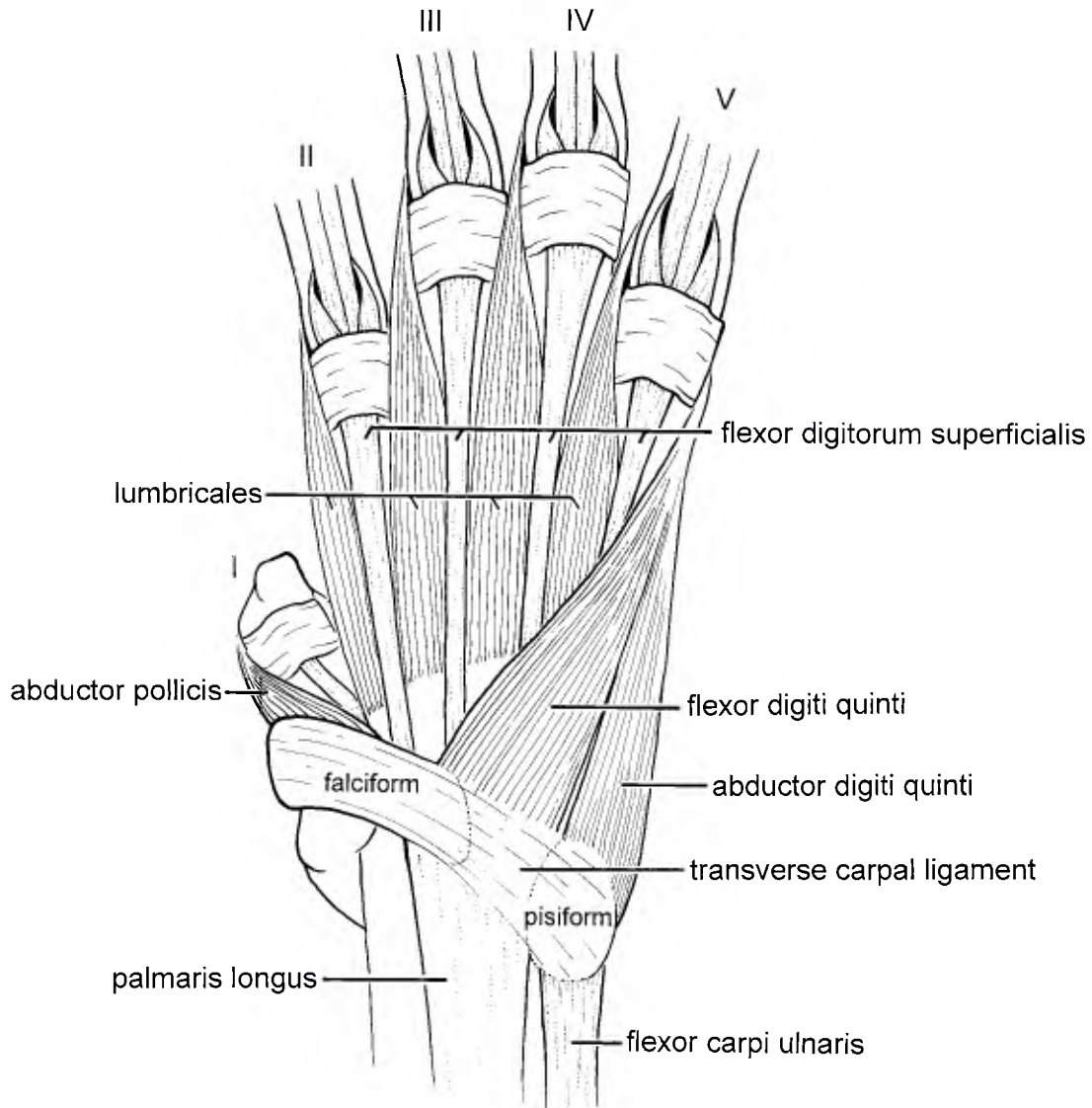
**Carpal tunnel.** The carpal tunnel is encircled by ligaments (Fig. 7). The transverse carpal ligament forms the palmar side of the tunnel (Fig. 6). In most squirrels, it takes origin on the distal end of radius, along the ventro-radial border, on the scapholunate bone along the ulnar side of the falciform articulation, and the most superficial fibers also originate on the ulnar end of the falciform bone. A deeper layer extends across the wrist as the floor of the tunnel. It inserts on the distal end of the ulna, on the radial edge of the epiphysis just proximal to the styloid process, on the radial edge of the pisiform and triquetrum, adjacent to the pisiform-triquetral articulation, and distally on the palmar surface of the hamate. The roof of the tunnel is formed by a sheet of ligaments covering the palmar surfaces of the scapholunate and the adjoining carpal bones.

The carpal tunnel does not incorporate the falciform bone in flying squirrels. The distal end of the tunnel takes origin from the scapholunate. Strong ligamentous fibers connect the ventral surface of the ulna to the pisiform along the ventro-proximal edge of the scapholunate-pisiform articulation. This part of the carpal tunnel could be considered a distinct ventral ulno-pisiform ligament. In other respects, the carpal tunnel is similar to that in other squirrels.

**Styliiform-falciform ligament.** In flying squirrels there is a styliiform-falciform ligament that crosses the palm, connecting the distal end of the base of the styliiform cartilage with the ulnar edge of the falciform bone. This lies superficial to the carpal tunnel and does not serve as a flexor retinaculum.

**Compartments for the extensor muscles.** In most squirrels, the extensor muscles cross the distal





## *Sciurus*

Fig. 6. Superficial dissection of the left palm of *Sciurus* showing flexor and abductor muscles. Roman numerals indicate digits.

ends of the radius and ulna in four compartments, defined by ligaments that hold the tendons close to the bone. The abductor pollicis longus tendon passes through the first compartment, a groove on the dorso-radial surface of the radius. A ligament attaches to the two sides of the groove and forms the roof of the compartment.

The tendons of two muscles, the extensor carpi radialis longus and brevis, pass through the second compartment, which lies immediately ulnar to the first and ulnar to the styloid process, on the dorsal surface of the radius. The ligament that defines this compartment attaches at both ends to the dorsal surface of the radius (Fig. 2) at short ridges that are

sometimes clearly defined on the epiphysis of the bone.

The third compartment transmits the tendons of the digital extensor muscles. The ligament connects small ridges on the epiphyses of the radius and ulna and the compartment consists of grooves in both bones and the space between the bones.

The tendon of the extensor carpi ulnaris passes through the fourth compartment, a groove on the dorso-ulnar surface of the styloid process of the ulna. The ligament attaches to the two small ridges, which define the groove on the epiphysis of the ulna.

In the African tree squirrel, *Protoxerus*, the third compartment is divided by a tendinous partition,

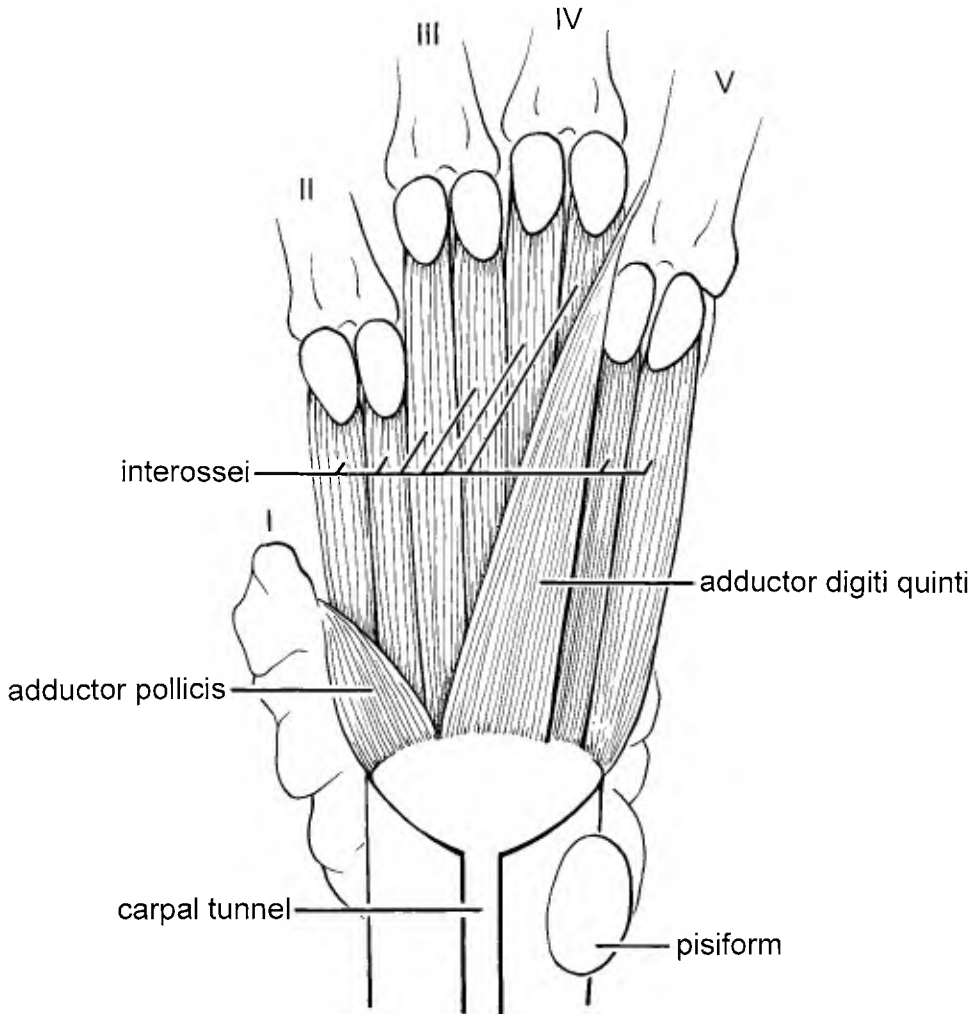


Fig. 7. Deep dissection of the left palm of *Sciurus* showing adductor and interosseous muscles. Roman numerals indicate digits.

with the tendons of the extensor digiti quinti proprius separated on the ulnar side of the compartment from the other tendons.

In the Asian giant tree squirrels, *Ratufa*, and in the ground squirrels, *Marmota*, *Spermophilus*, and *Xerus*, there is a separate compartment for the two tendons of the extensor digiti quinti proprius, between the third and fourth compartments.

**Radial radio-scapholunate ligament.** This ligament originates on the radial side of the styloid process of the radius, passes across the radial side of the joint, and inserts on the ventral side of the scapholunate in a wide variety of squirrels, *Sciurus*, *Ratufa affinis*, *Protoxerus*, *Heliosciurus*, *Callosciurus*, *Paraxerus*, *Funambulus*, *Funisciurus*, *Marmota*, *Spermophilus*, and *Xerus*.

In *Ratufa bicolor* it is a strong ligament originating on the radius, from the radial side of compartment one, and inserting on the proximo-radial edge

of the scapholunate, just proximal to the articular surface of the falciform bone.

In the flying squirrels, *Petaurista*, *Eoglaucmys*, and *Glaucmys*, the floor of the first compartment forms this ligament. It originates on the radial side of the styloid process of the radius, passes across the radial side of the joint, and inserts on the radial or ventral side of the scapholunate. It is a strong, well-defined ligament.

**Ventral radio-scapholunate ligament.** In *Sciurus*, *Ratufa*, *Protoxerus*, *Heliosciurus*, *Callosciurus*, *Funambulus*, *Funisciurus*, and *Eoglaucmys*, this is not a well-defined ligament but instead appears to be part of the roof of the carpal tunnel, extending between the ventral surface of radius and ventro-ulnar edge of scapholunate.

In *Petaurista*, *Glaucmys*, *Paraxerus*, *Marmota*, *Spermophilus*, and *Xerus*, there is a discrete ventral radio-scapholunate ligament that originates on the

ventro-ulnar side of radius and inserts on the ulnar side of the scapholunate and sometimes on the adjacent edge of the triquetrum.

**Dorsal radio-triquetral ligament.** A small dorsal radio-triquetral ligament was found only in *Sciurus carolinensis*. (It was not seen in *Sciurus granatensis*). It connects the ulnar edge of radius with the triquetral bone. It originates immediately ulnar to the dorsal radio-scapholunate ligament and inserts on the dorso-radial corner of the triquetrum.

It was not found in *Ratufa*, *Protoxerus*, *Heliosciurus*, *Callosciurus*, *Paraxerus*, *Funambulus*, *Funisciurus*, *Marmota*, *Spermophilus*, *Xerus*, *Petaurista*, *Eoglaucmys*, or *Glaucmys*. In these genera, the third compartment passes over the scapholunate without ligamentous connection, but it is strongly bound to the dorsal surface of the triquetrum. In *Ratufa affinis* and *Funambulus*, the third compartment continues from the dorsal surfaces of the radius and ulna across the proximal carpal joint to the dorsal surfaces of the triquetrum and the scapholunate, forming a strong ligamentous connection.

**Dorsal ulno-triquetral ligament.** In *Sciurus*, *Ratufa*, *Protoxerus*, *Heliosciurus*, *Callosciurus*, *Paraxerus*, *Funambulus*, *Funisciurus*, *Marmota*, *Spermophilus*, and *Xerus*, the third compartment continues across the proximal carpal joint and the dorsal ulno-triquetral ligament is an extension of the ulnar side of this compartment. It originates on the ulna between the third and fourth compartments and inserts on the triquetrum immediately dorsal to the proximal articular surface, and ulnar to the insertion of the radio-triquetral ligament. This ulno-triquetral ligament is strong and extensive in the flying squirrels, *Petaurista*, *Eoglaucmys*, and *Glaucmys*.

**Collateral ulno-pisiform ligament.** In many tree and ground squirrels, *Sciurus*, *Protoxerus*, *Heliosciurus*, *Paraxerus*, *Funambulus*, *Funisciurus*, *Marmota*, *Spermophilus*, and *Xerus*, the fascia on the ulnar side of the wrist does not form a discrete ligament.

In the Asian tree squirrels *Ratufa* and *Callosciurus* there is a strong collateral ligament originating on the ulnar side at the base of the styloid process of the ulna and inserting at the palmar end of the pisiform and on the fascia superficial to it. The fascia on the ulnar side of the ulno-pisiform joint is also strongly ligamentous.

In the flying squirrels, *Petaurista*, *Eoglaucmys*, and *Glaucmys*, the ulno-pisiform collateral ligament originates on the ulnar side of the styloid process of the ulna and inserts on the pisiform along the ventral edge of the ulno-pisiform articulation. It is a strong, well-defined ligament on adults, but it is not as conspicuous on subadults.

**Ventral and dorsal fascial sheets.** The ligaments that connect the radius and ulna to the proximal row of carpal bones on the ventral surface of the wrist form a continuous sheet that

constitutes the roof of the carpal tunnel. It inserts on the carpals along the ventral edge of the articular surfaces and continues distally to the base of the metacarpals, incorporating the ventral surfaces of the remaining carpal bones. A similar dorsal sheet extends from the dorsal surfaces of the scapholunate and triquetrum, across the mid-carpal joint to the dorsal surfaces of the more distal carpal bones. These two sheets of fascia provide the main ligamentous connections between these carpals. The carpals seem more tightly bound by the ventral sheet, suggesting that there is more mobility at the dorsal end. A number of distinct interosseous ligaments also occur, and are treated separately below.

The dorsal sheet passes distally over the proximal carpal joint and has a limited insertion on the dorso-radial side of the scapholunate and a strong insertion on the dorsal surface of the triquetrum. The third compartment passes over the scapholunate without inserting on it, except in the Asian giant tree squirrel, *Ratufa affinis*, and the Indian striped squirrel, *Funambulus*. In other tree squirrels, *Ratufa*, *Protoxerus*, *Callosciurus*, and *Paraxerus*, a deeper layer, separate from the dorsal sheet of the proximal joint, takes origin from the distal edges of the scapholunate and triquetrum, crosses the mid-carpal joint, and attaches to the dorsal surfaces of all the distal carpal bones, together with the more superficial layer of the dorsal sheet. The dorsal sheet provides the main ligamentous connections between adjoining carpals of the distal row and between these and the metacarpals. Other squirrels exhibit different variations. In *Funisciurus*, the deeper layer consists only of a ligamentous connection between the scapholunate and triquetrum. In *Heliosciurus* and *Xerus*, the dorsal sheet does not attach to the centrale. In *Marmota* there is a distinct ligament from the distal dorso-ulnar edge of the scapholunate to the ulnar corner of the centrale and, in one specimen, to the proximal edge of the capitate. In addition, the dorsal sheet inserts only along the distal edge of the centrale.

Flying squirrels differ only slightly. The dorsal sheet does not insert on the scapholunate. In *Petaurista*, the ventral sheet extends further dorsally as interosseous ligaments between the distal carpal bones, and the dorsal sheet does not insert on the centrale.

**Falciform-scapholunate ligament.** In most squirrels a somewhat variable ligament connects the distal end of the scapholunate with the radial end of the falciform and the base of metacarpal I. In *Ratufa*, the falciform is more extensively connected to the scapholunate by the radial side of the carpal tunnel and by ligamentous tissue connecting the falciform with the ventral surfaces of the scapholunate, greater multangular, and metacarpal I. In flying squirrels there are no distinct lig-

aments connecting the falciform with the scapholunate.

**Scapholunate-triquetral ligament.** In squirrels a variable scapholunate-triquetral ligament connects the two bones. In many genera (*Sciurus*, *Callosciurus notatus*, *Protoxerus*, *Paraxerus*, *Marmota*, *Spermophilus*) it connects only along the adjoining ventral edges of their articulation. In others (*Ratufa*, *Heliosciurus*, *Funambulus*, *Funisciurus*, *Callosciurus prevostii*) the two bones are connected by ligamentous fascia both ventrally and dorsally. In the African ground squirrel, *Xerus*, the two bones are connected by ligamentous fascia ventrally and along their distal articular edges but not along their dorsal or proximal articular edges. The fascia is even more extensive in flying squirrels, connecting the ventral, proximal, and dorsal articular edges in *Eoglaucmys* and *Glaucmys*, and in *Petaurista* the distal edge as well.

**Scapholunate-hamate ligament.** The roof of the carpal tunnel connects the hamate process of the scapholunate with the hamate bone in most squirrels. In one specimen of *Petaurista*, there was a small, distinct ligament between the disto-radial edge of the hamate process of the scapholunate and the ventral edge of the hamate bone at its proximo-radial corner.

**Ventral scapholunate-centrale ligament.** In most squirrels the ventral surfaces of the scapholunate and centrale are embedded in the connective tissue that forms the roof of the carpal tunnel. This gives the appearance of a ligament connecting the two bones ventrally, but it is not readily separated from the rest of the roof of the carpal tunnel. Occasionally in large squirrels (one *Marmota* and one *Petaurista* specimen) the ligament appears more distinct and is separable from the roof of the carpal tunnel.

**Triquetral-pisiform ligament.** The triquetral-pisiform ligament connects these two bones along the distal edge of their articulation in diverse tree squirrels, *Sciurus*, *Ratufa*, *Protoxerus*, *Heliosciurus*, *Callosciurus*, and *Paraxerus*. The ligament connects the two bones along the distal and ulnar edges of their articulation in other diverse squirrels: the flying squirrels, *Petaurista*, *Eoglaucmys*, and *Glaucmys*; the Indian and African striped squirrels, *Funambulus* and *Funisciurus*; and the ground squirrels, *Marmota*, *Spermophilus*, and *Xerus*.

**Pisiform-metacarpal V ligament.** In all squirrels except the flying squirrels, the pisiform-metacarpal V ligament originates near the tip of the pisiform, dorsal (deep) to the origin of the abductor of the fifth digit; it inserts on the ventral surface of the proximal end of metacarpal V. In flying squirrels there is no pisiform-metacarpal V ligament. Instead, the base of the styloform cartilage (which is found only in flying squirrels) is bound by ligaments prox-

imally to the pisiform and distally to the proximal end of the fifth metacarpal.

**Greater multangular-metacarpal II ligament.** The greater multangular-metacarpal II ligament originates on the dorso-distal tip of the greater multangular and inserts on the radial side of the second metacarpal, proximal to the insertion of the extensor carpi radialis longus. In *Sciurus*, *Ratufa*, *Protoxerus*, *Paraxerus*, and *Xerus*, the ligament is distinct. In other genera it is not as discrete a ligament, but more like a thickened portion of the dorsal sheet.

**Lesser multangular-metacarpal II ligament.** In the giant tree squirrels, *Ratufa*, particularly *R. bicolor*, this ligament originates on the ventro-distal tip of the lesser multangular and inserts on metacarpal II at the ventro-radial edge of the carpal joint. This ligament is not distinct from the ventral sheet in other genera.

**Hamate-metacarpal III ligament** In both African and Holarctic ground squirrels, *Xerus*, *Spermophilus*, and *Marmota*, a distinct ligament takes origin from the radial surface of the hamate, near its distal edge, and inserts on the ulnar side of metacarpal III. In *Spermophilus*, and in one *Marmota* specimen, the ligament originates from both the hamate and the adjoining surface of capitate.

**Hamate-capitate ligament.** In *Xerus* and in one specimen of *Marmota*, there is a distinct ligament connecting the radial side of the hamate with the ulnar side of capitate. In the *Marmota* specimen the ligament is continuous with the hamate-metacarpal III ligament.

**Ligaments of the hypothenar and styloform cartilages.** In most squirrels, including *Sciurus*, *Protoxerus*, *Heliosciurus*, *Paraxerus*, *Funambulus*, *Funisciurus*, *Marmota*, *Spermophilus*, and *Xerus*, there is a large hypothenar cartilage that is incorporated into the superficial fascia of the hand and the tendon of the palmaris longus muscle. It is attached to the pisiform and the falciform by fascia. In *Callosciurus* there is a similar, but small, hypothenar cartilage.

In the Asian giant tree squirrels, *Ratufa*, the hypothenar cartilage is anchored by a ligament extending from the distal end of the ulna to the proximal end of the cartilage. There is an additional cartilage in the thenar pad, attached to the distal edge of the falciform bone.

In the flying squirrels, the hypothenar pad is supported by the base of the styloform cartilage rather than by the hypothenar cartilage. The styloform cartilage is tightly bound to the ulnar surface of the palmar end of pisiform. The distal end of the base of the styloform cartilage has a strong ligament attaching it to the proximal end of metacarpal V. There is also a styloform-falciform ligament that connects the two across the palm.

## Muscles

The muscles of the hand can be grouped into the most superficial palmaris brevis, the superficial muscles of the fifth digit, the superficial muscles of the pollex, the contrahentes layer, which usually consists of two adductor muscles, and finally the deepest layer, the interosseus muscles. Human-like opponens muscles, inserting along the metacarpals of the first and fifth digits and serving to rotate these bones, do not occur in squirrels, but the homologs of the human opponens muscles are considered to be present. Interosseus muscles to the first digit are absent. Grossly, it appears that there are eight interosseous muscles, but the most ulnar of these is thought to be derived from a different muscle layer and probably should not be considered an interosseous muscle. The descriptions of these muscles have been reasonably consistent among authors but the names applied to them have not been, based on different interpretations of their homologies.

**M. palmaris brevis.** The palmaris brevis has a variable origin from the superficial fibers of the transverse carpal ligament and the falciform bone (*Sciurus*, *Funambulus*, *Funisciurus*, *Marmota*, *Xerus*), and from connective tissue in the midline of the hand (*Ratufa*, *Protoxerus*, *Heliosciurus*, *Spermophilus*). It inserts on the deep side of the hypothenar cartilage in most squirrels and variably on the skin of the thenar and hypothenar regions. In flying squirrels, the origin is similar, from the falciform-styliform ligament, and it inserts on the skin of the hypothenar pad and sometimes on the styliform cartilage.

**M. abductor digiti quinti (Fig. 6).** The abductor digiti quinti muscle originates from the palmar end of the pisiform bone and inserts on the ulnar surface of the proximal end of the first phalanx of the fifth digit. The origin is commonly restricted to the pisiform bone in *Sciurus*, *Protoxerus*, *Heliosciurus*, *Funambulus*, *Xerus*, and the flying squirrels. Fibers originate also from the deep surface of the hypothenar cartilage in *Callosciurus*, *Ratufa*, *Paraxerus*, *Funisciurus*, *Marmota*, and *Spermophilus*. The tendinous insertion is independent of the insertion of the flexor digiti quinti muscle in *Paraxerus*, *Funisciurus*, *Funambulus*, *Marmota*, *Spermophilus*, and the flying squirrels. In *Protoxerus* and *Heliosciurus* the two muscles insert side by side by a broad continuous tendon, and in *Sciurus*, *Ratufa*, and *Callosciurus*, the muscles join to insert by a common tendon.

**M. flexor digiti quinti (Fig. 6).** The flexor digiti quinti muscle originates from the distal edge of the transverse carpal ligament, palmar to the carpal tunnel. Fibers may originate also from the falciform itself or the hypothenar cartilage. It inserts tendinously on the ulnar surface of the proximal end of the first phalanx of the fifth digit. It inserts in common with, or independent of, the abductor digiti

quinti, as listed above. In individual specimens it can be ambiguous whether fibers originating from the hypothenar cartilage and inserting with the abductor should be considered as part of the flexor or as part of the abductor.

**M. abductor pollicis brevis (Fig. 6).** The abductor pollicis brevis muscle is a small bundle of fibers originating on the disto-radial edge of falciform and inserting on the radial side of the proximal phalanx of the thumb.

**M. adductor digiti quinti (Fig. 7).** The adductor digiti quinti muscle originates from the distal edge of the dorsal surface of the carpal tunnel, at the base of metacarpals III and IV. It inserts on the radial side of the proximal end of the first phalanx of the fifth digit. In the flying squirrels, the origin of this muscle is narrower, restricted to the base of metacarpal IV.

**M. adductor pollicis (Fig. 7).** The adductor pollicis muscle takes origin from fascia on the palmar surface of the greater multangular bone. It inserts on the ulnar side of the proximal phalanx of the thumb. It is more robust in the Asian giant tree squirrels, *Ratufa*, than in other squirrels.

**M. lumbricales.** There are normally four lumbricale muscles. Each takes origin from a tendon of the deep flexor of digits II–V and inserts with the extensor tendons on the dorsal surface of the same digit at the distal interphalangeal joint. In *Ratufa bicolor* we found two additional lumbricales, one each to the ulnar side of the first phalanx of digits III and IV. In *R. affinis* we found one additional lumbricale inserting on the ulnar side of digit IV.

**M. interossei (Fig. 7).** Eight interosseus muscles appear to be present. They originate on the volar surface of the base of metacarpals II–V, not on the shafts of these bones. They insert on the sesamoid bones at the proximal ends of digits II–V.

## DISCUSSION

### Form and Function

Wrist function and use cannot be determined from an anatomical study alone, but morphology does provide clues, particularly in the shape of the articular surfaces and the position and strength of ligaments. We present our interpretations of these clues below, in the hope that they will elicit further study.

Hand musculature varies little among squirrels and thus provides little evidence of differences in function and use. The prominence of the hypothenar cartilage and of the palmaris brevis muscle in all tree and ground squirrels suggests that these structures are used extensively in grasping with the hands. Exactly how they are used remains undocumented. The absence of a differentiated flexor pollicis brevis muscle is consistent with the small size of the thumb and the relatively little use made of it in most squirrels. Only the giant tree squirrels, *Ratufa*, of Southern Asia, have a more developed thenar

region and a thenar cartilage, suggesting that they make more use of their thumbs.

In contrast to the musculature, there is much variation in the bones and ligaments among these taxa. The distal ends of radius and ulna are connected by a movable joint—either a diarthrosis or ligamentous connection—in tree and ground squirrels, but not in flying squirrels. All squirrels pronate and supinate their hands, especially in the manipulation of food. In tree squirrels and ground squirrels, the radio-ulnar joint permits movement of the two bones relative to one another, thus allowing pronation and supination at the wrist, as in most mammals. The scapholunate and triquetrum must also move relative to one another during pronation and supination in order to compensate for the relative movements of the distal ends of the radius and ulna, so the diarthrosis between scapholunate and triquetrum is a slightly movable joint, and the interosseous ligaments connect only the ventral edges of these bones or their ventral and dorsal edges.

In contrast to the tree and ground squirrels, flying squirrels have an immovable joint between the distal ends of the radius and ulna—either a syndesmosis or a tight ligamentous connection. Accordingly, movement is greatly restricted and pronation and supination occur by rotation of the forearm at the elbow joint (Thorington, 1984; Thorington et al., 1998), resulting from the ulna rocking on the distal end of the humerus with compensatory rotation of the radius. Because the distal ends of the radius and ulna do not move relative to one another, no relative movements of the scapholunate and triquetrum are required during pronation and supination. The articulation of the pisiform with both the triquetrum and scapholunate and the presence of interosseous ligaments on three sides of the scapholunate-triquetrum articulation suggest that little movement occurs at this joint. In flying squirrels, the articulation between the pisiform and triquetrum is also more elongate than in other squirrels, probably increasing the stability of the joint. These features should cause the proximal row of carpal bones to function as a single unit, probably providing a more stable base for the styliiform cartilage and the wing tip during gliding.

At the proximal wrist joint, between the radius and ulna proximally, and the first row of carpal bones distally, the permitted movements are dorsal and ventral flexion, radial and ulnar deviation, and circumduction. The amount of angular movement at this joint is determined by the curvature of the articular surfaces. By eye, it appears that the ground squirrels, *Xerus* and *Spermophilus*, exhibit the least curvature. There is more curvature in the tree squirrels, *Sciurus* and *Callosciurus*, and the most curvature, particularly radio-ulnar curvature, in the flying squirrels, *Petaurista* and *Glaucomys*. In flying squirrels, the whole dorsal surface of the scapholunate is articular, and the dorsal ligamentous sheet

does not insert on it. This permits extensive dorsiflexion between the scapholunate and radius. The greater radio-ulnar curvature appears to permit more extreme radial deviation at the same joint.

The distal wrist joint, lying between the proximal carpal bones and the distal row of carpal bones, is variable and complex. The hamate, centrale, and greater multangular always articulate with the triquetrum and scapholunate; the capitate, lesser multangular, and metacarpal I are variable. The articulation of metacarpal I with the scapholunate (only in flying squirrels) probably causes the abductor pollicis longus muscle to effect the radial deviation of the whole wrist through its insertion on metacarpal I, instead of just moving the thumb. Articulations of the centrale with the greater multangular and with the hamate may serve to reduce the independent movement of the individual carpals of the distal row. In flying squirrels these articulations are associated with more extensive inter-osseous ligaments between the distal carpal bones, than in other squirrels.

These differences between flying squirrels and tree squirrels in their carpal bones and connecting ligaments correlate with functional differences and usage. When gliding, flying squirrels position their hands in extreme dorsiflexion and radial deviation (Thorington et al., 1998). The great curvature of the proximal surface of the scapholunate, the extensive dorsal articular surface on this bone, and also the elongation of the styloid process of the ulna are all morphological manifestations of this movement. The abductor pollicis longus muscle serves to extend the wing tip. It inserts on the falciform bone and the first metacarpal, at the radial side of the wrist, but the force of contraction is transmitted across to the ulnar side of the wrist by the falciform-styliiform ligament, to the distal surface of the styliiform process, and causes wing tip extension (Thorington et al., 1998). The derived morphology of the mid-carpal joint in many flying squirrels, in which the centrale articulates with both the hamate and the greater multangular, may also have an important function during gliding. The distal end of the base of the styliiform cartilage is attached to the proximal end of metacarpal V. If the distal carpal row moves as a single unit because of these articulations of the centrale, then the radial deviation and dorsiflexion of the wrist may move the proximal end of the fifth metacarpal in a radial direction, relative to the pisiform, assisting in extending the styliiform cartilage and the wing tip.

A variable feature of the carpal-metacarpal articulations is the articulation between metacarpal II and centrale, which is normally pronounced in dorsiflexion and appears to prevent hyperextension. The absence of this articulation in some flying squirrels may permit greater dorsiflexion of the hand when the animals are gliding. It is also absent in the Asian tree squirrel, *Callosciurus*, for unknown reasons.

## Carpal Homologies

In most Recent rodents, a single carpal bone, the scapholunate, articulates with the radius. In only two families, the Bathyergidae and the Ctenodactylidae, there are rodents with separate scaphoid and lunate bones (specifically in the genera *Bathyergus* and *Ctenodactylus*). In the other families the single bone is called the "scapholunate" under the presumption that it is the fused scaphoid and lunate bones, although the evidence for this is weak. In primitive squirrels it is probable that there were separate scaphoid and lunate bones, as reported by Emry and Thorington (1982) for the Eocene fossil squirrel *Dougllassia jeffersoni* (formerly *Protosciurus* c.f. *jeffersoni*). In contrast, all Recent squirrels have only a single "scapholunate" bone. The only developmental evidence bearing on the origin of this "scapholunate" has been presented by Holmgren (1952) for prenatal *Funambulus*, the Indian striped squirrel, in which he found separate precartilaginous anlagen for both the lunate and the scaphoid cartilages. It is not known if these two elements fuse or if one of them is lost, nor at which stage this occurs, precartilaginous or cartilaginous. Stafford and Thorington (1998) found a single "scapholunate" cartilage in young postnatal *Sciurus*, suggesting that the determining stage is prenatal. In other families of rodents, the origin of the "scapholunate" is also uncertain, and it is unknown how many times and by what developmental processes the single "scapholunate" has evolved among rodents. We must suspect that it has been lost or fused independently in many different lineages.

## Comparative Myology and Muscle Homologies

**M. palmaris brevis.** Descriptions of the palmaris brevis muscle in squirrels differ. Parson's (1894) description appears to be relevant to other rodents, but not to Sciurids. Bryant's (1945) description does not vary greatly from ours, except for the absence of reference to the hypothenar cartilage and the claim that the muscle is absent in *Sciurus* (and in *Tamiasciurus* and *Neotamias*). In cricetine rodents, the palmaris brevis is similar to that of sciurids (Rinker, 1954). In other small rodents it has been difficult to study (Stein, 1986).

**M. abductor digiti quinti.** Hoffmann and Weyenbergh (1870) and Parsons (1894) considered the abductor digiti quinti to have two heads, treating what we call the flexor digiti quinti as a second head of the abductor. This terminology resulted from the ambiguous use of the name "flexor brevis minimi digiti" for the most ulnar interosseous muscle. Alezais (1900) called this muscle in *Marmota* the short flexor of the fifth digit. The muscle is consistent in squirrels, differing only in the extent of the origin and degree to which it inserts with the flexor digiti quinti.

In other rodents it is usually similar to the abductor in squirrels. In geomyids the origin and insertion are both identical to *Sciurus* (Hill, 1937). In cricetines (Rinker, 1954) and arvicolidids (Stein, 1986), the abductor takes origin from the hypothenar fascia and cartilage, not from the pisiform bone, contrary to the report of Howell (1926) that it takes origin from the pisiform in *Neotoma*.

**M. flexor digiti quinti.** As noted above, this muscle is considered part of the abductor by Hoffmann and Weyenbergh (1870) and Parsons (1894). It is not the flexor digiti quinti of Hoffmann and Weyenbergh (1870) and Parsons (1894), who gave this name to the most ulnar of the interosseus muscles. The flexor brevis manus of Parsons (1894) may be this muscle, as suggested by Bryant (1945), but we found no sciurid in which the flexor digiti quinti inserts with flexor sublimis muscle instead of the abductor.

This muscle is presumably absent in geomyids, having not been described by Hill (1937). In other rodents, it tends to differ in its insertion on the fifth digit. In cricetines and arvicolidids (Rinker, 1954; Stein, 1986) it inserts on the flexor retinaculum on the radial side of the fifth digit.

The flexor digiti quinti is possibly derived from the abductor digiti quinti, in which case the common insertion of these two muscles, as seen in many squirrels, would be the ancestral condition. The deep palmar branch of the ulnar nerve passes between the origins of these muscles in squirrels, as in humans.

**M. abductor pollicis brevis.** The most proximal fibers of this muscle may insert on the metacarpophalangeal joint or the adjacent surface of the first metacarpal. These may be the fibers that Parsons (1894) called the opponens pollicis muscle, which would explain his report that this muscle is present in sciurids. We prefer to interpret these fibers as part of the abductor pollicis brevis, with which they are contiguous. A separate flexor pollicis brevis is not distinguishable in squirrels (Parsons, 1894; Bryant, 1945) or geomyids (Hill, 1937), but it is described in cricetine and arvicolid rodents. In other rodents the abductor pollicis brevis is similar to that of squirrels.

**M. adductor digiti quinti.** The adductor digiti quinti muscle is in the contrahentes layer, superficial to the interosseus muscles and deep to the carpal tunnel. Inexplicably, Bryant (1945) calls this muscle the opponens digiti quinti, although it inserts on the radial sesamoid of the fifth digit, not on the metacarpal. The adductor has a similar configuration in cricetines, arvicolidids, and other cricetid rodents (Parsons, 1896; Rinker, 1954; Stein, 1986). It is not described by Hill (1937) in geomyids.

**M. adductor pollicis.** The adductor pollicis muscle is also in the contrahentes layer, like the adductor digiti quinti. Bryant (1945) calls it "abductor pollicis," probably a misprint. Probably missing in

geomyids (Hill, 1937) and perhaps absent in diverse other rodents (Parsons, 1896), this adductor is reported to be consistently present in cricetine (Rinker, 1954) and arvicolid rodents (Stein, 1986).

An adductor of the second digit is not found in sciurids but does occur in cricetine and arvicolid rodents (Rinker, 1954; Stein, 1986).

**M. interossei.** The most ulnar of the eight interosseous muscles was called the "flexor digiti quinti" by Hoffmann and Weyenbergh (1870) and Parsons (1894). The confusion caused by the use of this name for two different muscles was reviewed by McMurrich (1903), who restricted the use of the name to the muscle palmar to the long flexor tendons and separated from the abductor of the fifth digit by a branch of the ulnar nerve.

This most ulnar muscle of the eight is derived from a more volar muscle layer (the hyponeural layer) than the other seven (derived from the epineural layer), and it probably should not be considered an interosseous muscle according to McMurrich (1903). It is called the opponens digiti quinti by Rinker (1954) and Stein (1986), although Rinker stated that he used the name in a topographic sense without confidence in the homology with the human muscle with the same name. McMurrich (1903) based his conclusions on the interpretations of Cunningham (1878) which have been contested in part by Campbell (1939). This whole issue needs to be reconsidered.

### Phylogeny of Flying Squirrels

The distinct differences in the morphology of the pisiform bones of flying squirrels suggest different phylogenetic groupings from those suggested by McKenna (1962) and Mein (1970). The distinct spur (or "triquetral process") on the pisiform is evident in five genera: *Petaurista*, *Aeretes*, *Trogopterus*, *Belomys*, and *Pteromyscus*. A small spur occurs in *Aeromys*. A rather different morphology, still showing a small spur, occurs in *Pteromys* and *Eupetaurus*. A spur is lacking on the pisiform of *Glaucomys*, *Eoglaucmys*, *Hylopetes*, *Petinomys*, *Petaurillus*, and *Iomys*. (The last four of these exhibit an untwisted morphology, not seen in other genera.) All these morphologies are derived relative to the presumed ancestral condition seen in tree squirrels, and they involve the bracing of the pisiform on the scapholunate and triquetrum for wing-tip support. Because of the aerodynamic importance of the wing-tip, this was probably an early modification in the history of flying squirrels and the variation among them probably also occurred early. It seems unlikely that these differences are responses to body size. A big spur occurs in large (*Petaurista*) and medium-sized (*Belomys*) flying squirrels; a small spur occurs in other large (*Eupetaurus* and *Aeromys*) squirrels; the absence of a spur characterizes small (*Petaurillus*,

*Glaucomys*) to medium-sized (*Eoglaucmys*) squirrels.

The taxonomic pattern exhibited by differences in the shape of the pisiform bones is concordant with the known pattern for attachment of the gliding membrane to the ankle. In *Glaucomys*, *Eoglaucmys*, *Hylopetes*, and *Iomys*, the tibio-carpalis muscle inserts on a tubercle at the distal end of the tibia. In *Petaurista*, *Trogopterus*, *Eupetaurus*, and *Aeromys*, the tubercle is absent (Thorington et al., 1996), and the tibio-carpalis is assumed to insert on the metatarsals, as reported in *Petaurista* and *Pteromys* (Johnson-Murray, 1977). We suggest that these two features, the morphology of the pisiform bone and the insertion of the tibio-carpalis muscle are important phylogenetic indicators, because of their importance in supporting the gliding membrane at wrist and ankle, a basic adaptation differentiating flying squirrels from all other squirrels.

The concordance of these two features suggests a more basal division of flying squirrels into two lineages, which was not recognized by McKenna (1962) and Mein (1970). It also clearly suggests that *Pteromys* is not a member of the *Glaucomys* group, and that *Aeromys* is not a member of the *Petinomys* group, contrary to McKenna (1962) and in agreement with Mein (1970). Based on this study and theirs, our phylogenetic hypothesis is ((*Glaucomys*, *Eoglaucmys*) ((*Hylopetes*, *Petinomys*) (*Iomys* (*Petaurillus*))) ((*Petaurista*, *Aeretes*) (*Trogopterus*, *Belomys*, *Pteromyscus*) (*Pteromys*) (*Aeromys*) (*Eupetaurus*)). We continue to consider flying squirrels a monophyletic group (Thorington, 1984) in contrast to the hypotheses of Black (1963, 1972) and Hight et al. (1974). If diphyletic, the two groups are probably the *Glaucomys* group (including *Iomys*, contrary to the hypothesis of Hight et al., [1974]) and the *Petaurista* group, but we submit that the preponderance of evidence supports monophyly. The grouping of *Hylopetes* and *Petinomys* is based on the distinctive pitted enamel of their teeth; *Petaurista* and *Aeretes* are generally recognized to be closely related; and the *Trogopterus* group is based on McKenna (1962), who included *Pteromyscus* in the group, which was maintained by Mein (1970). As indicated, the relative positions of *Pteromys*, *Aeromys*, and *Eupetaurus* in the *Petaurista* group are not evident to us. Further study of the postcranial anatomy, combined with reexamination of the teeth and crania, should test these ideas and provide a stronger phylogenetic hypothesis for flying squirrels.

Another unresolved issue is the rooting of the tree. We consider the flying squirrels to be a subfamily, Pteromyinae, of the squirrel family, Sciuridae, and suspect that they are derived from early tree squirrels. Mein (1970) and deBruijn and Uenay (1989) submit that the fossil evidence, based completely on dental remains, implies that flying squirrels evolved from paramyid rodents of the Eocene, independent of the other squirrels. Accordingly, Corbett and Hill



(1992) treat them as a separate family, the Pteromyidae. Other paleontologists (Emry and Korth, 1996) consider the evidence not compelling. Resolution of this disagreement will require careful, critical reexamination of the morphology of both fossil and Recent squirrels, together with analyses based on molecular data.

## ACKNOWLEDGMENTS

We thank Charles G. Anderson, who assisted in collecting data on carpal bone morphology, Lindsay A. Pappas and Diane Pitassy for assistance in completion of the manuscript, and Brian Stafford for detailed review of the manuscript. Field Museum specimens were kindly loaned to us by Lawrence R. Heaney and William T. Stanley. Access to the specimen of *Eupetaurus* was provided by Peter Zahler, who retrieved it from beneath the nest of an Eagle Owl.

## LITERATURE CITED

- Alezais H. 1900. Contribution a la myologie des rongeurs. Paris: F. Alcan.
- Black CC. 1963. A review of the North American Tertiary Sciuridae. Bull Museum Compar Zool Harvard Univ 130:100–248.
- Black CC. 1972. Holarctic evolution and dispersal of squirrels (Rodentia: Sciuridae). Evol Biol 6:305–322.
- Brizzee KR. 1941. Osteology and myology of the pectoral and pelvic girdles and limbs of the Uinta ground squirrel, *Citellus armatus*. MS Thesis, University of Utah.
- deBruijn H, Uenay E. 1989. Petauristinae (Mammalia, Rodentia) from the Oligocene of Spain, Belgium, and Turkish Thrace. Series of the Natural History Museum, Los Angeles County 33:139–145.
- Bryant MD. 1945. Phylogeny of Nearctic Sciuridae. Am Midland Natural 33:257–390.
- Campbell B. 1939. The comparative anatomy of the dorsal interosseous muscles. Anat Rec 73:115–125.
- Cartmill M. 1974. Pads and claws in arboreal locomotion. In: Jenkins FA Jr, editor. Primate locomotion. New York: Academic Press. p 45–83.
- Corbett GB, Hill JE. 1992. Mammals of the Indomalayan region. New York: Oxford University Press.
- Cunningham DJ. 1878. The intrinsic muscles of the hand of the thylacine (*Thylacinus Cynocephalus*), cuscus (*Phalangista Maculata*), and phascogale (*Phascogale Calura*). J Anat Physiol 12:434–444.
- Emry R, Korth WW. 1996. A new genus of squirrel (Sciuridae: Rodentia) from the Chadronian of western North America. J Vert Paleontol 16:775–780.
- Emry RJ, Thorington RW Jr. 1982. Descriptive and comparative osteology of the oldest fossil squirrel, *Protosciurus* (Rodentia: Sciuridae). Smithsonian Contrib Paleobiol 47:1–35.
- Gupta BB. 1966. Notes on the gliding mechanism in the flying squirrel. Occas Papers Museum Zool, Univ Michigan 645:1–7.
- Hight ME, Goodman M, Prychodko W. 1974. Immunological studies of the Sciuridae. System Zool 23:12–25.
- Hildebrand M. 1985. Digging of quadrupeds. In: Hildebrand M, Bramble DM, Liem KF, Wake DB, editors. Functional vertebrate morphology. Cambridge, MA: Harvard Univ Press. p 89–109.
- Hill JE. 1937. Morphology of the pocket gopher, mammalian genus *Thomomys*. Univ Calif Publ Zool 42:81–172.
- Hoffmann CK, Weyenbergh H Jr. 1870. Die osteologie und myologie von *Sciurus vulgaris* L., verglichen mit der anatomie der *Lemuriden* und des *Chiomys* und ueber die stellung des letzteren im natuerlichen systeme. Haarlem: Loosjes Erben.
- Hoffmann RS, Anderson CG, Thorington RW Jr, Heaney LR. 1993. Family Sciuridae. In: Wilson DE, Reeder DM, editors. Mammal species of the world: a taxonomic and geographic reference, 2nd ed. Washington, DC: Smithsonian Institution Press.
- Holmgren N. 1952. An embryological analysis of the mammalian carpus and its bearing upon the question of the origin of the tetrapod limb. Acta Zool 33:1–115.
- Howell AB. 1926. Anatomy of the woodrat. Baltimore: Williams and Wilkens.
- Johnson-Murray JL. 1977. Myology of the gliding membranes of some Petauristine rodents (genera: *Glaucomys*, *Pteromys*, *Petionomys*, and *Petaurista*). J Mamm 58:374–384.
- McKenna MC. 1962. Eupetaurus and the living Petauristine Sciurids. Am Museum Novitates 2104:1–38.
- McMurrich JP. 1903. The phylogeny of the palmar muscles. Am J Anat 2:463–500.
- Mein P. 1970. Les sciuropteres (Mammalia, Rodentia) neogenes d'Europe occidentale. Geobios 3:7–77.
- Parsons FG. 1894. On the myology of the sciuriform and hystricomorphine rodents. Proc Zool Soc Lond 18:251–297.
- Parsons FG. 1896. Myology of rodents. II. An account of the Myomorpha, together with a comparison of the muscles of the various suborders of rodents. Proc Zool Soc Lond 20:159–192.
- Peterka HE. 1936. A study of the myology and osteology of tree sciurids with regard to adaptation to arboreal, glissant and fossorial habits. Trans Kansas Acad Sci 39:313–332.
- Rinker GC. 1954. The comparative myology of the mammalian genera *Sigmodon*, *Oryzomys*, *Neotoma*, and *Peromyscus* (Cricetinae), with remarks on their intergeneric relationships. Univ Michigan, Misc Publ Mus Zool 83:1–124.
- Stafford BJ, Thorington RW Jr. 1998. Carpal development and morphology in archontan mammals. J Morphol 235:135–155.
- Stein BR. 1986. Comparative limb myology of four arvicolid rodent genera (Mammalia, Rodentia). J Morphol 187:321–342.
- Thorington RW Jr. 1984. Flying squirrels are monophyletic. Science 225:1048–1050.
- Thorington RW Jr, Thorington EM. 1989. Postcranial proportions of *Microsciurus* and *Sciurillus*, the American pygmy tree squirrels. In: Eisenberg JF, Redford KH, editors. Advances in neotropical mammalogy. Leiden: EJ Brill. p 125–136.
- Thorington RW Jr, Musante AL, Anderson CG, Darrow K. 1996. The validity of three genera of flying squirrels: *Eoglaucomys*, *Glaucomys*, and *Hylopetes*. J Mamm 77:69–83.
- Thorington RW Jr, Darrow K, Betts ADK. 1997. Comparative myology of the forelimb of squirrels (Sciuridae). J Morphol 234:155–182.
- Thorington RW Jr, Darrow K, Anderson CG. 1998. Wingtip anatomy and aerodynamics in flying squirrels. J Mamm 79:245–250.

## APPENDIX

Specimens examined (d = dissection; x = X-ray; s = skeleton). All are USNM unless otherwise indicated.

### Family Sciuridae

Subfamily Sciurinae: Tree, ground, and pygmy squirrels

Tribe Ratufini: Indo-Malayan giant squirrels

*Ratufa affinis*: 522980 (d), 198121 (s), 151757 (s)  
*Ratufa bicolor*: 5469334 (d), 254740 (x), 464512 (s), 49703 (s)

*Ratufa indica*: 548661 (d), 355785 (x), 308415 (s)

Tribe Protoxerini: African giant and sun squirrels

*Epixerus wilsoni*: 220420 (x), 220467 (x)

- Protoxerus stangeri*: 481817 (dx), 481821 (dx), 21513 (s), 21514 (s), 237333 (s), 481824 (s), 539439 (s), 539443 (s)  
*Heliosciurus gambianus*: 381419(d)  
*Heliosciurus rufobrachium*: 463545(d), 541537(d)  
Tribe Funambulini: Indian and African tree and pygmy squirrels  
Subtribe Funambulina: Indian Striped squirrels  
*Funambulus palmarum*: 448821(d), 448824(d)  
*Funambulus pennanti*: 267872 (s), 395765 (s)  
Subtribe Funisciurina: African striped squirrels and tree squirrels  
*Funisciurus anerythrus*: 463536(d)  
*Funisciurus lemniscatus*: 539418(d)  
*Paraxerus palliatus*: 548034(d)  
Tribe Callosciurini: Oriental squirrels  
*Callosciurus notatus*: 521151 (d), uncatalogued (IMR 86338) (d), 488265 (x), 488267 (x)  
*Callosciurus prevostii*: FMNH 141467 (d), 481212 (x), 481216 (x), (Uncatalogued: San Diego Zoo specimen (x))  
*Dremomys everetti*: 252163 (x), 300992 (x)  
*Exilisciurus whiteheadi*: 198722 (x), 292638 (x)  
*Glyphotes simus*: 301013 (x), 301018 (x)  
*Nannosciurus melanotis*: 124881 (x), 145387 (x), 196641 (x), 196642 (x), 311469 (x), 311470 (x)  
*Rhinosciurus laticaudatus*: 488514 (x), 488517 (x), 488548 (s)  
*Sundasciurus tenuis*: 488466 (x), 488470 (x), 488485 (x)  
*Sundasciurus hippurus*: 488403 (x), 488416 (x)  
Tribe Sciurini: Holarctic and Neotropical tree and pygmy squirrels  
*Microsciurus mimulus*: 259773 (x), 267562 (x), 581937 (x)  
*Reithrosciurus macrotis*: 197262 (x), 488087 (x)  
*Sciurus carolinensis*: 522976 (d), (uncatalogued specimen, dx), 248247 (s), 256047 (s), 297850 (s), 396002 (s), 396386 (s), 396996 (s), 396997 (s), 527997 (s), 528016 (s), 528025 (s), 548048 (s), 548051 (s)  
*Sciurus granatensis*: 495253 (d), 540703 (s)  
*Sciurus griseus*: 21513 (s), 21514 (s), 249614 (s)  
*Sciurus niger*: 546847 (d), (two uncatalogued specimens (dx)), 257965 (s), 397159 (s), 514363 (s)  
*Tamiasciurus hudsonicus*: 397070 (s), 397152 (s), 399962 (s), 497839 (s), 524525 (s), 564078 (s), 564084 (s), 551803 (s)  
Tribe Marmotini: Holarctic ground squirrels  
*Marmota flaviventris*: 575170 (s)  
*Marmota monax*: 522967 (d), 535061 (dx), 88618 (s)  
*Sciurotamias davidianus*: 258505 (s), 258508 (s), 258509 (s), 258510 (s), 258511 (s)  
*Spermophilus beechyi*: 547914 (d), 484953 (s)  
*Spermophilus richardsonii*: 398236 (d)  
Tribe Xerini: African ground squirrels  
*Atlantoxerus getulus*: 476806 (s)  
*Spermophilopsis leptodactylus*: 545231(x)  
*Xerus erythropus*: 481845 (d)  
*Xerus inauris*: 368419 (s)  
*Xerus rutilus*: CM 86231 (d), 484010 (s)  
Subfamily Pteromyinae: Flying squirrels  
*Aeretes melanopterus*: 219205 (x), 240740 (x), 548434 (x)  
*Aeromys tephromelas*: 481187 (x), 481190 (x), 196743 (s)  
*Belomys pearsoni*: 358354 (s), 359595 (x)  
*Eoglaucmys fimbriatus*: FMNH 140501 (dx), 140505 (d), 173363 (s), 173365 (s), 353243 (s)  
*Eupetaurus cinereus*: uncatalogued forelimb (dx)  
*Glaucmys sabrinus*: 235940 (s), 397067 (s), 524544 (s), 551841 (s)  
*Glaucmys volans*: 262266 (x), 262267 (x), 397031 (s), 397082 (s), 397083 (s), 525962 (s), 457978 (x), 457979 (dx)  
*Hylopetes nigripes*: 478004 (s)  
*Hylopetes phayrei*: 260622 (x), 260624 (x), 355128 (x), 355131 (x), 260621 (s)  
*Hylopetes spadiceus*: 488638 (s), uncatalogued specimens: IMR 89799 (x), 89816 (x), 89856 (x), 89883 (x), 89902 (x), 89903 (x), 89908 (x)  
*Ionys horsfieldi*: 292654 (s), 317240 (x), 317241 (x)  
*Petaurista elegans*: 84422 (x), 307576 (x), 307577 (x), 481189 (x), 481191 (x)  
*Petaurista leucogenys*: 140876 (s), 140879 (x)  
*Petaurista petaurista*: 49660 (s), 326354 (x), 353207 (x)  
*Petaurista philippensis*: 334352 (dx), 334359 (dx), 307073 (s)  
*Petaurillus kinlochii*: 488708 (x), 488709 (x), 488710 (x), 488711 (x)  
*Petinomys genibarbis*: 488670 (x), 488671 (x), 488672 (x), 488673 (x)  
*Petinomys hageni*: 143344 (x), 143345 (x)  
*Petinomys lugens*: 252319 (x), 252320 (x), 252322 (x), 252324 (x), 252326 (x)  
*Petinomys setosis*: 481121 (x), 481122 (x), 481124 (x), 481125 (x), 481129 (x)  
*Petinomys vordermani*: 481163 (x), 481165 (x), 481167 (x)  
*Pteromys volans*: 155557 (x), 172619 (x), 172620 (x), 172621 (x), 172623 (x), 172624 (x), 172626 (x), 270545 (x), 546339 (s), 172625 (x)  
*Pteromyscus pulverulentus*: 488692 (x), 488694 (x), 488696 (s), 489516 (x), 489523 (x)  
*Trogopterus xanthipes*: 268872 (s), 258520 (s), 258980 (x), 268873 (x)