

## Outcome of Lateral Mass Fixation and Fusion – A Comprehensive Analytical Study of 205 Lateral Mass Screws in 35 Patients at Punjab Institute of Neurosciences (PINS)

IJAZ HUSSAIN WADD, LIAQAT MEHMOOD AWAN, ASIF SHABIR  
YASIR-O-DIN, SYED MOHSIN AJMAL, RIZWAN MASOOD BUTT

Lahore General Hospital, LGH/PINS, Lahore, Pakistan

DOI: <https://doi.org/10.36552/pjns.v23i4.390>

### ABSTRACT

**Objective:** To see outcome, accuracy and expected complications in passing lateral mass screws in patients with cervical spine injury, degenerative disease at the cervical spine level and neoplastic lesions.

**Materials and Methods:** In this study, 35 patients were included and 205 screws passed in lateral mass patients' age ranged from 12-70 years (25 males and 10 females) with trauma to the cervical spine, degenerative disease at the cervical spine level and Intradural extramedullary benign tumors and extradural malignant neoplasm. Patients less than 12 years and more than 65 years of age, patients with traumatic ruptured disc causing spinal cord compression anteriorly and operated for cervical spine were excluded from our study. In all patients, we did lateral mass fixation with polyaxial screws and rods under fluoroscopic assistance. For assessment of screws trajectory and position, CT scan cervical spine with 3D reconstruction was performed on a first post op day to confirm screw orientation and direction and for facet, foraminal, foramen transversarium violations.

**Results:** All screws were passed by using Megrel's trajectories. Not a single patient had nerve root, cord injury nor vertebral artery injury. One patient had screw pullouts requiring reoperation. 12 to 14mm size screws were used under fluoro guidance. On postoperative CT cervical spine with 3D reconstruction shows no breach or violations of any foramen transversarium, nerve root injury or neural foramen penetration by screws. In all patients polyaxial screw/rod construct was used. Two patients had complications; one patient adjacent-level disc herniation for which anterior surgery was done and 2nd patient there were still compression over the spinal cord for which laminectomy extended to that level.

**Conclusion:** Cervical spine lateral mass fixation with polyaxial screws is a safe and effective technique in expert hands under fluoroscopic assistance.

**Keywords:** Cervical Injury, Degenerative cervical spine disease, Lateral mass screw.

### INTRODUCTION

Cervical spine is the most mobile segment of the spinal column and its mobility leads to more chances of trauma to it & variety of other degenerative spinal diseases.<sup>1</sup> The lateral mass is part of bone that lies between superior articular surface and inferior articular surface of that vertebrae superiorly and inferiorly and medial boundary is the laminae and

facet line and is attached with the vertebral body through pedicle.<sup>2</sup>

Thorough understanding of three dimensional cervical spine anatomy is required to perform surgery at cervical spine because many vital structures lie nearby the cervical spine. Good skill and fluoro guidance are also equally important for surgery in this region. Cervical cord compression due to traumatic

subluxation and degenerative cervical disease can cause motor and sensory loss of all four limbs. MRI cervical spine is the best investigation to detect compression on the cervical cord. For lateral mass screw placements, CT cervical spine with 3D reconstruction was also done to see 3 dimensional anatomy of lateral mass and for the proper planning of screw trajectory.

Cervical spine fixation can be done anteriorly as well as posterior or both approaches can be combined. The posterior cervical fixation is much easier to perform and widely practiced all over the world due to improvements in polyaxial screws and rods systems. Most of the spinal surgeons believe that after standard cervical laminectomy and decompression of spinal cord, lateral mass fixation with polyaxial screws and rods is good option for stabilization of cervical spine.<sup>3,4</sup> It is very easy technically under fluoro guidance and gives enough stability with very few little complications of nerve root or vertebral artery injuries and facet joint violations.<sup>5,6</sup> We operated all patients in prone position under fluoroscopic guidance. We used Megrel's technique for the direction and trajectory of all screws followed by fusion. A CT cervical spine with 3D was done in all cases on a first post op day to see screw trajectory and its orientations. Postoperative radiology was also done at three and six months after surgery. We conducted our study to see neurologic and vascular safety of surgery and screw trajectory and orientation on the first post op day.

## MATERIAL AND METHODS

### Study Design

It is prospective study. We conducted the study in the department of Neurosurgery Unit 1 at Punjab institute of Neurosciences (PINS), Lahore from 1st Jan, 2018 to 31st December, 2018.

### Inclusion Criteria

This study included 205 screws passed in 35 patients, with different pathologies like trauma, degenerative, neoplastic etc.

### Exclusion Criteria

Patients younger than 12 years of age and older than 65 years, with traumatic ruptured discs causing compression anteriorly and patient with previous

surgery over cervical spine level were excluded from our study.

### Data Collection

MRI of cervical spine along with CT scan cervical spine with 3D reconstruction were obtained in all patients. All data collected and entered on Proforma. Any neurological or vascular complication and screw orientation were noted. All patients were followed and follow up was done at 6 weeks, 3 months, 6 months postoperatively. The purpose of our study was to see the orientation of screws and their violation of the spinal canal, neural foramen and foramen transversarium on the first post op day rather than later fusion status.

### Data Analysis

Statistical analysis was done with the help of SPSS version 22. Any Categorical data was expressed in percentages and frequency like age, gender and level of injury. The quantitative data was expressed in mean  $\pm$  SD with range like age and no of screws. Chi square test was used and P-value of  $\leq 0.05$  was taken as significant.

## RESULTS

### Gender Distribution

25 (71.42%) patients were male and 10 (28.57%) female.

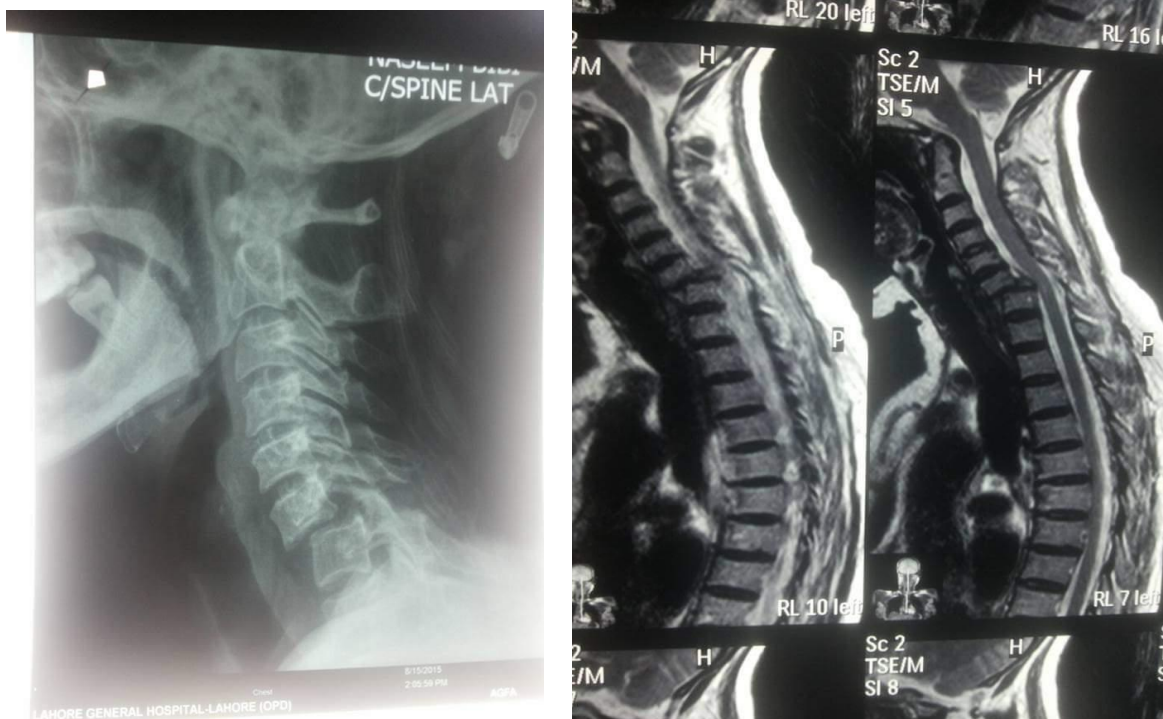
### Age Incidence

Age range of 12-70 yrs with mean of  $56 \pm 7$  yrs.

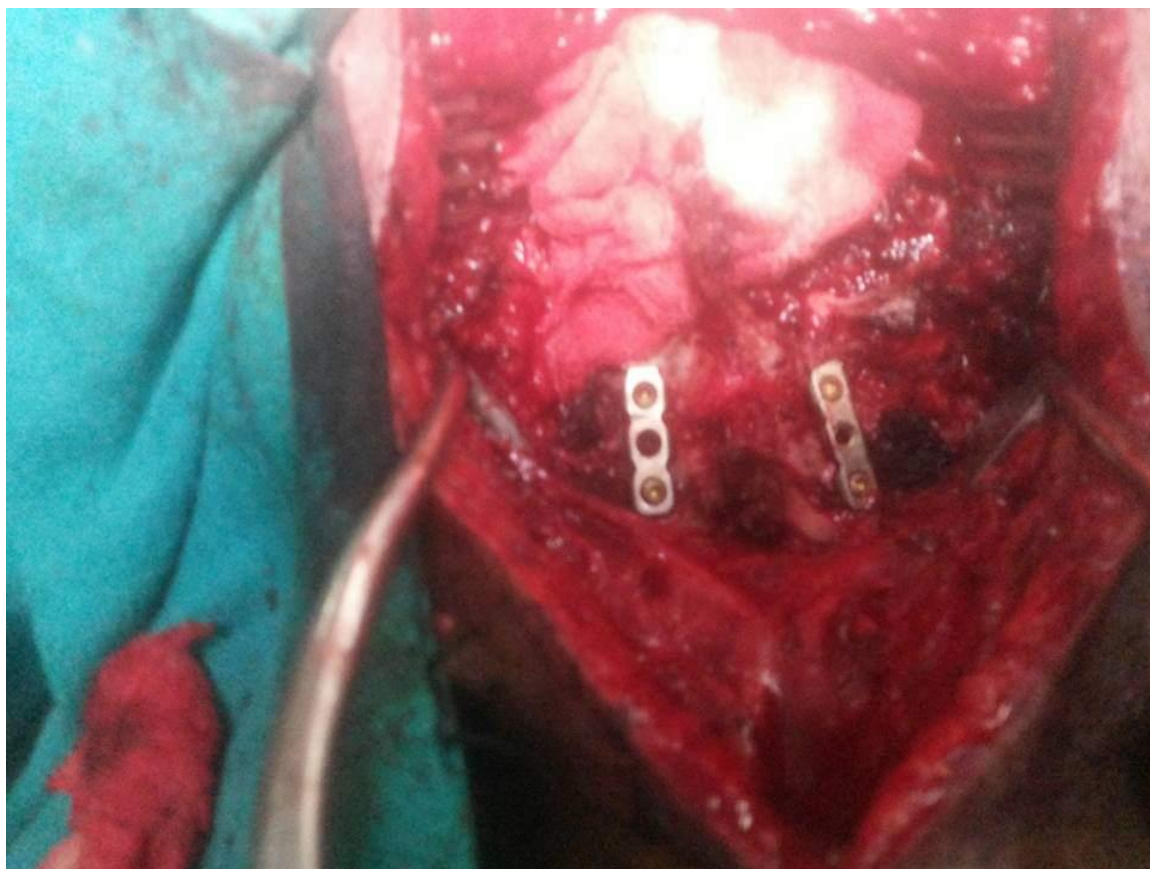
### Clinical Presentation

The 205 screws passed in 35 patients of different pathologies including trauma (10 cases, 28.57%), degenerative disease (17 cases, 48.57%), iatrogenic instability (1 cases, 2.85%), rheumatoid arthritis (1 cases, 2.85%), malignant extradural tumors (2 cases, 5.71%), and benign intra-dural extra-medullary tumors (4 cases, 11.42%).

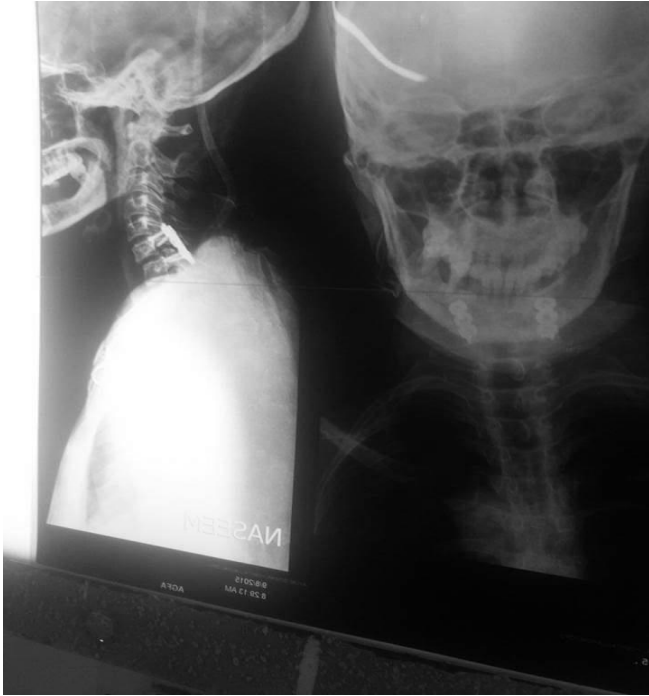One patient (2.85%) was smoker with no other risk factor in any patient. Maximum number of levels fixed were 4 with mean 2.6. The 92.4% of all the screws passed were properly oriented with bi-cortical purchase.



**Fig. 1:** Pre-operative X-Ray and MRI Cervical Spine.



**Fig. 2:** Per-Operative view, Fixation via Mini Plates.



**Fig. 3:** Post-Operative X-Ray of Cervical Spine.

### Outcome

We used 12-14-mm screws were used in our patients. In one of our patients (2.85%) there were screw pullouts, in one patient (2.85%), there was an adjacent level symptomatic disc herniation needing surgery and in one patient (2.85%), the adjacent level residual stenosis required the extension of laminectomy and decompression of the spinal cord.

No root or vertebral artery injury in any patient nor any neurological deterioration in any patient.

### DISCUSSION

Spinal cord injury is mostly due to trauma, degenerative and neoplastic lesions and had a bad outcome if injury to the cervical spine. Traumatic injury to cervical spinal cord had poor outcomes.<sup>7</sup> Surgical manipulations at cervical spine is too much technically demanding with a lot of risk to surrounding vital structures, especially injury to the carotid artery, esophagus, trachea and cervical nerve roots or cord. The injuries to the cervical spine is mostly at young age and mostly caused by road traffic accidents followed by sports injuries and violence.<sup>23</sup> Mild trauma like a ground level fall can cause cervical cord injury in older patients. The cervical spondylotic changes are more at older ages and these changes increases the chances of injury to cervical cord at this

age from minor trauma and nondynamic injuries.<sup>24</sup> Early decompression of the cervical cord after injury leads to good outcome.<sup>8</sup> There are multiple surgical options and procedures (anterior and posterior) available and being practiced with its own indications and complications. When the posterior elements, especially laminae and spinous processes are absent or compromised with disease lateral mass fixation is the procedure of choice.<sup>9</sup>

The transarticular fixation is another posterior surgical option in expert hands, but not most commonly done by spinal surgeons.<sup>10</sup> Many techniques for fixation of the lumbar spine are being used by spine surgeons.<sup>11</sup> But for Cervical spine, Roy-Camille et al,<sup>12</sup> first started lateral mass screw and platefixations to stabilize the cervical spine. Later on, many modifications in posterior cervical fixation techniques were done by many surgeons<sup>13</sup> like Roy-Camille and Megrel techniques. Anatomically lateral mass is located between superior and inferior articular surfaces of the facet joint and laminae. Our starting point was 1mm inferior and medial to the mid-point of lateral mass and directed screws 20 degree up and laterally with continuous fluoro monitoring. This technique has minimum chances of injury to the spinal cord and nerve roots as suggested by Megrel.<sup>13</sup> At present, the lateral mass fixation is commonly being used for cervical spine fixation worldwide. Lateral mass fixation is not without complications. Injuries to vertebral artery, facet joint, and/or nerve root are the most common complications and lateral mass can fracture during drilling or screw threading. These complications are mostly due to wrong trajectory and angulations in screw threading and not using appropriate size screws. All described techniques may result in different complications, depending on the surgeon's perfection of the technique. In all techniques used for lateral mass fixations, proper screw size and diameter with its angulations and trajectory are properly described and practically very difficult to follow to be perfect and exact.<sup>14</sup> A lot of work has been done on both clinically and in the laboratory on cadavers by spine surgeons on the lateral mass fixation to minimize these complications and to prove why these complications occurs. Ebraheim et al did a study on cadavers and proved that the foramen transversarium lies at midpoint of the lateral mass.<sup>14</sup>

Some screws and implant related complications can occur like loosening and its pulling out and the rod breakage. Lateral mass screws fixation is safe and acceptable as observed in our study because no

patients developed any neurological and vascular complications. Katonis et al,<sup>15</sup> proved that it is safe with no chances of injury to neural tissue nor vertebral artery. Graham and Roche<sup>17</sup> proved that it's not proper direction and position of the screws that leads to these neurovascular complications. Roche et al<sup>16</sup> proved that it's not necessary to use a fluoroscope in every case, but we used fluoroscopy in every patient and it gives us more accurate placements of screws and improves the safety. We can think for confirmation of screw orientation and its trajectory fluoroscopy is important. Other studies,<sup>19</sup> have shown that lateral mass fixation is safe, sound and effective methods for posterior spinal fixation in properly selected cases. The patients in which anatomy of lateral mass is abnormal, there are more chances of injury to nerves and vessels by posterior fixation.<sup>20</sup> CT scan cervical spine with 3D reconstruction is preoperatively necessary to select the size of screws and see lateral mass anatomy. Computed tomography (CT) scanning can show spinal fractures much better and is cost effective.<sup>21,22</sup>

## RECOMMENDATION

We recommend that surgeons using this technique should know the cervical anatomy in 3 dimensional views preoperatively, then select the case for posterior fixation with favorable anatomy.

## CONCLUSION

Cervical spine lateral mass fixation with polyaxial screws is a safe and effective technique in expert hands under fluoroscopic assistance.

## REFERENCES

1. Umerani MS, Abbas A, Sharif S. Clinical Outcome in Patients with Early versus Delayed Decompression in Cervical Spine Trauma. *Asian Spine J.* 2014; 8: 427–434. Doi:10.4184/asj.2014.8.4.42.
2. Jónsson H Jr, Rauschnig W. Anatomical and morphometric studies in posterior cervical spinal screw-plate systems. *J Spinal Disord.* 1994; 7: 429–438.
3. Song M, Zhang Z, Lu M, Zong J, Dong C, Ma K, et al. Four lateral mass screw fixation techniques in lower cervical spine following laminectomy: a finite element analysis study of stress distribution. *Bio Medical Engineering Online*, 2014; 13: 115. Doi:10.1186/1475-925X-13-115.
4. Du W, Zhang P, Shen Y, Zhang YZ, Ding WY, Ren LX. Enlarged laminectomy and lateral mass screw fixation for multilevel cervical degenerative myelopathy associated with kyphosis. *Spine J.* 2014; 14: 57–64. Doi:10.1016/j.spinee.2013.06.017.
5. Mikhael MM, Celestre PC, Wolf CF, Mroz TE, Wang JC. Minimally invasive cervical spine for laminotomy and lateral mass screw placement. *Spine (Phila Pa 1976)* 2012; 37: 318–322.
6. Yoshihara H, Passias PG, Errico TJ. Screw-related complications in the subaxial cervical spine with the use of lateral mass versus cervical pedicle screws: a systematic review. *J Neurosurg Spine*, 2013; 19: 614–623. Doi:10.3171/2013.8.SPINE13136.
7. Coe JD, Vaccaro AR, Dailey AT, Skolasky RL, Jr, Sasso RC, Ludwig SC, et al. Lateral mass screw fixation in the cervical spine: a systematic literature review. *J Bone Joint Surg Am.* 2013; 4 (95): 2136–2143.
8. Al-Barbarawi MM, Allouh MZ. Cervical lateral mass screw-rod fixation: Surgical experience with 2500 consecutive screws, an analytical review, and long-term outcomes. *Br J Neurosurg.* 2015; 29: 699–704. Doi:10.3109/02688697.2015.1026798.
9. Jost GF, Bisson EF, Schmidt MH. Computed tomography-based determination of a safe trajectory for placement of transarticular facet screws in the subaxial cervical spine. *J Neurosurg Spine*, 2012; 16: 334–339. Doi:10.3171/2011.12.SPINE11141.
10. Pal D, Bayley E, Magaji SA, Boszczyk BM. Freehand determination of the trajectory angle for cervical lateral mass screws: how accurate is it? *Eur Spine J.* 2011; 20: 972–976. Doi:10.1007/s00586-011-1694-9.
11. Roy-Camille R, Saillant G, Laville C. et al. Treatment of lower cervical spine injuries—C3 to C7. *Spine*, 1992; 17 (10S): S442–S446.
12. Anderson P A, Henley M B, Grady M S, Montesano P X, Winn H R. Posterior cervical arthrodesis with AO reconstruction plates and bone graft. *Spine*, 1991; 16 (3, Suppl.): S72–S79.
13. Heller JG, Silcox DH, 3rd, Sutterlin CE., 3rd. Complications of posterior cervical plating. *Spine (Phila Pa 1976)* 1995; 20: 2442–8.
14. Ebraheim NA, Xu R, Yeasting RA. The location of the vertebral artery foramen and its relation to posterior lateral mass screw fixation. *Spine*, 1996; 21: 1291–1295.
15. Katonis P, Papadakis SA, Galanakos S, Paskou D, Bano A, Sapkas G, et al. Lateral mass screw complications: analysis of 1662 screws. *J Spinal Disord Tech.* 2011; 24: 415–420. Doi:10.1097/BSD.0b013e3182024c06.
16. Roche S, Freitas DJ, Lenehan B, Street JT, McCabe JP. Posterior cervical screw placement without image guidance: a safe and reliable practice. *J Spinal Disord Tech.* 2006; 19: 383–388.
17. Yehya A. The clinical outcome of lateral mass fixation after decompressive laminectomy in cervical spondylotic myelopathy. *AJM.* 2014; 51: 153–159.
18. Chowdhury FH, Haque MR. C1-C3 Lateral Mass

- Screw-Rod Fixation and Fusion for C2 Pathologies and Hangman's Fractures. *Asian Spine J.* 2014; 8: 735–746. Doi:10.4184/asj.2014.8.6.735.
19. Kim DY, Kim JY, Yoon SH, Park HC, Park CO. Radiological Efficacy of Cervical Lateral Mass Screw Insertion and Rod Fixation by Modified Magerl's Method (Yoon's Method) with Minimum 2 Years of Follow-up. *Korean J Spine*, 2012; 9: 137–141.
  20. Brown CV, Antevil JL, Sise MJ, Sack DI. Spiral computed tomography for the diagnosis of cervical, thoracic, and lumbar spine fractures: its time has come. *J Trauma*. 2005 May, 58 (5): 890-5; Discussion 895-6.
  21. Grogan EL, Morris JA Jr, Dittus RS, et al. Cervical spine evaluation in urban trauma centers: lowering institutional costs and complications through helical CT scan. *J Am Coll Surg.* 2005 Feb. 200 (2): 160-5.
  22. Uhrenholt L, Charles AV, Hauge E, Gregersen M. Pathoanatomy of the lower cervical spine facet joints in motor vehicle crash fatalities. *J Forensic Leg Med.* 2009 Jul. 16 (5): 253-60.
  23. Kouyoumdjian P, Guerin P, Schaelderle C, Asencio G, Gille O. Fracture of the lower cervical spine in patients with ankylosing spondylitis: Retrospective study of 19 cases. *Orthop Traumatol Surg Res.* 2012 Sep. 98 (5): 543-51.

**Additional Information**

**Disclosures:** Authors report no conflict of interest.

**Ethical Review Board Approval:** The study was conformed to the ethical review board requirements.

**Human Subjects:** Consent was obtained by all patients/participants in this study.

**Conflicts of Interest:**

In compliance with the ICMJE uniform disclosure form, all authors declare the following:

**Financial Relationships:** All authors have declared that they have no financial relationships at present or within the previous three years with any organizations that might have an interest in the submitted work.

**Other Relationships:** All authors have declared that there are no other relationships or activities that could appear to have influenced the submitted work.

*Address for Correspondence:*

*Dr. Ijaz Hussain Wadd, Lahore General Hospital, LGH/PINS, Lahore, Pakistan. Email: drejazns@gmail.com*

AUTHORSHIP AND CONTRIBUTION DECLARATION			
Sr.#	Author's Full Name	Intellectual/Contribution to Paper in Terms of:	
1.	<b>Ijaz Hussain Wadd</b> (Main/Principal Author).	1. Proposed topics and Basic Study Design, methodology.	Signature by the author(s) IJAZ WADD
2.	<b>Liaqat Mehmood Awan</b> (2nd Author)	2. Data collection and calculations	
3.	<b>Asif Shabir</b> (5th Author)	3. Analysis of data and interpretation of results etc.	
4.	<b>Yasir-o-Din</b> (4th Author)	4. Literature review and manuscript writing	
5.	<b>Syed Mohsin Ajmal</b> (3rd Author)	5. Paper writing, referencing, Data Calculations and quality insurer	
6.	<b>Rizwan Masood Butt</b> (6th Author)	6. Study Design and methodology	

Date of Submission: 11-10-2019

Date of Revision: 28-11-2019

Date of Online Publishing: 25-12-2019

Date of Print: 31-12-2019