

PDF hosted at the Radboud Repository of the Radboud University Nijmegen

The following full text is a publisher's version.

For additional information about this publication click this link.

<http://hdl.handle.net/2066/24306>

Please be advised that this information was generated on 2021-10-04 and may be subject to change.

LIPOAMIDE DEHYDROGENASE DEFICIENCY: A NEW CAUSE FOR RECURRENT MYOGLOBINURIA

O.N. ELPELEG, MD, A.B. SAADA, PhD, A. SHAAG, MSc, J.Z. GLUSTEIN, MD, W. RUITENBEEK, PhD, I. TEIN, MD, and J. HALEVY, MD

Inborn errors of pyruvate metabolism and the mitochondrial respiratory chain are rarely associated with recurrent myoglobinuria. A defect in the proteins containing iron-sulfur clusters, including components of the Krebs cycle and the mitochondrial respiratory chain, was found in 1 patient⁶ and deletions of mitochondrial DNA (mtDNA) were reported in 3 patients.^{8,13} Severe coenzyme Q deficiency in muscle was detected in 2 sisters who suffered since early childhood from recurrent myoglobinuria and myopathy, short stature, seizure disorder, and cerebellar symptoms.¹¹ We describe a 37-year-old man with recurrent myoglobinuria and lactic acidemia due to deficiency of the mitochondrial enzyme lipoamide dehydrogenase (LAD).

CASE REPORT

A 37-year-old man of Ashkenazi-Jewish origin developed generalized weakness, recurrent vomiting, and weight loss of 10 kg over a period of 2 months. His parents, 2 sisters, and 4 children were healthy. He suffered several episodes of muscle weakness associated with "anicteric hepatitis" in the past 17 years. Prior to admission, he had elevated alanine aminotransferase (ALT) (peak value, 556 U/L; control, 5–50 U/L) and aspartate aminotransferase (AST)

(231 U/L; control, 7–56 U/L). On admission, he had symmetric generalized hyporeflexia. Electromyography revealed low-voltage polyphasic motor unit potentials. Creatine kinase (CK) (11277 U/L; control, 30–150 U/L), AST (400 U/L), and ALT (757 U/L) were elevated. After administration of chlorpromazine (12.5 mg IV) to alleviate vomiting, he was found pale, tachypneic, and confused, with severe metabolic acidosis (blood pH 6.8, pCO₂ 14). Serum lactate was 29.7 mmol/L (control, 0.9–2.1 mmol/L), β -hydroxybutyrate 2.77 mmol/L (control, 0.05–0.2 mmol/L), acetoacetate 0.28 mmol/L (control, 0.02–0.15 mmol/L), CK 71000 U/L, serum carnitine 167 μ mol/L (control, 30–60 μ mol/L), AST 591 U/L, and ALT 1640 with prolongation of the prothrombin time. The branched-chain amino acids in plasma were 1.5–2.5 times the upper limit of the control range. In the urine, myoglobin was strongly positive and organic acid analysis revealed massive excretion of lactic and β -hydroxybutyric acids, low-normal levels of Krebs cycle components, and no evidence of fatty acid oxidation defect. A biopsy of the quadriceps revealed small cytoplasmic lipid droplets. Total muscle carnitine was 3.3 μ mol/g tissue (control, 2.7–4.6) and nonesterified carnitine was 3.1 μ mol/g tissue (control, 2.2–4.2). The patient recovered with complete normalization of all biochemical abnormalities, but reported occasional vomiting and mild exertional myalgia. Therapy with lipoic acid was recommended but compliance was poor. He was rehospitalized 5 months later because of vomiting, weakness, and elevation of lactate (24.2 mol/L), ammonia (150 μ mol/L), and CK (1129 U/L). An intractable metabolic acidosis developed and the patient expired 12 h after admission. Consent for autopsy was not given.

METHODS

In the mitochondrial enriched fraction of the muscle, the activity of citrate synthase, reduced form of nicotinamide adenine dinucleotide (NADH)-

From the Metabolic and the Internal Medicine Units, Shaare-Zedek Medical Center, Jerusalem, Israel (Drs. Elpeleg, Saada, Glustein, and Halevy, and Mr. Shaag); Department of Pediatrics, University Hospital Nijmegen, Nijmegen, The Netherlands (Dr. Ruitenbeek); and Division of Neurology, the Hospital for Sick Children, Toronto, Canada (Dr. Tein).

Acknowledgment: This work was supported in part by the Israeli Ministry of Health, grant no. 3272-95, and by the Mirsky Foundation. The expert technical assistance of C. Belaishe and E. Chen is acknowledged.

Address reprint requests to Orly N. Elpeleg, MD, Metabolic Unit, Shaare-Zedek Medical Center, Jerusalem 91031, Israel.

Accepted for publication August 6, 1996.

CCC 0148-639X/97/020238-03
© 1997 John Wiley & Sons, Inc.

ferricyanide reductase, antimycin-sensitive succinate-cytochrome *c* oxidoreductase, succinate-ubiquinone reductase, ubiquinol-cytochrome *c* reductase, pyruvate dehydrogenase complex (PDHc), and cytochrome *c* oxidase were determined. The activity of carnitine palmitoyltransferase was measured in the 600-g supernatant of the muscle and the activities of PDHc, pyruvate decarboxylase, LAD, and α -ketoglutarate dehydrogenase complex (α KGDHc) were determined in muscle homogenate and in fibroblasts.^{5,14,18,19}

PDHc antiserum was produced in rabbits as described by De Marcucci et al.¹ LAD antiserum was produced by immunization of rabbits with 0.5 mg of LAD (Sigma Chemicals, St. Louis, MO) in complete Freund's adjuvant, followed by three boosts in incomplete Freund's adjuvant. Muscle mitochondrial fractions of the patient and controls were separated by sodium dodecyl sulfate/polyacrylamide gel electrophoresis (SDS-PAGE), transferred to polyvinylidene difluoride (PVDF) membrane, and incubated with anti-PDHc or anti-LAD antisera. Antigen-antibody complexes were visualized using the alkaline-phosphatase conjugate substrate kit (Bio-Rad Laboratories, Richmond, CA).

Genomic DNA was isolated and cDNA was produced from fibroblasts of the patient and 5 controls. Direct sequencing of the entire coding region of the LAD gene and of a genomic DNA fragment up to nt -207 was performed as previously described.⁴

RESULTS

The enzymatic analysis revealed normal or elevated activities of all mitochondrial enzymes in muscle tissue with the exception of PDHc (11% of the control mean), α KGDHc (5%), and LAD (21%). The activity of LAD in fibroblasts was also reduced (11.5 nmol/min/mg protein; control, 83 ± 7.6).

The western blot disclosed reduced amount of the LAD protein (25% of the control) and normal amounts of pyruvate decarboxylase subunits ($E_{1\alpha}$ and $E_{1\beta}$), transacetylase (E_2), and the X protein (Fig. 1).

No mutations were detected in the coding region of the cDNA of LAD and the 5' flanking region up to nt -207.

DISCUSSION

Recurrent myoglobinuria was reported to accompany at least 17 inborn errors of metabolism. These include six heritable defects in glycogenolysis or glycolysis, six in the pathway of short-, medium-, or long-chain fatty acid oxidation, one in the pentose phosphate pathway, one in the purine nucleotide cycle, and three in the respiratory chain, Krebs cycle, and mtDNA. Partial deficiency of carnitine palmitoyltransferase II is the most common cause of recurrent rhabdomyolysis.^{2,12,13,16,20}

We attribute the recurrent myoglobinuria and lactic acidemia to LAD deficiency in this patient. LAD is one of the three catalytic proteins of the

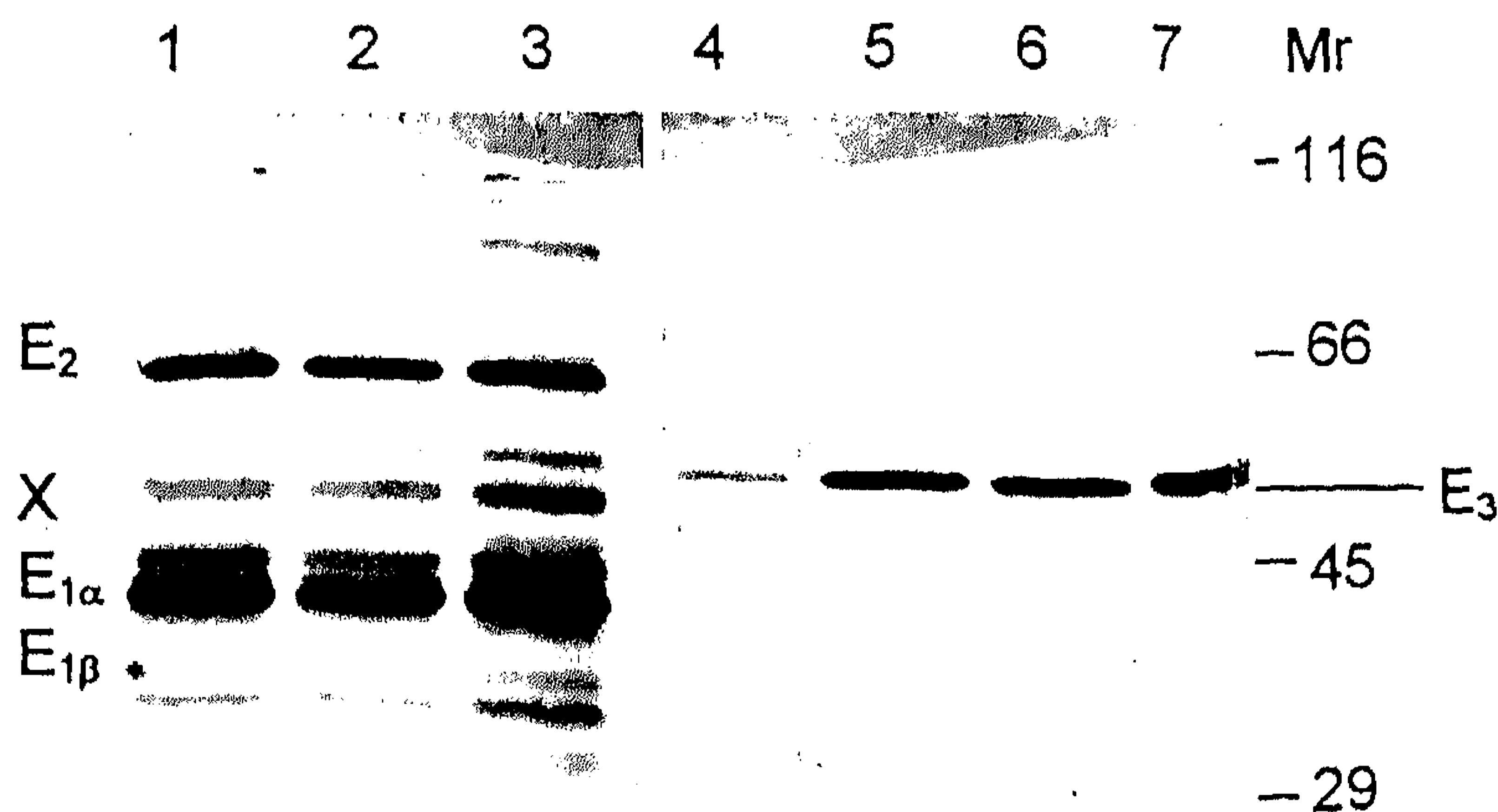


FIGURE 1. Western blot analysis: Lanes 1 and 4: 5 μ g of mitochondrial protein of the patient; lanes 2, 3, 5, and 6: 5 μ g of mitochondrial protein of 2 controls with citrate synthase activity which is similar to that of the patient; lane 7: porcine LAD. Lanes 1-3 were exposed to anti-PDHc antiserum (this serum does not react with LAD). Lanes 4-7 were exposed to anti-LAD antiserum.

PHDc which converts pyruvate to acetyl-CoA and a component of two other α -keto acid dehydrogenase complexes, α KGDHc and branched-chain keto acid dehydrogenase complex. Thus, the lactic acidemia, elevation of branched-chain amino acids, and reduction of both PDHc and α KGDHc as seen in our patient can all result from a single defect in LAD.

Because abnormalities of mitochondrial enzymes are not commonly associated with rhabdomyolysis, we considered the possibility that the deficiency of LAD was an epiphenomenon. However, the defect was also present in fibroblasts which were propagated in culture, excluding a transient inhibition of the enzyme activity.

The few patients with LAD deficiency previously reported had a clinical picture which was in no way similar to that of our patient. Their disease was characterized by progressive neurological deterioration and lactic acidemia, and most of them died within the first few years of life.^{9,10,14,15,17} Peripheral muscle involvement was not previously documented. We have diagnosed several children with LAD deficiency whose presentation in infancy was of hepatocellular failure, sparing central nervous system and muscle.^{3,4} In some of them, sequencing of the LAD gene revealed an insertion mutation within the leader sequence. In the present patient, no mutation was identified in the entire coding region of the LAD gene or in the immediate 5'-flanking region. In view of the reduced quantity of the enzymatic protein in the muscle tissue, the disease-causing mutation may interfere with the translation or transcription process; such a mutation may reside in fragments -208 to -583 and -646 to -864, which were shown to contain positive transcriptional regulatory elements and were not yet analyzed by us.⁷

In summary, the present report widens the clinical spectrum of LAD deficiency to include adult-onset recurrent myoglobinuria, and indicates that LAD deficiency should be included in the differential diagnosis.

REFERENCES

1. De Marcucci OL, Hunter A, Lindsay JG: Low immunogenicity of the common lipoamide dehydrogenase subunit (E3) of mammalian pyruvate dehydrogenase and 2-oxoglutarate dehydrogenase multienzyme complexes. *Biochem J* 1985;226:509-517.
2. Dionisi-Vici C, Burlina AB, Bertini E, Bachmann C, Mazziotta MRM, Zacchello F, Sabetta G, Hale DE: Progressive neuropathy and recurrent myoglobinuria in a child with long-chain 3-hydroxyacyl-coenzyme A dehydrogenase deficiency. *J Pediatr* 1991;118:744-746.
3. Elpeleg ON, Ruitenbeek W, Jakobs C, Barash V, Devivo D, Amir N: Favourable outcome of congenital lactic acidemia due to lipoamide dehydrogenase deficiency. *J Pediatr* 1995;126:72-74.
4. Elpeleg ON, Shaag A, Glustein JZ, Anikster Y, Joseph A, Saada A: Lipoamide dehydrogenase deficiency in Ashkenazi Jews: an insertion mutation in the mitochondrial leader sequence. *Hum Mutat* (in press).
5. Fischer JC, Ruitenbeek W, Gabreels FJM, Janssen AJM, Renier WO, Sengers RCA, Stadhouders AM, Ter Laak HJ, Trijbels JMF, Veerkamp JHA: A mitochondrial myopathy: the first case with an established defect at the level of coenzyme Q. *Eur J Pediatr* 1986;144:441-444.
6. Hall RE, Henrikson KG, Lewis SF, Haller RG, Kennaway NG: Mitochondrial myopathy with succinate dehydrogenase and aconitase deficiency. Abnormalities of several iron-sulfur proteins. *J Clin Invest* 1993;92:2660-2666.
7. Johanning GL, Morris JI, Madhusudhan KT, Samols D, Patel MS: Characterization of the transcriptional regulatory region of the human dihydrolipoamide dehydrogenase gene. *Proc Natl Acad Sci USA* 1992;89:10964-10968.
8. Keightley JA, Hoffbuhr KC, Burton MD, Salas VM, Johnston WSW, Penn AMW, Buist NRM, Kennaway NG: A microdeletion in cytochrome c oxidase (COX) subunit III associated with COX deficiency and recurrent myoglobinuria. *Nat Genet* 1996;12:410-416.
9. Matalon R, Stumpf DA, Michals K, Hart RD, Parks JK, Goodman SI: Lipoamide dehydrogenase deficiency with primary lactic acidosis: favourable response to treatment with oral lipoic acid. *J Pediatr* 1983;104:65-69.
10. Munnich A, Saudubray JM, Taylor J, Charpentier C, Marsac C, Rocchiccioli F, Amedee-Manesme O, Coude FX, Frezal J, Robinson BH: Congenital lactic acidosis, α -ketoglutaric aciduria and variant form of maple syrup urine disease due to a single enzyme defect. Dihydrolipoyl dehydrogenase deficiency. *Acta Paediatr Scand* 1982;71:167-171.
11. Ogashara S, Engel AG, Frens D, Mack D: Muscle coenzyme Q deficiency in familial mitochondrial encephalomyopathy. *Proc Natl Acad Sci USA* 1989;86:2379-2382.
12. Ogilvie I, Pourfarzam M, Jackson S, Stockdale C, Bartlett K, Turnbull DM: Very long-chain acyl coenzyme A dehydrogenase deficiency presenting with exercise-induced myoglobinuria. *Neurology* 1994;44:467-473.
13. Ohno K, Tanaka M, Sahashi K, Ibi T, Sato W, Yamamoto T, Takahashi A, Ozawa T: Mitochondrial DNA deletions in inherited recurrent myoglobinuria. *Ann Neurol* 1991;29:364-369.
14. Robinson BH, Taylor J, Sherwood WG: Deficiency of dihydrolipoyl dehydrogenase (a component of the pyruvate and α -ketoglutarate dehydrogenase complexes): a cause of congenital chronic lactic acidosis in infancy. *Pediatr Res* 1977;11:1198-1202.
15. Robinson BH, Taylor J, Kahler SG, Kirkman HN: Lactic acidemia, neurological deterioration and carbohydrate dependence in a girl with dihydrolipoyl dehydrogenase deficiency. *Eur J Pediatr* 1981;136:35-39.
16. Ruitenbeek W, Poels PJE, Turnbull DM, Garavaglia B, Chalmers RA, Taylor RW, Gabreels FJM: Rhabdomyolysis and acute encephalopathy in late onset medium-chain acyl-CoA dehydrogenase deficiency. *J Neurol Neurosurg Psychiatry* 1995;58:209-214.
17. Sakaguchi Y, Yoshino M, Aramaki S, Yoshida I, Yamashita F, Kuhara T, Matsumoto I, Hayashi T: Dihydrolipoyl dehydrogenase deficiency: a therapeutic trial with branched-chain amino acid restriction. *Eur J Pediatr* 1986;145:271-274.
18. Scholte HR, Jennekens FGI, Bouvy JJB: Carnitine palmitoyltransferase II deficiency with normal carnitine palmitoyltransferase I in skeletal muscle and leukocytes. *J Neurol Sci* 1979;40:39-51.
19. Sperl W, Ruitenbeek W, Kerkhof CMC, Sengers RCA, Trijbels JMF, Guggenbichler JP, Janssen AJM, Bakkeren JAJM: Deficiency of the α and β subunits of pyruvate dehydrogenase (E₁) in a patient with lactic acidosis and unexpected sudden death. *Eur J Pediatr* 1990;149:487-492.
20. Tein I, DiMauro S, Rowland LP: Myoglobinuria, in Vinken PJ, Bruyn GW, Klawans HL (eds): *Handbook of Clinical Neurology*. Amsterdam, Elsevier Science Publishers B.V., 1992, vol 18 (62), Myopathies, pp 553-593.