

## PERCUTANEOUS HEART VALVE INTERVENTIONS

# Percutaneous heart valve interventions: a South African perspective

**H. Weich and A.F. Doubell**

Division of Cardiology, Department of Medicine, Stellenbosch University and Tygerberg Hospital

**Address for correspondence:**

Dr Hellmuth Weich  
Senior specialist  
Cardiology Unit  
Tygerberg Hospital & Stellenbosch University  
Parow  
7505  
South Africa

**Email:**

[hweich@sun.ac.za](mailto:hweich@sun.ac.za)

### INTRODUCTION

Valvular heart disease represents a significant health care problem worldwide. More than 5 million Americans are diagnosed with heart valve lesions and 60 000 artificial valves are implanted annually in the USA.<sup>(1)</sup> The aetiology of valve disease in the developed world is predominantly degenerative. Research and technical advances in valve replacement surgery are therefore mainly focused on degenerative valve disease. Typical degenerative valve lesions are senile aortic stenosis (AS) and mitral valve regurgitation (MR) due to prolapse.

These developments may not be as relevant in the South African context where the aetiology of valve disease is frequently rheumatic and the affected patient population is much younger. The prevalence of rheumatic heart disease in South Africa is unknown; a prevalence of 0.69% has been reported for children, rising to 2% for children 12-14 years of age.<sup>(2)</sup> Rheumatic heart disease typically results in mitral stenosis (MS) and MR, and the latter, when present, has a completely different mechanism to the causes of MR mostly seen in developed countries.

### ABSTRACT

**Valvular heart disease represents a significant health care challenge in South Africa, mainly due to the prevalence of rheumatic fever. This review discusses the recent advances in percutaneous heart valve treatment, including heart valve replacement, as an alternative to open prosthetic valve replacement and its relevance in South Africa.**

**Balloon mitral valvotomy is discussed with emphasis on patient selection, management during pregnancy and management in the presence of left atrial thrombus. Further developments regarding the percutaneous treatment of mitral valve disease include percutaneous treatment of mitral incompetence by annuloplasty via the coronary sinus and edge-to-edge repair with the aid of a mitral clip.**

**Transcatheter aortic valve replacement is the more developed procedure and two valves have the CE mark of approval. Both have good short to medium term data demonstrating efficacy but are technically difficult to insert, very expensive and patient selection remains a major problem. Their use is thus limited to patients turned down for conventional surgery.**

**Percutaneous pulmonary valve replacement has good evidence to show efficacy but its use is largely limited to patients with degenerated pulmonary outflow tract conduits.**

SAHeart 2009; 6:90-99

For nearly four decades open prosthetic valve replacement has been the only option for most of these patients, but in 2000 Phillip Bonhoeffer replaced the first heart valve (a pulmonary valve) percutaneously<sup>(3)</sup> and in 2002, Cribier performed the first percutaneous replacement of an aortic valve.<sup>(4)</sup> Percutaneous heart valve replacement has enjoyed a lot of interest with numerous new developments since then. This paper will discuss these developments and their relevance to South Africa.

### BALLOON MITRAL VALVOTOMY

Balloon mitral valvotomy (BMV) for rheumatic mitral stenosis is widely used throughout South Africa and there is considerable local expertise for this procedure. The technical aspects of the procedure are beyond the scope of this review and will not be discussed.

## Patient Selection

Several studies have documented the excellent long-term outcome of the minimally invasive BMV procedure.<sup>(5,6)</sup> In a series of 1 024 patients followed up for a median of 49 months, the 10-year actuarial rate for survival free of surgery or repeat dilatation was 67 % for the patients who had a good immediate result. Pre-procedural patient selection is pivotal to achieving a good immediate result.

The following factors were identified as predictors of a poor long-term result after BMV:

### 1. Valve factors

- final mitral valve area of  $<1.75\text{cm}^2$  (relative risk 1.9);
- mean gradient  $\geq 6\text{mmHg}$  (relative risk 4.0); and
- grade 2 MR (relative risk 1.4).<sup>(5)</sup>

### 2. Clinical factors

- age  $>70$ ;
- NYHA class III/IV;
- previous commissurotomy; and
- atrial fibrillation.<sup>(5,7)</sup>

Echocardiographic evaluation of the mitral valve is essential for correct patient selection. A number of scoring systems have been developed to improve patient selection. The morphology of the subvalvular apparatus, the presence of commissural fusion and the presence of calcification are included in most scoring systems. A well validated example is the Massachusetts General Hospital Score.<sup>(8)</sup> A score of  $<9$  in association with no more than mild MR, is associated with a good short term outcome following the procedure.<sup>(9,10)</sup>

The following clinical settings are of interest:

## Pregnancy

Mitral stenosis is a relatively common valve lesion in young pregnant South Africans and is poorly tolerated during the second and third trimester of gestation and during labour. Ideally, pregnancy should be postponed until after treatment of the valve lesion and planned in conjunction with the patient's cardiologist. In South Africa, however, patients are frequently only seen in their mid- or last trimester with severe MS. In pregnancy, a valve area below  $1.5\text{cm}^2$  is haemodynamically signi-

ficant<sup>(11)</sup> and intervention should be considered. If the valve morphology is favourable, balloon valvotomy is performed in the mid trimester when the risk of radiation to the foetus is acceptable, provided the patient's abdomen is shielded during the procedure. In a report by Sivadasanpillai, the procedure was performed successfully in 35/36 patients with no foetal or maternal mortality. Fluoroscopy time was less than 6 minutes in 31/36 of these cases.<sup>(12)</sup> The risk during open valve replacement is low for the mother but there was a 40% fetal loss following open valve replacement in a study at our institution.<sup>(13)</sup> Combining Caesarian section and valve replacement surgery is no longer considered a safe option at Tygerberg Hospital due to concern regarding a high risk of maternal infective endocarditis. We have also shown that BMV can be performed safely during pregnancy in a study of 29 pregnant (and 29 female controls) patients. The procedure was successful in 97% of cases and the complications comparable to the non-pregnant group.<sup>(14)</sup> For these reasons, we consider BMV in selected cases with less favourable valvular morphology. The development of MR post BMV remains a risk but MR is better tolerated in pregnancy than MS and can then be treated by valve replacement surgery post partum.

## Thrombus in left atrium

The American Heart Association / American College of Cardiologists' guidelines for BMV require the absence of a thrombus in the left atrium (LA) because of the risk of embolisation.<sup>(15)</sup> Trans-oesophageal echo (TEE) is more sensitive than transthoracic echo to screen patients for the presence a LA thrombus. Risk factors for the presence of thrombus includes older age, atrial fibrillation, LA size and smaller valve area.<sup>(16)</sup> Patients in whom a thrombus is detected receive anti-coagulation therapy for 3 months. BMV can be performed safely once the thrombus has been resolved.<sup>(17)</sup> BMV is not performed in cases where the thrombus has not resolved after 3 months of anti-coagulation therapy, unless the patient is a poor surgical candidate. In a study of 313 patients, Shaw et al. found that thrombus limited to the LA appendage (and not protruding from the mouth of the appendage) was not associated with embolic events during BMV. Such cases at Tygerberg Hospital would be considered for BMV in patients who are poor surgical candidates on an individual basis. The presence of a

thrombus anywhere else in the LA is an absolute contraindication to performing BMV and was supported by Shaw et al.'s study.<sup>(16)</sup>

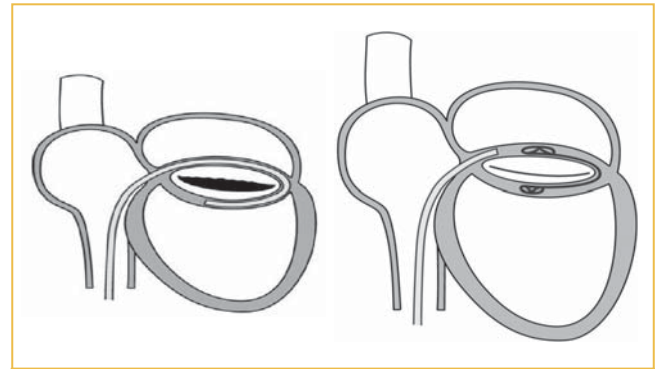
**MITRAL INCOMPETENCE**

Mitral valve prolapse (MVP) is the major indication for mitral valve surgery in developed countries, but in South Africa it remains a comparatively much less common indication. Mitral valve repair surgery is, however, performed in combination with coronary artery bypass grafting in patients with ischaemic mitral incompetence (MI). A percutaneous repair procedure is inappropriate in the latter setting, as the patient already requires open heart surgery. Surgical mitral valve repair for prolapse pathology is an effective procedure and any percutaneous alternative would have to compete with a surgical procedure with a very good track record.<sup>(18)</sup>

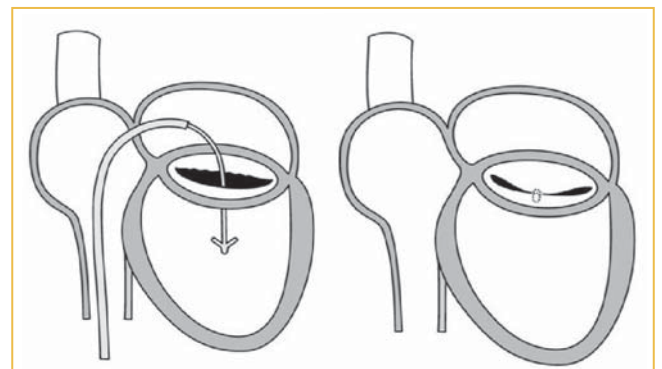
The attempts at percutaneous repair of mitral valve incompetence have focused on attempting to mimic the following two surgical techniques: mitral valve annuloplasty and edge-to-edge repair (so called Alfieri stitch), neither of which addresses the true mechanism of MR. To date none of these devices have received FDA approval for use outside of an investigational setting.

**Mitral valve annuloplasty**

The close anatomical relationship between the coronary sinus (CS) and the posterior mitral valve annulus (MVA), presents an apparently obvious approach to percutaneously intervene on the annulus. Patient selection for this procedure involves patients with MI and a dilated annulus. Several devices are under development at present. Most have a design where the device is anchored proximally and distally in the coronary sinus and tension is then applied between the two anchors to reduce the diameter of the annulus (Figure 1). Failure to maintain this tension has resulted in mechanical failure in a number of cases. In addition this approach has been hampered by the close proximity of the circumflex artery to the coronary sinus. Tops found that in 68% of cases scanned with computer tomography, the circumflex artery coursed between the CS and the MVA.<sup>(19)</sup> Post mortem data showing that the CS is often not at the same level as the mitral valve annulus further reduces the appeal of



**FIGURE 1:** Diagrammatic representation of a coronary sinus percutaneous mitral annuloplasty device. On the left is the catheter based device being inserted into the coronary sinus and on the right it is after deployment.



**FIGURE 2:** Diagrammatic representation of the Evalve Mitraclip™ device for treatment of mitral valve prolapse.

this technique.<sup>(20)</sup> Therefore, these devices have to date been tested mostly in animals. The multi-centre COMPETENT trial is currently enrolling humans for the insertion of the CARILLON™ Mitral Contour System™ (Cardiac Dimensions, Kirkland, WA.).

**Edge-to-edge repair**

Since Alfieri introduced this surgical technique in 1991, a great deal of experience has been gained and in their hands up to 95% of patients do not require repeat surgery at 4 years. Edge-to-edge repair involves suturing the central portion of the two mitral valve leaflets together to create a double orifice. This prevents prolapse of the one leaflet and does not impair diastolic filling.<sup>(21)</sup> To date the Evalve Mitraclip™ (Evalve Inc., Menlo Park, CA) system has the most data and experience of the percutaneous techniques that evolved from Alfieri's surgical

technique. The device consists of a surgical alloy clip covered with a biocompatible fabric that is attached to a delivery catheter. The catheter is positioned above the mitral valve via a transseptal puncture, passed over the valve orifice and then pulled back and closed to grasp the central portions of both leaflets, creating a double orifice mitral valve (Figure 2). More recently, a second clip has been deployed if required. The guide catheter diameter is 24F at the skin entry and 22F at the inter-atrial septum. The Evalve Mitraclip™ device was tested in the EVEREST I trial (a multi-centre feasibility trial) where clips were implanted in 24 patients. One month post procedure only 18 patients were free from surgery, but successful results were maintained at six months post procedure.<sup>(22)</sup> The much larger multi-centre EVEREST II trial planned to complete enrollment by the end of 2008.

The following factors could limit the future use of the above mentioned devices:

- The complexity of the procedure and small number of referral centers with experience in performing the procedure.
- It will be difficult for the percutaneous procedures to match the excellent surgical results with up to 30 year follow-up data.
- The regulatory approval of the devices may take too long.
- An isolated edge-to-edge repair is unlikely to be sufficient in patients with annulus dilatation, which represents 90% of cases currently referred for surgery to the Alfieri group.<sup>(21)</sup>

This rather pessimistic view must be tempered by the fact that, as opposed to percutaneous aortic valve replacement (where patients are non-surgical candidates), the procedure can be offered to relatively healthy individuals. In cases where the procedure is unsuccessful, the clip can be explanted during an open repair procedure. The procedure may eventually be considered at an earlier stage to prevent the progression to left ventricular dysfunction. Although the device is registered in the US as an Investigational Device only, it received CE registration in 2008.

### **PERCUTANEOUSLY INSERTABLE MITRAL VALVE**

No percutaneous mitral valve replacements have been performed in humans to date. Most experts agree that due to the complex

structure and function of the mitral valve, medical science is still years away from achieving success with this procedure.

Bonhoeffer developed a percutaneous tricuspid valve consisting of 2 discs (similar to an ASD closure device) which he implanted in seven ewes. Though successful, the stresses on this valve are by no means comparable to the left heart. Bonhoeffer postulated that a possible alternative approach is to initially surgically replace the valve with a prosthesis that is designed to function as a docking station for future percutaneous replacements. Bonhoeffer has tested his theory by surgically replacing mitral valves in sheep and then inserting a valved stent off-pump via the left atrium.<sup>(23)</sup> The procedure is currently not suitable for application in humans, but the concept may prove useful in future.

### **AORTIC STENOSIS**

Isolated AS is typically due to degenerative changes or to congenital bicuspid aortic valve deformities. Many patients are elderly with a multitude of co-morbid conditions that increases the risk of open heart surgery. In Europe, up to one third of potential candidates are consequently not offered valve surgery. This is in spite of numerous advances and excellent long term results in aortic valve replacement surgery.<sup>(24)</sup>

Balloon valvotomy has been the initial procedure in percutaneous aortic valve interventions. This procedure has been unsuccessful due to a high rate of acute embolisation resulting in stroke and a high re-stenosis rate at short term (six months) follow-up.<sup>(25)</sup>

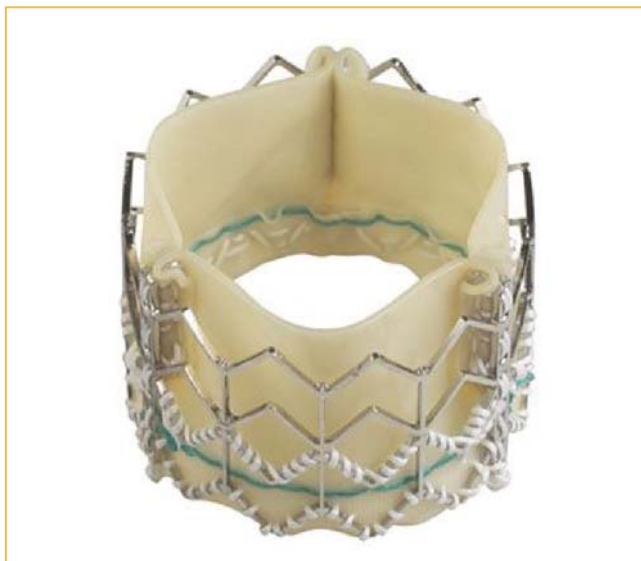Transcatheter aortic valve implantation (TAVI) experiments were first published in 1992.<sup>(26)</sup> Bonhoeffer implanted a bovine jugular vein valve that was sutured onto a stent in the descending aorta of lambs in 2002.<sup>(27)</sup> Inserting a stented valve in the sub coronary position without obstructing the coronary ostia has proven difficult in animal studies.<sup>(28)</sup> In humans, however, the rim of calcified tissue between the valve and the aortic wall probably acts as a barrier, preventing coronary obstruction. Since Alain Cribier's first human implantation in 2002, this field has experienced exponential growth with an estimated 2 000 implantations worldwide reported at EuroPCR08. Most of the current designs incorporate an expandable metal stent with a tissue valve sewn into it. Alternatives include inflatable

anchorage (which can also be deflated and repositioned) (Direct Flow Medical™, Santa Rosa, CA) and a foldable, sheet metal stent (AorTx™, CA). A variety of tissues have been tested and bovine or porcine pericardium is used in the majority of cases. Synthetic valve cusps under development include polymers and flexible metal (eNitinol utilising nanotechnology). Two major approaches are used with metal stents: balloon expandable or self expanding Nitinol stents. It is important to note that no valve has been approved by the FDA for use in humans, other than in an investigational setting.

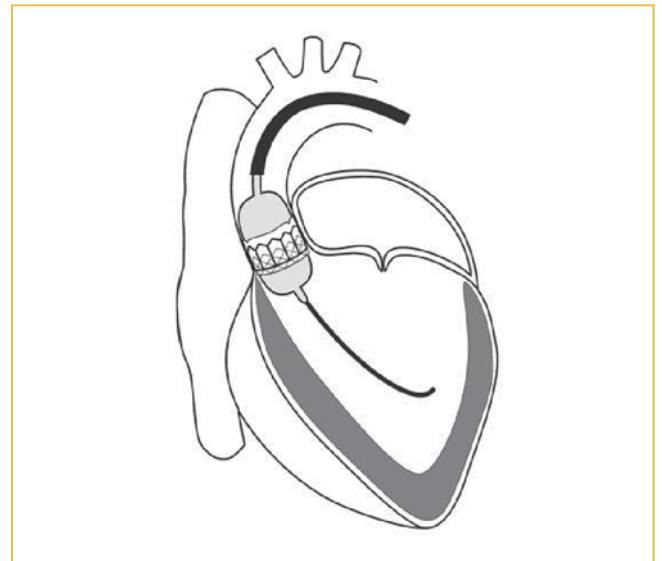
Numerous groups have described experience in animals and Grube recently published the first implantation of the Sadra Medical Lotus valve™.<sup>(29)</sup> This discussion will however focus on the designs with the most human experience.

### SAPIEN VALVE

The Cribier-Edwards™ valve (Figure 3) and its updated version, the Edwards-SAPIEN valve™ (Edwards Lifesciences™, Irvine CA) is based on Cribier's design for the first human implantation. The initial approach was pro-grade (via venous access and transseptal puncture) to aid in crossing the aortic valve. A major complication of this technique is that with traction, the catheter acts like a cheese cutter and can tear the anterior



**FIGURE 3:** The Cribier –Edwards™ valve. (Used with permission: Edwards Lifesciences™, California, USA)



**FIGURE 4:** Diagram illustrating deployment of a balloon expandable valve in the aortic position

mitral valve leaflet as well as the inter atrial septum.<sup>(4)</sup> More recent procedures have been performed via a femoral arterial puncture and insertion of a 24F sheath, with femoral artery diameter of 7-8mm as a prerequisite (depending on the size of the valve). As these patients tend to be elderly with frequent peripheral vascular disease, problematic access is an important contra-indication to this approach.

The procedure may be performed under local anesthesia, but many experts prefer general anesthesia to enable transesophageal echo monitoring. Balloon valvuloplasty is performed initially, which is similar to the procedure followed during Core-Valve implantation. The crimped valve is then passed through the aorta to the native annulus with a steerable guiding catheter (Figure 4). Final position of the valve is confirmed by fluoroscopy, aortography, and where used, TEE.<sup>(30)</sup> To attain a stable position in the native aortic valve orifice, the patients are paced at a rate of 180-220 bpm (and the systolic blood pressure falls to below 60 mmHg) prior to deployment of the valve. Most groups could demonstrate a steep learning curve but immediate success rates have also increased due to refinement of the delivery system.<sup>(31,32)</sup>

The trans-apical approach is used in patients with inaccessible femoral arteries. A small antero-lateral thoracotomy is performed

under general anaesthesia. The apex of the left ventricle is identified and punctured with an arterial needle and a standard sheath is placed over the wire into the left ventricle through which the valve is deployed. Valve positioning may be easier than the transarterial route. The apex is surgically closed with pledgeted sutures and a chest tube placed.<sup>(33)</sup> To date this approach is only approved for the SAPIEN valve.

### Clinical experience

The experience with the Sapien valve (and most others) has been exclusively in patients turned down for open valve replacement surgery. Cribier published a series of 27 patients with a 75% acute procedural success rate and immediate improvement in hemodynamic parameters in all successful cases. Two of the acute failures were due to valve migration. Significant paravalvular aortic regurgitation (AR) was seen in 17 patients. At 30 days after implantation, 26% of patients had major adverse events (pericardial tamponade, stroke, and arrhythmia). At nine months after implantation only 11 patients were still alive but the majority of deaths were due to their comorbid conditions.<sup>(34)</sup>

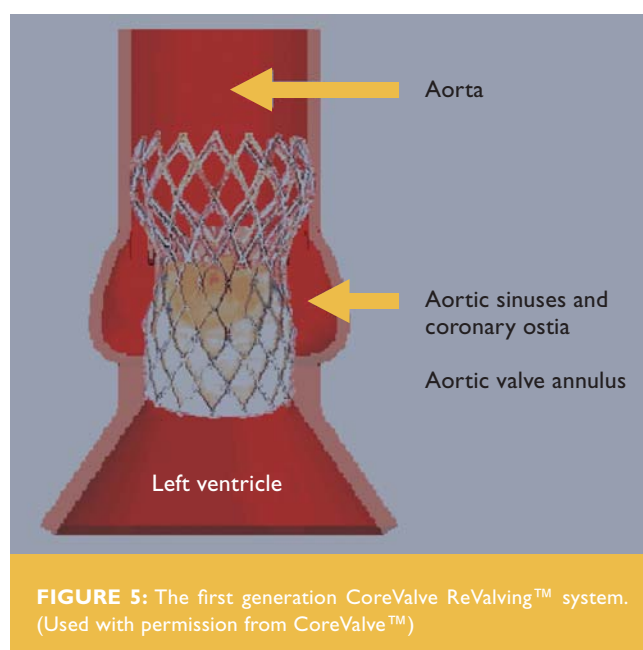
Webb published a series of 50 patients with an average Euro SCORE predicted mortality risk of 28%. At 30 days, their mortality was 16% for the initial 25 cases but decreased to 8% for the remaining 25. Procedural success increased from 76% for the initial 25 cases to 96% for the last 25. The median hospital stay was 5 days. Significant improvements were demonstrated in valve area (from  $0.6 \pm 0.2$  cm<sup>2</sup> to  $1.7 \pm 0.4$  cm<sup>2</sup>), LV ejection fraction (from  $53 \pm 15\%$  to  $57 \pm 13\%$ ), mitral regurgitation grade (from 2 to 1) and functional class. Improvement was maintained at one year. Two patients suffered strokes during the procedure.<sup>(32)</sup> More recently they have also reported no evidence of structural valve deterioration beyond 2 years.<sup>(30)</sup> In the data presented by Martin Leon at EuroPCR 07, the average logistic Euro SCORE was 33% but in the 55 patients treated in the REVIVAL II study, 6 month mortality was only 16% (unpublished data).

With the trans-apical approach, Webb et al. described their first seven cases with 6/7 patients alive at 3 months and significant haemodynamic improvement in all patients.<sup>(35)</sup> In the largest published series of 59 cases with an average Euro SCORE predicted risk of  $27 \pm 14\%$ , Walther et al. demonstrated a 13%

in-hospital mortality. Valve positioning was performed successfully in 53 patients. Four patients required early conversion to sternotomy and mild AR was present in 25% of cases.<sup>(36)</sup> Although it was initially thought that this approach would lead to lower risk of peri-procedural stroke, both approaches have a similar published stroke rate of  $\pm 4\%$ .<sup>(37,38)</sup>

### COREVALVE REVALVING SYSTEM™

The first percutaneous aortic valve replacement with a self expanding valve was published by Grube in 2005.<sup>(39)</sup> The major advantage of these valves is their smaller profile (the third generation Core Valve™ has a delivery sheath diameter of only F18) and a smaller incidence of post-procedural AR (mean grade of AR improved and deterioration in AR in only 5/25 patients).<sup>(40)</sup> The prosthesis is, however, much longer than the Edwards-SAPIEN valve™ (50mm vs. 16mm), stretching from the LVOT, over the valve and aortic annulus, into the ascending aorta (Figure 5 and 6). Another disadvantage, due to the longer time required for deployment of the valve, is that the patients were initially all put on percutaneous cardio pulmonary bypass. More recently this procedure has been performed successfully off-pump. In their follow-up study of 86 patients, Grube et al. included 36 cases using the 18F valve. In 64% of these, they could deploy the valve without hemo-



**FIGURE 5:** The first generation CoreValve ReValving™ system. (Used with permission from CoreValve™)



**FIGURE 6:** Current third generation CoreValve™ (Used with permission from CoreValve™)

dynamic support, cutting down on procedure time and cost. In 25% of cases the procedure was performed with only local anesthesia to the groin and in most an arterial closure device was used.<sup>(41)</sup>

### Clinical experience

In the most experienced centre, acute device success was 88% with 6 devices misplaced and 2 cases where the device would not cross the native valve. Overall 30-day mortality was 12% (mean logistic Euro SCORE was 23%).<sup>(41)</sup> Grube have now published their experience with all three generations of this device in 136 patients and demonstrated a 30-day combined rate of death/stroke/myocardial infarction for generation 1, 2, and 3 of 40.0%/20.8%/14.7% (P=0.11), with no procedural deaths in generation 3. Implantation success was 92% for the third generation device.<sup>(42)</sup>

Despite receiving CE approval recently, the CoreValve ReValving™ system has not been released onto the market but is proceeding with an expanded clinical evaluation and is not available in the USA.

### Patient selection for TAVI

Patient selection remains crucial but is very difficult. It is recommended that a multi-disciplinary team of cardiologists,

surgeons, imaging specialists and anaesthetists assess each patient individually. To date, the procedure is only done in patients with severe symptomatic AS who are turned down for open heart valve replacement surgery (and this should be the first step in the evaluation). Risk scores, such as the Euro SCORE<sup>(43)</sup> and the STS Predicted Risk of Mortality score<sup>(44)</sup> are useful. They do, however, share similar limitations. Predictive ability is reduced in these high-risk patients and some have shown that the Euro SCORE in particular tends to overestimate risk.<sup>(45,46)</sup> Imaging should include echocardiography and angiography of the coronary, aortic root and ilio-femoral arteries. CT-angiography is recommended in addition to echocardiography to evaluate the above structures, and for assessing the possibility of obstruction of the left main coronary artery.<sup>(30)</sup>

General contraindications for TAVI<sup>(47)</sup> include:

- Aortic annulus < 18 or >25 mm for balloon-expandable and <20 or >27 for self-expandable devices;
- Bicuspid valves due to the risk of incomplete deployment of the prosthesis;
- Presence of asymmetric heavy valvular calcification, which may compress the coronary arteries during TAVI; and
- Aortic root dimension > 45 mm at the sino-tubular junction for self-expandable prostheses.
- Presence of apical LV thrombus.

Contra-indications for the trans-femoral approach<sup>(47)</sup> include:

- Iliac arteries: severe calcification, tortuosity, small diameter (<6 to 9 mm according to the device used) and previous aorto-femoral bypass;
- Aorta: severe angulation, severe atheroma of the arch, coarctation and aneurysm of the abdominal aorta with protruding mural thrombus;
- Presence of bulky atherosclerosis of the ascending aorta and aortic arch; and
- A transverse position of the ascending aorta (balloon-expandable device).

## Limitations

A large number of AS patients in South Africa have rheumatic involvement of the valve which is associated with mitral valve disease in the vast majority. The use of these new percutaneous procedures will therefore probably be limited to patients with senile degeneration of their aortic valves.

These devices were developed for AS and their experience in patients with predominant AR is limited.<sup>(48)</sup> Paravalvular AR has been reported in most series<sup>(4,33,42,49)</sup> but with routine oversizing and accurate placement of the device the majority of leaks are mild and well tolerated. In vitro valve testing anticipates durability comparable to many conventional bio-prostheses.<sup>(30)</sup> Although structural valve deterioration has not been reported, limited late follow-up data is available.<sup>(31,38,42)</sup> Survival without structural failure has been reported for up to 4 years.<sup>(51)</sup>

Open surgery has an excellent track record with decades of follow up. No data exists to compare open surgery to TAVI in high risk patients. A joint statement by the ACC, AHA, STS, AATS and SCAI was published to outline how studies to address this question should be designed and controlled.<sup>(52)</sup> The published results come from large volume centers where considerable effort and funds have been invested to set up the procedure team. It is uncertain if this will be reproduced in lower volume centers.

Once these valves have been tested for longer periods and become commercially available, the exact role in our country will possibly depend on a number of factors:

- **Training for the procedure:** Local interventionists will have to undergo accredited training and probably spend time in an accredited centre abroad. These training posts are likely to be extremely competitive.
- **Patient selection:** This technology provides hope for a group of patients who previously had no treatment options. The potential for abuse/inappropriate use is, however, real and methods to curb this is not in place in South Africa. It is encouraging to see that in Europe, industry is playing a

leading role in the regulation of the use of their devices. One can only hope that a similar approach will be followed here.

- **Cost:** The development of percutaneous heart valves has been a long and expensive process and the cost of these valves could be prohibitively high for the majority of South Africans.
- **Cooperation between cardiologists and surgeons** is crucial for the selection of ideal patients and technically this is a new field for all involved. Surgeons have superior experience in valvular interventions and arterial cut downs, and cardiologists are experienced in catheter manipulation and balloon/stent management.

## PULMONARY VALVE REPLACEMENT

Right ventricular outflow tract (RVOT) reconstruction forms an important part of surgical correction for a wide variety of congenital cardiac abnormalities – most notably Tetralogy of Fallot and arterial switch procedures. This procedure often improves the haemodynamic situation dramatically despite residual pulmonary valve regurgitation (PR) or RVOT obstruction. These two residual lesions were long thought to be benign, but recent data has shown that they may lead to right ventricular dysfunction and malignant arrhythmia.<sup>(53,54)</sup> The treatment options for these lesions include homograft implantation, balloon dilatation and stenting of the RVOT. The longevity of the first two procedures in particular is limited by calcific degeneration resulting in re-stenosis and frequent re-intervention.<sup>(55)</sup>

Since Bonhoeffer's first percutaneous pulmonary valve implantation (PPVI) in 2000, his group has performed well over a 100 of these procedures (personal communication). They have shown that PPVI improves bi-ventricular performance (as measured by tissue Doppler, MRI) as well as exercise tolerance and symptoms.<sup>(56)</sup> They have also reported extensive data on 59 patients with 9.8 (+/- 1.4) months follow-up.<sup>(57)</sup> Of the 59 patients, 61% had previous Tetralogy of Fallot repairs and 78% had a homograft conduit in the RVOT. Only 3 patients had a procedure in a native RVOT. Most haemodynamic parameters



improved significantly (RVOT gradient, PA pressures, RV stroke volume) and no patient had more than mild regurgitation post procedurally. Complications were classified into 3 categories:

1. Complications related to balloon dilatation (dissection, haemorrhage or conduit rupture and residual stenosis) – fortunately very rare.
2. Patient selection – patients had varied RVOT anatomies and, for regurgitant lesions, dislodgement was a problem. More recent imaging modalities will reduce this complication.
3. Device design – stent fracture and acute in-stent stenosis due to protrusion of the vessel wall lead to modifications of the design which should reduce these problems.

Despite the above problems, there were no fatalities and in a number of patients, complications could be managed by deploying a second valve within the faulty one.

The patent for this design was acquired by the Medtronic™ Corporation who launched it as the Melody™ Transcatheter Pulmonary valve. Although not available for sale in the USA at the time of this review, it has received the CE Mark approval for distribution in Europe. According to the package insert, intended lifetime of this device is 2 years.

One can conclude that the future is (almost) here, but that South Africans would probably have to wait a bit longer. Issues that need to be addressed are cost, adequate training and regulation.

**ACKNOWLEDGEMENT**

We would like to express our thanks to Professor Lesley Burgess for her critical review of the manuscript.

**REFERENCES**

1. Ruiz CE. Transcatheter aortic valve implantation and mitral valve repair: state of the art. *Pediatr Cardiol* 2005 May;26(3):289-94.
2. Gene HS. Rheumatic fever. *The Lancet* 1997 March 29;349(9056):935.
3. Bonhoeffer P, Boudjemline Y, Qureshi SA, et al. Percutaneous insertion of the pulmonary valve. *Journal of the American College of Cardiology* 2002 May 15;39(10 (Print)):1664-9.
4. Cribier A, Eltchaninoff H, Tron C. First human transcatheter implantation of an aortic valve prosthesis in a case of severe calcific aortic stenosis. *Ann Cardiol Angeiol (Paris)* 2003 June;52(3):173-5.
5. Lung B, Garbarz E, Michaud P, et al. Late results of percutaneous mitral commissurotomy in a series of 1024 patients. Analysis of late clinical deterioration: frequency, anatomic findings and predictive factors. *Circulation* 1999 June 29;99(25):3272-8.
6. Palacios IF, Sanchez PL, Harrell LC, et al. Which patients benefit from percutaneous mitral balloon valvuloplasty? Prevalvuloplasty and postvalvuloplasty variables that predict long-term outcome. *Circulation* 2002 March 26;105(12):1465-71.
7. Prendergast BD, Shaw TR, Lung B, et al. Contemporary criteria for the selection of patients for percutaneous balloon mitral valvuloplasty. *Heart* 2002 May; 87(5):401-4.
8. Wilkins GT, Weyman AE, Abascal VM, et al. Percutaneous balloon dilatation of the mitral valve: an analysis of echocardiographic variables related to outcome and the mechanism of dilatation. *Br Heart J* 1988 October;60(4):299-308.
9. Abascal VM, Wilkins GT, Choong CY, et al. Echocardiographic evaluation of mitral valve structure and function in patients followed for at least 6 months after percutaneous balloon mitral valvuloplasty. *J Am Coll Cardiol* 1988 September;12(3):606-15.
10. Abascal VM, Wilkins GT, O'Shea JP, et al. Prediction of successful outcome in 130 patients undergoing percutaneous balloon mitral valvotomy. *Circulation* 1990 August 1;82(2):448-56.
11. Task FM, Vahanian A, Baumgartner H, et al. Guidelines on the management of valvular heart disease: The Task Force on the Management of Valvular Heart Disease of the European Society of Cardiology. *European Heart Journal* 2007 January 2;28(2):230-68.
12. Sivadasanpillai H, Srinivasan A, Sivasubramoniam S, et al. Long-term outcome of patients undergoing balloon mitral valvotomy in pregnancy. *Am J Cardiol* 2005 June 15;95(12):1504-6.
13. Hall DR, Olivier J, Rossouw GJ, et al. Pregnancy outcome in women with prosthetic heart valves. *Journal of Obstetrics and Gynaecology: The Journal of The Institute of Obstetrics and Gynaecology*. 2001 March;21(2):149-53.
14. Lalla U. Percutaneous balloon mitral valvuloplasty (PBMV) in pregnancy at Tygerberg Hospital, Cape Town, South Africa: a 10-year retrospective audit. 2008 September.
15. Bonow R, Carabello B, de Leon J, et al. ACC/AHA guidelines for the management of patients with valvular heart disease: A report of the American College of Cardiology/American Heart Association Task Force on practice guidelines (Committee on management of patients with valvular heart disease). *Journal of the American College of Cardiology* 1998 November 1;32(5):1486-582.
16. Shaw TR, Northridge DB, Sutaria N. Mitral balloon valvotomy and left atrial thrombus. *Heart* 2005 August;91(8):1088-9.
17. Kang DH, Song JK, Chae JK, et al. Comparison of outcomes of percutaneous mitral valvuloplasty versus mitral valve replacement after resolution of left atrial appendage thrombi by Warfarin therapy. *Am J Cardiol* 1998 January 1;81(1): 97-100.
18. Braunberger E, Deloche A, Berrebi A, et al. Very long-term results (more than 20 years) of valve repair with carpentier's techniques in non-rheumatic mitral valve insufficiency. *Circulation* 2001 September 18;104(12 Suppl 1):I8-11.
19. Tops LF, Van de Veire NR, Schuijf JD, et al. Non-invasive evaluation of coronary sinus anatomy and its relation to the mitral valve annulus: implications for percutaneous mitral annuloplasty. *Circulation* 2007 March 20;115(11):1426-32.
20. Maselli D, Guaraccino F, Chiaramonti F, et al. Percutaneous mitral annuloplasty: an anatomic study of human coronary sinus and its relation with mitral valve annulus and coronary arteries. *Circulation* 2006 August 1;114(5):377-80.
21. Alfieri O, Maisano F, Colombo A. Future of transcatheter repair of the mitral valve. *The American Journal of Cardiology* 2005 December 19;96(12A):71L-5L.

22. Feldman T, Wasserman HS, Herrmann HC, et al. Percutaneous mitral valve repair using the edge-to-edge technique: six-month results of the EVEREST Phase I Clinical Trial. *Journal of the American College of Cardiology* 2005 December 6;46(11):2134-40.
23. Boudjemline Y, Pineau E, Borenstein N, et al. New insights in minimally invasive valve replacement: description of a cooperative approach for the off-pump replacement of mitral valves. *Eur Heart J* 2005 October;26(19):2013-7.
24. Lung B, Cachier A, Baron G, et al. Decision-making in elderly patients with severe aortic stenosis: why are so many denied surgery? *Eur Heart J* 2005 December;26(24):2714-20.
25. Cribier A, Jolly N, Letac B. The role of balloon aortic valvuloplasty in current practice. *Coronary Artery Disease* 1993 October;4(10 (Print)):943-6.
26. Andersen HR, Knudsen LL, Hasenkam JM. Transluminal implantation of artificial heart valves. Description of a new expandable aortic valve and initial results with implantation by catheter technique in closed chest pigs. *European Heart Journal* 1992 May 1;13(5):704-8.
27. Boudjemline Y, Bonhoeffer P. Steps toward percutaneous aortic valve replacement. *Circulation* 2002 February 12;105(6):775-8.
28. Vahanian A, Palacios I. Percutaneous approaches to valvular disease. *Circulation* 2004;109:1572-9.
29. Buellesfeld L, Gerckens U, Grube E. Percutaneous implantation of the first repositionable aortic valve prosthesis in a patient with severe aortic stenosis. *Catheterization and Cardiovascular Interventions: Official Journal of the Society for Cardiac Angiography & Interventions* 2008 April 1;71(5):579-84.
30. Webb JG, Lichtenstein S. Transcatheter percutaneous and transapical aortic valve replacement. *Seminars In Thoracic and Cardiovascular Surgery* 2007; 19(4):304-10.
31. Cribier A, Eltchaninoff H, Tron C, et al. Treatment of calcific aortic stenosis with the percutaneous heart valve: mid-term follow-up from the initial feasibility studies: the French experience. *J Am Coll Cardiol* 2006 March 21;47(6):1214-23.
32. Webb JG, Pasupati S, Humphries K, et al. Percutaneous transarterial aortic valve replacement in selected high-risk patients with aortic stenosis. *Circulation* 2007 August 14;116(7):755-63.
33. Walther T, Falk V, Kempfert J, et al. Transapical minimally invasive aortic valve implantation: the initial 50 patients. *European Journal of Cardio-Thoracic Surgery: Official Journal of the European Association for Cardio-Thoracic Surgery* 2008 June 21;33(6):983-8.
34. Cribier A, Eltchaninoff H, Tron C, et al. Treatment of Calcific Aortic Stenosis With the Percutaneous Heart Valve: Mid-Term Follow-Up From the Initial Feasibility Studies: The French Experience. *Journal of the American College of Cardiology* 2006 March;47(6):1214-23.
35. Ye J, Cheung A, Lichtenstein SV, et al. Six-month outcome of transapical transcatheter aortic valve implantation in the initial seven patients. *European Journal of Cardio-Thoracic Surgery: Official Journal of the European Association for Cardio-Thoracic Surgery* 2007 January 28;31(1):16-21.
36. Walther T, Simon P, Dewey T, et al. Transapical minimally invasive aortic valve implantation: multi-center experience. *Circulation* 2007 September 11;116(11 Suppl):I240-I245.
37. Lichtenstein SV, Cheung A, Ye J, et al. Transapical transcatheter aortic valve implantation in humans: initial clinical experience. *Circulation* 2006 August 8;114(6):591-6.
38. Webb JG, Pasupati S, Humphries K, et al. Percutaneous transarterial aortic valve replacement in selected high-risk patients with aortic stenosis. *Circulation* 2007 August 14;116(7):755-63.
39. Grube E, Laborde JC, Zickmann B, et al. First report on a human percutaneous transluminal implantation of a self-expanding valve prosthesis for interventional treatment of aortic valve stenosis. *Catheterisation and Cardiovascular Interventions: Official Journal of the Society for Cardiac Angiography & Interventions* 2005 December;66(4 (Print)):465-9.
40. Grube EM, Laborde JCM, Gerckens UM, et al. Percutaneous Implantation of the CoreValve Self-Expanding Valve Prosthesis in High-Risk Patients With Aortic Valve Disease: The Siegburg First-in-Man Study. [Article]. *Circulation* 2006 October 10;114(15):1616-24.
41. Grube E, Schuler G, Buellesfeld L, et al. Percutaneous aortic valve replacement for severe aortic stenosis in high-risk patients using the second- and current third-generation self-expanding CoreValve prosthesis: device success and 30-day clinical outcome. *Journal of the American College of Cardiology* 2007 July 3;50(1):69-76.
42. Grube E, Buellesfeld L, Mueller R, et al. Progress and Current Status of Percutaneous Aortic Valve Replacement: Results of Three Device Generations of the CoreValve Revalving System. *Circulation: Cardiovascular Interventions* 2008 December 1;1(3):167-75.
43. Roques F, Nashef SAM, Michel P, et al. Risk factors and outcome in European cardiac surgery: analysis of the Euro-SCORE multi-national database of 19030 patients. *European Journal of Cardio-Thoracic Surgery* 1999 June 1;15(6): 816-23.
44. STS National Database. STS US Cardiac Surgery Database: 1997 Aortic Valve Replacement Patients: Preoperative Risk Variables. 2000. Society of Thoracic Surgeons.
45. Brown ML, Schaff HV, Sarano ME, et al. Is the European System for Cardiac Operative Risk Evaluation model valid for estimating the operative risk of patients considered for percutaneous aortic valve replacement? *The Journal of Thoracic and Cardiovascular Surgery* 2008 September 26;136(3):566-71.
46. Dewey TM, Brown D, Ryan WH, et al. Reliability of risk algorithms in predicting early and late operative outcomes in high-risk patients undergoing aortic valve replacement. *J Thorac Cardiovasc Surg* 2008 January;135(1):180-7.
47. Vahanian A, Alfieri OR, Al-Attar N, et al. Transcatheter valve implantation for patients with aortic stenosis: a position statement from the European Association of Cardio-Thoracic Surgery (EACTS) and the European Society of Cardiology (ESC), in collaboration with the European Association of Percutaneous Cardiovascular Interventions (EAPCI). *Eur J Cardiothorac Surg* 2008 July;34(1):1-8.
48. Ruiz CE, Laborde JC, Condado JF, et al. First percutaneous transcatheter aortic valve-in-valve implant with three-year follow-up. *Catheterization and Cardiovascular Interventions: Official Journal of the Society for Cardiac Angiography & Interventions* 2008 August 1;72(2):143-8.
49. Webb JG, Chandavimol M, Thompson CR, et al. Percutaneous aortic valve implantation retrograde from the femoral artery. *Circulation* 2006 February 14;113(6):842-50.
50. Webb JG, Lichtenstein S. Transcatheter percutaneous and transapical aortic valve replacement. *Seminars In Thoracic and Cardiovascular Surgery* 2007; 19(4):304-10.
51. Cribier A, Eltchaninoff H, Tron C, et al. Percutaneous Implantation of Aortic Valve Prosthesis in Patients with Calcific Aortic Stenosis: Technical Advances, Clinical Results and Future Strategies. *Journal of Interventional Cardiology* 2006 October 2;19:S87-S96.
52. Vassiliades TA, Jr, Block PC, Cohn LH, et al. The clinical development of percutaneous heart valve technology: a position statement of the Society of Thoracic Surgeons (STS), the American Association for Thoracic Surgery (AATS), and the Society for Cardiovascular Angiography and Interventions (SCAI) Endorsed by the American College of Cardiology Foundation (ACCF) and the American Heart Association (AHA). *Journal of the American College of Cardiology* 2005 May 3;45(9 (Print)):1554-60.
53. Carvalho JS, Shinebourne EA, Busst C, et al. Exercise capacity after complete repair of Tetralogy of Fallot: evaluation using radionuclide ventriculography. *British Heart Journal* 1992;67:470-3.
54. Michael AG, Seshadri B, Steven AW, et al. Risk factors for arrhythmia and sudden cardiac death late after repair of Tetralogy of Fallot: A multicentre study. *The Lancet* 2000 September 16;356(9234):975.
55. Dore A, Glancy DL, Somerville J. Cardiac Surgery for Grown-Up Congenital Heart Patients. *The American Journal of Cardiology* 1997;80(7):906-13.
56. Coats L, Khambadkone S, Derrick G, et al. Physiological and clinical consequences of relief of right ventricular outflow tract obstruction late after repair of congenital heart defects. *Circulation* 2006 May 2;113(17):2037-44.
57. Khambadkone S, Coats L, Taylor A, et al. Percutaneous pulmonary valve implantation in humans: results in 59 consecutive patients. *Circulation* 2005 August 23;112(8):1189-97.