

A NEW WINDOW OF OPPORTUNITY FOR TAVI

Image in cardiology

**Hellmuth Weich^{*#}, Jacques van Wyk[#], Wynand van Zyl[†]
and Vinayak Bapat[‡]**

^{*} Division of Cardiology, Department of Medicine, Tygerberg Academic Hospital & University of Stellenbosch, South Africa

[#] Panorama Mediclinic, Panorama, South Africa

[†] Vergelegen Mediclinic, Somerset West, South Africa

[‡] Guy's and St. Thomas' Hospital, London, United Kingdom

Address for correspondence:

Hellmuth Weich
Division of Cardiology
8th Floor
Tygerberg Hospital
Tygerberg
7505
South Africa

Email:

hweich@sun.ac.za

This short report features the role of multi detector computer tomography (MDCT) in imaging the ascending aorta to assess the feasibility of a transaortic access route for transcatheter placement of an Edwards SAPIEN XT™ aortic valve.

Vascular access is a frequent limitation to the insertion of transcatheter valves as the patients are usually elderly and often have peripheral vascular disease. If femoral access is not feasible, alternatives include the left subclavian route (often not favourable due to a patent left internal mammary artery graft to the left anterior descending artery) or the trans-apical approach which involves suturing and puncturing of the left ventricular wall. A question mark was recently raised over the longer term result of the trans-apical approach in the PARTNER A trial. The trial showed increased cost and decreased quality of life scores for the trans-apical approach when compared to conventional surgery (unpublished data presented at TCT 2011).

A new alternative access route utilises a direct puncture of the anterior wall of the ascending aorta. This part of the aortic wall is often free of calcification and cardiothoracic surgeons regularly use it for insertion of bypass catheters and are therefore familiar with the technique of gaining access in this area. Assessment of the feasibility of arterial access at this site should include a CT scan prior to the procedure. The image should then be optimised for the visualisation of calcification and any one of a number of software programmes may be used - in this case the programme OsiriX was used (<http://www.osirix-viewer.com/>).

Placement of the sheath requires absence of calcification in the anterior ascending aorta, approximately 6 - 8cm above the aortic annulus. Figure 1a is a 64 slice MDCT reconstruction of the proximal aorta showing essentially a porcelain aorta but an area clear of calcification in the ideal window for puncture. It is our experience that many patients have this area free of calcium despite extensive calcification elsewhere in the aorta. A minimum distance of 6 - 8cm from the annulus to the puncture site is required to allow manipulation of the Edwards SAPIEN XT™ (Edwards Lifesciences™, Irvine, California) device and delivery system.

We view this approach as an exciting development as it negates the need for surgery to the left ventricular muscle required for the trans-apical approach in patients without peripheral access. It is important to note that this procedure is currently considered "off-label" usage for the SAPIEN XT transcatheter aortic valve. Further work is required to delineate the exact role of this technique and to develop dedicated devices for this access route.

Conflict of interest: none declared.

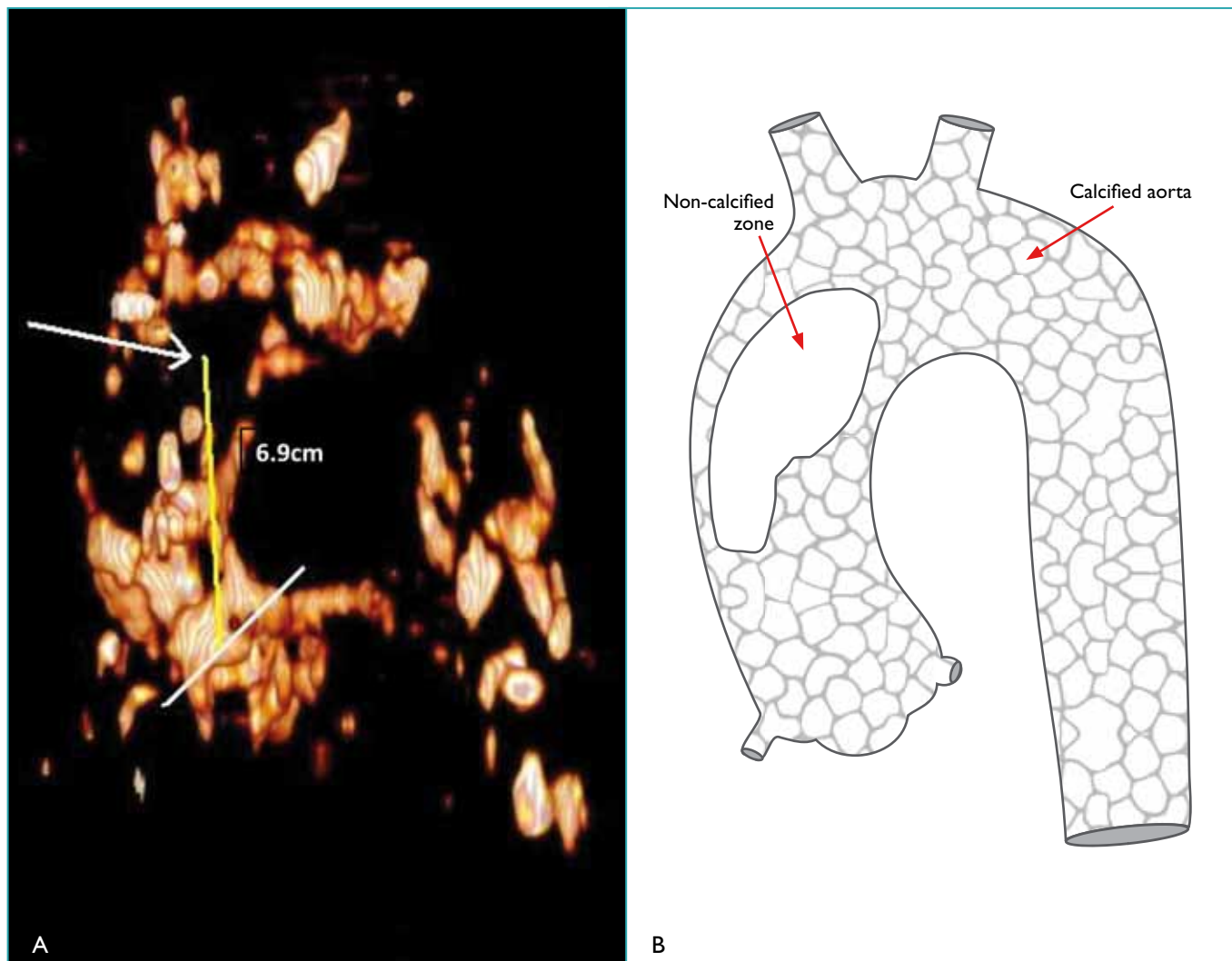


FIGURE 1: a) Volume rendered reconstruction of an uncontrasted MDCT scan (64 slice) of the ascending aorta optimised for visualisation of calcium. Note the area free of calcium (arrow) 6.9cm above the plane of the aortic annulus (white line). This is the optimal site for puncturing the aorta. b) Line diagram of the volume rendered reconstruction of the aorta shown in Figure 1a.