

ONLINE FIRST

This is a provisional PDF only. Copyedited and fully formatted version will be made available soon.



ISSN: 0015-5659

e-ISSN: 1644-3284

Vascular variations of the kidney, retrospective analysis of computed tomography images of ninety-one laparoscopic donor nephrectomies, and comparison of computed tomography images with perioperative findings

Authors: Murat Ferhat Ferhatoglu, Eray Atli, Alp Gurkan, Abut Kebudi

DOI: 10.5603/FM.a2019.0135

Article type: ORIGINAL ARTICLES

Submitted: 2019-07-10

Accepted: 2019-09-16

Published online: 2019-12-20

This article has been peer reviewed and published immediately upon acceptance. It is an open access article, which means that it can be downloaded, printed, and distributed freely, provided the work is properly cited.
Articles in "Folia Morphologica" are listed in PubMed.

Vascular variations of the kidney, retrospective analysis of computed tomography images of ninety-one laparoscopic donor nephrectomies, and comparison of computed tomography images with perioperative findings

Running title: Vascular variations of kidney

Murat Ferhat FERHATOĞLU¹, Eray ATLI², Alp GÜRKAN¹, Abut Kebudi¹

¹Department of General Surgery, Medical School of Okan University, Istanbul, Turkey

²Department of Radiodiagnostics, Medical School of Okan University, Istanbul, Turkey

Address for correspondene: Murat Ferhat Ferhatoglu, MD, Department of General Surgery, Medical School of Okan University, Istanbul, Turkey, Icmeler Mahallesi, Aydinli Yolu Cad., Aydemir Sk. No:2, 34947 Icmeler - Tuzla/Tuzla/Istanbul, tel: +905553214793, e-mail: ferhatferhatoglu@gmail.com

Abstract

Background: In this retrospective study, we aimed to determine the variations of kidney arteries and veins in kidney donor patients who underwent preoperative, computed tomography angiography.

Materials and methods: We analyzed kidney computed tomography angiography findings of ninety-one donor nephrectomy patients operated from July 2016 through December 2017. Demographics, vascular diameters, abnormalities, numbers, branching variations, routing variations of arteries, and veins were assessed according to computed tomography angiography images. We also compared the radiological findings with perioperative findings. Two radiologists evaluated computed tomography angiography images, and the same surgical team performed all donor nephrectomies by laparoscopic approach.

Results: Ninety-one of the 96 patients involved to study. Forty-six (50.5%) patients were female. Thirty-five (38.4%) of 91 cases had accessory arteries. Seven right (7.6%), one left (1.1%) and eight (8.7%) bilateral double hilar artery was observed on computed tomography angiography. No statistically significant difference was observed in the evaluation of the side

of accessory/ polar arteries ($p>0.05$), and in the evaluation of the distribution of arterial/ venous variations according to perioperative findings ($p>0.05$). However, in the evaluation of computed tomography angiography images, we found that the diameter of the kidney artery and vein differed according to gender and side.

Conclusions: The knowledge of the vascular variations of the kidney is essential for surgeons performing kidney transplantation. It is also essential for urologist and vascular surgeons. Incompatible with the literature, the right kidney has more vascular variations and, one kidney artery is found in the majority of Turkish kidney donor patients.

Key words: accessory, supernumerary, computed tomography, nephrectomy, vascular, variation, radiology, kidney transplantation

Introduction

Kidney transplantation is the gold standard treatment option for patients with end-stage kidney disease (1), and vascular variations of this organ are the most critical anatomical variations that should be entirely known by kidney transplant surgeons (2). According to traditional anatomical knowledge, one single artery originating from the abdominal part of the aorta at the second lumbar vertebral plane and supplies each kidney (3). However, the vascular net of the kidneys has many variations which are divided into two main topics: early division (prehilar branching) and extrarenal arteries. Prehilar branching is branching of the main artery of the kidney into segmental arteries before entering hilus of the kidney. Extrarenal arteries are classified into two groups: hilar arteries and polar arteries. Hilar artery enters renal hilus with the main artery, whereas polar arteries directly enter the kidney capsule outside the hilus (4). Accessory arteries of the kidney may falsely be defined radiologically or perioperatively as polar arteries constitute the most prevalent and clinically significant arterial variation of kidneys (5). The incidence of these accessory arteries varies according to sex and race (2,5). Evaluating this complex vascular net with preoperative radiological examinations protects the surgeon from many perioperative difficulties and prevents complications. Besides, the importance of imaging methods for the identification of renal vascular net has become more crucial to obtain more safety and feasibility in the era of laparoscopic surgery. Regarding the increase in the number of kidney transplantations, knowledge of the vascular variations of this organ is essential for transplantation surgeons.

In the present study, we aimed to analyze the variations of renal arteries and frequency of supernumerary renal arteries in kidney donor patients according to preoperative computed tomography angiography (CT-A) images and compare this results with perioperative findings.

Materials and methods

Inclusion criteria: The patients who underwent living kidney donor nephrectomy consequently from July 2016 through December 2017 at Istanbul Okan University Hospital and Research Center were enrolled in this observational cohort study.

Exclusion criteria: The patients who had CT-A at another institution, who did not want to participate in the study protocol and deceased kidney donors were excluded from the study (Figure 1).

Surgical procedure: The same two surgeons performed all surgical procedures by using the video-assisted mini-incision technique, which was described and standardized by Choi KH et al (6).

Radiologic evaluation of the individuals: Two different radiologists evaluated CT-A images of all individuals. In case of difference of opinion, CT-A images were assessed until a consensus was reached. Vascular diameters, abnormalities, numbers, branching variations, routing variations of arteries, and veins were assessed according to CT-A images. Diameters of renal arteries (primary or accessory) were measured from the origin of the aorta, the diameter of all renal veins (primary or accessory) was measured from the connection of venae cavae.

Tomography technique: Nonionic and water-soluble contrast medium were injected intravenously (1 ml per kg) at the rate of 4-5 ml/s with automatic pressure injector. CT-A was performed on a 64-slice CT scanner (Optima CT 660, General Electric Medical Systems, Milwaukee, Wisconsin, USA). The scans were obtained by tube current automodulation (80-450 mAs) with adaptive statistical iterative reconstruction (ASIR), tube voltage 120 kVp, gantry rotation time 0.6 s, detector coverage 40 mm, slice thickness 1,25 m, and pitch 1.375. Acquired contiguous axial 1.25 mm slice CT images were reformatted in the coronal and sagittal plane as well, and all images were transferred to picture archiving communication systems (PACS) for further analysis.

Ethical approval: All procedures performed in studies involving human participants were following the Helsinki declaration and its later amendments or comparable ethical standards. The study protocol was also reviewed and approved by the ethics committee of Istanbul Okan University, Istanbul (No: 104, Date: March 13, 2019).

Informed consent: All individuals gave written informed consent.

Statistical analysis: Statistical analyses were performed using the Number Cruncher Statistical System 2007 (Kaysville, Utah, USA). The study data were evaluated using descriptive statistical methods (Frequency, Rate). Qualitative data were compared using Pearson Chi-Square and Fisher–Freeman–Halton tests. $p < 0.05$ was considered to be significant.

Results

Study population: Ninety-five kidney transplants were performed over 17 months. Four kidney transplantations were cadaveric transplantations, which were excluded from the study.

Demographics: Forty-six (50.5%) patients were caucasian female, and forty-five (49.5%) were caucasian male. The mean age of the patients was 44.05 ± 13.76 in both genders, 47.8 ± 12.97 in females, 40.2 ± 13.64 in males (Table 1).

Vascular findings according to CT-A: Seventy-one (78%) cases had a single right, seventy (69%) cases had single left renal arteries. Thirty-five (38.4%) of 91 cases had accessory arteries, fourteen (15.3%) left, fifteen (16.4%) right, six (6.6%) bilateral accessory arteries were detected in CT-A and, the origins of all accessory arteries began from the aorta. Three (3.29%) right, one (1.09%) left, one (1.09%) bilateral polar arteries which entered the parenchyma of the kidney directly through the kidney capsule were identified. According to gender, no statistically significant difference was observed in terms of side of accessory and polar arteries ($p > 0.05$, $p > 0.05$; respectively) (Table 2).

Eighty-five (93.4%) cases had a single right, eighty (87.9%) cases had single left renal veins. Three of 91 (3.3%) cases had double right veins, one of 91 (1.1%) cases had triple right veins, and one (3.3%) double left renal vein was detected in CT-A. Also, eight (8.7%) left renal veins were a circumaortic route, and six (6.6%) left renal veins routed retroaortic. According to gender, no statistically significant difference was observed in terms of side of single or double veins ($p > 0.05$, $p > 0.05$; respectively) (Table 2).

The diameter of arteries and veins according to gender and side are shown in Table 3.

Perioperative vascular findings: Twenty-one right, seventy left donor nephrectomies performed laparoscopically during one- year. Twenty-one (100%) single right, sixty-one (87.14%) single left arteries were found. Also, eight (11.42%) double, one (11.42%) triple arteries were detected on the left side. Twenty (95.2%) single right, one (4.8%) double right veins were found on the right side. Also, sixty-seven (95.7%) single, three (4.3%) double

veins were located on the left side (Table 4). Perioperative vascular findings of five patients (5.5%) were different from preoperative performed CT-A and shown in Table 5.

Discussion

The variations of the kidney vascularization make the preoperative assessment of arterial and venous anatomical conditions critical. The knowledge of these vascular abnormalities, variations or origin diversities preoperatively preserves both patient and surgeon against unexpected surgical complications.

The mesonephric arteries which exist during embryological development create a vascular net named as “rete arteriosum urogenitale” and feeds kidneys, adrenal glands, and gonads. Over embryological development, all mesonephric arteries degenerate except one which creates renal arteries and supplies arterial circulation of the kidneys (7). Alterations in these embryological development process cause the creation of vascular variants or abnormalities of kidneys.

A single renal artery which takes origin from the abdominal part of the aorta at the level of the second dorsal vertebra on either side and one renal vein which routes anterior to the renal artery is found in the majority of the cases (8). The inferior positioning of right kidney creates a longer course of the artery. The right renal vein also has a shorter route which is 2-3 cm, and it joins the lateral edge of inferior vena cava. The left renal vein has a more extended course which is 6-10 cm and joins the medial side of inferior vena cava (4).

Many studies show a wide distribution in the prevalence of supernumerary renal arteries (9-76%) (4,5,9-14). A recent study published by Sosnik H revealed that renal arterial variations were prevalent in the Polish population (15). Stasikiewicz et al also observed that the incidence of multiple renal arteries was 27% (16). Stasikiewicz et al also found that the incidence of supernumerary renal arteries is more common on the right kidney. Another morphometric study of Satyapal et al (11) demonstrated that single renal arteries were more common on the right kidney. In contradistinction to Satyapal et al (11) and Stasikiewicz et al (16), Ozkan U et al (4) and Dogra A et al (7) reported single renal arteries were more common on the left kidney. Our study is compatible with the study of Ozkan U et al. and Dogra et al. The majority of the analyzed cases were African American and Indian in the study of Satyapal et al. Unlike the Satyapal et al, all cases were the caucasian race in our study. Also, according to the study of Saldarriaga et al, high frequency of supernumerary renal arteries is reported in Caucasian and African (30–40%), as opposed to Indian population (13.5%) (17). Similar to our results, Saldarriaga et al and Staśkiewicz et al did not observe

gender differences in frequency of supernumerary arteries. There may be vascular variations according to races, but further studies are needed on this topic. In any event, preoperative identification of renal arteries is crucial for a safe and feasible nephrectomy procedure. Nowadays, supernumerary renal arteries are no longer contraindication for laparoscopic donor nephrectomy procedure. However, awareness of supernumerary arteries may help to obviate possible complications (16,18).

Prehilar or double hilar branching is a standard variant in which the main artery of the kidney subdivides into segmental arteries at a more proximal level before entering the hilum of the kidney. Prehilar branching is momentous for donor nephrectomy procedure because most surgeons need at least 1.0 cm arterial length for anastomosis without stricture and good blood supply of the transplanted kidney (12). Double hilar branching was reported in many studies and ranges between 10% to 25% (13,19-21). The present study observed double hilar branching in 17.6% of cases.

The accessory arteries of the kidney mostly begin from the abdominal part of the aorta and supplies the bloodstream of the inferior and superior pole of the kidney. In the study of Kumar et al (24), the incidence of these arteries reported as 19%, and Weld et al. observed the frequency as 24.7%. In the presented study, thirty-five (38.4%) of 91 cases had accessory arteries (25).

In comparison with the perioperative findings, we found a precision rate of 94.5% with CT-A describing vascular anatomy of the transplanted kidney. Our results are compatible with the previous literature, which reports a concordance rate of 87-97% (26-33). Only five of our cases have different vascular findings on CT-A compared to perioperative findings. Platt *et al* and Del Pizzo *et al* which are the two most extensive series about this topic reported the concordance rate of 95% and 93% respectively (29,33). Although different perioperative findings do not result in catastrophic outcomes to any of our patients, we think that preoperative imaging of the kidney donor can be improved. This improvement could be accomplished by improved communication between radiologist and surgeon.

Surgeons should be careful in dissecting the fat to avoid accidental injury to these arteries; they supply a particular segment of the kidney and do not anastomose with adjacent arteries. Accidental damage of these arteries during fat dissection over the kidney leads to necrosis of a kidney segment as these arteries are end arteries and can increase the failure rate due to renal vascular thrombosis (34).

Limitations of the study

The study limitations include its retrospective nature, and the limited number of patients makes it difficult to draw firm conclusions. Also, not to evaluate small vessels that cannot be seen on CT-A or non-preserved arteries that are too small to be anastomosed by the surgeon is another critical limitation of the present study.

Conclusions

The knowledge of the vascular variations of the kidney is essential for surgeons performing kidney transplantation. Incompatible with the literature, the right kidney has more vascular variations and, one renal artery is found in the majority of Turkish kidney transplant patients. Each artery should be preserved to prevent segmental ischemia. Due to technical simplicity, left donor nephrectomy is preferred. According to this study, vascular variations are more common on the right side. So, evaluation of these vascular variations in transplant surgery is essential for preoperative surgical planning. CT-A provides useful information about vascular variations of the kidney.

Conflict of interest: The authors declare that they have no conflict of interest.

Ethical approval: All procedures performed in studies involving human participants were in accordance with the ethical standards of the institutional and/or national research committee and with the Helsinki declaration and its later amendments or comparable ethical standards.

Informed consent: Informed consent was obtained from all individual participants included in the study.

References

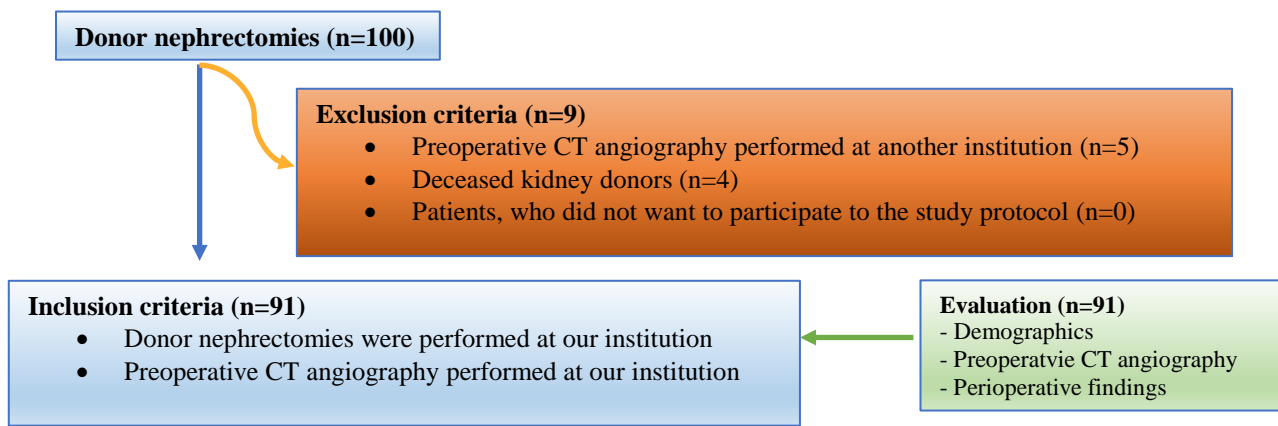
- 1- Roi SG, Mosconi G, Totti V, et al. Renal function and physical fitness after 12-month supervised training in kidney transplant recipients. *World J Transplant.* 2018; 8: 13-22, doi: 10.5500/wjt.v8.i1.13
- 2- Shakeri AB, Shane Tubbs R, Shoja MM, et al. Bipolar supernumerary renal artery. *Surg Radiol Anat.* 2007; 29: 89-92, doi:10.1007/s00276-006-0158-0
- 3- Bordei P, Sapte E, Iliescu D. Double renal arteries originating from the aorta. *Surg Radiol Anat.* 2004; 26: 474-479, doi: 10.1007/s00276-004-0272-9
- 4- Ozkan U, Oguzkurt L, Tercan F, Kızılkılıç O, Koc Z, Koca N. Renal artery origins and variations: angiographic evaluation of 855 consecutive patients. *Diagn Interv Radiol* 2006; 12: 183–186, indexed in Pubmed: 17160802

- 5- Khamanarong K, Prachaney P, Utraravichien A, Tong-Un T, Sripaoraya K. Anatomy of renal arterial supply. *Clin Anat.* 2004; 17: 334–336, doi:10.1002/ca.10236
- 6- Choi KH, Yang SC, Lee SR, et al. Standardized video- assisted retroperitoneal minilaparotomy surgery for 615 living donor nephrectomies. *Transpl Int* 2011;24:973-83, doi: 10.1111/j.1432-2277.2011.01295.x
- 7- Dogra A, Chauhan RS, Sharma S, et al. Variations of renal arteries on 64 slice Multidetector Computed Tomography. *Journal of the Anatomical Society of India* 2017; 66: 20–25, doi: 10.1016/j.jasi.2017.05.001
- 8- Jiménez R, Morant F. In: *The Importance of Venous and Renal Anomalies for Surgical Repair of Abdominal Aortic Aneurysms.* Grundmann R (Ed). Diagnosis, Screening and Treatment of Abdominal, Thoracoabdominal and Thoracic Aortic Aneurysms. United Kingdom, London InTech publishing. 2011; 269-292, doi: 10.5772/19103
- 9- Cicekbasi AEZiylan T, Salbacak A, Seker M, Buyukmumcu M, Tuncer I. An investigation of the origin, location and variations of the renal arteries in human fetuses and their clinical relevance. *Ann Anatomy.* 2005; 187: 421-427, doi: 10.1016/j.aanat.2005.04.011
- 10- Bayazit M, Göl MK, Zorlutuna Y, Tasdemir O, Bayazit K. Bilateral triple renal arteries in a patient with iliac artery occlusion: a case report *Surg. Radiol. Anat.* 1992; 14: 81-83, indexed in Pubmed: 1589852
- 11- Satyapal KS, Haffejee AA, Singh B, Ramsaroop L, Robbs JV, Kalideen JM. Additional renal arteries: incidence and morphometry *Surg. Radiol. Anat.* 2001; 23: 33-38, indexed in Pubmed: 11370140
- 12- Sampaio FJB, Passos MARF. Renal arteries: anatomic study for surgical and radiological practice *Surg. Radiol. Anat.* 1992; 14: 113-117, indexed in Pubmed: 1641734
- 13- Merklin RJ, Michels NA. The variant renal and suprarenal blood supply with data on the inferior phrenic, ureteral and gonadal arteries. *J. Int. Coll. Surg.* 1958; 29: 41-76, indexed in Pubmed: 13502578
- 14- Gurkan A, Varilsuha C, Eren S, et al. Renal transplant vericilerinin saptanmasında spiral bilgisayarlı tomografik angiografinin değeri. *Klinik ve Deneysel Cerrahi Dergisi.* 2000; 8: 190-193.

- 15- Sośnik H, Sośnik K. Renal vascularisation anomalies in the Polish population. Coexistence of arterial and venous anomalies in the vascular pedicle of the kidney. *Folia Morphol* 2019; 78: 290-296, doi: 10.5603/FM.a2018.0079.
- 16- Staśkiewicz G, Jajko K, Torres K, Czekajska-Chehab E, Maciejewski R, Drop A. Supernumerary renal vessels: analysis of frequency and configuration in 996 computed tomography studies. *Folia Morphol.* 2016; 75: 245-250, doi: 10.5603/FM.a2015.0085
- 17- Saldarriaga B, Pérez AF, Ballesteros LE. A direct anatomical study of additional renal arteries in a Colombian mestizo population. *Folia Morphol*, 2008; 67: 129–134, doi: indexed in Pubmed: 18521812
- 18- Hung CJ, Yin YJ, Chang SS, Chou TC, Lee PC. Kidney grafts with multiple renal arteries is no longer a relative contraindication with advance in surgical techniques of laparoscopic donor nephrectomy. *Transplant Proc.* 2012; 44: 36-38, doi: 10.1016/j.transproceed.2011.12.027
- 19- Saritha S, Jyothi N, Kumar PM, Supriya P. Cadaveric study of accessory renal arteries and its surgical correlation. *Int J Res Med Sci.* 2013; 1: 19-22, doi: 10.5455/2320-6012.ijrms20130205
- 20- Rao NS, Kishore K, Sujatha K, Krishna Rao HR. Extra hilar branching of renal arteries: An anatomical study. *Int J Anat Res* 2015; 3: 1568-1572. doi: 10.16965/ijar.2015.290
- 21- Goyal N, Bala A, Batra APS, Chaudhary S, Garg A, Deswal A. Variations in branching pattern of renal vessels. *Int J Sci Res.* 2017; 9: 1-3.
- 22- Majos M, Stefańczyk L, Szemraj-Rogucka Z, et al. Does the type of renal artery anatomic variant determine the diameter of the main vessel supplying a kidney? A study based on CT data with a particular focus on the presence of multiple renal arteries. *Surg Radiol Anat.* 2018 ; 40: 381–388.
- 23- Gulas E, Wyśiadecki G , Szymański J, Majos A, Stefańczyk L, Topol M, Polgaj M. Morphological and clinical aspects of the occurrence of accessory (multiple) renal arteries. *Archives of Medical Science* 2018; 12: 442–453
- 24- Kumar U, Prabha R. Study of prehilum branching pattern of renal artery in human cadaveric kidneys. *Nat J Clin Anat.* 2016; 5: 86–90.
- 25- Weld KJ, Bhayani SB, Belani J, Ames CD, Harubi G, Landman J. Extrarenal vascular anatomy of kidney: assessment of variations and their relevance to partial nephrectomy. *Urology.* 2005; 66: 985–989, doi: 10.1016/j.urology.2005.05.023

- 26- Uday D. Patil, Ashok Ragavan, Nadaraj, Keshava Murthy, Ravi Shankar, Bahar Bastani, Sudarshan H. Ballal; Helical CT angiography in evaluation of live kidney donors, *Nephrology Dialysis Transplantation*, Volume 16, Issue 9, 1 September 2001, Pages 1900–1904
- 27- Dachman AH, Newmark GM, Mitchell MT, Woodle ES. Helical CT examination of potential renal donors. *Am J Roentgenol* 1998; 171: 193–200, doi: 10.2214/ajr.171.1.9648788
- 28- Cochran ST, Krasny RM, Danovitch GM *et al.* Helical CT angiography for examination of living renal donors. *Am J Roentgenol* 1997; 168: 1569–1573, doi: 10.2214/ajr.168.6.9168727
- 29- Platt JF, Ellis JH, Korobkin M, Reige K. Helical CT evaluation of potential kidney donors, findings in 154 subjects. *Am J Roentgenol* 1997; 169: 1325–1330, doi: 10.2214/ajr.169.5.9353451
- 30- Pozniak MA, Balison DJ, Lee FT *et al.* CT angiography of potential renal transplant donors. *Radiographics* 1998; 18: 565–587, doi: 10.1148/radiographics.18.3.9599383
- 31- Slakey DP, Florman S, Lovretich J *et al.* Utility of CT angiography for evaluation of living kidney donors. *Clin Transplant* 1999; 13: 104–107, indexed in Pubmed: 10081645
- 32- Kaynan AM, Rozenlit AM, Figueroa KI *et al.* Use of spiral computerized tomography in lieu of angiography for preoperative assessment of living renal donors. *J Urol* 1999; 161: 1969–1975, doi: 10.1016/S0022-5347(05)68796-4
- 33- Del Pizzo JJ, Sklar GN, You-Cheong JW *et al.* Helical computerized tomography arteriography for evaluation of live renal donors undergoing laparoscopic nephrectomy. *J Urol* 1999; 162: 31–34
- 34- Kumar S, Neyaz Z, Gupta A. The Utility of 64 Channel Multidetector CT Angiography for Evaluating the Renal Vascular Anatomy and Possible Variations: a Pictorial Essay. *Korean J Radiol.* 2010; 11: 346-54, doi: 10.1016/10.3348/kjr.2010.11.3.346

Figure 1. Scheme of the present study



CT: Computed tomography

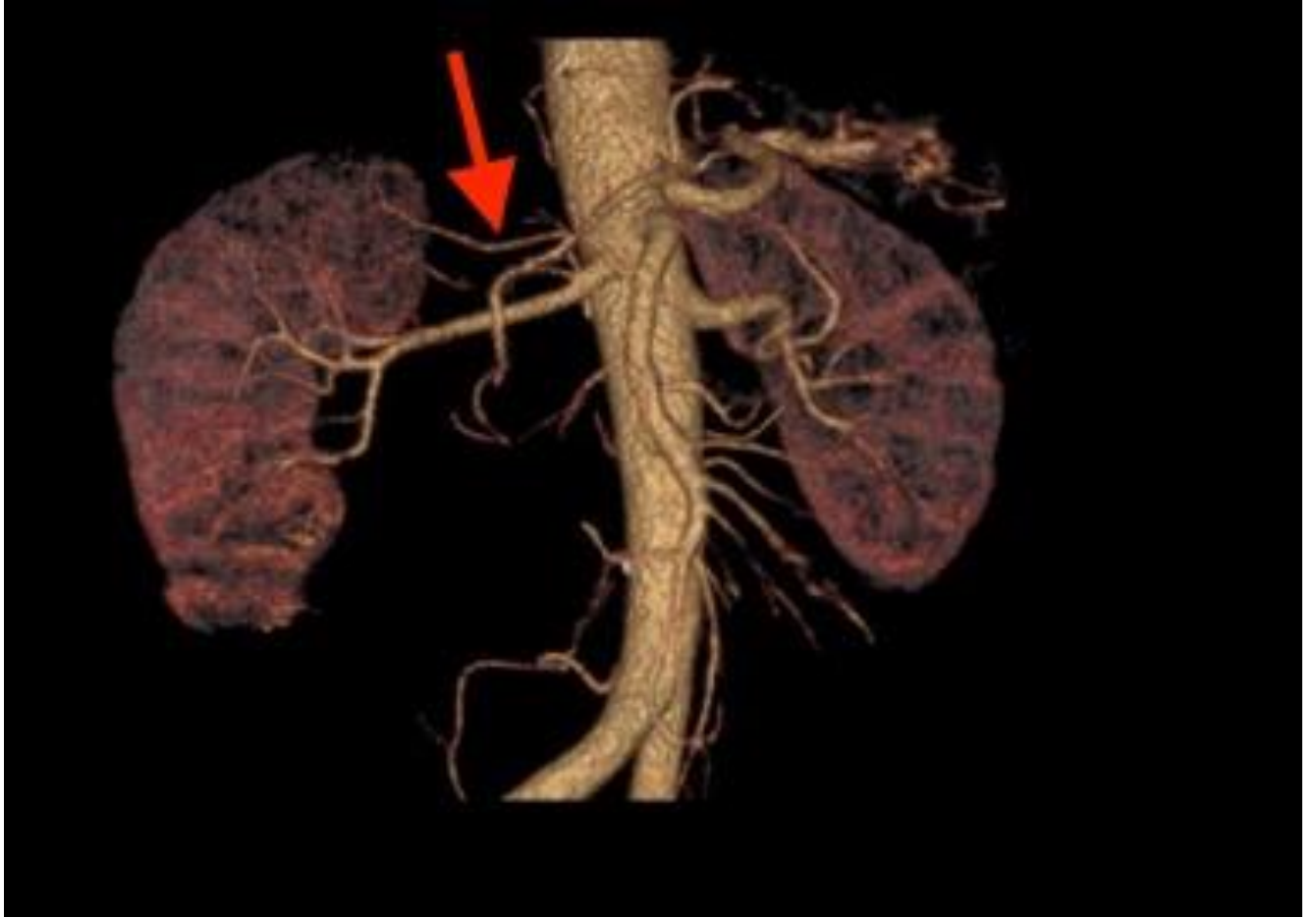


Figure 2. Polar artery of the right kidney in computed tomography angiography image (Red arrow)

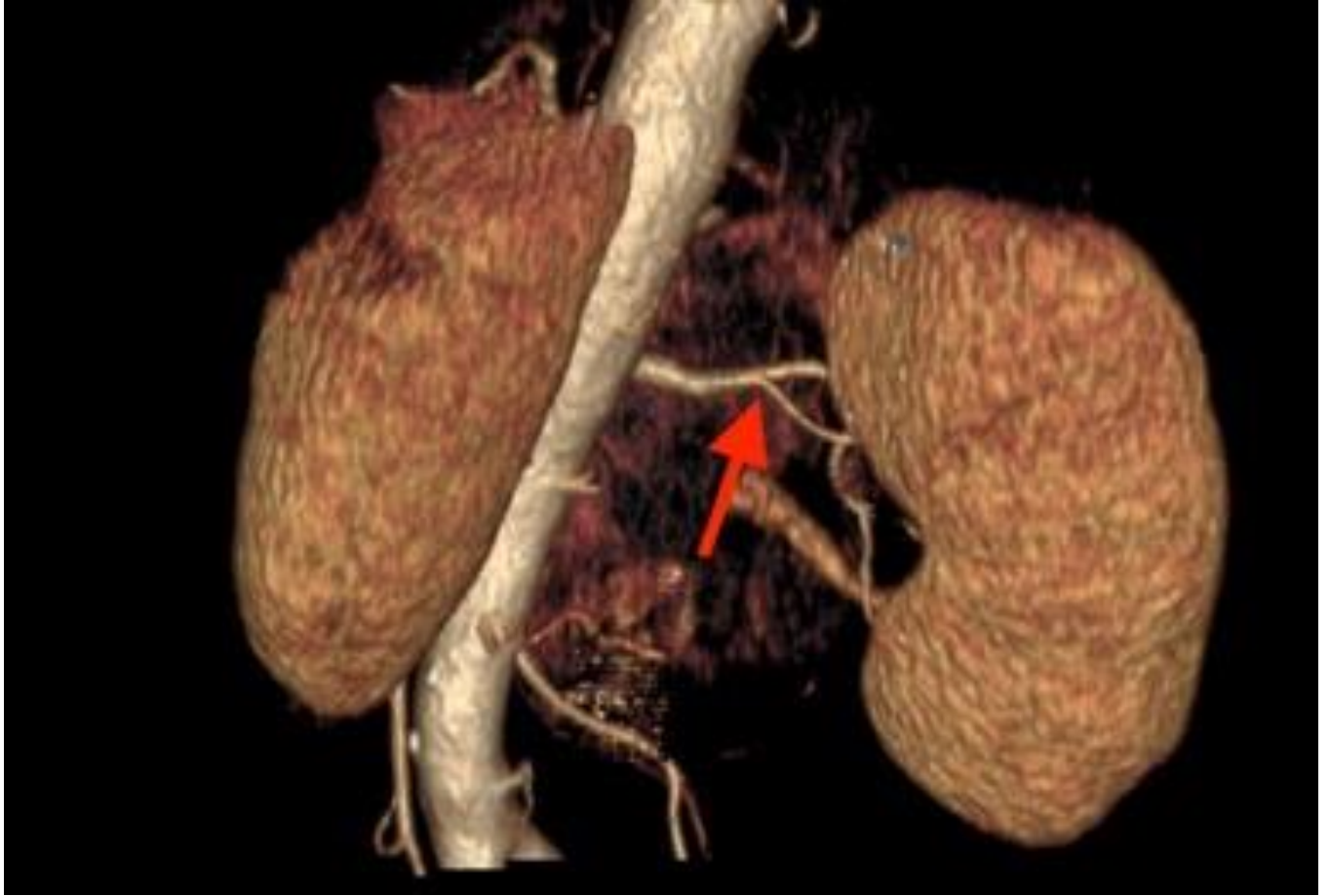

Figure 3. Prehilar branching of left kidney artery in computed tomography angiography image (Red arrow)

Table 1. Patients characteristics

Age (year)	<i>Min-Max (Median)</i>	20-71 (44)
	<i>Mean±SD</i>	44.09±13.54
Gender	Female	46 (50.5%)
	Male	45 (49.5%)
BMI* (kg/m²)	<i>Min-Max (Median)</i>	18.6-40.23 (28.2)
	<i>Mean±SD</i>	28.30±4.44
Hospitalization time (day)	<i>Min-Max (Median)</i>	2-9 (3)
	<i>Mean±SD</i>	3.61±1.39

*BMI: Body mass index

Table 2. Distribution of arterial and venous variations according to gender

	Female n (%)	Male n (%)	p
Single left RA	39(84.8)	32(71.1)	^a 0,094
Single right RA	38(82.6)	32(71.1)	^a 0,101
Accessory right RA	6(13)	9(20)	^b 0,076
Accessory left RA	5(10.8)	9(20)	^b 0,403
Accessory left-right RA	2(4.3)	4(8.9)	^b 0,567
Polar right RA	1(2.2)	2(4.4)	^b 0,119
Single left RV	46 (100)	44(97.7)	^a 0,192
Single right RV	42(91.3)	43(95.5)	^a 1.000
Double right RV	2(4.3)	2(4.4)	^b 1.000

^aFisher's Exact Test ^bStudent - test **p*<0,05 ***p*<0,01

RA: Renal artery, RV: Renal vein

Table 3. The diameter of arteries and veins according to gender and side (Evaluated according to CT-A*)

Side		Female (n=46)	Male (n=45)	^bp
		<i>Mean±SD (mm)</i>	<i>Mean±SD (mm)</i>	
Artery	Right	5.37±0.76	5.56±0.89	0.048*
	Left	5.65±0.64	5.81±0.76	0.317
	^bp	0.013*	0.462	
Vein	Right	6.69±1.2	6.98±2.1	0.006**
	Left	6.04±1.26	6.36±1.98	0.015*
	^bp	0.004**	0.022	
Accessory artery	Right	3.3±0.92	3.6±1.26	0.001**
	Left	2.7±0.81	2.97±1.12	0.003**
	^bp	0.120	0.004**	

^aFisher's Exact Test ^bMann Whitney U Test **p*<0.05 ***p*<0.01

*CT-A: Computed tomography angiography

Table 4. Distribution of arterial and venous variations according to perioperative findings

	Right n (%)	Left n (%)	p
Single artery	21 (100)	61 (85.9)	^a 0.084
Single vein	20 (95.2)	67 (94.3)	^a 0.91
Triple artery	1 (4.7)	3 (4.2)	^b 0.43
Double artery	0 (0)	8 (11.2)	^b 0.49
Double vein	0 (0)	1 (1.4)	^b 0.19

^aFisher's Exact Test ^bStudent T test * $p < 0,05$ ** $p < 0,01$

Table 5. Kidney computed tomography angiography- perioperative findings vascular discordance cases

	Operation side	Preoperative CT findings	Different perioperative findings
Case 1	Left	Double left arteries	Single left artery
Case 2	Left	Single left artery	Double left arteries
Case 3	Left	Single left artery	Double left vein
Case 4	Left	Single left artery	Double left vein
Case 5	Left	Single left artery	Double left arteries