

MIXED GERM CELL TERATOMATOUS TUMOUR OF TESTIS IN ADULTS: DIAGNOSTIC CHALLENGES FOR A HISTOPATHOLOGIST (case report)

D. Aden¹, M. Shadan¹, I. D. Khan², F. Alam¹, M. Naim¹, R. Mohiyadheen¹, E. Naim¹
¹JAWAHARLAL NEHRU MEDICAL COLLEGE, ALIGARH MUSLIM UNIVERSITY, ALIGARH, INDIA
²ARMY COLLEGE OF MEDICAL SCIENCES AND BASE HOSPITAL, NEW DELHI, INDIA

Background. Testicular tumours account for approximately 1-2 % of the total cancer cases in the male population globally and show higher incidence in the younger male age group of up to 15 years. The majority (~98 %) of testicular tumours are observed to be of the germ-cell origin which can either be of seminomatous type or non-seminomatous type. The non-seminomatous germ cell neoplasm may be pure or of mixed subtype.

Objective was to emphasize the rare case of mixed germ cell teratomatous tumour of testis in adult man.

Methods. A mixed germ cell teratomatous tumour of testis comprising of yolk sac tumour and embryonal carcinoma in an adult Indian male is reported in the research.

Results. A 45 year-old Indian male presented with enlargement of right testis which was found to be an encapsulated right testicular tumour on exploratory surgery which was followed by radical orchiectomy. Serum AFP and β -hCG levels were elevated to 380 ng/ml and 590 mg/ml respectively. Histopathology revealed a mixed germ cell teratomatous tumour of testis comprising of yolk sac tumour and embryonal carcinoma.

Conclusions. In adults teratomas occur usually as a component of mixed germ cell tumours. However in the present case teratomatous embryoid yolk sac germ cell tumour of testis was observed in an Indian adult male. The prognosis of embryoid germ cell tumours of testis is generally poor. The possibility of this condition should always be considered in all cases that present with a testicular lump.

KEY WORDS: **testicular tumours; mixed germ cell tumor; embryoid bodies; adult male.**

Introduction

Testicular tumours account for approximately 1-2 % of the total cancer cases in the male population globally [1]. Testicular neoplasia present in a very distinctive age group of distribution and prove higher incidence in the younger male age group of up to 15 years old [2]. The majority (~98 %) of testicular tumours are observed to be of the germ-cell origin [3]. Germ cell neoplasia includes the seminomatous (SGCT) and non-seminomatous germ-cell tumour (NSGCT) types. NSGCT may present as pure (one cell type), or mixed cell (multiple cell type) tumours, depending upon the origin from the adult germ cells or dedifferentiated embryonal cells or from both [2, 4]. The adult germ cell tumours include seminoma, spermatocytic seminoma, while the dedifferentiated NSGCT present a wide spectrum including embryonal carcinoma, embryonal-like somatically differentiated teratoma, extra-embryonally differentiated choriocarcinoma,

Corresponding author: Dr. Inam Danish Khan, Associate Professor, Clinical Microbiology and Infectious Diseases, Army College of Medical Sciences and Base Hospital, New Delhi 110010, India

E-mail: titan_afmc@yahoo.com
Mobile phone: +91 8076324060

and yolk sac tumour phenotypes [2]. The embryonal tumours usually occur in the infant and child groups [5].

A mixed germ cell teratomatous tumour of testis comprising of yolk sac tumour and embryonal carcinoma in an adult Indian male is reported in the research.

Case History

A 45 year-old Indian male was admitted in Jawaharlal Nehru Medical College, Aligarh Muslim University, India with the complaints of enlargement of right testis in the scrotum for six months. Patient was conscious about testicular mass and had no other constitutional symptoms. On clinical examination, a non-tender, firm, freely mobile, and oval lump measuring 6x4x3 cm was palpable, diffusely involving the right testis. The left side showed normal descended testis of normal size, shape, and consistency. Other external genitalia were normal.

Ultrasonographic examination of testis revealed a well-defined encapsulated mass of a size of 54x44 mm with solid and cystic components. No inguinal lymph node enlargement was evidenced. Chest radiography results

were normal. Serum AFP and β -hCG levels were elevated to 380 ng/ml and 590 mg/ml respectively. Exploratory surgery revealed an encapsulated right testicular tumour. Radical orchiectomy was performed and excised mass was submitted for final diagnosis.

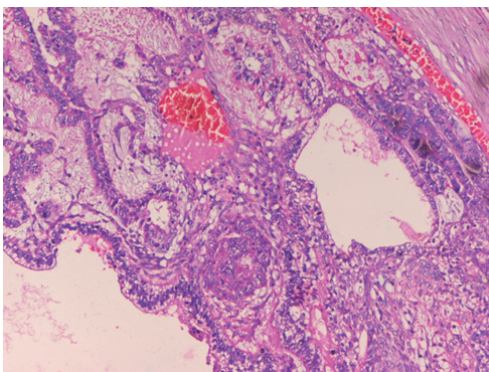
Gross examination proved a firm, encapsulated globular swelling measuring 4.5x4x3 cm. The cut surface presented greyish brown appearance with cystic and solid areas (Fig. 1).

Haematoxylin and Eosin (H&E) stained paraffin sections revealed mixed cell tumour

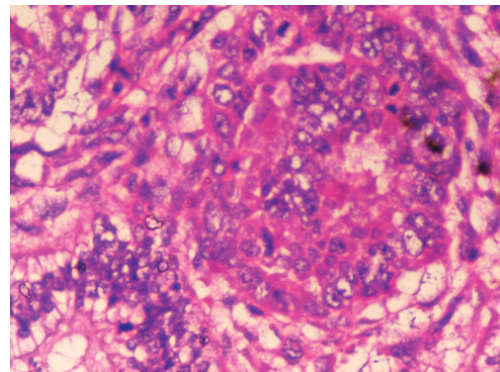
comprising of large pleomorphic atypical cells with vesicular nucleus, prominent nucleoli, abundant cytoplasm, and poorly defined cell borders forming embryoid bodies pathognomonic of embryonal carcinoma of testis (Fig. 2a and 2b). The interspersed areas were of epithelial tubulo-papillary structures with Schiller-Duval bodies and presence of hyaline globules characteristic of yolk sac tumour (Fig. 3). The findings were diagnostic of teratomatous mixed germ cell tumour of testis comprising of yolk sac tumour with embryoid carcinoma of testis.

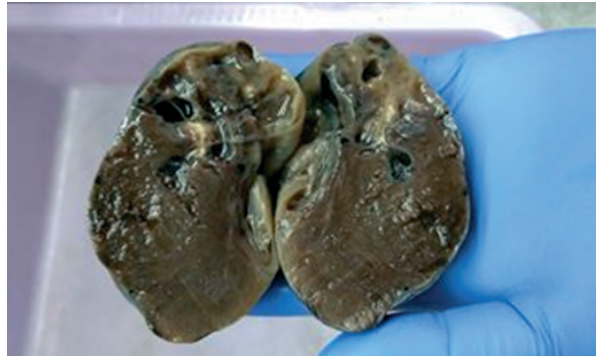

Fig. 1. Gross examination showed a firm, encapsulated globular swelling measuring 4.5x4x3 cms. The cut surface presented greyish brown appearance with solid-cystic areas

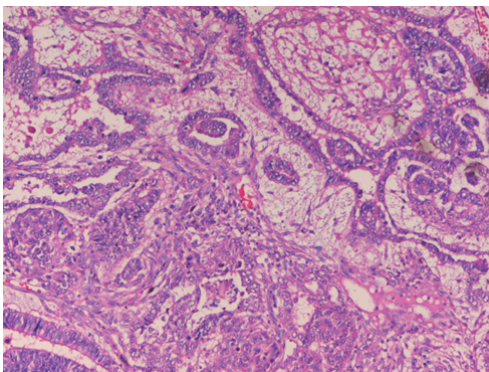


2a

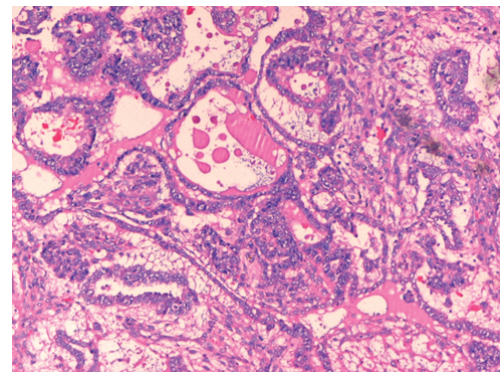


2b

Fig. 2a and 2b. H&E stained sections revealed mixed cell tumour comprising of large pleomorphic atypical cells with vesicular nucleus, prominent nucleoli, abundant cytoplasm, and poorly defined cell borders forming embryoid bodies pathognomonic of the embryonal carcinoma of the testis (100x and 400x).



3a



3b

Fig. 3a and 3b. H&E stained sections showing epithelial tubulo-papillary structures with Schiller-Duval bodies and presence of hyaline globules characteristic of Yolk sac tumour (100x).

Follow up. Post-surgical recovery of the patient was uneventful. He was referred to Medical Oncology Department for platinum chemotherapy and reporting well under follow up for the last 4 months.

Discussion

Histopathological findings in the present case were diagnostic of teratomatous mixed germ cell tumour of testis comprising of yolk sac tumour and embryoid carcinoma of testis. Diagnosis of gonadal germ cell tumours presents diagnostic challenges for the histopathologist. Microscopically, more than a half of germ cell tumours consist of more than one cell type, requiring appropriate sampling for the correct diagnosis [6]. Usually these tumours present one or more of the 4 basic histological patterns namely, seminoma, embryonal carcinoma, choriocarcinoma, and teratoma [7]. The correct diagnosis often has major important therapeutic and prognostic implications.

About one-third of all the testicular tumours are mixed germ cell tumours and 50 % of the mixed cell testicular tumours contain teratomatous components [8]. Very often a random admixture of elements is noted. Yolk sac tumour is a common component of mixed germ cell tumours of testis, accounting for about 1 % of the testicular germ cell tumours [7]. In one series the most frequent combination of mixed germ cells in the tumours was of teratoma and embryonal carcinoma, the major component being teratomatous embryoid elements with minor foci of yolk sac tumour [8]. Another study reported histologically that nearly 59 % of the mixed germ cell tumours contained seminoma, 41 % yolk sac tumour, and 47 % embryonal carcinoma and teratoma components [3].

Although mixed germ cell tumours are common in testis; the presence of embryonal carcinoma and yolk sac elements in the orchidectomy specimen have been a histopathological curiosity, emphasizing the pluripotentiality of the testicular germ cells.

Some workers related this pluripotency of testicular germ cells either to testicular embryonal cell-rests, or to mutations of gonocytes acquired during the fetal development, or to acquired germ cell chromosomal abnormalities during the adulthood [9, 10]. Irrespective of the developmental pathway the tumour cells can histologically differentiate into spermatogenic germ cell like differentiated (seminoma), primitive zygotic (embryonal carcinoma), embryonal-like somatically differentiated (teratoma), and extra-embryonally differentiated (choriocarcinoma and yolk sac tumour) phenotypes [7].

Human chorionic gonadotropin (HCG) and α -Fetoprotein (AFP) serve as helpful tumour marker for testicular germ cell tumours in the adult population [11].

In adults teratomas occur usually as a component of mixed germ cell tumours. The age range in adults is same as of other malignant germ cell tumours. Pure teratomas are uncommon in adults but when present behave in a malignant fashion [12]. Histologically, teratomas consist of tissues representing the 3 germinal layers: endoderm, mesoderm, and ectoderm. The embryonal carcinoma with teratoid embryoid bodies and yolk sac tumour elements are characteristic histopathological findings which distinguish the teratomatous germ cell tumours of testis from the other germ cell tumours. Usually teratomatous germ cell tumours occur in the infant and early childhood [5]. However in the present case teratomatous embryoid yolk sac germ cell tumour of testis was observed in an Indian adult male. The prognosis of embryoid germ cell tumours of testis is generally poor [13, 14].

Conclusions

We wish to emphasize through this case report that even though the occurrence of mixed germ cell tumour in adults is a rare phenomenon, the possibility of this condition should always be considered in all cases that are present with a testicular lump.

ЗМІШАНІ ГЕРМІНОГЕННІ ПУХЛИНИ ЯЄЧКА У ДОРΟΣЛИХ: ДІАГНОСТИЧНИЙ ВИКЛИК ДЛЯ ГІСТОЛОГА (КЛІНІЧНИЙ ВИПАДОК)

D. Aden¹, M. Shadan¹, I. D. Khan², F. Alam¹, M. Naim¹, R. Mohiyadheen¹, E. Naim¹
1 – JAWAHARLAL NEHRU MEDICAL COLLEGE, ALIGARH MUSLIM UNIVERSITY, ALIGARH, INDIA
2 – ARMY COLLEGE OF MEDICAL SCIENCES AND BASE HOSPITAL, NEW DELHI, INDIA

Вступ. Питома вага герміногенних пухлин яєчка становить приблизно 1-2% від загальної кількості злоякісних пухлин у чоловіків, і частіше зустрічаються у віці до 15 років. Більшість (~ 98%) пухлин яєчок, які мають походження із зародкових клітин, можуть бути семіномними і несеміномними пухлинами. Останні можуть бути представлені одним компонентом (чисті) або кількома – змішані пухлини.

Мета дослідження ознайомити широкий загал лікарів з рідкісним випадком змішаної герміногенної пухлини яєчка у дорослого чоловіка.

Методи дослідження. Описано клінічний випадок змішаної тератоматозної герміногенної пухлини, що складалася з пухлини жовткового мішка і ембріональної карциноми у дорослого індійського чоловіка.

Результати дослідження. У 45-річного чоловіка із збільшенням правого яєчка діагностовано інкапсульовану пухлину правого яєчка, після якої проведено радикальну орхіектомію. Рівні сироваткового альфа-фетопротеїну та хоріонічного гонадотропіну були підвищені до 380 нг/мл і 590 мг/мл відповідно. Гістологічний аналіз виявив змішані зародкові клітини тератоматозної пухлини яєчка, що містили клітини жовткового мішка і ембріональної карциноми.

Висновки. Зазвичай у дорослих тератоми виникають як компонент змішаних пухлин ембріональних клітин. Проте в даному клінічному випадку тератоматозна герміногенна пухлина спостерігалася у дорослого індійського чоловіка. Прогноз при таких пухлинах, як правило, несприятливий. Незважаючи на те, що подібні пухлини зустрічаються вкрай рідко, це необхідно враховувати при диференціальній діагностиці.

КЛЮЧОВІ СЛОВА: пухлини яєчок; змішана герміномна пухлина; ембріональні тільця; дорослий чоловік.

References

1. Shanmugalingam T, Soultati A, Chowdhury S, Rudman S, Van Hemelrijck M. Global incidence and outcome of testicular cancer. *Clinical Epidemiology*. 2013;5:417-27. doi:10.2147/CLEP.S34430.
2. Chaganti RSK, Houldsworth J. Genetics and Biology of Adult Human Male Germ Cell Tumors. *Cancer Research*. 2000;60:1475-82.
3. Jena A, Patnayak R, Anil KN, Chowhan AK, Vijaylakshmi DB, Lakshmi AY. Potpourri testicular tumour – combination of seminoma, teratoma and yolk sac tumour of testis in a young adult male. *J Clin Sci Res*. 2014;3:257-60.
4. Soriano SP, Chirivella I, Navarro FS. Coexistence of two germinal cell tumours, seminomatous and nonseminomatous with an uncommon clinical presentation. *Arch EspUrol*. 2008;61:626-30.
5. Pierce GB Jr, Ebell MR. Embryonal carcinoma of the testis. *Pathol Annu*. 1970;5:27-60.
6. Sesterhenn IA, Davis CJ, Jr. Pathology of germ cell tumours of the testis. *Cancer Control*. 2004; 11(6):374-87.
7. Bahrami A, Ro JY, Ayala AG. An overview of testicular germ cell tumors. *Arch Pathol Lab Med*. 2007;131:1267-80.
8. Ulbright TM. Germ cell tumours of the gonads: a selective review emphasizing problems in differential diagnosis, newly appreciated, and controversial issues. *Modern Pathology*. 2005;18 (supplement 2):S61-S79.
9. Skakkebaek, NE, Rajpert-de ME, Jorgensen N, Carlsen E, Meidahl PP, Giwercman A, et al. Germ cell cancer and disorders of spermatogenesis: an environmental connection? *Acta Pathol. Microbiol. Immunol. Scand*. 1998;106:3-12.
10. Chaganti RSK, Houldsworth J. The cytogenetic theory of the pathogenesis of human adult male germ cell tumors. *Acta Pathol. Microbiol. Immunol. Scand*. 1998;106:80-4.
11. Ross JH, Robert KR. Prepubertal testis tumours. *Reviews in Urology*. 2004;6(1):11-18.
12. Cheng L, Zhang S, Eble JN, Beck SD, Foster RS, Wang M, et al. Molecular genetic evidence supporting the neoplastic nature of fibrous stroma in testicular teratoma. *Mod Pathol*. 2012;25(10):1432-8.
13. Stamatiou K, Papadopoulos P, Perlepes G, Galariotis N, Olympitis M, Moschouris H, et al. Mixed germ cell tumour of the testicle with rhabdomyosarcomatous component: a case report. *Cases J*. 2009;2:9299.
14. Khan S, Singh V, Khan ID, Panda S. Sclerosing Stromal Cell Tumour of Ovary. *Med J Armed Forces India*. 2017. doi: <http://dx.doi.org/10.1016/j.mjafi.2017.09.007>

Received: 2018-05-03