

EMBOSSSED AUTODERMOTRANSPLANTS: THEORETICAL SUBSTANTIATION AND PRACTICAL USAGE

V. V. Koptiukh, I. Y. Galaychuk

I. HORBACHEVSKY TERNOPIL STATE MEDICAL UNIVERSITY

Background. It is established that granulation wound has uneven bumpy surface and modern electric dermatomes cut skin with a smooth internal surface. Therefore there is no tightly contact between the smooth surface of a graft and granulation tissue.

Objective. The method of harvesting by split-skin grafts with variable thickness (embossed) is proposed.

Methods. An embossed skin graft with sinusoidal surface of inner side was obtained by modified dermatome with special technological plate. The embossed autografting of skin was applied in 16 patients (21–60 years old) with deep burns of 7–9% of body. For clinical comparison the part of granulating wounds in each patient was covered with embossed transplants and the other part with smooth split-thickness grafts.

Results. During ultrasound Doppler examination of grafts on the fifth postop day the active blood flow in embossed transplants with 4–6 blood outbreaks and only 2–3 flashes in smooth graft were found. Clinically the embossed transplants were engraftment on 6–7th day. On 18–21st day the roughness of grafts surface disappeared. In two months the graft together with subcutaneous fatty tissue was taken in crease. Donor wound: on 14–15th day its surface was like “slate” but on 25–30th day the undulation of the re-epithelisation skin disappeared.

Conclusions. The improvement of dermatome design with technological plate allows cutting scalloped split-skin grafts of varied thickness (embossed).

Split-thickness embossed grafts combine anatomic and physiological features of skin cover granulation wound to adhere tightly because of the enlargement of area of their internal surface without retraction and/or secondary shrinkage.

Donor wounds, after the harvesting of embossed skin grafts, contain the morphological elements of dermis which contribute to their complete spontaneous healing.

KEY WORDS: embossed split-thickness skin graft, granulating wound.

Introduction

Skin transplantation is a method of choice in the treatment of patients with deep burns. In order to do this procedure, split-thickness skin grafts are harvested from donor areas. The donor wound regrows epithelium within two weeks [1–3, 5]. Sometimes there are complications with transplant skin engraftment to a granulating wound, sometimes areas of donor wounds suppurate [4, 6, 7, 11].

Important aspect of skin graft healing is wound contraction that may present serious functional and cosmetic concerns, depending on the location and severity. Myofibroblasts may cause contraction. The ability of a skin graft to resist contraction is related to the thickness of deep dermal component included in the

graft, not just the absolute thickness of the graft. This deep dermal component is able to suppress myofibroblast function. The severity of wound contraction from the least to the most is as follows: full-thickness skin graft cause least contraction, then thick and thin split-thickness skin graft, and finally the open wound has the most contraction [14].

Modern electric dermatomes cut skin with a smooth internal surface, in the meantime granulation wound has uneven bumpy surface [1, 12]. In certain cases there is no close contact between the smooth surface of a skin graft and granulation tissue; there are gaps and voids, where discharge from the wound collects, colonies of microorganisms form, which may cause hematomas or seromas and local inflammatory complications [4, 8, 9, 11].

Thus, for successful healing by a skin graft without contraction of the wound, it is necessary to have the surface adapted to the granulating

Corresponding author: Igor Galaychuk, Department of Oncology, Radiology Diagnostics and Therapy and Radiation Medicine, I. Horbachevsky Ternopil State Medical University, 1 Maidan Voli, Ternopil, Ukraine, 46001
 Phone number: +380506975723
 E-mail: halaychuk@gmail.com

wound surface and contained with the elements of dermis.

The question we are aiming to address is to find out if it is possible to cut skin graft with an uneven embossed surface, similar to the relief of granulations.

The study is **aimed** to introduce a method of harvesting the split-skin grafts of variable thickness.

Material and Methods

Theoretical consideration. The upper boundary of granulation tissue on the tentative vertical cut of the wound is a sinusoid with smaller or larger range, depending on which granulations (small-, medium-, or large-grained) fill the wound. Theoretically these granulations should be covered with analogic sinusoidal surface (Fig. 1). Obviously, the larger is the surface of granulations contact with the graft, the faster graft retention will be. Optimal configuration of internal surface of skin graft with spacing between ledges of $\pi/2$, $\pi/4$, $\pi/8$ mm (equals to 1.57 mm, 0.78 mm and 0.39 mm) is proved mathematically.

Technical solution. To obtain split-skin grafts with variable thickness (embossed) it is suggested to add a so called technological plate with embossed surface [10]. A technological plate is made of plastic mass or metal and consists of a base and shaped elements on it which have ledges of rectangular or other geometric figure shapes (Fig. 2).

Method of embossed skin graft cutting. Instruments and donor area do not differ from

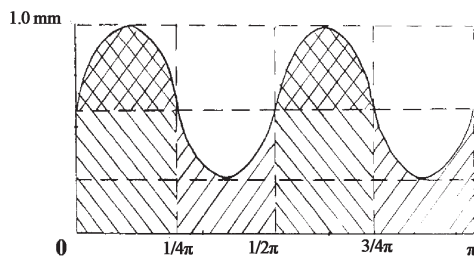


Fig. 1. Scheme of sinusoidal surface of granulation wound with the sinusoid length of $\pi/2$ mm (medium grained granulation tissue).

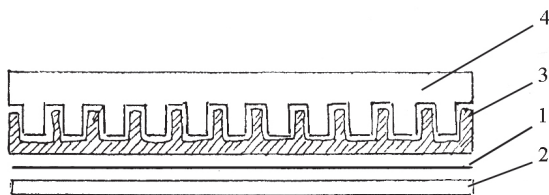


Fig. 2. The scheme of cutting edge of the dermatome: 1 — blade, 2 — protective plate of the dermatome, 3 — split-thickness embossed skin graft, 4 — technological plate.

regular grafting. The technological plate is fixed to the base of the dermatome. The embossed surface of the plate should adjoin the skin of donor area tightly. Technological plate should be chosen according to the size of granulation on the wound: small-, medium- and large-grained. Fig. 3 shows embossed skin graft harvest of the variable thickness and donor wound with sinusoidal surface.

An embossed skin graft has sinusoidal surface from the inner side, which considerably enlarges area of its contact with granulations on the wound (Fig. 4). E.g., the inner surface is embossed skin graft with 0.78 mm space between ledges is larger by 29.3% if compared to a smooth graft.

Full-scale adhesion to wound surface contributes to a quick engraftment of dermal transplant and minimizes the local postoperative complications. The epithelisation of donor wound is not affected because all skin appendages are preserved.

Clinical application. The embossed auto-grafting of skin was applied for 16 patients with deep burns of 7–9% of the body. The patients aged 21–60 years, 13 mail (81.0%), and 3 female (19.0%). Part of granulating wounds in each patient was covered with embossed transplants, and part of them with smooth split-thickness grafts. Thus it was possible to conduct a clinical comparison of survival of two types of grafts. Next day after the surgery the surface of the embossed skin grafts was of different colours — pale and cyanotic lines along the grafts. On the second or third day cyanosis

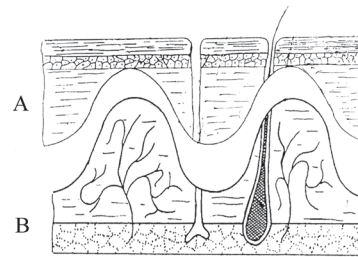


Fig. 3. Scheme of split-thickness embossed skin graft cutting: A — embossed skin graft, B — donor wound.

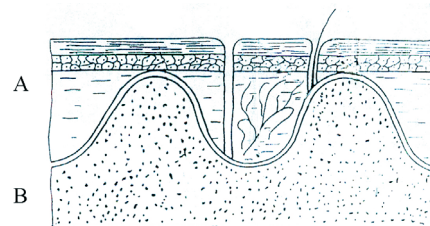


Fig. 4. Scheme of covering the granulation wound with embossed skin graft (A — skin graft, B — granulation wound).

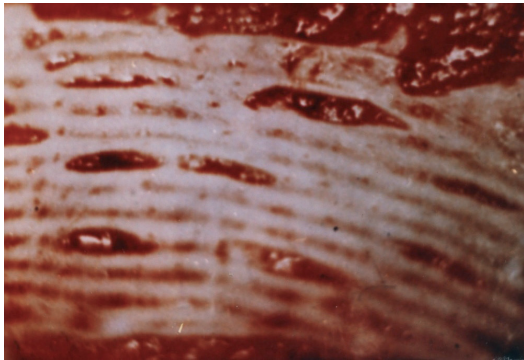


Fig. 5. Embossed split-thickness skin graft (clinical example).




Fig. 6. Fragment of sinusoidal surface of donor wound.

decreased, and on 4–5th days the colour of the embossed grafts became even. Clinically the embossed transplants were engrafted on 6–7th day. On 18–21st day the roughness of grafts surface disappeared. In two months the graft together with subcutaneous fatty tissue was taken in the crease. Donor wound: on 14–15th day its surface was like “slate”, but on 25–30th day the undulation of the re-epithelized skin disappeared.

Ultrasound Doppler (Siemens G60S) examination of grafts was performed on the 5th day. Active blood flow was found in some parts of the embossed transplants, there were on average 4–6 blood outbreaks on the length of the linear sensor (L10-5; 7.5–10.0 MHz), but in smooth graft, which was still swelling, there were only 2–3 flashes. Therefore, variable thickness skin graft integrated with granulation tissue faster. Thus, our clinical study proved the use of embossed skin grafts in closing the granulating wounds.

Results and Discussion

The embossed epidermo-dermal transplants with variable thickness contain morphological elements of dermis which the thin smooth split-thickness skin grafts do not have. The thin part of the sinusoidal graft is represented by the epidermis; the thick part contains papillary and reticular dermis. So there are all structures of the skin: loose and dense connective tissue containing blood and lymphatic capillaries and vessels, elastic and collagen fibres, reticular layer with fibroblasts, nerve endings, and epidermal appendages in the gel-like ground substance. The same components are also in donor sites and play a crucial role in its re-epithelialization. That is why after placement of sinusoidal graft, its initial adherence to the wound bed via a fibrin binding is favourable if compared to the straight skin graft.

It is established that the smooth split skin grafts shrink along fibres on cleavage lines and in transverse directions after cutting. Moreover, shrinkage along the cleavage lines is almost twice as much as transverse shrinkage. Convolution of split-thickness skin grafts to internal surfaces is its characteristic feature [1, 6].

The shrinkage of skin grafts increases with the increase of its thickness. Thin transplants of 0.1–0.4 mm shrink minimally, transplants of medium thickness (0.5–0.6 mm) shrink by 15–25%, thick (0.7–1.0 mm) — up to 50%, full-layer (>1.1 mm) — even more. Moreover, longitudinal and lateral components of shrinkage differ in 1.3–1.6 times [1, 3, 4, 12, 14].

Because of the embossed surface the shrinkage of epidermo-dermal transplant decreases considerably and the preserved morphological structure of dermis contributes to fast healing of burn wound as well as regeneration of functions of the transplanted skin.

The choice of skin grafts thickness is very important for successful autodermoplastic surgeries. Autodermoplastics with thin grafts have several advantages: the transplant survives for an average of 3–4 days, and the donor wound epithelizes for 12–14 days. However, this method has its deficiencies as well. Secondary shrinkage of the transplant occurs with usage of thin split grafts for wound covering; besides fatty tissue does not grow under this type of transplant [6, 8, 13].

Usage of full-thickness skin grafts has distinct advantages. They withstand mechanical loads, full fatty tissue grows under them, thanks to the renewed skin integument, which receives the functional and dynamic features. Long term retraction and retention of full-layer grafts are significant disadvantages. They suppurate and are rejected more often. The usage of such grafts creates problems for the treatment of a donor wound, which has to be covered with local tissues or autodermotransplants [1, 7, 9, 12, 14].

Epidermis of various topographical anatomical body areas is different in terms of relief, color and thickness (0.5–0.2 mm). Human skin thickness varies from 0.4 up to 4.0 mm. Thickness of the skin's dermal layer varies from 0.35 up to 4.0 mm and is a significant resource for harvesting split flaps [1, 14].

Opposite to the smooth split grafts, embossed dermotransplants with variable thickness retain anatomical and physiological features of skin in monofunctional structural integrity; herewith there is no substantial transplant shrinkage. The area of contact of transplant and wound increases because of the positioning of surface granulations, which hasten the process of its engraftment.

References

1. Ratner D. Skin grafting. From here to there. *Dermatol Clin* 1998; 16(1): 75–90.
2. White N, Hettiaratchy S, Papini RP. The choice of split-thickness skin graft donor site: patients' and surgeons' preferences. *Plast Reconstr Surg* 2003; 112 (3): 933–934.
3. Mimoun M, Chaouat M, Picovski D, et al. The scalp is an advantageous donor site for thin-skin grafts: a report on 945 harvested samples. *Plast Reconstr Surg* 2006; 118 (2): 369–373.
4. Unal S, Ersoz G, Demirkan F, et al. Analysis of skin-graft loss due to infection: infection-related graft loss. *Ann Plast Surg* 2005; 55 (1): 102–106.
5. Demirtas Y, Yagmur C, Soylemez F, Ozturk N, Demir A. Management of split-thickness skin graft donor site: A prospective clinical trial for comparison of five different dressing materials. *Burns* 2010; 36 (7): 999–1005.
6. Rudolph R. The effect of skin graft preparation on wound contraction. *Surg Gynecol Obstet* 1976; 142 (1): 49–56.
7. Zuidam JM, Coert JH, Hofer SO. Closure of the donor site of the free radial forearm flap: a comparison of full-thickness graft and split-thickness skin graft. *Ann Plast Surg* 2005; 55 (6): 612–616.
8. Terrill PJ, Goh RC, Bailey MJ. Split-thickness skin graft donor sites: a comparative study of two absorbent dressings. *J Wound Care* 2007; 16 (10): 433–438.
9. Liu J, Li Y, Rong X, Lin W, Zhang T, Wang B, et al. Application of crystalline cellulose membrane (Veloderm) on split-thickness skin graft donor sites in burn or reconstructive plastic surgery patients. *J Burn Care Res* 2013; 34 (3): e176–e182.
10. Patent UA 69020. IPC A61B 17 /322 (2006.01). Dermatome for cutting quasithick autodermograft / V.V. Koptiukh (UA). No. u201108642; Appl. 11.07.2011. Publ. 24.04.2012. Bulletin № 8.
11. World Union Wound Healing Societies (WUWHS). Wound Infection in Clinical Practice – An International Consensus. *International Wound Journal* 2008; 5 (3): 1–4.
12. Northern Sydney Central Coast Health (NSCCH.) Skin graft management guidelines [Internet]. Sydney: NSCCH; Sep, 2008. [cited 2013 Dec 12]. Available from: <http://web.archive.org/web/20130420112308/http://www.nscchealth.nsw.gov.au/services/wound.care/Final-Skingraftmanagement-draft.pdf>.
13. Brolmann FE, Eskes AM, Goslings JC, Niesen FB, de Bree R, Vahl AC, et al. Randomized clinical trial of donor-site wound dressings after split-skin grafting. *Br J Surg* 2013; 100 (5): 619–627.
14. Wax MK, Meyers AD. Split-Thickness Skin Grafts. [Updated: Mar 18, 2015]. Available from: <http://emedicine.medscape.com/article/876290>.

Received: 2016-10-08