

Comparison of computerized tomography and direct visualization in thoracic pedicle screw placement

GANESH RAO, M.D., DARREL S. BRODKE, M.D., MATTHEW RONDINA, B.S.,
AND ANDREW T. DAILEY, M.D.

*Departments of Neurosurgery, Orthopedics, and the College of Medicine, University of Utah,
Salt Lake City, Utah*

Object. To validate computerized tomography (CT) scanning as a tool to assess the accuracy of thoracic pedicle screw placement, the authors compared its accuracy with that of direct visualization in instrumented cadaveric spine specimens.

Methods. A grading scale was devised to score the placement of the pedicle screw. The grades ranged from 0 to 3 depending on the extent to which the pedicle had been violated. One hundred fifty-five pedicles were fitted with instrumentation in eight cadaveric spines. A single observer graded the appearance of the screw based on CT scans (3-mm axial sections with 1-mm overlap) and direct visualization of the specimen. The authors arrived at a Kappa value of 0.51, which suggested only moderate agreement between the two measurement techniques. Whereas CT had a positive predictive value of 95%, it had a negative predictive value of 62%.

Conclusions. The authors thus conclude that although CT scanning is the most valid tool to assess the accuracy of thoracic pedicle screw placement, it tends to overestimate the number of misplaced screws.

KEY WORDS • computerized tomography • pedicle • thoracic spine

THE indications for pedicle screw fixation in the thoracic spine continue to expand the more familiar surgeons become with the anatomy and techniques for pedicle fixation.^{1,3,7,13,17,18,21} By providing rigid fixation, pedicle screws allow for greater correction of deformity¹⁸ and greater pullout strength than traditional hook/rod constructs.¹² Whereas the authors of initial reports suggested screw misplacement rates of up to 41%,²⁰ those of more recent studies indicate rates of approximately 10%, with an incidence of neural complications of less than 1%.^{18,25} Stereotactic navigation for placement of thoracic pedicle screws has been shown to decrease the occurrence of cortical perforation compared with the use of anatomical landmarks and standard fluoroscopy.²⁵ There is no consistent method, however, with which to evaluate screw placement accuracy in the literature concerning thoracic pedicle screws.

The accuracy of pedicle screw placement is important for structural support, fusion, and ultimate surgical correction. This is particularly true in the thoracic spine where anatomical landmarks are small and where misplaced screws threaten vital thoracic structures.^{5,20,25} Computerized tomography scanning is often used both clinically and in the laboratory setting to assess the accuracy of pedicle screw positioning.^{12,16,18,20,25} The presence of artifact and flare from metallic implants, however, makes accurate CT assessments of screw position difficult.^{15,24} Other investigators have evaluated plain radiography to assess successful

pedicle screw placement.¹⁹ In one previous study the authors examined the accuracy of CT scanning to identify pedicle screw placement in the lumbar spine.²⁴ The authors did not consider the unique anatomy of the thoracic spine, nor did they use a grading system to differentiate the severity of pedicle screw misplacement. To our knowledge, there have been no other studies conducted to evaluate the reliability of CT scanning as a modality for assessing the accuracy of thoracic pedicle screw placement. To validate CT scanning in this endeavor, we compared pedicle screw placement demonstrated on CT scans with direct visualization in a cadaveric thoracic spine.

Materials and Methods

Eight thoracic spines were harvested from fresh-frozen adult cadavers for use in our analysis. In these eight specimens, 155 pedicles were instrumented. Preinstrumentation CT scans were obtained to determine the diameter of the thoracic pedicles. Pedicles less than 4.5 mm were not instrumented. Pedicles 4.5 to 5.5 mm were instrumented using 4.5-mm screws (Danek M8 screws; Sofamor Danek, Memphis, TN). The remaining pedicles were instrumented with 5.5-mm screws (Dynalok screws; Sofamor Danek). Titanium pedicle screws were placed using either a freehand technique or stereotactic or virtual fluoroscopy. Regardless of whether the pedicle was instrumented with the assistance of stereotaxy, the same basic technique was performed.⁴ After the spines had been instrumented, we performed CT scanning (CT/I scanner; General Electric, Milwaukee, WI). The protocol for imaging each spine consisted of 3-mm axial cuts with 1-mm overlap. Window settings were adjusted for optimum visualization of the screws and bone.

Each pedicle was assigned a grade from Grade 0 to 3. The grading scale is as follows: 0 reflected no perforation of the pedicle,

Abbreviation used in this paper: CT = computerized tomography.

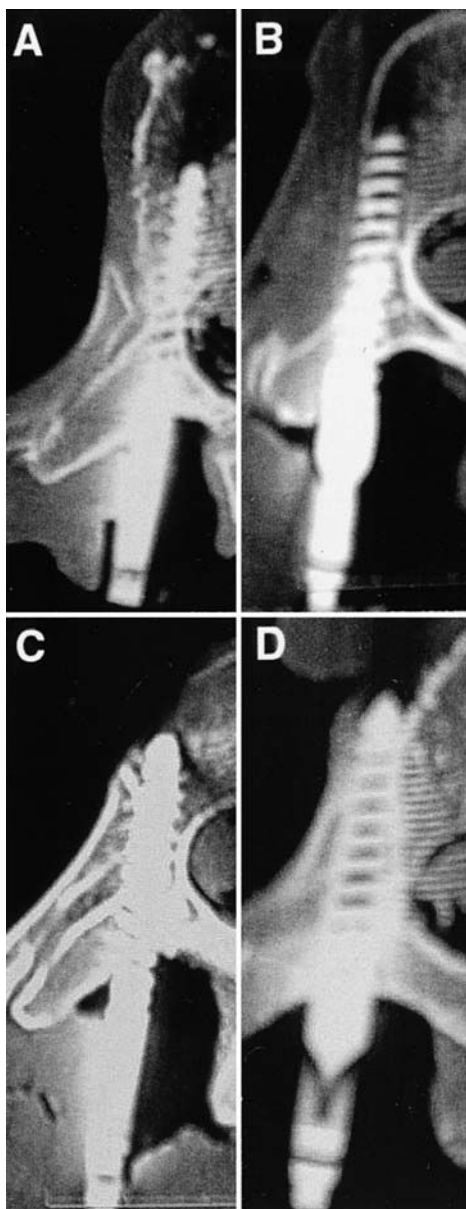


FIG. 1. Computerized tomography studies depicting Grades 0 (A), 1 (B), 2 (C), and 3 (D).

1 indicated less than 2 mm of perforation of the pedicle with one screw thread out of the pedicle, 2 represented 2 to 4 mm of perforation of the pedicle, and Grade 3 reflected greater than 4 mm. Medial and lateral perforations were grouped together for final analysis because of the small number of medial perforations in the study (see *Results*). Examples of each CT-visualized grade are shown in Fig. 1. Each spine was then directly visualized and assigned a grade as well. Figure 2 provides examples of Grades 1 and 2. Grading, both on CT scans and direct inspection, was performed by the senior author (A.T.D.), who was blinded to which CT scans correlated with each specimen.

Results

The positioning of 155 pedicle screws were graded based on CT scans and on direct visual inspection of each specimen. Figure 3 shows the distribution of grades

between the two methods of measurement. Based on results of CT evaluation Grade 0 was assigned to 110 pedicle screws, whereas Grade 0 was assigned to 122 screws based on direct visualization. There were 32 Grade 1 screws based on CT examination compared with 23 based on direct visualization. There were 13 Grade 2 scores based on CT studies versus 10 based on direct visualization. There were no Grade 3 screws determined using either technique. Only six screws appeared to be medially placed on CT examination, whereas four appeared to be medially placed on visual inspection. Because of the small number of medial perforations compared with the total number of perforations, all screw perforations were grouped together for statistical analysis.

We then calculated a Kappa value (performed with SPSS for Windows; SPSS, Chicago, IL), which is a reliability test used to determine observed agreement between techniques of measure.¹¹ In other words, how do these two methods for assessing the accuracy of pedicle screw placement in the thoracic spine compare? A Kappa value closer to 1 suggests a perfect association of agreement (that is, that CT measurement is just as accurate as direct visualization), whereas a value closer to 0 suggests any observed agreement is likely to be just chance. We found a Kappa value of 0.507, which suggests a moderate degree of agreement.¹⁹

We then calculated sensitivity, specificity, positive predictive value, and negative predictive value of CT scanning as a measure of the accuracy of pedicle screw placement (also performed with SPSS). We assumed that direct visual inspection of the instrumented specimen is the gold standard for determining such accuracy because the specimen can be viewed in all dimensions. We found a sensitivity of 86%, a specificity of 85%, a positive predictive value of 95%, and a negative predictive value of 62%.

Discussion

Placement of pedicle screws for spinal stabilization is a common procedure. In the lumbar spine, screw placement is made easier by the larger pedicles and less dangerous because of the lack of major vital structures.^{4,6,15,22,26} Instrumentation for thoracic fixation has more traditionally been of pedicle and laminar hooks because of the smaller diameters of thoracic pedicles and the proximity of important neural and vascular structures.^{5,9,20} Investigators of pedicle morphometry have revealed that the superoinferior diameter of the thoracic pedicle is much greater than the mediolateral diameter, with the narrowest pedicles occurring at T-5 or T-6 and measuring less than 4.5 mm on average.^{2,5,10} Additionally, the medial wall is significantly thicker than the lateral wall and may explain why most pedicle fractures after screw placement occur laterally.⁹ Accurate placement of screws is paramount, because the dural sac lies immediately adjacent to the pedicle throughout the thoracic spine.⁵ Numerous techniques have been conducted to make instrumentation-related fixation of the thoracic spine easier;^{4,8,13,16,20,23} however, transpedicular fixation in the thoracic spine is generally limited to those cases in which the clinical indication is clear.^{13,20}

Recently, a number of articles have appeared in which the authors describe pedicle screw fixation in the thoracic

Comparison of CT and direct visualization

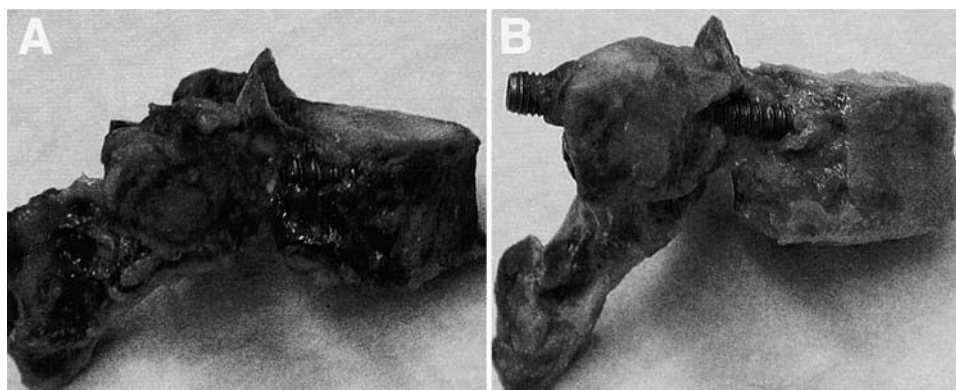


FIG. 2. Photographs. A: Specimen representing a Grade 1 pedicle perforation. B: Specimen representing a Grade 2 pedicle perforation.

spine.^{4,7,12,13,17,18,20} Surgeons have successfully used thoracic pedicle screw fixation for a variety of indications including idiopathic scoliosis, traumatic injury, and tumor. The ability to achieve greater correction of a deformity and maintain that correction has led to wider application of transpedicular fixation in the thoracic spine. In many reports the authors have outlined the accuracy of various techniques in vivo by using postoperative CT examination to determine the accuracy of screw positioning.^{1,4,7,12,13,17,18,20,25} Perforation rates (medial and lateral) have been reported to range from 1 to 43% when these methods are performed.¹ To our knowledge, there has not been a critical examination of the ability of CT scanning to assess the accuracy of pedicle screw placement in the thoracic spine. We therefore undertook this study to validate this modality for assessing the accuracy of pedicle screw placement, particularly in the thoracic spine where the pedicles are smaller and misplaced screws can be less forgiving. We found that CT scanning has a moderate measure of agreement compared with a standard of direct visual inspection of the specimen (Kappa value 0.51). This suggests that CT scanning provides an adequate assessment of screw accuracy in vitro or in vivo.

Using direct visual inspection of the pedicle as the gold standard of pedicle screw placement, we also determined the sensitivity, specificity, and positive and negative predictive values of CT-documented accuracy. With a specificity and sensitivity of 86 and 85%, respectively, CT evaluation is comparable with the gold standard (direct visual inspection) as a test of proper screw placement. These values are consistent with others reported in the literature with respect to evaluation of screws in the lumbar spine.²⁴ With a positive predictive value of 95%, when CT scanning demonstrated that a pedicle screw was in place, it was in fact most likely in place. We found, however, that CT scanning has a negative predictive value of 62%, which suggests that when CT scanning demonstrated that a screw was misplaced, it was only correct 62% of the time. In essence, CT scanning seems to overestimate screw misplacement. The reason for the appearance of screw breakout on CT scans, despite apparent pedicle integrity with direct visualization, probably lies in the phenomenon of plastic deformation of bone.^{14,15} This occurs once the endosteal diameter of the pedicle is exceeded by

the screw size or within 80% of the outer cortical diameter.¹⁴ Deformation may occur without pedicle fracture or screw cutout. In the study by Sjoström, et al.,¹⁵ the authors showed, in an in vivo setting, that pedicle screws increase a pedicle's width, giving credence to the principle of plastic deformation. Surgeons should therefore take plastic deformation of the pedicle into consideration when CT scanning demonstrates a titanium pedicle screw that appears to perforate the pedicle minimally.

We have shown that CT scanning can be used reliably to assess the accuracy of thoracic pedicle screw placement. This validates it as a tool both clinically and in the laboratory. Yoo, et al.,²⁴ found a significantly lower sensitivity and specificity for CT scanning when they evaluated cobalt-chrome screws compared with titanium screws in the lumbar spine. They concluded that in the setting of chrome-cobalt screws, CT scanning could not be relied on alone to provide accurate information after screw placement. Analysis of our results suggests that while CT scanning has good sensitivity and specificity for evaluation of titanium screw placement in the thoracic spine, it tends to exaggerate a minimal violation of the pedicle by a screw. Proper placement of pedicle screws is important for structural stability and avoidance of vital structures. Screw stability is dependent on the purchase it obtains within the

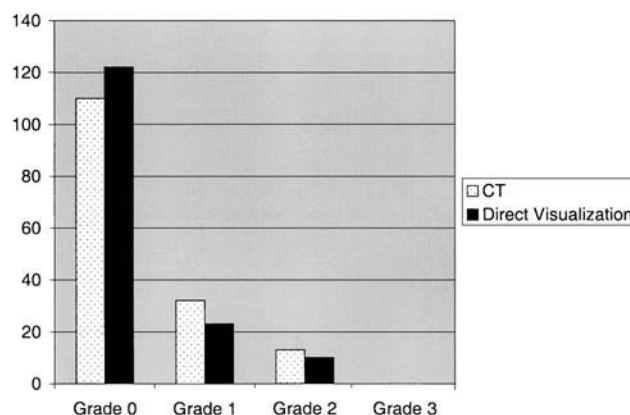


FIG. 3. Graph demonstrating grades obtained for CT scanning and direct visual inspection.

cancellous portion of the pedicle,¹⁸ and the ability to demonstrate this on CT scans has obvious importance. We conclude from this study that CT scanning is a useful and reliable tool for assessing the accuracy of thoracic pedicle screw placement. Because of plastic deformation of the pedicles following screw placement, however, CT scanning tends to be overly sensitive to screws that appear to be placed adjacent to the pedicle yet remain within the cortical margins.

Disclosure

The authors acknowledge the contribution of the cadaveric specimens and instruments from Sofamor Danek.

References

1. Belmont PJ Jr, Klemme WR, Dhawan A, et al: In vivo accuracy of thoracic pedicle screws. **Spine** 26:2340–2346, 2001
2. Berry JL, Moran JM, Berg WS, et al: A morphometric study of human lumbar and selected thoracic vertebrae. **Spine** 12:362–367, 1987
3. Chang KW: Oligosegmental correction of post-traumatic thoracolumbar angular kyphosis. **Spine** 18:1909–1915, 1993
4. Cinotti G, Gumina S, Ripani M, et al: Pedicle instrumentation in the thoracic spine. A morphometric and cadaveric study for placement of screws. **Spine** 24:114–119, 1999
5. Ebraheim NA, Jabaly G, Xu R, et al: Anatomic relations of the thoracic pedicle to the adjacent neural structures. **Spine** 22:1553–1557, 1997
6. Ebraheim NA, Xu R, Ahmad M, et al: Projection of the thoracic pedicle and its morphometric analysis. **Spine** 22:233–238, 1997
7. Esses SI, Botsford DJ, Wright T: Operative treatment of spinal fractures with the AO internal fixator. **Spine** 16:S146–S150, 1991
8. Gertzbein SD, Robbins SE: Accuracy of pedicular screw placement in vivo. **Spine** 15:11–14, 1990
9. Kothe R, O'Holleran JD, Liu W, et al: Internal architecture of the thoracic pedicle. An anatomic study. **Spine** 21:264–270, 1996
10. Krag MH, Weaver DL, Beynon BD, et al: Morphometry of the thoracic and lumbar spine related to transpedicular screw placement for surgical spinal fixation. **Spine** 13:27–32, 1988
11. Landis JR, Koch GG: The measurement of observer agreement for categorical data. **Biometrics** 33:159–174, 1977
12. Liljenqvist U, Hackenberg L, Link T, et al: Pullout strength of pedicle screws versus pedicle and laminar hooks in the thoracic spine. **Acta Orthop Belg** 67:157–163, 2001
13. Liljenqvist UR, Halm HF, Link TM: Pedicle screw instrumentation of the thoracic spine in idiopathic scoliosis. **Spine** 22:2239–2245, 1997
14. Misenhimer GR, Peek RD, Wiltse LL, et al: Anatomic analysis of pedicle cortical and cancellous diameter as related to screw size. **Spine** 14:367–372, 1989
15. Sjoström L, Jacobsson O, Karlström G, et al: CT analysis of pedicles and screw tracts after implant removal in thoracolumbar fractures. **J Spinal Disord** 6:225–231, 1993
16. Steinmann JC, Herkowitz HN, el-Kommos H, et al: Spinal pedicle fixation. Confirmation of an image-based technique for screw placement. **Spine** 18:1856–1861, 1993
17. Suk S, Lee CK, Kim WJ, et al: Segmental pedicle screw fixation in the treatment of thoracic idiopathic scoliosis. **Spine** 20:1399–1405, 1995
18. Suk SI, Kim WJ, Lee SM, et al: Thoracic pedicle screw fixation in spinal deformities: are they really safe? **Spine** 26:2049–2057, 2001
19. Szklo M, Nieto FJ: **Epidemiology: Beyond the Basics**. Gaithersburg, MD: Aspen, 2000, pp 375–380
20. Vaccaro AR, Rizzolo SJ, Balderston RA, et al: Placement of pedicle screws in the thoracic spine. Part II: An Anatomical and radiographic assessment. **J Bone Joint Surg (Am)** 77:1200–1206, 1995
21. Wu SS, Hwa SY, Lin LC: Management of rigid post-traumatic kyphosis. **Spine** 21:2260–2267, 1996
22. Xu R, Ebraheim NA, Ou Y, et al: Anatomic considerations of pedicle screw placement in the thoracic spine. Roy-Camille technique versus open-lamina technique. **Spine** 23:1065–1068, 1998
23. Xu R, Ebraheim NA, Shepherd ME, et al: Thoracic pedicle screw placement guided by computed tomographic measurements. **J Spinal Disord** 12:222–226, 1999
24. Yoo JU, Ghanayem A, Petersilge C, et al: Accuracy of using computed tomography to identify pedicle screw placement in cadaveric human lumbar spine. **Spine** 22:2669–2671, 1997
25. Youkilis, AS, Quint DJ, McGillicuddy JE, et al: Stereotactic navigation for placement of pedicle screws in the thoracic spine. **Neurosurgery** 48:771–779, 2001
26. Yuan HA, Garfin SR, Dickman CA, et al: A historical cohort study of pedicle screw fixation in thoracic, lumbar, and sacral spinal fusions. **Spine** 19:S2279–S2296, 1994

Manuscript received November 28, 2001.

Accepted in final form May 14, 2002.

Address reprint requests to: Andrew T. Dailey, M.D., Department of Neurosurgery, University of Utah, 30 North 1900 East, Suite 3B409 SOM, Salt Lake City, Utah 84132. email: andrew.dailey@hsc.utah.edu.