

Treatment of Herpes Simplex Labialis

Spotswood L Spruance and John D Kriesel, Division of Infectious Diseases, University of Utah School of Medicine, Salt Lake City, UT, USA.

HERPES SIMPLEX LABIALIS IS A CONSIDERABLE PHYSICAL AND PSYCHOLOGICAL PROBLEM FOR THOSE WHO SUFFER FROM FREQUENT RECURRENCES. DRs SPOTSWOOD SPRUANCE AND JOHN KRIESEL PRESENT A COMPREHENSIVE REVIEW OF THE LITERATURE THAT HAS SOUGHT TO IDENTIFY EFFECTIVE EPISODIC AND PROPHYLACTIC TREATMENT OF THIS CONDITION

KEY WORDS

■ HERPES SIMPLEX LABIALIS ■ ACICLOVIR ■ FAMCICLOVIR
■ PENCICLOVIR ■ VALACICLOVIR ■ TREATMENT

SUMMARY

Recurrent herpes simplex labialis is associated with mild morbidity, but remains a significant problem for people with frequent and/or severe recurrences. Both topical and peroral episodic antiviral treatments of recurrences are modestly effective at reducing the duration of signs and symptoms. Recent studies with high-dose, short-course valaciclovir suggest that maximum benefit from antiviral therapy may be achieved with as little as 1 day of treatment. Topical steroids may be useful in combination with an antiviral agent, but more needs to be learnt about the appropriate strength and duration of steroid therapy before a general recommendation can be made. Selected subgroups of patients are candidates for prophylactic treatment with perorally administered nucleoside antiviral agents. Prophylaxis with topical agents is not effective.

Introduction

HERPES SIMPLEX LABIALIS (herpes labialis) is a common and ubiquitous infection of the skin resulting from herpes simplex virus (HSV). The vast majority of cases are due to herpes simplex virus type 1 (HSV-1), although recurrent infections due to herpes simplex virus type 2 (HSV-2) have been reported. Approximately 20–40% of the population will experience labial or perioral outbreaks of vesicular herpetic lesions.^{1–4} The frequency of these outbreaks is extremely variable, ranging from rare episodes every 5–10 years in some individuals, to monthly or even more frequent outbreaks among a small proportion of patients. The severity of the illness is most often mild, although it is uncomfortable and disfiguring (Figure 1). In a classic case of herpes labialis, six stages of the sore are recognized: prodrome (localized tingling, itching or burning at the site of infection), erythema, papule/oedema, ulcer, crust (soft debris, then hard eschar) and healed (loss of crust). Some healed lesions may show one or more minor residual abnormalities for several days including swelling, flaking of the skin and erythema before the skin is entirely normal in appearance. The psychological impact of a prominent facial infection, particularly in young patients with frequent or severe recurrences, should not be underestimated. In those with an underlying immunosuppressing disease, lesions have a longer duration and may spread to cause major morbidity. Erythema multiforme reactions may complicate episodes of herpes labialis and can be temporarily disabling (Figure 2).⁵ Lastly, herpetic keratitis and herpes encephalitis are infrequent but grave complications of orofacial HSV-1 infection.⁶

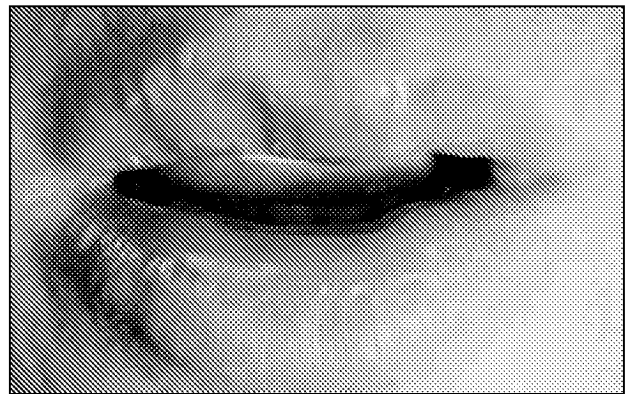

Figure 1:
Recurrent herpes labialis in the vesicle stage.

In recent years, major progress has been made in our understanding of HSV infections, and in the development of safe and effective antiviral drugs. Nucleoside analogues that inhibit HSV replication are available commercially for the treatment of herpetic keratitis, herpes genitalis, herpes labialis, mucocutaneous HSV infections in immunosuppressed hosts, neonatal herpes and herpes encephalitis. In the following report, the status of topical and peroral treatments for herpes labialis given either 'episodically' (at the onset of a recurrence) or chronically in the absence of lesions to prevent recurrences (prophylaxis) are reviewed.

Episodic or prophylactic treatment with antiviral drug therapy is the current standard care for recurrent herpes




Figure 2:
Erythema multiforme on the hand developing several days after an episode of herpes labialis.

Table 1: Some over-the-counter medicines available for topical treatment of herpes labialis in the USA

- Anbesol® gel (Wyeth, Madison, NJ)
- Blistex® lip ointment (Blistex, Inc., Oak Brook, IL)
- Campho-Phenique® (Bayer Corporation, Pittsburgh, PA)
- Herpecin-I® (Chattem, Inc., Chattanooga, TN)
- Viractin® (JB Williams Co., New Jersey, NJ)
- Zilactin® (Zila Pharmaceuticals, Inc., Phoenix, AZ)
- Abreva® (Avanir Pharmaceuticals, San Diego, CA)

labialis infections. A variety of topical over-the-counter (OTC) preparations are also available (Table 1), but in the majority of cases the mechanism of action is not clear, and rigorous clinical trials to define efficacy have not been performed. Abreva® (n-docosanol 10% cream) is the most intensively studied OTC product to date, and has recently been approved for OTC sale in the USA. Two large trials were performed, one in which Abreva® had no benefit, and another in which there was a small positive effect (Table 2). The mechanism of action of n-docosanol is unclear.^{7,8}

Topical Antiviral Therapy

Demonstration of the clinical efficacy of topical formulations of antiviral drugs among

immunocompetent patients has been difficult. Lesion severity varies markedly and necessitates large numbers of patients, natural healing of lesions is rapid, and it is difficult to find a topical drug formulation that facilitates skin penetration without causing undue skin irritation.⁹⁻¹¹ The results of recent trials are summarized in Table 2.

ACICLOVIR

Studies of aciclovir ointment in immunocompetent individuals have provided little to no evidence of efficacy.¹²⁻¹⁵ Aciclovir ointment was effective for herpes labialis in immunocompromised patients, however, and has been approved for this indication in the USA.¹⁶

Aciclovir was shown to penetrate human skin more effectively in cream rather than ointment formulation.¹⁷ Accordingly, data supporting the efficacy of aciclovir cream have been obtained more readily than with the ointment, and sufficient have been gathered to support licensure in European countries, albeit the studies in the literature were small ($n=30-51$),¹⁸⁻²⁰ and one negative report has been published.²¹ Using a more robust and modern protocol, we have recently re-examined the efficacy of aciclovir cream in two large, independent clinical trials.²² The mean duration of recurrent episodes was statistically significantly shorter ($P<0.01$) with aciclovir cream (4.4 days and 4.6 days in the respective trials) than with placebo cream (4.8 days and 5.2 days, respectively). There was no effect on the frequency of aborted lesions (Table 2).

Table 2: Randomized, double-blind, placebo-controlled, parallel-group, patient-initiated studies evaluating early^a episodic topical antiviral therapy of naturally recurrent herpes labialis in immunocompetent patients

Study	Treatment arms	Total study population (n)	Reduction in healing time compared with placebo (%) ^b		Other findings
			All patients	Classical ^c lesions	
Spruance <i>et al.</i> , 1990 ⁴¹	Idoxuridine 15% in dimethyl sulphoxide or dimethyl sulphoxide or water every 3 hours for 4 days	301	NS	38	Reduced symptoms
Spruance <i>et al.</i> , 1997 ¹¹	Penciclovir 1% cream or drug vehicle every 2 hours for 4 days	1573	ND	13-17	Reduced symptoms Reduced virus shedding
Boon <i>et al.</i> , 2000 ²⁴	Penciclovir 1% cream or water every 2 hours for 4 days	541	13	19	Reduced lesion area Reduced symptoms
Anonymous, 1996 ⁴²	n-docosanol 10% cream or stearic acid-containing cream ^d	846	NS	ND	None
Sacks <i>et al.</i> , 2001 ⁴³	n-docosanol 10% cream or polyethylene glycol ointment control every 3 hours until healing	743	15	1	Reduced symptoms
Spruance <i>et al.</i> , 2001 ²²	Aciclovir 5% cream or drug vehicle every 3 hours for 4 days	1385	10-12	10-12	Reduced symptoms

^aInitiation of treatment in the prodromal or erythema lesion stage.

^bHealing time was usually measured from the start of treatment to the cessation of all signs and symptoms for 'all patients', and from the start of treatment to the loss of crust for 'classical lesions'. Numbers given were statistically significant but may have been secondary end-points. Where more than one study was performed, the combined results are presented.

^cClassical lesions are those that progress to the vesicle, ulcer and/or crust stage.

^dThe dosing frequency was not reported in this study.

NS, not significant; ND, not done.

PENCICLOVIR

Penciclovir cream improved lesion healing in two randomized, double-blind trials, and was approved for the treatment of herpes labialis in the USA and other countries.^{11,23} Healing time was reduced by 13–17% compared with vehicle cream control ($P<0.001$). A further study of penciclovir cream was performed to see if the vehicle cream control used in these trials had a beneficial effect on herpes labialis healing, confounding the exact benefits attributable to penciclovir.²⁴ In this follow-up trial, penciclovir cream was compared with a purified water control for the treatment of sun-induced recurrences. The cream reduced median time-to-lesion healing by 1.1 days or 19% ($P=0.001$; Table 2). In the sun-induced study, there was a greater magnitude of benefit (1.1 days) than in the registration trials (0.7 days). Sun-induced lesions are more severe than herpes labialis from other causes, however, such that the reduction in lesion duration was approximately the same in the two studies (13–17%¹¹ versus 19%²⁴). These data provide evidence that the penciclovir cream vehicle does not have confounding antiviral or wound-healing properties, substantiating the outcome of the registration trials.

Peroral Antiviral Therapy

Peroral therapy of herpes labialis was investigated when it became apparent that topical therapy might be limited by poor penetration of nucleoside antivirals through the stratum corneum. To date, the two agents that have been studied are aciclovir and valaciclovir (Table 3).

Raborn *et al.*²⁵ treated patients through three consecutive episodes of herpes labialis with peroral aciclovir (200 mg five times daily for 5 days). The healing time of classical lesions was reduced by 12–17% compared with placebo control. This difference was statistically significant for the first two episodes, and there was a trend in the third. Aciclovir had a dramatic effect (30–40% reduction in healing time) on the severity of secondary lesions (those appearing after the onset of the first lesion and thus developing during therapy), demonstrating the critical relationship of efficacy to the timing of therapy. Spruance *et al.*²⁶ used higher doses of aciclovir (400 mg five times daily for 5 days), and reduced

healing time by 27% compared with placebo ($P=0.03$) in patients who started treatment in the prodrome or erythema lesion stage. In neither of these two peroral aciclovir studies did treatment abort lesion development.

In two studies, Spruance *et al.*²⁷ examined the feasibility of a high-dose, short-course oral regimen of valaciclovir for the acute treatment of herpes labialis. Participants were randomized to one of three treatment arms (valaciclovir 2000 mg twice daily for 1 day; valaciclovir 2000 mg twice daily for 1 day, then 1000 mg twice daily for 1 day; or placebo), and were instructed to begin treatment within 1 hour of the first prodromal symptom and before the development of any signs of the disease. For the two studies, the mean healing times of classical lesions for 1 day of valaciclovir treatment were 4.8 and 5.1 days, respectively; for 2 days of treatment, 5.0 and 5.2 days, respectively; and for 2 days of placebo treatment, 6.1 and 6.4 days, respectively (all comparisons with placebo were statistically significantly different, but 1 and 2 days of active treatment were not different). When the data from the two studies were combined, there was a statistically significant increase in the frequency of aborted lesions among the valaciclovir-treated patients.

Treatment of Experimental Ultraviolet Radiation-induced Herpes Labialis

We developed a technique for the systematic induction of herpes labialis with experimental ultraviolet radiation (UVR) in susceptible volunteers.²⁸ Using this technique, approximately 50% of exposed individuals develop lesions. The purpose of the model was to provide a rapid and sensitive means of testing new treatments for herpes labialis, and to study the relationship between drug efficacy and the timing of therapy. Since 1985, we have studied a variety of topical and systemic antiviral and anti-inflammatory agents in this model (Table 4). The efficacy of therapy in the UVR-induced model has generally been more favourable than in field trials because of the greater severity of UVR-induced lesions, the ability to select therapy-sensitive lesions and ensure early initiation of treatment. As shown in Table 4,

Table 3: Randomized, double-blind, placebo-controlled, parallel-group, patient-initiated studies evaluating early^a episodic peroral antiviral therapy of naturally recurrent herpes labialis in immunocompetent patients

Study	Treatment arms	Total study population (n)	Reduction in healing time compared with placebo (%) ^b		Other findings
			All patients	Classical ^c lesions	
Raborn <i>et al.</i> , 1987 ²⁵	Aciclovir 200 mg or placebo capsule five times daily for 5 days	149	NS	12–17	None
Spruance <i>et al.</i> , 1990 ²⁶	Aciclovir 400 mg or placebo capsule five times daily for 5 days	174	NS	27 symptoms	Reduced
Spruance <i>et al.</i> , 2002 ²⁷	Valaciclovir 2000 mg twice daily for 1 day, or valaciclovir 2000 mg twice daily for 1 day and 1000 mg twice daily for a second day, or placebo capsules	1856	1-day treatment 16–18 2-day treatment 13	1-day treatment 20–21 2-day treatment 18–19	Reduced symptoms More aborted lesions

^aInitiation of treatment in the prodromal or erythema lesion stage.

^bHealing time was usually measured from the start of treatment to the cessation of all signs and symptoms for 'all patients', and from the start of treatment to the loss of crust for 'classical lesions'. Numbers given were statistically significant but may have been secondary end-points. Where more than one study was performed, the combined results are presented.

^cClassical lesions are those that progress to the vesicle, ulcer and/or crust stage.
NS, not significant.

Table 4: Randomized, double-blind, placebo-controlled, parallel-group, patient-initiated studies evaluating antiviral therapy of experimental ultraviolet radiation-induced herpes labialis in immunocompetent patients

Study	Treatment arms	Total study population (n)	Timing of treatment in relation to onset of lesion	Reduction in healing time compared with control (%) ^a		Other findings
				All patients	Classical ^b lesions	
Spruance <i>et al.</i> , 1991 ²⁸	Aciclovir 200 mg or placebo capsules five times daily for 5 days	15	2 days after irradiation	35	48	Reduced lesion area (66%)
Bernstein <i>et al.</i> , 1997 ³²	Foscarnet 3% cream or vehicle cream ^c	125	Immediately after irradiation	NS	18	Reduced lesion area (43%)
Spruance <i>et al.</i> , 1999 ²⁹	Famciclovir 125 mg, 250 mg, 500 mg or placebo capsules three times daily for 5 days	102	2 days after irradiation	ND	125 mg NS 250 mg NS 500 mg 48	The highest dose reduced lesion area (60%)
Spruance and McKeough, 2000 ³⁰	Famciclovir 500 mg plus topical corticosteroid three times daily for 5 days or famciclovir 500 mg plus topical vehicle control three times daily for 5 days	29	At first sign or symptom of a lesion	ND	NS	Reduced symptoms Reduced lesion area (70%)
Evans <i>et al.</i> , 2002 ⁴⁴	Aciclovir 5%/ hydrocortisone 1% cream or vehicle cream ^c	120	2 days after irradiation	ND	10	More aborted lesions (29%)

^aHealing time was usually measured from the start of treatment to the cessation of all signs and symptoms for 'all patients', and from the start of treatment to the loss of crust for 'classical lesions'. Numbers given were statistically significant but may have been secondary end-points. Where more than one study was performed, the combined results are presented.

^bClassical lesions are those that progress to the vesicle, ulcer and/or crust stage.

^cThe dosing frequency was not reported in this study.

NS, not significant; ND, not done.

a number of treatments have led to a reduced lesion area, while this has never been observed in field trials (trials among the general population). The sensitivity of the UVR model allows potential compounds and therapeutic strategies to be screened for further development.

Our studies showed that UVR-induced lesions developed in a bimodal fashion: an 'immediate' group (0–2 days post-irradiation) and a 'delayed' group (3–7 days post-irradiation).²⁸ The immediate lesions had the characteristic histological features of herpes labialis, but appeared to be resistant to antiviral chemotherapy. Topical therapy suppressed neither the immediate nor the delayed group, regardless of when it was initiated. Systemic therapy begun immediately after irradiation or 7 days before irradiation suppressed the delayed, but not immediate, lesions. Initiating systemic therapy 48 hours post-irradiation did not suppress the subsequent delayed lesions. Because of the latter observation, we have used systemic therapy initiated at 48 hours post-irradiation as an idealized model of early episodic therapy.

A dose-ranging study of peroral famciclovir in the UVR model was used to investigate whether the apparent limited efficacy of antivirals in the treatment of herpes labialis was an inherent feature of the illness or was due to difficulties delivering high doses of drug to the infected basal cell layer of the epidermis.²⁹ In this randomized, double-blind, placebo-controlled trial, 248 patients were exposed to UVR and treated 48 hours later with famciclovir 125 mg, 250 mg or 500 mg, or placebo three

times daily for 5 days. Of these patients, 102 developed delayed UVR-induced lesions and could be used to evaluate drug efficacy. Oral famciclovir (500 mg three times daily) produced statistically significant, dose-dependent reductions in time to healing and lesion size, reducing the lesion healing time by 48%, from 5.8 days to 3.0 days ($P=0.008$), and the maximum lesion area by 60%, from 139 mm² to 55 mm² ($P=0.009$).

To determine the potential utility of anti-inflammatory therapy in the treatment of herpes labialis, we compared the efficacy of oral famciclovir (500 mg three times daily for 5 days) plus a topical corticosteroid gel (0.05% fluocinonide, Lidex GelTM, Danbury Pharmacal, Inc., Danbury, CT, USA) with famciclovir alone as episodic treatment in a randomized, double-blind study of 29 patients with UVR-induced recurrent herpes labialis.³⁰ Therapy was applied within 1 hour of the appearance of the first signs or symptoms of a recurrence. The combination treatment reduced the maximum lesion size by 70%, from 162 mm² to 48 mm² ($P=0.02$), and the proportion of patients with lesion pain from 100% to 59% ($P=0.02$) compared with famciclovir monotherapy. There was also a trend towards more aborted lesions with combination treatment than with famciclovir alone (41% versus 8%, respectively; $P=0.09$). The increased benefit seen in the topical corticosteroid arm suggests that combination antiviral/anti-inflammatory therapy is a promising new area for clinical research in herpes labialis.

Prophylactic Antiviral Chemotherapy

Prophylactic peroral chemotherapy for herpes labialis can be an effective and appropriate management strategy for selected patients. Those who should be considered for this approach include: patients with frequent recurrent episodes (≥ 6 episodes/year); patients with a history of herpes-associated erythema multiforme; patients anticipating a period of intense sun exposure or stress; patients undergoing surgical procedures on the trigeminal ganglion for relief of tic douloureux; persons undergoing peri- or intraoral surgeries such as laser, chemical or abrasive cosmetic facial resurfacing; immunocompromised patients; patients with herpes gladiatorum; selected healthcare professionals to lower the potential for virus transmission; and selected persons in the advertising, television and entertainment industries to improve facial appearance.

Both field trials and our experience with aciclovir cream and foscarnet cream in the UVR-induced herpes labialis model demonstrate that topical therapies are not effective for prophylaxis.^{28,31,32} The most likely reason for this is that topical therapy is unable to access the reactivating virus in the trigeminal ganglion. Raborn *et al.*³³ reported that prophylactic aciclovir cream reduced the frequency of herpes labialis in skiers, but this study was flawed by the potential sun-blocking activity of the drug. Aciclovir absorbs in the ultraviolet B range, such that the stimulus to reactivation would be reduced in the aciclovir cream recipients.

Despite its frequency, the industry has paid little attention to prophylaxis of herpes labialis compared with the research invested in the prevention of genital herpes. Reported experience with peroral antiviral nucleoside prophylaxis of herpes labialis is summarized in Table 5. Raborn *et al.*³⁴ were unable to prevent sun-induced herpes labialis with peroral aciclovir. Since prophylaxis may be ineffective against 'immediate' lesions occurring within the first 2 days of UVR exposure,^{28,35} their study may have been confounded by including the many individuals who were followed for only a few days. In contrast, in our study of 147 skiers, who had all experienced UVR-exposure triggered facial HSV recurrences in the past, aciclovir (400 mg twice daily) or placebo was taken 12 h before the first anticipated exposure, and continued for a maximum of 7 days.³⁵ Significantly fewer individuals receiving aciclovir developed lesions than placebo recipients (7% versus 26%, respectively; $P=0.001$). For unknown reasons, the overall results are less impressive than those seen with similar doses in the prophylaxis of genital herpes. It would be valuable to perform a dose-ranging study to see if higher doses might be more effective.³⁶

Rooney *et al.*³⁷ reported a study in which 22 patients with six or more recurrences of herpes labialis a year received either 400 mg aciclovir or placebo twice daily for 4 months. There was a 53% decrease in the number of outbreaks for those on aciclovir, from 1.80 episodes every 4 months with placebo to 0.85 episodes every 4 months with aciclovir ($P=0.009$). Outbreaks of herpes labialis have also been prevented by valaciclovir 500 mg once daily.²⁷ In a double-blind trial of suppressive oral valaciclovir, 40 patients received either valaciclovir 500 mg once daily or placebo for 4 months; valaciclovir significantly prolonged the time to first recurrence compared with placebo (mean, 16.7 weeks versus 10.6 weeks, respectively; $P=0.005$). There were also trends in favour of valaciclovir in the number of individuals experiencing a recurrence (35% versus 70%; $P=0.056$) and the number of recurrences per individual per month (0.08 versus 0.17; $P=0.066$).

Conclusions

In the past 30 years, many significant advances have been made in our understanding of the pathogenesis of herpes labialis and in our ability to manage this infection episodically and prophylactically with antiviral chemotherapy. The predominant cause of herpes labialis is HSV-1. HSV-2 may also infect the oral cavity, but viral latency and/or reactivation appear to occur much less readily in the trigeminal ganglion than the sacral sensory ganglia for this virus type. A recurrence of herpes labialis develops and matures very rapidly, reaching maximum severity within 8–16 hours of onset, leaving only a small window of opportunity to intervene with chemotherapy.⁹

The efficacy of nucleoside antiviral agents is lower in herpes labialis than in herpes genitalis, regardless of whether it is administered episodically or prophylactically. Higher doses of nucleoside antiviral agents may be required to achieve a comparable effect, such as in our recent trial of high-dose valaciclovir.²⁷ In contrast, a dose-ranging study of famciclovir in recurrent herpes genitalis found that doses above 125 mg twice daily had no additional benefit.³⁸ In both diseases, there is growing evidence that only short treatment courses are necessary for the episodic treatment of recurrences.^{27,39,40}

More media, industry and public health attention has been directed towards herpes genitalis than labialis. This is probably due to the psychological trauma of genital herpes, the greater efficacy of antiviral agents, the voice of advocacy groups, and the existence of public health sexually transmitted diseases programmes. Based on the number of persons with the illness and the severity of the potential complications, however, research in orofacial

Table 5: Randomized, double-blind, placebo-controlled studies evaluating peroral antiviral prophylaxis of recurrent herpes labialis

Study	Study design	Treatment arms	Total study population (n)	Reduction in the frequency of recurrences compared with placebo (%)
Spruance <i>et al.</i> , 1988 ³⁵	Parallel-group short-term prophylaxis during ski vacations	Aciclovir 400 mg or placebo twice daily for 7 days	147	73
Rooney <i>et al.</i> , 1993 ³⁷	Long-term crossover study	Aciclovir 400 mg or placebo twice daily for 4 months	22	53
Raborn <i>et al.</i> , 1998 ³⁴	Parallel-group short-term prophylaxis during ski vacations	Aciclovir 800 mg or placebo twice daily for 3–7 days	239	NS
Baker <i>et al.</i> , 2000 ⁴⁵	Long-term parallel-group study	Valaciclovir 500 mg or placebo once daily for 4 months	40	53

NS, not significant.

herpes infection should be given equal consideration. Important areas for future research should include optimization of antiviral prophylaxis and development of a suitable vaccine.

Address for correspondence:
 Dr Spotswood L Spruance, Division of Infectious Diseases, School of Medicine, Room 4B319, University of Utah, 30 North 1900 East, Salt Lake City, UT 84132-2405, USA.

E-mail: woody.spruance@hsc.utah.edu

Received for publication: 14 June 2002

Accepted for publication: 5 August 2002

REFERENCES

- Ship II, Morris AL, Durocher RT, Burket LW. Recurrent aphthous ulcerations and recurrent herpes labialis in a professional school student population. *Oral Surg Oral Med Oral Pathol* 1960;**13**: 1191-1202.
- Embil JA, Stephens RG, Manuel FR. Prevalence of recurrent herpes labialis and aphthous ulcers among young adults on six continents. *Can Med Assoc J* 1975;**113**:627-630.
- Crout P, Barber VE. Cold sores - an epidemiologic survey. *J Roy Coll Gen Pract* 1976;**26**:428-434.
- Young SK, Rowe NH, Buchanan RA. A clinical study for the control of facial mucocutaneous herpes virus infections. I. Characterization of natural history in a professional school population. *Oral Surg Oral Med Oral Pathol* 1976;**41**:498-507.
- Huff JC. Erythema multiforme and latent herpes simplex infection. *Semin Dermatol* 1992;**11**:207-210.
- Stanberry LR, Cunningham AL, Mindel A, Scott LL, Spruance SL, Aoki FY *et al*. Prospects for control of herpes simplex virus disease through immunization. *Clin Infect Dis* 2000;**30**:549-566.
- McKeough MB, Spruance SL. Comparison of new topical treatments for herpes labialis: efficacy of penciclovir cream, acyclovir cream, and n-docosanol cream against experimental cutaneous herpes simplex virus type 1 infection. *Arch Dermatol* 2001;**137**: 1153-1158.
- Khalil MH, Marcellotti JF, Katz LR, Katz DH, Pope LE. Topical application of docosanol- or stearic acid-containing creams reduces severity of phenol burn wounds in mice. *Contact Dermatitis* 2000;**43**:79-81.
- Spruance SL, Wenerstrom G. Pathogenesis of herpes simplex labialis: IV. Maturation of lesions within 8 hours after onset and implications for antiviral treatment. *Oral Surg Oral Med Oral Pathol* 1984;**58**: 667-671.
- Spruance SL, McKeough MB, Sugibayashi K, Robertson F, Gaede P, Clark DS. Effect of azone and propylene glycol on penetration of trifluorothymidine through skin and the efficacy of different topical formulations against cutaneous herpes simplex virus infection in guinea pigs. *Antimicrob Agents Chemother* 1984;**26**:819-823.
- Spruance SL, Rea TL, Thoming C, Tucker R, Saltzman R, Boon R. Penciclovir cream for the treatment of herpes simplex labialis. A randomized, multicenter, double-blind, placebo-controlled trial. Topical Penciclovir Collaborative Study Group. *JAMA* 1997;**277**: 1374-1379.
- Spruance SL, Schnipper LE, Overall JC, Jr, Kern ER, Wester B, Modlin J *et al*. Treatment of herpes simplex labialis with topical acyclovir in polyethylene glycol. *J Infect Dis* 1982;**146**: 85-90.
- Spruance SL, Grumpacker CS, Schnipper LE, Kern ER, Marlow S, Arndt KA *et al*. Early, patient-initiated treatment of herpes labialis with topical 10% acyclovir. *Antimicrob Agents Chemother* 1984;**25**:553-555.
- Raborn GW, McGaw WT, Grace M, Houle L. Herpes labialis treatment with acyclovir 5 per cent ointment. *Can Dent Assoc J* 1989;**55**:135-137.
- Fiddian AP, Ivanyi L. Topical acyclovir in the management of recurrent herpes labialis. *Br J Dermatol* 1983;**109**:321-326.
- Whitley RJ, Levin M, Barton N, Hershey BJ, Davis G, Keeney RE *et al*. Infections caused by herpes simplex virus in the immunocompromised host: natural history and topical acyclovir therapy. *J Infect Dis* 1984;**150**: 323-329.
- Freeman DJ, Sheth NV, Spruance SL. Failure of topical acyclovir (aciclovir) in ointment to penetrate human skin. *Antimicrob Agents Chemother* 1986;**29**:730-732.
- Raborn GW, McGaw WT, Grace M, Percy J, Samuels S. Herpes labialis treatment with acyclovir 5% modified aqueous cream: a double-blind, randomized trial. *Oral Surg Oral Med Oral Pathol* 1989;**67**:676-679.
- Fiddian AP, Yeo JM, Stubbings R, Dean D. Successful treatment of herpes labialis with topical acyclovir. *Br Med J* 1983;**286**: 1699-1701.
- Van Vloten WA, Swart RNJ, Pot F. Topical acyclovir therapy in patients with recurrent orofacial herpes simplex infections. *J Antimicrob Chemother* 1983;**12**:89-93.
- Shaw M, King M, Best JM, Banatvala JE, Gibson JR, Klaber MR. Failure of acyclovir cream in treatment of recurrent herpes labialis. *Br Med J* 1985;**291**:7-9.
- Spruance SL, Johnson J, Spaulding T and Aciclovir Cream Study Group. Acyclovir cream for the treatment of herpes simplex labialis: the results of two double-blind, placebo-controlled trials (abstract). *Antiviral Res* 2001;**49**:A60.
- Raborn GW, Martel AY, Lassonde M, Lewis MA, Boon R, Spruance SL. Effective treatment of herpes simplex labialis with penciclovir cream: combined results of two trials. *J Am Dent Assoc* 2002;**133**: 303-309.
- Boon R, Goodman J, Martinez J, Marks GL, Gamble M, Welch C *et al*. Penciclovir cream for the treatment of sunlight-induced herpes simplex labialis: a randomized, double-blind, placebo-controlled trial. *Clin Ther* 2000;**22**:76-90.
- Raborn GW, McGaw WT, Grace M, Tyrrell LD, Samuels SM. Oral acyclovir and herpes labialis: a randomized, double-blind, placebo-controlled study. *J Am Dent Assoc* 1987;**115**:38-42.
- Spruance SL, Stewart JCB, Rowe NH, McKeough MB, Wenerstrom G, Freeman DJ. Treatment of recurrent herpes simplex labialis with oral acyclovir. *J Infect Dis* 1990;**161**:185-190.
- Spruance SL, Jones TM, Blatter MM, Vargas-Cortes M, Barber J, Goldstein D *et al*. Oral valaciclovir for the treatment of herpes labialis: two trials of early, high-dose, short-course therapy (abstract). *Antiviral Res* 2002;**53**:A53.
- Spruance SL, Freeman DJ, Stewart JCB, McKeough MB, Wenerstrom LG, Krueger GG *et al*. The natural history of ultraviolet radiation-induced herpes simplex labialis and response to therapy with peroral and topical formulations of acyclovir. *J Infect Dis* 1991;**163**:728-734.
- Spruance SL, Rowe NH, Raborn GW, Thibodeau EA, D'Ambrosio JA, Bernstein DI. Peroral famciclovir in the treatment of experimental ultraviolet radiation-induced herpes simplex labialis: a double-blind, dose-ranging, placebo-controlled, multicenter trial. *J Infect Dis* 1999;**179**:303-310.
- Spruance SL, McKeough MB. Combination treatment with famciclovir and a topical corticosteroid gel versus famciclovir alone for experimental ultraviolet radiation-induced herpes simplex labialis: a pilot study. *J Infect Dis* 2000;**181**: 1906-1910.
- Spruance SL. Prophylactic chemotherapy with acyclovir for recurrent herpes simplex labialis. *J Med Virol* 1993;**41** (Suppl 1): 27-32.
- Bernstein DI, Schleupner CJ, Evans TG, Blumberg DA, Bryson Y, Grafford K *et al*. Effect of foscarnet cream on experimental UV radiation-induced herpes labialis. *Antimicrob Agents Chemother* 1997;**41**:1961-1964.
- Raborn GW, Martel AY, Grace MG, McGaw WT. Herpes labialis in skiers: randomized clinical trial of acyclovir cream versus placebo. *Oral Surg Oral Med Oral Pathol Oral Radiol Endod* 1997;**84**:641-645.
- Raborn GW, Martel AY, Grace MG, McGaw WT. Oral acyclovir in prevention of herpes labialis. A randomized, double-blind, multi-centered clinical trial. *Oral Surg Oral Med Oral Pathol Oral Radiol Endod* 1998;**85**: 55-59.
- Spruance SL, Hammil ML, Hoge WS, Davis G, Mills J. Acyclovir prevents reactivation of herpes labialis in skiers. *JAMA* 1988;**260**:1597-1599.
- Reitano M, Tyring S, Lang W, Thoming C, Worm AM, Borrelli S *et al*. Valaciclovir for the suppression of recurrent genital herpes simplex virus infection: a large-scale dose range-finding study. International Valaciclovir HSV Study Group. *J Infect Dis* 1998;**178**:603-610.
- Rooney JF, Straus SE, Mannix ML, Wohlenberg CR, Ailing DW, Dumois JA *et al*. Oral acyclovir to suppress frequently recurrent herpes labialis. A double-blind, placebo-controlled trial. *Ann Intern Med* 1993;**118**:268-272.
- Sacks SL, Aoki FY, Diaz-Mitoma F, Sellors J, Shafan S, Romanowski B *et al* and Canadian Cooperative Study Group. Patient-initiated treatment of recurrent genital herpes with oral famciclovir: a Canadian, multicenter, placebo-controlled, dose-ranging study (abstract). *Program and Abstracts of the Interscience Conference on Antimicrobial Agents and Chemotherapy* 1994;**34**:11.
- Sacks SL, Shafan SD, Diaz-Mitoma F, Trottier S, Sibbald RG, Hughes A *et al*. A multicenter phase I/III dose escalation study of single-dose cidofovir gel for treatment of recurrent genital herpes. *Antimicrob Agents Chemother* 1996;**42**:2996-2999.
- Leone PA, Trottier S, Miller JM. Valacyclovir for episodic treatment of genital herpes: a shorter 3-day treatment course compared with 5-day treatment. *Clin Infect Dis* 2002;**34**:958-962.
- Spruance SL, Stewart JCB, Freeman DJ, Brightman VI, Cox JL, Wenerstrom G *et al*. Early application of topical 15% idoxuridine in dimethyl sulfoxide shortens the course of herpes simplex labialis: a multicenter placebo-controlled trial. *J Infect Dis* 1990;**161**: 191-197.
- Anonymous. Topical Lidakol Phase III trials for oral HSV fail to show efficacy vs placebo. *Antiviral Agents Bull* 1996;**9**: 104-105.
- Sacks SL, Thisted RA, Jones T, Barbarash RA, Mikolich D, Ruoff G *et al*. Clinical efficacy of topical docosanol 10% cream for herpes simplex labialis: a multicenter, randomized, placebo-controlled trial. *J Am Acad Dermatol* 2001;**45**: 222-230.
- Evans TG, Bernstein DI, Raborn GW, Harmerberg J, Kowalski J, Spruance SL. Double-blind, randomized, placebo-controlled study of topical 5% acyclovir-1% hydrocortisone cream (ME-609) for treatment of UV radiation-induced herpes labialis. *Antimicrob Agents Chemother* 2002;**46**:1870-1874.
- Baker DA, Deeter RG, Redder K, Phillips JA. Valaciclovir effective for suppression of recurrent HSV-1 herpes labialis (abstract). *Proceedings of 40th Interscience Conference on Antimicrobial Agents and Chemotherapy*, Toronto, Canada, 2000;p263.