

#6

**ORIGINAL CONTRIBUTION****Utility of Helical Computed Tomography in Differentiating Unilateral and Bilateral Facet Dislocations**

Andrew T. Dailey, MD¹; Christopher I. Shaffrey, MD²; Raja Rampersaud, MD³; Joonyung Lee, MD⁴; Darrel S. Brodke, MD⁵; Paul Arnold, MD⁶; Ahmad Nassr, MD⁷; James S. Harrop, MD⁸; Jonathan Grauer, MD⁹; Christopher M. Bono, MD¹⁰; Marcel Dvorak, MD¹¹; Alexander Vaccaro, MD¹²

¹Department of Neurosurgery, University of Utah, Salt Lake City, Utah; ²Department of Neurosurgery, University of Virginia, Charlottesville, Virginia; ³Department of Surgery, Division of Orthopedics and Neurosurgery, University of Toronto, Toronto, Ontario; ⁴Department of Orthopedic Surgery, University of Pittsburgh, Pittsburgh, Pennsylvania; ⁵Department of Orthopedics, University of Utah, Salt Lake City, Utah; ⁶Department of Neurosurgery, University of Kansas, Kansas City, Kansas; ⁷Department of Orthopedic Surgery, Mayo Clinic, Rochester, Minnesota; ⁸Department of Neurosurgery, Thomas Jefferson University, Philadelphia, Pennsylvania; ⁹Department of Orthopedic Surgery, Yale University, New Haven, Connecticut; ¹⁰Department of Orthopedic Surgery, Brigham and Women's Hospital, Boston, Massachusetts; ¹¹Department of Orthopedic Surgery, University of British Columbia, Vancouver, British Columbia; ¹²Department of Orthopedic Surgery, Thomas Jefferson University, Philadelphia, Pennsylvania

Received February 11, 2008; accepted July 21, 2008

Abstract

Objective: Diagnosis of cervical facet dislocation is difficult when relying on plain radiographs alone. This study evaluates the interobserver reliability of helical computed tomography (CT) in the assessment of cervical translational injuries, correlates the radiographic diagnosis with intraoperative observation, and examines the role of neurologic injury in the evaluation and diagnosis of these injuries.

Methods: Clinical histories and radiographic studies of 10 patients with cervical facet dislocations were presented to 25 surgeons. Participants classified cases as unilateral or bilateral facet dislocations after reviewing selected axial CT slices and sagittal reconstructions. Surgeons' interpretations were compared with intraoperative diagnosis. Participants interpreted the same radiographic studies with 3 different clinical scenarios: neurologically intact, incomplete, and complete spinal cord injury. Vertebral body translation from midsagittal CT was evaluated to confirm whether all unilateral facet dislocations had <25% translation.

Results: Interrater κ coefficient showed moderate agreement between observers in classifying injuries as unilateral or bilateral (κ : 0.54–0.58), regardless of neurologic status. Percent agreement among observers varied from 50% to 100% for each individual case. Agreement was statistically higher for bilateral facet dislocation (85%) than for unilateral dislocations (78%), with 1 unilateral fracture showing nearly 50% translation on a midsagittal image.

Conclusions: The addition of helical CT to reconstruction enables spine surgeons to more reliably distinguish bilateral from unilateral cervical facet dislocations. Despite frequent occurrence of these injuries and presumed agreement on injury description, agreement may be improved by a more precise definition of facet dislocations and subluxations and thorough review of all imaging studies.

J Spinal Cord Med. Feb 2009;32(1):43–48

Key Words: Spine, cervical; Facet dislocation; Imaging; Computed tomography; Trauma, spinal

INTRODUCTION

Facet dislocations of the cervical spine have the potential to cause devastating neurologic injuries. Patients need

prompt evaluation and clear identification of the type and extent of the injury. Radiographic evaluation of the patient with suspected cervical spine fracture has traditionally consisted of a cross-table lateral view supplemented as necessary by additional plain radiographic views (1–3). Historically, cervical dislocations have been artificially categorized by defining them as either unilateral or bilateral. Although magnetic resonance imaging (MRI) studies have identified widespread

Please address correspondence to Andrew Dailey, MD, Department of Neurosurgery, University of Utah, 175 N. Medical Drive East, Salt Lake City, UT 84106; p: 801 581 6908; f: 801 581 4138 (e-mail: Andrew.dailey@hsc.utah.edu).

© 2009 by the American Paraplegia Society

soft tissue injury, the categorization and definition of particular injuries as either unilateral or bilateral remains useful (4). Translation of the cephalad vertebrae by approximately 25% of the anteroposterior diameter of the vertebral body on radiographic imaging has been used to define a unilateral facet dislocation, whereas 50% or more translation typically occurs with a bilateral facet dislocations (5,6). Some injuries can be easily appreciated on the lateral view alone; however, in some patients (up to 60%), even the addition of anterior posterior (AP), open-mouth odontoid (3-view), and oblique (5-view) radiographs may not substantially aid in discerning the injury type (7).

Computed tomography (CT) has been used as an adjunct to the 3-view plain radiograph series in the evaluation of cervical trauma with some success. Before the widespread use of 2-dimensional reformations, surgeons evaluating nonhelical CT scans often missed the presence of some cervical injuries, depending on the relationship of the plane of the axial cuts and the plane of the injury. The advent of helical CT scans, which provide more precise reconstruction in the coronal and the paramedian sagittal planes, has dramatically reduced the number of missed cervical spine injuries, with recent reports showing greater than 98% sensitivity and specificity (2,8). The improved sensitivity and accuracy of this imaging technique has led most trauma centers to conclude that helical CT, with appropriate reconstruction, is superior to plain radiography for the initial assessment and diagnosis of cervical spine injury (9,10).

Despite the improvements in diagnostic accuracy of CT imaging, confusion remains regarding the precise definitions of various cervical injuries, particularly when there is associated injury to the posterior elements. New cervical classification systems, such as the Sub-Axial Cervical Spine Injury Classification System (SLIC), rely on the accurate identification and categorization of specific morphologic injury patterns (11). The reliable identification of unilateral and bilateral facet dislocation is important to the reliability of these classification systems and thus may have therapeutic implications.

In this study, a group of surgeons with a primary interest in spine trauma (members of the Spinal Trauma Study Group) were each asked to diagnose the type of cervical translational injury as unilateral or bilateral facet dislocation based on CT with reconstructions through the facet joints. The primary purpose of this study is to measure the variability among a group of experienced spinal traumatologists when attempting to identify unilateral or bilateral facet injuries on a series of CT images and validate the radiographic diagnosis with the intraoperative findings.

METHODS

Ten cases representing either a unilateral or bilateral facet dislocation confirmed with intraoperative observation were distributed to 25 members of the Spine Trauma

Table 1. Interrater Percent Agreement for 2 Different Clinical Scenarios: Neurologically Intact and Incomplete Injuries

Patient No.	Diagnosis	Intact	Incomplete	Percent Translation
1	Unilateral	50	58	50
2	Unilateral	100	100	25
3	Bilateral	100	100	87
4	Unilateral	100	100	21
5	Unilateral	70	78	17
6	Unilateral	75	72	13
7	Bilateral	75	78	51
8	Unilateral	75	72	23
9	Bilateral	88	78	62
10	Unilateral	58	67	24
Overall reliability		77.7% agreement $\kappa = 0.535$	80.3% agreement $\kappa = 0.576^a$	

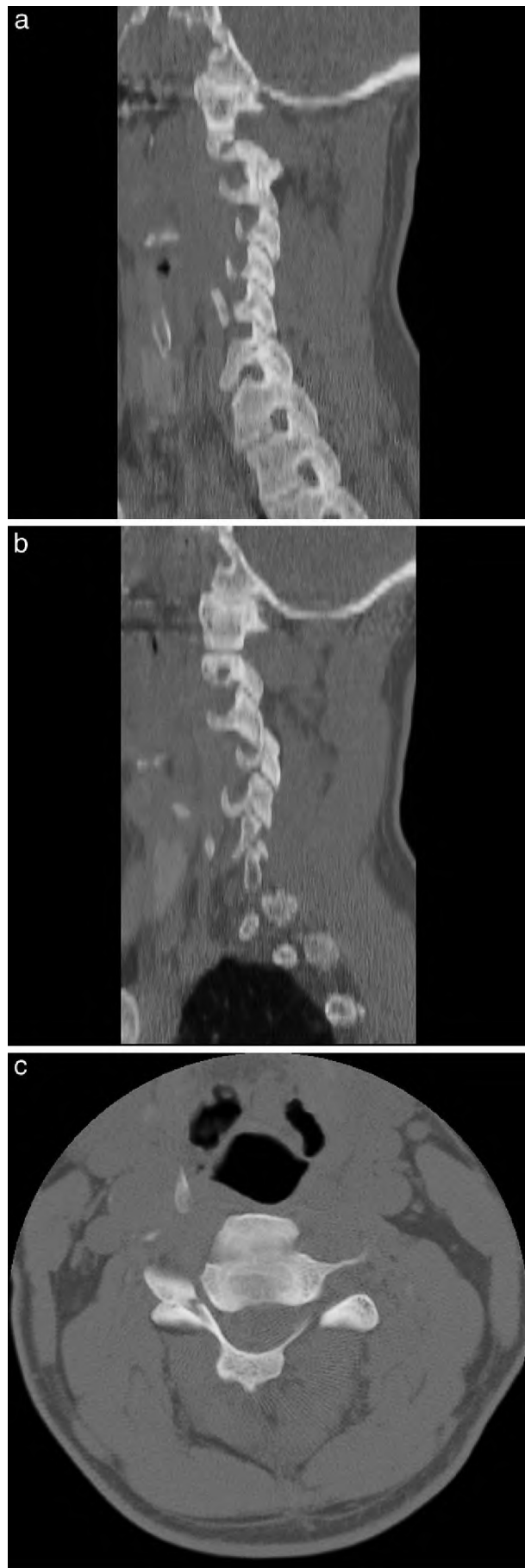Except for Case 9, there was an overall trend toward higher percent agreement when observers were presented with an incomplete or complete patient.

^a $P < 0.05$ for difference between intact and incomplete. Data for complete injuries were identical to those for incomplete injuries except for Case 9, which showed a 84% agreement in the complete scenario.

Study Group. CT examination was performed on a General Electric (GE, Fairfield, CT) multislice scanner with 4 detectors. The axial images were acquired in 2.5-mm slices and reconstructed at 2-mm intervals in the sagittal plane. CT images were supplemented with a cross-table lateral radiograph. All patient identifiers were removed from the images, which were distributed on CD-ROM as jpeg images grouped according to case number. Participants were asked to classify each injury as a unilateral or bilateral facet dislocation.

The original CT scans were examined and edited so that the best representative sections were distributed to Study Group members, consisting of 1 midline sagittal reconstruction, 2 paramedian reconstructions through both the right and left facet joints, and 2 axial cuts through the level of the involved facet articulations. Participants reviewed each case on 3 separate occasions for the different clinical presentations: a patient with neurologically complete injury, a patient with a neurologically incomplete injury, and a neurologically intact patient. To determine whether some cases were more ambiguous in the diagnosis, an interrater percent agreement was calculated for each case (Table 1). CT studies are presented for those cases with low agreement (Figures 1 and 2).

The diagnosis of unilateral facet dislocation from plain radiographs can be determined by measuring the percent translation of the superior vertebral body on that of the inferior vertebral body. More than 50% translation is generally thought to represent bilateral dislocations



and less than 25% represents unilateral dislocation (5,12). Because of the limited sensitivity of plain radiographs in acute trauma, many trauma centers have adopted CT as the primary screening method for cervical injury (9). Therefore, we examined the percent of vertebral body translation from the midline sagittal CT reconstructed image. Vertebral body width was determined from the vertebra below the dislocation and the distance of subluxation for the cephalad vertebra (13). A percentage translation was determined for each case and correlated with percent agreement among study participants (Table 1).

Interrater reliability was assessed by Cohen κ value and percent agreement among observers. In addition, the validity of the observer's diagnosis was assessed by comparison with the gold standard, which is the clinical diagnosis confirmed by intraoperative observation. The most commonly used interpretation of the κ statistic is that reported by Landis and Koch (14), in which a value of 0.41 to 0.60 indicates moderate agreement and values 0.61 to 0.80 indicate substantial agreement among observers. These standards were applied in this study. For significance tests on κ coefficient comparisons, all unweighted coefficients were converted into Fisher z-scores. Alpha level was set at 0.05 ($\Delta Z/SE \geq 1.96$). MedCalc Version 8.1 software (Mariakerke, Belgium) was used for all statistical analyses.

RESULTS

The interrater reliability among the 25 physicians responding to the survey showed moderate agreement for all clinical scenarios. When presented with a neurologically intact patient, observers were less likely to agree ($\kappa = 0.54$; 77% agreement) than when patients with incomplete and complete injuries ($\kappa = 0.58$; 80% agreement for both scenarios) were included ($P < 0.05$ for difference between intact κ and both incomplete and complete κ). Except for 1 case of a bilateral facet dislocation (Case 9), the interrater percent agreement was identical for all other cases whether participants were presented with a scenario of incomplete or complete neurologic injury. The study participants' diagnoses were compared with the known clinical diagnosis of each case presented and showed excellent agreement (intermethod $\kappa = 0.71$, 87% agreement). The agreement was

←
Figure 1. Left sagittal (a), right sagittal (b), and axial (c) CT scans of the patient in Case 1 who had a unilateral facet dislocation and a contralateral facet fracture. Percent agreement among observers was the lowest of all cases (50%), probably because of the limited number of images presented of the left C3–C4 facet on the sagittal reconstructions (a) and the involvement of the facet with a fracture (arrow, c). The facet dislocation on the right C4–C5 facet is clear on the sagittal images (b).

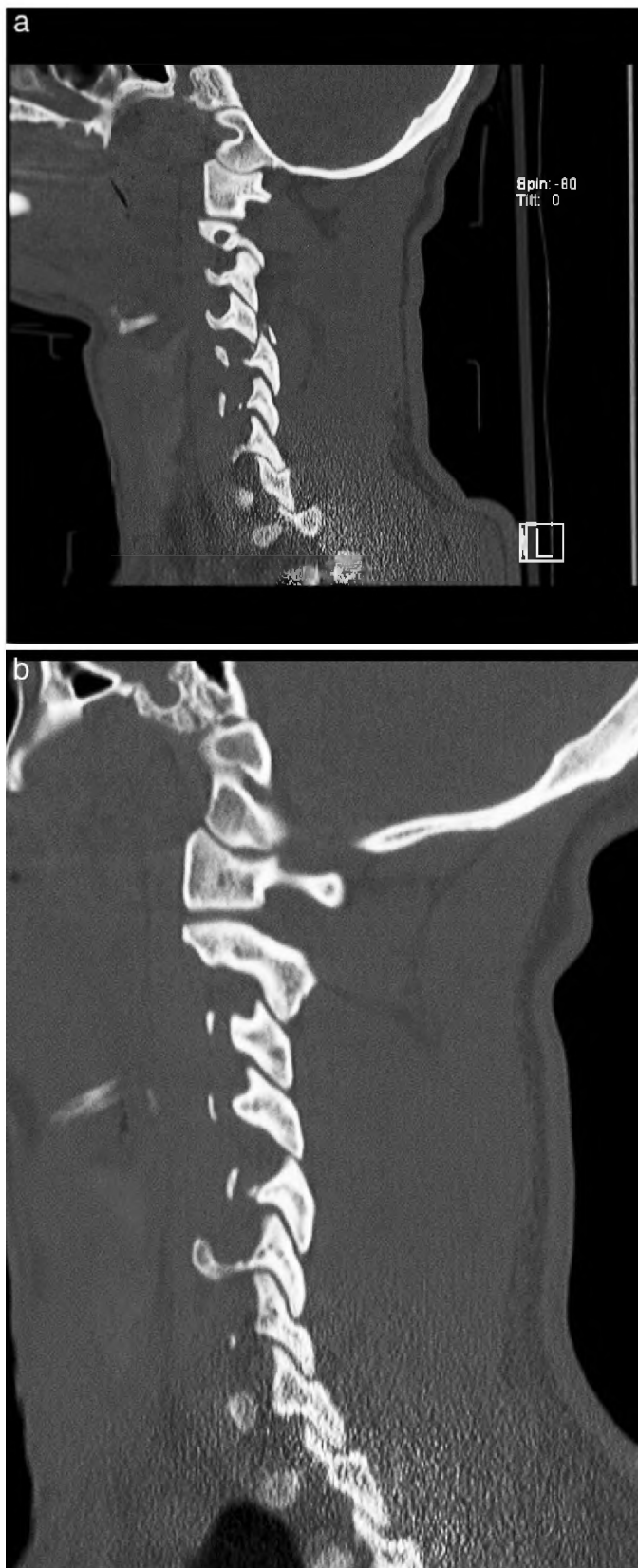


Figure 2. CT reconstructions of Case 10 show a dislocated facet on the left at C4–C5 (a) and a subluxation or perch of the facet on the right (b). The agreement among observers was only 58% because of the lack of clear differentiation of

higher for cases with a known diagnosis of bilateral facet dislocation than for cases of a known diagnosis of unilateral facet dislocation (85% agreement vs 78% agreement, $P < 0.0001$).

To determine whether specific cases provided more uncertainty in the diagnosis of unilateral or bilateral facet dislocation, reliability was calculated for each case and presented as percent agreement (Table 1). The percent agreement was compared for the intact and incomplete clinical scenarios to evaluate the effect of neurologic injury on diagnosis. Notably, the clinical scenarios of intact neurologic status had 2 cases of unilateral facet dislocation, which had agreement of 50% to 58%, whereas agreement for all other cases was 75% to 100% (Figures 1 and 2). When the degree of translation was examined for all cases, all unilateral facet dislocations had 25% or less translation except for Case 1 (50%), which also had the lowest percent agreement among the study participants.

DISCUSSION

Cervical facet fracture dislocations can result in devastating neurologic injuries, with up to 100% incidence of neurologic injury reported in most series of bilateral lesions (12,15,16). Therefore, prompt recognition and correct diagnosis are the foundations for effective treatment. The difficulties in obtaining a radiographic diagnosis in the cervical spine have been well outlined, and the standardization of measurement techniques has been an objective of the Spinal Trauma Study Group (13).

This study showed excellent agreement (87%) between a diagnosis based on helical CT with reconstructions and the actual intraoperative diagnosis. Furthermore, helical CT with reconstructions through the paramedian and midsagittal planes showed moderate correlation between observers ($\kappa > 0.54$) evaluating unilateral or bilateral facet dislocation with different degrees of neurologic injury. This contrasts with earlier radiographic studies that suggested the use of plain radiographs alone can lead to 60% of cervical spine injuries being missed (7–10). Although no interobserver reliability studies using plain radiographs alone to determine the diagnosis of facet dislocation have been reported, one might presume that the low sensitivity of plain radiographs would severely limit interobserver reliability when attempting to identify a facet dislocation. In our institutions, plain radiographs are rarely obtained and were often unavailable for review in the cases selected for this study. Although CT was initially promoted as an adjunct to clearing the cervical spine in

←
 facet dislocation from facet subluxation. The remaining apposition of the right C4–C5 facet joint led the treating physician to classify this as a unilateral facet dislocation.

the trauma patient, it has become the primary modality in the diagnosis of cervical fracture (2,8).

CT has proven more cost effective than plain radiographs for patients with the highest risk for cervical spine injury, such as the elderly and those with head injuries, distracting injuries, and injuries sustained in high-speed motor vehicle accidents, with sensitivity and specificity approaching 100% (2,17,18). McCulloch et al (10) obtained cervical spine CT and 3-view plain radiographs in 407 consecutive patients with Level 1 and 2 trauma and found that plain radiographs missed 48% of cervical fractures, whereas only 1 of 58 patients in whom a cervical fracture was ultimately diagnosed did not have the fracture identified on CT. This study supports the utility of helical CT in the identification of facet dislocations, but the moderate interobserver reliability shows that clearer definitions and classification systems are needed for surgeons to communicate effectively. To our knowledge, no studies have looked at the interobserver reliability of CT when trying to diagnose a specific injury pattern.

Although CT improves the diagnosis of cervical fractures, injuries can still be missed with its use. Most fractures that are missed on CT imaging are horizontally oriented fractures through the base of the dens or C2 (8,19), and radiologists experienced in the evaluation of trauma (18) have emphasized the need for properly oriented sagittal and coronal reconstructions. One limitation of our study is that the entire set of axial and reconstructed images was not distributed, and interpretation proved difficult if the facet contained a fracture or could not be fully visualized (Figure 2). The advantage of helical CT is rapid acquisition of a large amount of data that covers the entire anatomic area of the cervical spine and allows for review in axial, sagittal, and coronal planes. If all images are not reviewed or are not available, fractures and misalignments may be missed (20). For instance, when just a midline sagittal image is reviewed, even a relatively large percentage subluxation may correspond to a unilateral facet dislocation as seen in Case 1.

In previous work, we identified degree of neurologic injury as an important determinant of treatment modality in cervical facet dislocations (21). For instance, a neurologically intact patient with a unilateral facet injury was treated more commonly with an anterior approach, whereas a neurologic injury in the setting of a bilateral facet dislocation was thought to be better treated with a combined approach. Overall interobserver reliability was only $\kappa < 0.1$ for surgical approach in this series of cervical facet injuries. This analysis suggests that clearer treatment algorithms could be defined for facet dislocations. Part of the difficulty in determining treatment may be the difficulty in radiographic interpretation of CT imaging. Although more severe injury patterns are often assumed with greater radiographic abnormalities, the moderate interobserver reliability in all clinical scenarios suggests

that further work is needed to precisely define translational rotational injuries of the cervical spine.

The lack of standard definitions when differentiating facet subluxations from dislocations may explain our relatively modest interobserver reliability. In studies in which plain radiographs alone have been used, the authors were unable to differentiate a precise difference between dislocation and subluxation, resulting in a number of injuries not identified on cross-table lateral radiography (7,22,23). The improved imaging capabilities of CT provide more precise identification of facet injuries and can differentiate a subluxation from a dislocation. To standardize definitions of cervical spine injuries, the Spinal Trauma Study Group has proposed definitions for subluxation as a "facet joint disruption in which the inferior articular process of the cranial vertebra has translated antero-superiorly with respect to the superior articular process of the caudal vertebra with some apposition still remaining between the two surfaces." A unilateral facet dislocation is defined as "the disruption of a single facet joint in which the inferior articular process of the cranial vertebra has translated antero-superiorly completely over the superior articular process of the caudal vertebra, leaving no apposition between the two articular surfaces" (Bono CM, written manuscript in preparation, November 2008). The clarification and acceptance of these definitions will increase precise identification of cervical facet injuries and allow for increased agreement among clinicians when viewing cases where 1 facet is dislocated and the other is subluxed or dislocated (Figure 2, Case 10). Differentiation of unilateral from bilateral facet injuries may influence not only the type of management (ie, operative vs nonoperative) but also the surgical approach (21). It is our impression that standardized definitions combined with more reliable diagnostic modalities will translate into improved intra- and interobserver reliability in the classification of facet dislocations.

CONCLUSION

In summary, the use of helical CT has decreased the number of cervical injuries that are missed on radiographic evaluation. This modality provides clinicians with a means to differentiate unilateral from bilateral dislocations with moderate interobserver reliability and good validity with respect to intraoperative diagnosis. The agreement is higher in cases with bilateral dislocations than unilateral dislocations, likely because of the uncertainty when trying to determine differences of dislocation from subluxation. Further clarification and broad acceptance of precise definitions used to classify facet injuries will increase the reliability of helical CT in the diagnosis of cervical facet dislocations.

ACKNOWLEDGMENT

We thank Kristin Kraus, MSc, for editorial assistance.

REFERENCES

1. Clark CR, Igram CM, El-Khoury GY, Ehara S. Radiographic evaluation of cervical spine injuries. *Spine*. 1988;13(7):742–747.
2. Berne J, Velhams GC, El-Tawil K, et al. Value of complete cervical helical computed tomographic scanning in identifying cervical spine injury in the unevaluatable blunt trauma patient with multiple injuries: a prospective study. *J Trauma*. 1999;47:896–903.
3. Holdsworth F. Fractures, dislocations and fracture-dislocations of the spine. *J Bone Joint Surg Am*. 1970;52(8):1534–1551.
4. Vaccaro AR, Madigan L, Schweitzer ME, Flanders AE, Hilibrand AS, Albert TJ. Magnetic resonance imaging analysis of soft tissue disruption after flexion-distraction injuries of the subaxial cervical spine. *Spine*. 2001;26(17):1866–1872.
5. Beatson TR. Fractures and dislocation of the cervical spine. *J Bone Joint Surg Br*. 1963;45B:21–35.
6. Rah AD, Errico TJ. Classification of lower cervical fractures and dislocations. In: Clark CR, ed. *The Cervical Spine*. 3rd ed. Philadelphia, PA: Lippincott-Raven Publishers; 1998: 449–456.
7. Woodring JH, Lee C. Limitations of cervical radiography in the evaluation of acute cervical trauma. *J Trauma*. 1993;34(1):32–39.
8. Barba CA, Taggart J, Morgan AS, et al. A new cervical spine clearance protocol using computed tomography. *J Trauma*. 2001;51(4):652–657.
9. Daffner RH, Sciulli RL, Rodriguez A, Protetch J. Imaging for the evaluation of suspected cervical spine trauma: a 2-year analysis. *Injury*. 2006;37(7):652–658.
10. McCullogh PT, France J, Jones DL, et al. Helical computed tomography alone compared with plain radiographs with adjunct computed tomography to evaluate the cervical spine after high-energy trauma. *J Bone Joint Surg Am*. 2005;87(11):2388–2394.
11. Vaccaro AR, Hurlbert RJ, Patel AA, et al. The Sub-axial Cervical Spine Injury Classification System (SLIC): a novel approach to recognize the importance of morphology, neurology and integrity of the disco-ligamentous complex. *Spine*. 2007;(21):32:2365–2374.
12. Allen BL, Ferguson RL, Lehmann TR, O'Brien RP. A mechanistic classification of closed indirect fractures and dislocations of the lower cervical spine. *Spine*. 1982;7(1):1–27.
13. Bono CM, Vaccaro AR, Fehlings M, et al. Measurement techniques for lower cervical spine injuries: consensus statement of the Spine Trauma Study Group. *Spine*. 2006;31(5):603–609.
14. Landis JR, Koch GG. An application of hierarchical kappa-type statistics in the assessment of the majority agreement among multiple observers. *Biometrics*. 1977;33(2):363–374.
15. Maiman DJ, Barolat G, Larson SJ. Management of bilateral locked facets of the cervical spine. *Neurosurgery*. 1986;18(5):542–547.
16. O'Brien PJ, Schweigel JF, Thompson WJ. Dislocations of the lower cervical spine. *J Trauma*. 1982;22(8):710–714.
17. Blackmore CC, Deyo RA. Specificity of cervical spine radiography: importance of the clinical scenario. *Emerg Radiol*. 1997;4:283–286.
18. Blackmore CC, Mann FA, Wilson AJ. Helical CT in the primary trauma evaluation of the cervical spine: an evidence based approach. *Skeletal Radiol*. 2000;29(11):632–639.
19. Pech P, Kilgore DP, Pojunas KW, Haughton VM. Cervical spine fractures: CT detection. *Radiology*. 1985;157(1):117–120.
20. Barrett TW, Mower WR, Zucker MI, Hoffman JR. Injuries missed by limited computed tomographic imaging of patients with cervical spine injuries. *Ann Emerg Med*. 2006;47(2):129–133.
21. Nassr A, Lee JY, Dvorak MF, et al. Variations in surgical treatment of cervical facet dislocations. *Spine*. 2008;33(7):E188–E193.
22. Braakman R, Vinken PJ. Old luxations of the lower cervical spine. *J Bone Joint Surg Br*. 1968;50-B(1):52–60.
23. Scher AT. Unilateral locked facet in cervical spine injuries. *Am J Roentgenol*. 1977;129(1):45–48.