

Neurosurg Focus 15 (2):Article 15, 2003, Click here to return to Table of Contents

Diagnosis and management of sacral Tarlov cysts

Case report and review of the literature

**FRANK L. ACOSTA, JR., M.D., ALFREDO QUINONES-HINOJOSA, M.D.,
MEIC H. SCHMIDT, M.D., AND PHILIP R. WEINSTEIN, M.D.**

Department of Neurological Surgery, University of California, San Francisco, San Francisco, California; and University of Utah Medical Center, Salt Lake City, Utah

Perineurial (Tarlov) cysts are meningeal dilations of the posterior spinal nerve root sheath that most often affect sacral roots and can cause a progressive painful radiculopathy. Tarlov cysts are most commonly diagnosed by lumbosacral magnetic resonance imaging and can often be demonstrated by computerized tomography myelography to communicate with the spinal subarachnoid space. The cyst can enlarge via a net inflow of cerebrospinal fluid, eventually causing symptoms by distorting, compressing, or stretching adjacent nerve roots. It is generally agreed that asymptomatic Tarlov cysts do not require treatment. When symptomatic, the potential surgery-related benefit and the specific surgical intervention remain controversial. The authors describe the clinical presentation, treatment, and results of surgical cyst fenestration, partial cyst wall resection, and myofascial flap repair and closure in a case of a symptomatic sacral Tarlov cyst. They review the medical literature, describe various theories on the origin and pathogenesis of Tarlov cysts, and assess alternative treatment strategies.

KEY WORDS • sacrum • Tarlov cyst • spinal lesion • outcome

Tarlov or perineurial cysts are pathological formations located in the space between the peri- and endoneurium of the spinal posterior nerve root sheath at the DRG.^{17,39,41} These lesions have been estimated to affect between 4.6 and 9% of the adult population.^{24,34} Although originally believed by Tarlov³⁹ to be asymptomatic lesions, these cysts, when present in the sacral neural canal and foramina, have since been found to cause a variety of symptoms, including radicular pain, paresthesias, and urinary or bowel dysfunction.^{4,5,7,15,16,18,24,31,32,38,46} The development of CT myelography has led to an improvement in our ability to diagnose “Tarlov cysts” as a cause of sacral radiculopathy.^{16,17,20,21,42} Although the term Tarlov cyst has often been erroneously applied to other cystic spinal lesions,^{9,13,17,19,26,27,29,34,35} the distinctive feature of the Tarlov perineurial cyst is the presence of spinal nerve root fibers within the cyst wall, or the cyst cavity itself.^{9,17,37-41}

Despite advancements in diagnosis, there remains a great deal of controversy regarding the optimal treatment of symptomatic Tarlov cysts. Nonsurgical therapies include lumbar CSF drainage²⁴ and CT scanning-guided

cyst aspiration,^{23,24} neither of which prevents symptomatic cyst recurrence. Neurosurgical techniques for symptomatic perineurial cysts include simple decompressive laminectomy,³³ cyst and/or nerve root excision,^{20,37,38,41,42} and microsurgical cyst fenestration and imbrication.¹⁶ Although no consensus exists on the definitive treatment of symptomatic Tarlov cysts, we believe surgical methods have yielded the best long-term results to date. We describe the case of one patient with a symptomatic Tarlov cyst to illustrate the surgical treatment involving cyst fenestration, partial resection of the cyst wall, and myofascial-cutaneous flap closure reinforcement. We also review the literature, summarizing various theories on the origin and pathogenesis of Tarlov cysts, and assess current treatment options.

CASE REPORT

Presentation. This 47-year-old woman presented with a 1-year history of progressive, intractable sacrococcygeal pain and numbness as well as dysesthesias of both feet. At the time, she was becoming increasingly incapacitated, although she was still able to work as a flight attendant. She rated her pain as 6 of 10 possible points on a visual analog scale. Her symptoms were aggravated by standing,

Abbreviations used in this paper: CSF = cerebrospinal fluid; CT = computerized tomography; DRG = dorsal root ganglion; MR = magnetic resonance.

walking, lifting, and climbing stairs as well as by coughing. Pain was rapidly relieved by recumbency. She had a history of renal calculi. She had no bowel or bladder dysfunction, and sensation for urination and defecation was normal.

Examination. On physical examination, a grade of 5/5 strength was demonstrated throughout all muscle groups. Heel and toe walking and knee bends were well performed. Straight leg raising was negative. Jugular compression test induced sacrococcygeal paresthesias without pain. Sensory examination showed diminished sensory perception to pinprick on the soles of her feet and in the S1–2 distribution. There was no sensory deficit over the perineum. Anal sphincter tone and constriction were normal. Knee jerks were hyperreflexive with a Grade 4+ response bilaterally, and ankle jerks were Grade 2+ bilaterally. Lumbar flexion seemed to relieve the pain, whereas extension made it worse.

Preoperative MR imaging demonstrated a large sacral cyst arising within the thecal sac at S-2, with expansion of the osseous sacral central canal and enlargement of S-1 and S-2 neural foramina causing compression of all adjacent nerve roots. Postmyelography CT scanning revealed evidence of cauda equina compression. The cyst did not fill with contrast material and appeared to have no communication with the spinal subarachnoid space (Fig. 1).

Operation. To relieve progressively incapacitating symptoms, surgery was recommended. After sacral laminectomy, microsurgical cyst fenestration was performed with the assistance of intraoperative electromyographic monitoring. Muscle flap closure reinforcement was conducted as described previously.¹⁶ Briefly, after exposure of the S2–S4 sacral nerve roots, a large meningeal cyst was identified arising from the S-2 nerve root. The thin transparent cyst wall membrane was widely fenestrated with a scalpel and microscissors. Clear fluid contents of the cyst drained spontaneously. The posterolateral wall of the cyst was resected after electrical stimulation verified that no motor nerve fibers were present. Anal sphincter electromyography was activated by low intensity 0.4 mA electrical stimulation applied to the anterior and medial surfaces of the cyst wall. Although rapid high-volume drainage of

CSF from the rostral subarachnoid space was not observed, some seepage did occur, indicating that microscopic communication was present.

Fibrin glue was then applied to fill the cyst cavity. To prevent cyst recurrence or CSF leakage, a sacral spinalis muscle flap was then rotated into the epidural space created by evacuation of the S2–S4 cyst. Cyst closure was also supported using a lumbar subarachnoid drain for postoperative CSF diversion (Fig. 2). Although the cyst wall specimen was sent to the laboratory for pathological examination, its volume was inadequate to determine whether nerve root fibers were present.

Postoperative Course. The patient's postoperative course was uneventful. The lumbar drain was removed on postoperative Day 3, and a CT myelography revealed a very small amount of contrast exiting from the thecal sac to surround the myocutaneous flap. There was only mild indentation of the posterior thecal sac (Fig. 3). She noted marked improvement in her pain symptoms prior to discharge home on Day 4 postoperatively. During the follow-up visit 5 weeks later, she reported that the burning in her

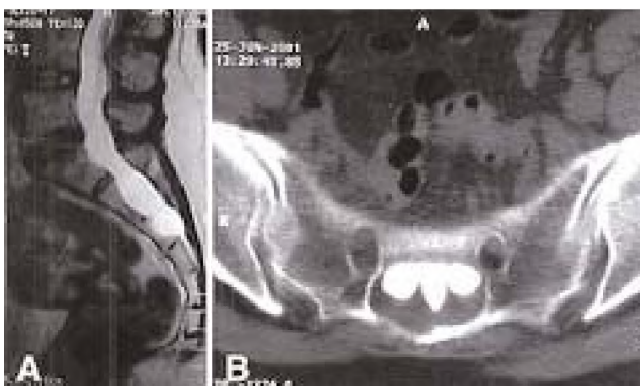


Fig. 1. Preoperative imaging studies. A: Sagittal T₂-weighted MR image revealing a high signal intensity cystic lesion in the sacral spinal canal. B: Axial CT myelogram of the sacrum demonstrating a Tarlov cyst.

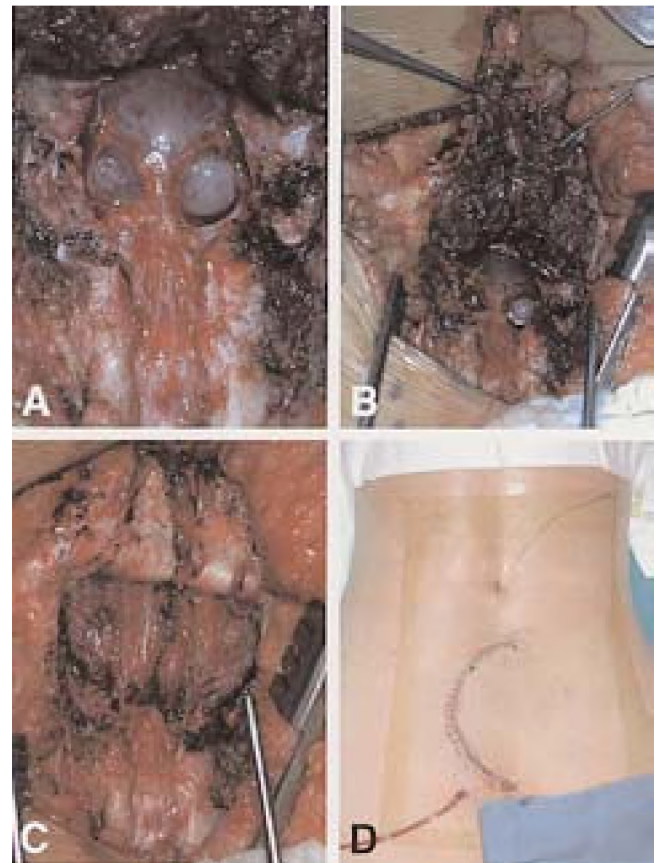


Fig. 2. A: Intraoperative view of a large Tarlov cyst. B: Intraoperative view of the muscle flap, divided in the middle, used for the obliteration of the cystic space. C: Intraoperative view after cyst wall resection showing sacral spinalis muscle flap rotated into position in the presacral space to obliterate the cyst cavity. D: Photograph obtained immediately after closure, demonstrating a U-shaped incision over the lumbosacral area, with a lumbar subarachnoid drain placed for postoperative CSF diversion.

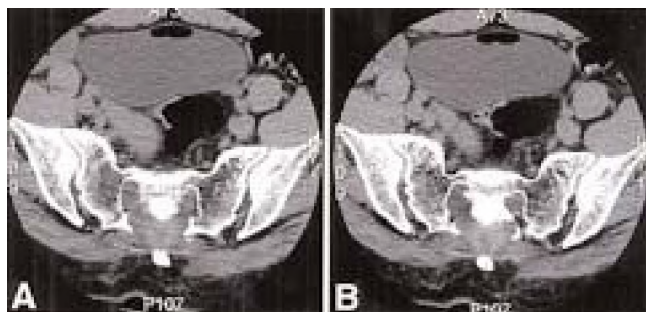


Fig. 3. A and B: Postoperative CT myelograms demonstrating obliteration of the cyst cavity with a muscle graft occupying the space formerly filled by the cyst.

feet had resolved; however, she experienced some intermittent residual sacral coccygeal and retrorectal pain, which was much less severe than it had been preoperatively. There were no focal sensory or motor deficits. Subsequent communication from the patient indicated that further resolution of residual pain occurred slowly over the ensuing 3 months.

DISCUSSION

Definition and Classification of Tarlov Cysts

Tarlov’s original description of “perineurial cysts” was reported in 1938 and based on observations made during dissection of 30 cadaveric terminal filum specimens at the Montreal Neurological Institute.³⁹ He noted extradural cysts, often multiple, on portions of the posterior sacral and coccygeal nerve roots in five of these specimens. On histological examination, he found that these cysts were located in the perineurial space, between the endo- and perineurium at the junction of the posterior nerve root and its ganglion. These lesions either surrounded the entire nerve root or invaded it and became surrounded by compressed nerve fibers. Based on this and later studies, Tarlov^{38,39,41} distinguished perineurial cysts from meningeal diverticula on the basis of three main findings (Table 1). First, Tarlov cysts have a potential, but not an actual, communication with the spinal subarachnoid space and thus may exhibit delayed filling or lack of filling on myelographic examination. Meningeal diverticula, on the other hand, are in free communication with the spinal subarachnoid space and thus usually fill initially during myelography. Second, Tarlov cysts occur at or distal to the junction of the posterior nerve root and the DRG, usually in the

sacral region. In comparison, meningeal diverticula occur proximal to the DRG and develop throughout the vertebral column, most often at thoracic levels. Last, Tarlov cysts occur in the perineurial space and have at least part of their wall composed of nerve fibers or ganglion cells. Conversely, meningeal diverticula have a wall lined with arachnoid mater, with or without a dural covering, and do not contain nerve fibers. Moreover, Tarlov noted that perineurial cysts, although often asymptomatic, were capable of producing clinical symptoms, whereas meningeal diverticula were more often asymptomatic. Tarlov⁴¹ also distinguished perineurial cysts from “unusually long arachnoidal prolongations over nerve roots,” which he asserted were of no pathological significance.

Despite Tarlov’s efforts, a great deal of confusion continues to exist over the precise definition of Tarlov cysts and their distinction from other spinal cysts. Tarlov cysts have been referred to as perineurial cysts,^{7,37–41,45,46} nerve root diverticula,³⁵ meningeal cysts,²³ sacral cysts,^{31,32} arachnoid cysts,^{27–29} and arachnoid pouches.¹³ Two recent classifications have been described in an effort to standardize cyst-related nomenclature and diagnosis (Table 2).^{9,17} Goyal, et al.,⁹ classified intraspinal cysts according to five categories: 1) perineurial or Tarlov cyst (Strully “nerve root diverticulum”³⁵); 2) nerve root sleeve dilation, 3) intradural arachnoid cyst; 4) extradural arachnoid cyst; and 5) traumatic nerve root cyst. More recently, Nabors, et al.,¹⁷ divided spinal meningeal cysts into three categories: Type I or “extradural meningeal cysts without spinal nerve root fibers”; Type II or “extradural meningeal cysts with spinal nerve root fibers” (that is, Tarlov cysts); and Type III or “spinal intradural meningeal cysts.” These authors noted that CT myelography usually demonstrated that both Tarlov cysts and spinal nerve root diverticula have a communication, albeit delayed, with the spinal subarachnoid space, and are actually the same lesion. Thus, CT myelography has enhanced our understanding of Tarlov cysts and has led to a revision of Tarlov’s original hypothesis that perineurial cysts do not communicate with the subarachnoid space. However, CT scans must be obtained with the lumbosacral spine in dependent position and delayed 30 to 60 minutes after subarachnoid contrast injection to avoid missing a microscopic communication. Regardless of the nomenclature or classification system, the defining feature of Tarlov perineurial cyst is the presence of spinal nerve root fibers within the cyst wall or within the cyst cavity itself.^{9,17,37–41} Thus, although CT myelography and MR imaging are useful tools, the final diagnosis of a Tarlov cyst is not a radiological one; rather, it is a histopathological one.

TABLE 1
Tarlov’s classification of spinal cysts*

Lesion	Communication W/ SS	Filling Pattern on Myelography	Location Along Nerve Root	Nerve Fibers W/in Cyst
perineurial cysts (Tarlov cysts)	no	delayed filling	at or distal to junction of pst nerve root & DRG	yes
meningeal diverticula	yes	rapid filling	proximal to DRG	no
long arachnoidal prolongations	yes	rapid filling	continuous prolongation of SS over nerve root	NA†

* NA = not applicable; pst = posterior; SS = subarachnoid space.

† Although these can be confused with meningeal diverticula and perineurial cysts, arachnoidal prolongations are not actual cystic lesions.

TABLE 2
Current classification systems for spinal cysts

Classification, Authors & Year	Nomenclature	Description
Goyal, et al., 1987	perineurial cyst/Tarlov cyst	cyst formation w/in nerve root sheet at DRG
	root sleeve dilation	enlargement of SS around nerve root proximal to DRG
	intradural arachnoid cyst	arachnoid pockets w/in thecal sac
	extradural arachnoid cyst	arachnoid outpouching through dural defect
Nabors, et al., 1988	traumatic root cyst	traumatic tear in leptomeninges causing CSF collection
	Type I	extradural meningeal cyst w/out nerve root fibers
	Type II (Tarlov cyst)	extradural meningeal cyst w/ nerve fibers
	Type III	intradural spinal meningeal cyst

Signs and Symptoms of Tarlov Cysts

In his original description,³⁹ Tarlov noted that perineurial cysts developed in asymptomatic patients, although he later speculated that these cysts could cause sacral radiculopathy when he noted that resection of a cyst relieved one woman of sciatic pain.³⁷ Although they most often affect S-2 and S-3 nerve roots,³² Tarlov cysts have been found to occur anywhere in the cervical, thoracic, and lumbar spine.^{8,12,17,19,22,32,36,40,41} Most are diagnosed as incidental findings on CT or MR imaging. Approximately one fifth of Tarlov cysts are symptomatic and can produce, according to their anatomical location,¹⁶ a variety of symptoms of nerve root compression (Table 3). Sacral cysts have been noted to cause sacral radiculopathy, hip, leg, or foot pain, perineal pain, paresthesias, and bowel or bladder dysfunction.^{1,2,5,7,18,24,30–32,35–38,40,41,46} Symptoms can be exacerbated by standing, coughing, or other Valsalva maneuvers, because elevated subarachnoid pressure forces CSF from the spinal subarachnoid space through a small ball valve–like communication into the perineurial cyst cavity.^{16,36} Tarlov cysts may also cause diffuse poorly localized sacral pain due to pressure on adjacent periosteum and joint capsules and can also result in sacral insufficiency fractures from erosion of the sacrum.^{9,25} Thoracic Tar-

lov cysts have even been noted to cause angina-like symptoms.¹¹

Tarlov cysts can also cause various objective neurophysiological abnormalities, including decreased sural nerve action potentials and sensory nerve conduction velocities.^{5,46} Tarlov cysts cause mostly sensory disturbances, because of their location at the DRG. Accordingly, motor nerve conduction is often normal in patients harboring these cysts.⁵ Bladder dysfunction can be documented by cystometrographic studies, and sexual impotence was observed in our previous series.¹⁶

Radiological Features

Tarlov cysts are associated with a variety of radiological findings. Initial plain radiographic examination may reveal Tarlov cysts causing erosion of the sacrum, bone scalloping, or a rounded paravertebral shadow.^{1,6,14,32,35,41} Schrieber and Haddad³¹ were the first to demonstrate that Tarlov cysts exhibited a characteristic delayed filling pattern on oil-based pantopaque contrast–enhanced myelography. This pattern, in which Tarlov cysts do not immediately fill with oil-based contrast but can later be visualized hours, days, or weeks later to contain contrast, has since been described by several authors,^{20,31–33,35,36,41} and was one of the criteria used by Tarlov⁴¹ to distinguish perineurial

TABLE 3
Clinical and radiological characteristics of Tarlov cysts*

Authors & Year	No. of Cases	Location of Cysts	Presenting Symptoms	Radiological Exam	
				Modality	Findings
Nabors, et al., 1988	9	sacral (S2–3)	sacral radicular pain in 5; low-back pain in 4; bladder dysfunction in 2; coccydynia in 1; abdominal pain in 1; headache in 1	CTM alone in 5; CTM + MRI in 2; MRI alone in 1; MRI + conventional myelography in 1	MRI showed spinal cyst in 4 of 4 patients; CTM showed communication w/SS in 7 of 7†
Mummaneni, et al., 2000	8	sacral (S1–3)	sacral radicular pain in 8; motor deficits in 4; bladder dysfunction in 3; impotence in 1	MRI in all; CTM in 6	MRI confirmed spinal cyst in all; CTM showed communication w/SS in 5 of 6
Voyadzis, et al., 2002	10	sacral (S1–3) in all; L-5 meningeal diverticulum in 1	sacral radicular pain in 7; anal &/or bladder dysfunction in 3; coccydynia in 2; dyspareunia in 2; low-back pain in 1	CTM in all; MRI in some‡	CTM showed communication with SS in all; MRI demonstrated spinal cyst in at least 1‡

* CTM = CT myelography.

† In one patient with multiple sacral nerve root cysts, CT myelography showed all but one cyst to communicate with the SS.

‡ The number of patients who underwent preoperative MR imaging is not reported.

cysts from meningeal diverticula. Because Tarlov cysts have only a potential, or very small communication with the subarachnoid space, the visualization of the cyst cavity on myelography occurs as a result of a much slower process in which contrast is forced, via the hydrostatic pressure of CSF, from the subarachnoid space through this small aperture or by transudation across the cyst wall membrane, into the perineurial cyst cavity.⁴¹ Meningeal diverticula, on the other hand, having a relatively greater communication with the spinal subarachnoid space, can be seen to fill with oil-based contrast immediately after injection during myelography.⁴¹ Tarlov cysts can, however, often be seen to fill more rapidly on myelography with lower viscosity water-soluble contrast materials (metrizamide).^{20,21,41} The authors of other studies have found Tarlov cysts to have no communication with the spinal subarachnoid space, thus only producing an extraarachnoid filling defect on myelography.^{1,32,45}

Computerized tomography scanning, both with and without intrathecal contrast material, has enhanced our ability to detect perineurial cysts. These lesions are isodense with CSF on noncontrast CT scans^{21,45} and can often be seen to cause various osseous abnormalities and erosions.^{7,33} Postmyelography CT scanning is effective in demonstrating the presence of a communication of the cyst with the spinal subarachnoid space, and it can also demonstrate surrounding sacral bone scalloping.¹⁶

Because of the absence of interference from bone, enhanced resolution of tissue density, and its multiplanar imaging capabilities, MR imaging is particularly useful in studying sacral Tarlov cysts, thus, it is considered to be the preferred initial imaging modality when a sacral perineurial cyst is suspected.^{24,30} These cysts have CSF-like characteristics on MR imaging—that is, a low signal on T₁-weighted images and a high signal on T₂-weighted images.²⁴ Magnetic resonance imaging can also be used to delineate the exact relationship of the cyst to the thecal sac, as well as the total volume of fluid within the cyst.²³ It may also demonstrate bone and pedicle erosion, sacral canal widening, and neural foramina enlargement.²⁴ The senior author¹⁶ (P.R.W.) and others¹⁷ have recommended MR imaging for initial identification of a spinal cystic mass, followed by CT myelography for further delineation of cyst characteristics (Table 3).

Origin and Pathogenesis of Tarlov Cysts

In his original description, Tarlov³⁹ discovered inflammatory cells in some cyst walls and adjacent tissues, leading him to postulate that these cysts were formed by a process of inflammation within the nerve root sheath, followed by inoculation of fluid. He later noted that pantopaque contrast could initiate an inflammatory process that sealed off communication between an asymptomatic meningeal diverticulum and the subarachnoid space, creating a symptomatic perineurial cyst.⁴¹ He also described changes consistent with ischemic degeneration in some cysts.³⁹ A hemorrhagic origin was later described by Tarlov^{37,40,41} and others^{31,43,44} in which cyst formation occurs as a result of infiltrating subarachnoid hemorrhage, or traumatic intraneural hemorrhage, followed by cystic degeneration of red blood cells and destroyed neural tissue. Nishiura, et al.,²⁰ described a history of antecedent trauma

in 40% of their patients with Tarlov cysts. Schreiber and Haddad³¹ and Strully and Heiser³⁶ noted that cysts can form as a result of dural lacerations during spinal surgery, leading to pseudomeningocele formation. Some authors favor a congenital origin and hypothesize that these cysts can arise from a congenital dural diverticulum or weakness, or from persistent embryonic fissures.^{12,22,35} Tarlov cysts have been associated with other congenital abnormalities, connective tissue disorders, and nerve root sheath duplications.^{3,8,10,14,19,27,42} Rexed alone²⁸ and with Wennstrom²⁹ argued that the cysts occur as a result of proliferation of arachnoid mater, followed by a closure of the communication between the arachnoid proliferations and the spinal subarachnoid space. Finally, some authors have ascribed the hydrostatic pressure of CSF as the causative factor in cyst formation.^{24,34,35} They argued that the hydrostatic pressure of CSF is exerted along the spinal subarachnoid space and is elevated with arterial pulsations or Valsalva maneuvers. This acts to force CSF into the normally obliterated perineurial space, while outflow is restricted because of a ball-valve effect. Cysts subsequently enlarge by means of this mechanical “pulsatile” CSF action, and become symptomatic by displacing adjacent nerve roots.^{22,24}

Natural History and Treatment of Symptomatic Tarlov Cysts

Although most remain asymptomatic throughout the patient's life, the natural history of symptomatic Tarlov cysts is one of progressive enlargement leading to increasing symptoms. The hydrostatic and pulsatile forces of CSF cause Tarlov cysts to grow over time. As the mass enlarges, sensory nerve root filaments are stretched over the periphery of the lesion or are compressed against adjacent bone or other nerve roots, causing pain or other sensory disturbances.^{2,30,35,41}

There is no consensus on the optimal management of symptomatic Tarlov cysts. Nonsurgical methods include lumbar CSF drainage to decrease the hydrostatic pressure and therefore the pressure within the cyst cavity.² Symptoms do recur, however, after drainage is stopped.² In one case the authors found that continuous CSF drainage via a lumboperitoneal shunt was an effective therapy for symptomatic Tarlov cysts in each of two patients.² Some authors have asserted that by providing temporary symptomatic relief, lumbar CSF drainage can be a useful diagnostic tool when there is a question about the clinical significance of Tarlov cysts.^{2,4}

Another nonsurgical treatment is percutaneous cyst drainage.^{23,24} Symptoms do recur after percutaneous drainage because cysts reform, although the authors of one study asserted that percutaneous cyst aspiration and fibrin glue placement can prevent the recurrence of both the cyst and its associated symptoms.²³ In this study, 75% of the patients developed postprocedural aseptic meningitis. As a result of these findings, some authors have argued that there is no place for percutaneous cyst drainage in the treatment of these lesions.^{11,42}

Surgical treatment of symptomatic perineurial cysts, involving complete cyst removal, and excision of the affected posterior root and ganglion, was advocated by Tarlov^{37,38,41} and has since been used by others,²⁰ although

some assert that the morbidity resulting from neurological defects following this procedure is too great to justify its use, especially when dealing with multiple bilateral sacral cysts.^{4,44} Simple decompressive laminectomy has been attempted,³³ but its success rate has been low.⁴ Other surgical therapies include cyst resection at the neck,^{4,42} cyst wall resection,^{38,41,42} cyst fenestration and imbrication,^{4,16,36,46} and cyst shrinkage by using bipolar cautery.³⁰ One author described the surgical placement of a cyst-subarachnoid shunt tube to equalize pressures within the spinal subarachnoid space and the cyst cavity.¹⁵ In our experience good results have been obtained with microsurgical cyst fenestration and imbrication when using electrophysiological monitoring, along with a fat- or muscle graft-reinforced cyst closure.¹⁶ In a study conducted at our institution, seven of eight patients experienced improvement in symptoms. Bladder control improved in two of three patients with bladder dysfunction treated with cyst fenestration and imbrication. There were no postoperative complications.¹⁶ In the present case, cyst imbrication was not performed because CT myelography revealed no direct communication with the spinal subarachnoid space. We instead performed microsurgical cyst fenestration and cyst wall resection with myocutaneous flap closure reinforcement to prevent a reaccumulation of CSF or a cyst recurrence. Cyst wall resection may result in postoperative neurological deficits⁴² and should be performed during electrophysiological monitoring to minimize damage to sacral nerve roots.

Indications for Surgery

The authors of one study found that patients with Tarlov cysts greater than 1.5 cm and with associated radicular pain or bowel/bladder dysfunction benefit most from surgery.⁴² We have recommended that patients presenting with radicular pain referable to the location of a cyst should initially undergo medical treatment with anti-inflammatory drugs and physical therapy. Surgery should be reserved for that subset of patients in whom these conservative measures elicit no response. We have also found that patients presenting with symptoms exacerbated by postural changes or Valsalva maneuvers, as was true in the present case, are likely to benefit most from surgery.¹⁶

CONCLUSIONS

Tarlov cysts are a documented cause of sacral radiculopathy and other radicular pain syndromes. These lesions are diagnosed with MR imaging, which should be followed by CT myelography to demonstrate communication with the spinal subarachnoid space. Although first described over 60 years ago, there is still no uniform opinion on the origin of these cysts; they may be caused by inflammation, trauma, or congenital weakness of the dura mater combined with elevated CSF hydrostatic pressure.

Symptomatic Tarlov cysts have been treated with various techniques, including CSF drainage, percutaneous aspiration, and, excision. We have described the case of a woman with a symptomatic sacral Tarlov cyst treated successfully with cyst fenestration, cyst wall resection, and closure with myocutaneous flap reinforcement to prevent cyst recurrence or CSF leakage. Electrophysiological

monitoring is necessary to minimize damage to sacral nerve roots. Patients with radicular symptoms exacerbated by postural changes and Valsalva maneuvers are the best candidates for surgery.

References

- Abbott KH, Retter RH, Leimbach WH: The role of perineurial sacral cysts in the sciatic and sacrococcygeal syndromes. A review of the literature and report of 9 cases. **J Neurosurg** **14**: 5–21, 1957
- Bartels RH, van Overbeeke JJ: Lumbar cerebrospinal fluid drainage for symptomatic sacral nerve root cysts: an adjuvant diagnostic procedure and/or alternative treatment? Technical case report. **Neurosurgery** **40**:861–865, 1997
- Bergland RM: Congenital intraspinal extradural cyst. Report of three cases in one family. **J Neurosurg** **28**:495–499, 1968
- Caspar W, Papavero L, Nabhan A, et al: Microsurgical excision of symptomatic sacral perineurial cysts: a study of 15 cases. **Surg Neurol** **59**:101–106, 2003
- Cattaneo L, Pavesi G, Mancina D: Sural nerve abnormalities in sacral perineurial (Tarlov) cysts. **J Neurol** **248**:623–624, 2001
- Dastur HM: The radiological appearances of spinal extradural arachnoid cysts. **J Neurol Neurosurg Psychiatry** **26**:231–235, 1963
- Davis DH, Wilkinson JT, Teaford AK, et al: Sciatica produced by a sacral perineurial cyst. **Tex Med** **83**:55–56, 1987
- Gortvai P: Extradural cysts of the spinal canal. **J Neurol Neurosurg Psychiatry** **26**:223–230, 1963
- Goyal RN, Russell NA, Benoit BG, et al: Intraspinal cysts: a classification and literature review. **Spine** **12**:209–213, 1987
- Howieson J, Norrell HA, Wilson CB: Expansion of the subarachnoid space in the lumbosacral region. **Radiology** **90**: 488–492, 1968
- Kumar K, Malik S, Schulte PA: Symptomatic spinal arachnoid cysts: report of two cases with review of literature. **Spine** **28**: E25–E29, 2003
- Lombardi G, Morello G: Congenital cysts of the spinal membranes and roots. **Br J Radiol** **36**:197–205, 1963
- McCrum C, Williams B: Spinal extradural arachnoid pouches. Report of two cases. **J Neurosurg** **57**:849–852, 1982
- Mitchell GE, Lourie H, Berne AS: The various causes of scalloped vertebrae with notes on their pathogenesis. **Radiology** **89**:67–74, 1967
- Morio Y, Nanjo Y, Nagashima H, et al: Sacral cyst managed with cyst-subarachnoid shunt. **Spine** **26**:451–453, 2001
- Mummaneni PV, Pitts LH, McCormack BM, et al: Microsurgical treatment of symptomatic sacral Tarlov cysts. **Neurosurgery** **47**:74–79, 2000
- Nabors MW, Pait TG, Byrd EB, et al: Updated assessment and current classification of spinal meningeal cysts. **J Neurosurg** **68**:366–377, 1988
- Nadler SF, Bartoli LM, Stitik TP, et al: Tarlov cyst as a rare cause of S1 radiculopathy: a case report. **Arch Phys Med Rehabil** **82**:689–690, 2001
- Nathan H, Rosner S: Multiple meningeal diverticula and cysts associated with duplications of the sheaths of spinal nerve posterior roots. **J Neurosurg** **47**:68–72, 1977
- Nishiura I, Koyama T, Handa J: Intracanalicular perineurial cyst. **Surg Neurol** **23**:265–269, 1985
- North RB, Kidd DH, Wang H: Occult, bilateral anterior sacral and intracanalicular meningeal and perineurial cysts: case report and review of the literature. **Neurosurgery** **27**:981–986, 1990
- Nugent GR, Odom GL, Woodhall B: Spinal extradural cysts. **Neurology** **9**:397–406, 1959
- Patel MR, Louie W, Rachlin J: Percutaneous fibrin glue therapy of meningeal cysts of the sacral spine. **AJR** **168**:367–370, 1997

Diagnosis and management of sacral Tarlov cysts

24. Paulsen RD, Call GA, Murtagh FR: Prevalence and percutaneous drainage of cysts of the sacral nerve root sheath (Tarlov cysts). **AJNR** **15**:293–297, 1994
25. Peh WC, Evans NS: Tarlov cysts—another cause of sacral insufficiency fractures? **Clin Radiol** **46**:329–330, 1992
26. Raja IA, Hankinson J: Congenital spinal arachnoid cyst: report of two cases and review of literature. **J Neurol Neurosurg Psychiatry** **33**:105–110, 1970
27. Rengachary SS, O'Boynick P, Karlin CA, et al: Intrasacral extradural communicating arachnoid cyst: case report. **Neurosurgery** **8**:236–240, 1981
28. Rexed B: Arachnoidal proliferations with cyst formation in human spinal nerve roots at their entry into the intervertebral foramina. Preliminary report. **J Neurosurg** **4**:414–421, 1947
29. Rexed BA, Wennstrom KG: Arachnoidal proliferations and cystic formation in the spinal nerve-root pouches of man. **J Neurosurg** **16**:73–84, 1959
30. Rodziewicz GS, Kaufman B, Spetzler RF: Diagnosis of sacral perineural cysts by nuclear magnetic resonance. **Surg Neurol** **22**:50–52, 1984
31. Schreiber F, Haddad B: Lumbar and sacral cysts causing pain. **J Neurosurg** **8**:504–509, 1951
32. Seaman WB, Furlow LT: The myelographic appearance of sacral cysts. **J Neurosurg** **13**:88–94, 1956
33. Siqueira EB, Schaffer L, Kranzler LI, et al: CT characteristics of sacral perineural cysts. Report of two cases. **J Neurosurg** **61**:596–598, 1984
34. Smith DT: Cystic formations associated with human spinal nerve roots. **J Neurosurg** **18**:654–660, 1961
35. Strully KJ: Meningeal diverticula of sacral nerve roots (perineural cysts). **JAMA** **161**:1147–1152, 1956
36. Strully KJ, Heiser S: Lumbar and sacral cysts of meningeal origin. **Radiology** **62**:544–549, 1954
37. Tarlov IM: Cysts (perineurial) of the sacral roots: another cause (removable) of sciatic pain. **JAMA** **138**:740–744, 1948
38. Tarlov IM: Cyst of the sacral nerve roots: clinical significance and pathogenesis. **Arch Neurol Psychiatry** **68**:94–108, 1952
39. Tarlov IM: Perineural cysts of the spinal nerve roots. **Arch Neurol Psychiatry** **40**:1067–1074, 1938
40. Tarlov IM: **Sacral Nerve-Root Cysts: Another Cause of the Sciatic or Cauda Equina Syndrome**. Springfield, IL: Charles C. Thomas, 1953, pp 56–116
41. Tarlov IM: Spinal perineurial and meningeal cysts. **J Neurol Neurosurg Psychiatry** **33**:833–843, 1970
42. Voyadzis JM, Bhargava P, Henderson FC: Tarlov cysts: a study of 10 cases with review of the literature. **J Neurosurg (Spine)** **95**:25–32, 2001
43. Wilkins RH: Intrasacral cysts, in Wilkins RH, Rengachary SS (eds): **Neurosurgery**. New York: McGraw-Hill, 1985, pp 2061–2070
44. Wilkins RH: Prevalence and percutaneous drainage of cysts of the sacral nerve root sheath (Tarlov cysts). (Commentary) **AJNR** **15**:298–299, 1994
45. Willinsky RA, Fazl M: Computed tomography of a sacral perineural cyst. **J Comput Assist Tomogr** **9**:599–601, 1985
46. Yucesoy K, Naderi S, Ozer H, et al: Surgical treatment of sacral perineural cysts. A case report. **Kobe J Med Sci** **45**:245–250, 1999

Manuscript received June 30, 2003.

Accepted in final form July 17, 2003.

Address reprint requests to: Alfredo Quinones-Hinojosa, M.D., Department of Neurological Surgery, University of California, San Francisco, 505 Parnassus Avenue, M-780C, San Francisco, California 94143-0112. email: quinones@neurosurg.ucsf.edu.